Study Guide 3

This guide covers chapters 5 and 6. First you build the neurological map: how a spinal nerve forms, the borders of the foramen, the dermatome and myotome anchors, the reflex arc, upper versus lower motor neuron signs, which root a disc hits, and the entrapments that mimic a root. Then you learn why pain does not match damage: nociception versus pain, sensitization, the gate, the descending system, chronic pain and how to explain it. Work one chapter at a time, try each worked case with the steps covered, and finish with the ten board style self-test items. The cram sheet holds every level, number and rule.

WHAT THIS GUIDE COVERS

- Chapter 5 · dorsal and ventral roots and rami, 31 pairs and the exit rule, the foramen, dermatomes and key sensory points, myotomes and the MRC scale, the stretch reflex and its levels, UMN versus LMN signs, radicular versus referred pain, herniation zones, neurodynamic tests, red flags and peripheral entrapments.
- Chapter 6 · pain versus nociception, the four processes, fiber types and the spinothalamic tract, nociceptive, neuropathic and nociplastic pain, peripheral and central sensitization, gate control, descending modulation, placebo and nocebo, chronic pain, the biopsychosocial and fear avoidance models, and pain neuroscience education.

CHAPTER 5

Nerve Roots, Dermatomes and Reflexes

Read it in full: **Chapter 5 in the textbook**. See it in motion: **Nerve Roots Walkthrough** and **Nerve Roots Lab**.

What to know

Rootlets gather into a **dorsal root** (purely sensory, cell bodies in the dorsal root ganglion) and a **ventral root** (motor: alpha and gamma motor axons, plus preganglionic autonomic fibers at T1 to L2 and S2 to S4). Just beyond the DRG, usually inside the foramen, they merge into a short mixed **spinal nerve** about a centimeter long. It splits into a small **dorsal ramus** (deep back muscles,

back skin and, through its medial branch, the facet joints) and a larger **ventral ramus** (front and sides of the trunk and the limbs). Ventral rami form the cervical (C1 to C4), brachial (C5 to T1), lumbar (L1 to L4) and sacral (L4 to S4) plexuses. White rami exist only at T1 to L2; gray rami reach every spinal nerve. The sinuvertebral nerve supplies the PLL, outer third of the annulus and anterior dura.

There are 31 pairs: 8 cervical, 12 thoracic, 5 lumbar, 5 sacral and 1 coccygeal. C1 to C7 exit above the same numbered vertebra, C8 exits between C7 and T1, and every nerve from T1 down exits below its vertebra. So a posterolateral C5 to C6 herniation usually gives a C6 radiculopathy. The cord ends near the L1 to L2 disc, so a large central lumbar herniation compresses cauda equina roots, giving a lower motor neuron picture with saddle numbness and bladder change rather than spasticity.

The **intervertebral foramen** has the pedicle above as its roof, the pedicle below as its floor, the bodies and disc in front (plus the uncovertebral joint in the neck) and the facet joint with the ligamentum flavum behind. In the lumbar spine the root takes up about a third to a half of the foramen and rides high, under the upper pedicle, above the disc, so disc height loss squeezes it. In the neck the foramen is a gutter at about 45 degrees, and foraminal stenosis from uncovertebral and facet spurs is the most frequent cause of cervical radiculopathy, ahead of soft disc herniation. Flexion opens the foramen; extension, same side bending and rotation close it. Compression alone tends to cause numbness or weakness; pain needs inflammation too (phospholipase A2, TNF alpha and venous congestion).

A **dermatome** is skin supplied by one root; a **myotome** is the muscles supplied mainly by one root. Limb buds rotate (the upper limb laterally, the lower limb medially), so leg dermatomes spiral and the big toe is L5 while the little toe is S1. Maps overlap, disagree and vary between people, so test key points near the center of each dermatome. Trunk anchors: nipple T4, xiphoid T6, umbilicus T10, inguinal ligament T12 to L1. C4 sits next to T2 on the upper chest.

Key sensory points: C5 lateral antecubital fossa, C6 thumb, C7 middle finger, C8 little finger, T1 medial antecubital fossa, L2 mid anterior thigh, L3 medial femoral condyle, L4 medial malleolus, L5 dorsum of the foot at the third MTP joint, S1 lateral heel, S2 popliteal fossa, S3 to S5 the saddle. Strength uses the MRC scale: 0 none, 1 flicker, 2 movement with gravity eliminated, 3

against gravity, 4 against some resistance, 5 normal. Most root weakness is grade 4, so add functional tests: ten single leg heel raises for S1, heel walking for L4 and L5, step up for L3 and L4.

A root lesion is likely when sensation, strength and reflexes agree on one level on one side and match the pain. A peripheral nerve lesion has sharp sensory borders that cut across dermatomes and weakness limited to one nerve's muscles. Light touch tests large fibers (dorsal columns); pinprick tests small fibers (spinothalamic). Paresthesia is tingling, hypoesthesia is reduced feeling, dysesthesia is unpleasant burning and allodynia is pain from harmless touch.

The **stretch reflex** is monosynaptic: the tap stretches the muscle, spindles fire **Ia afferents** that synapse directly on alpha motor neurons of the same muscle, and a branch drives a Ia inhibitory interneuron that relaxes the antagonist (**reciprocal inhibition**). Golgi tendon organs signal tension through Ib fibers (autogenic inhibition). Gamma motor neurons set spindle sensitivity, so the brain turns reflexes up and down. Levels: biceps C5, brachioradialis C6, triceps C7 (the most common reflex loss in cervical radiculopathy), patellar L4, medial hamstring L5 (unreliable), Achilles S1.

Grade reflexes 0, 1+, 2+ (normal), 3+ and 4+ (often with sustained clonus). Asymmetry matters more than the grade. Ankle reflexes often fade after about 60. Use the Jendrassik maneuver before calling a reflex absent; a reflex seen only with reinforcement is 1+. Upper motor neuron lesions give spasticity, hyperreflexia, clonus, an extensor plantar response and little early wasting. Lower motor neuron lesions give flaccid weakness, reduced reflexes, marked atrophy and sometimes fasciculations. **Babinski** (normal up to about one to two years), **Hoffmann** and sustained clonus (more than about four or five beats) point to the brain or cord. An inverted brachioradialis response suggests myelopathy at C5 to C6. Cervical spondylotic myelopathy is the most common cause of cord dysfunction in older adults.

Four terms differ. **Radicular pain** comes from an irritated root or DRG: shooting, electric, narrow, often below the knee. **Radiculopathy** is objective loss of root function: numbness, weakness or a reduced reflex. **Somatic referred pain** comes from disc, facet, SI joint, ligament or muscle: deep, dull, vague, usually above the knee, no neurological deficit; it is explained by convergence in the dorsal horn. **Visceral referred pain** comes from organs: heart to chest, left arm and jaw; diaphragm (C3 to C5) to the shoulder tip; gallbladder to below the right scapula;

kidney to flank and groin; pancreas and a leaking aortic aneurysm through to the mid back. Sciatica is a lay term; replace it after the exam.

About 90 to 95% of symptomatic lumbar herniations are at L4 to L5 or L5 to S1. Positions from the midline out: central, subarticular (paracentral, lateral recess), foraminal and extraforaminal (far lateral). Subarticular L4 to L5 hits the traversing L5; at L5 to S1 it hits S1. Foraminal or far lateral L4 to L5 hits the exiting L4 and its DRG, often very painfully. A large central herniation can compress several roots on both sides. In the neck, C7 is the most common root, then C6.

The **straight leg raise** is positive when familiar leg pain below the knee appears between about 30 and 70 degrees; back pain or hamstring stretch alone is not positive. It is sensitive (about 0.9 in surgical populations) but not specific, so a negative SLR helps rule out herniation. The **crossed SLR** is specific. The slump test releases neck flexion to tell neural from muscular pain; the prone knee bend tensions L2 to L4. **Spurling** (extension, side bend and rotation toward the painful side with gentle pressure) is specific; the upper limb tension test is sensitive; shoulder abduction relief supports a root source. SnNout and SpPin.

Most disc related radicular pain improves within 6 to 12 weeks, and extruded or sequestered fragments are the most likely to regress. MRI is for red flags, progressive deficits or symptoms past about six weeks when results would change care. In radiculopathy, sensory nerve action potentials are typically normal because the lesion is proximal to the DRG; EMG may show denervation after about two to three weeks. Emergencies: cauda equina syndrome (saddle numbness, new retention or incontinence, bilateral leg symptoms; same day imaging and surgical assessment), progressive or severe weakness such as a new foot drop, myelopathy, and radicular pain with fever, cancer history or weight loss.

Entrapment starts with venous congestion at only about 20 to 30 mmHg, then edema, demyelination and axon loss. Injury grades: neurapraxia (conduction block, recovers in days to weeks), axonotmesis (regrowth about 1 mm a day) and neurotmesis (needs repair). **Carpal tunnel**: median nerve with nine tendons under the transverse carpal ligament; night numbness of the thumb to the radial ring finger; **thenar skin is spared** because the palmar cutaneous branch passes over the ligament. Cubital tunnel (ulnar at the elbow; Froment sign), Guyon canal (spares dorsal hand sensation), radial nerve at the spiral groove (wrist drop with triceps spared), thoracic

outlet (C8 and T1), meralgia paresthetica (purely sensory outer thigh), **common fibular palsy** (foot drop with normal inversion and hip abduction, unlike L5), tarsal tunnel, Morton neuroma and deep gluteal syndrome.

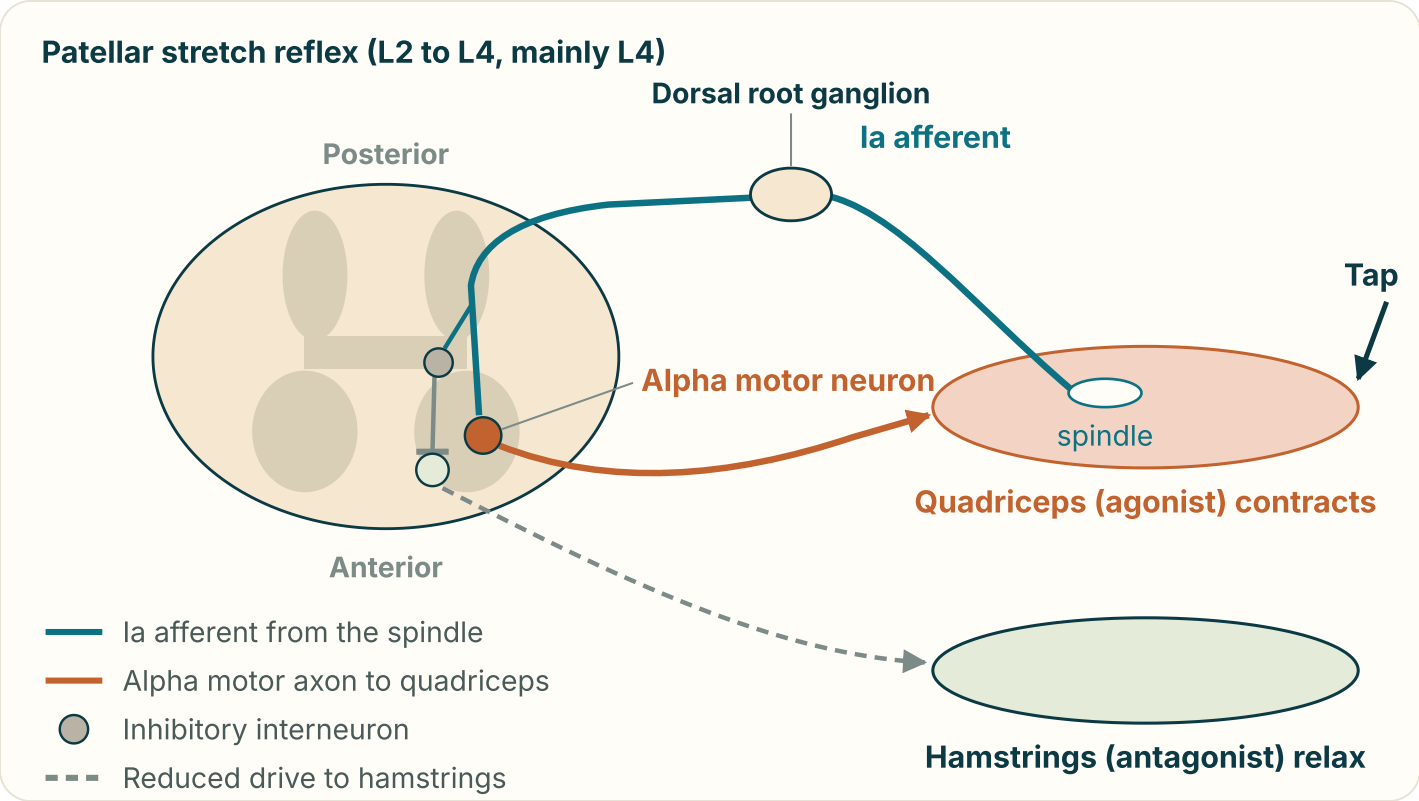

One synapse, plus a brake on the antagonist. The Ia afferent synapses directly on the alpha motor neuron of the same muscle, which makes the reflex monosynaptic; a branch drives an inhibitory interneuron so the antagonist relaxes. Levels: biceps C5, brachioradialis C6, triceps C7, patellar L4, Achilles S1.

LOCK THESE IN

- 31 pairs: 8 C, 12 T, 5 L, 5 S, 1 Co. C8 exits between C7 and T1.
- Dorsal root sensory (DRG); ventral root motor. Dorsal ramus: back muscles and facets. Ventral ramus: plexuses and limbs.
- Anchors: C6 thumb, C7 middle finger, C8 little finger, T4 nipple, T10 umbilicus, L4 medial malleolus, L5 big toe, S1 lateral foot.
- Reflexes: biceps C5, brachioradialis C6, triceps C7, patellar L4, Achilles S1.
- Radiculopathy is defined by objective signs, not by pain.
- Paracentral herniation hits the traversing root; far lateral hits the exiting root.
- SLR sensitive, rules out. Crossed SLR and Spurling specific, rule in.
- Foot drop with normal inversion and hip abduction: fibular nerve, not L5.

Root syndromes

Root (usual disc)	Pain and sensory change	Weakness	Reflex
C5 (C4 to C5)	Shoulder and lateral upper arm	Shoulder abduction, elbow flexion	Biceps reduced
C6 (C5 to C6)	Lateral forearm, thumb, index finger	Elbow flexion, wrist extension	Brachioradialis and biceps
C7 (C6 to C7)	Back of arm and forearm, middle finger	Elbow extension, wrist flexion, finger extension	Triceps reduced
C8 (C7 to T1)	Medial forearm, ring and little fingers	Finger flexion, hand intrinsics	No standard reflex
L4 (L3 to L4; far lateral L4 to L5)	Anterior thigh, medial leg to medial malleolus	Knee extension, ankle dorsiflexion	Patellar reduced
L5 (L4 to L5)	Lateral leg, dorsum of foot, big toe	Great toe extension, dorsiflexion, inversion, hip abduction	Usually none
S1 (L5 to S1)	Back of calf, lateral foot, sole, little toe	Plantar flexion, eversion, hip extension	Achilles reduced

Entrapments that mimic roots

Entrapment	Nerve and site	How to tell it from a radiculopathy
Carpal tunnel	Median, at the wrist	Thenar skin spared; reflexes and proximal strength normal (vs C6 or C7)
Cubital tunnel	Ulnar, at the elbow	Medial forearm sensation normal; index finger flexors spared (vs C8)
Radial at spiral groove	Radial, mid humerus	Triceps spared; no neck pain (vs C7)
Thoracic outlet	Lower trunk of the plexus, vessels	Positional and vascular features; neck movement does not reproduce it
Meralgia paresthetica	Lateral femoral cutaneous, near the ASIS	Purely sensory; no weakness or reflex change (vs L2 or L3)
Fibular nerve palsy	Common fibular, fibular neck	Inversion and hip abduction normal; no back pain (vs L5)
Tarsal tunnel	Tibial, behind the medial malleolus	Achilles reflex and calf strength normal (vs S1)

Worked cases

WORKED CASE 1 · PLACING A LUMBAR LESION

A 41 year old has shooting pain from the buttock down the back of the calf to the lateral foot. The right Achilles reflex is absent (left 2+), he cannot do ten single leg heel raises on the right, and the straight leg raise reproduces his leg pain at 45 degrees. Which root and which disc?

STEP 1 · READ THE SENSORY PATTERN

Back of the calf, lateral foot and sole belong to **S1**.

STEP 2 · READ THE MOTOR AND REFLEX FINDINGS

Weak plantar flexion and an absent Achilles reflex on one side both point to S1.

STEP 3 · CHECK THE PROVOCATION TEST

Leg pain below the knee between 30 and 70 degrees is a positive SLR for L5 or S1 irritation.

STEP 4 · NAME THE DISC

A posterolateral (subarticular) herniation at **L5 to S1** catches the traversing S1 root.

SCREEN FOR RED FLAGS

Ask about saddle numbness, bladder or bowel change and progressive weakness before planning conservative care.

WORKED CASE 2 · ROOT OR NERVE: FOOT DROP

A patient developed foot drop after weeks of crossing her legs while losing weight. Dorsiflexion and eversion are weak and the dorsum of the foot is numb. Inversion and hip abduction are strong, she has no back pain and the SLR is negative. Root or nerve?

STEP 1 · LIST THE SHARED FINDINGS

Weak dorsiflexion with dorsal foot numbness fits both L5 radiculopathy and common fibular nerve palsy.

STEP 2 · TEST THE SEPARATING MUSCLES

Inversion (tibialis posterior, tibial nerve) and hip abduction (gluteus medius, superior gluteal nerve) share the L5 root but not the fibular nerve.

STEP 3 · INTERPRET

Both are strong, so the lesion is distal to the root: **common fibular nerve** at the fibular neck.

STEP 4 · CONFIRM WITH CONTEXT

Leg crossing and weight loss that removes the nerve's fat padding are classic causes; no back pain and a negative SLR also argue against the root.

WORKED CASE 3 · HAND NUMBNESS: WRIST OR NECK

A patient wakes at night with numb thumb, index and middle fingers and shakes the hand for relief. Thenar skin feels normal, wrist extension and the brachioradialis reflex are normal, and thumb abduction is weak. C6 root or median nerve?

STEP 1 · LOOK AT THENAR SKIN

The palmar cutaneous branch leaves above the wrist and passes over the ligament, so thenar skin is spared in carpal tunnel syndrome but may be numb in a C6 lesion.

STEP 2 · LOOK AT THE MUSCLES

Weak thumb abduction (abductor pollicis brevis) is median nerve. Wrist extension and the brachioradialis reflex (C6) are normal.

STEP 3 · INTERPRET

The pattern points to the **median nerve at the wrist** (carpal tunnel syndrome), not C6.

STEP 4 · PLAN

Start with a neutral night splint and activity changes; nerve conduction studies help when the diagnosis is uncertain.

TRAPS PEOPLE FALL INTO

- **Assigning the big toe to S1.** The big toe and dorsum of the foot are L5. The little toe and lateral foot are S1.
- **Calling radicular pain radiculopathy.** Radiculopathy needs objective signs: numbness, weakness or a reduced reflex.
- **Counting back or hamstring pain as a positive SLR.** Only familiar leg pain below the knee counts.
- **Reading a positive SLR as proof of herniation.** The SLR is sensitive, not specific. A negative one is the useful result.
- **Expecting a Babinski sign from a lumbar herniation.** Below L1 to L2 the canal holds roots, so the picture is lower motor neuron.
- **Calling bilaterally absent ankle jerks in an 80 year old a root lesion.** They often fade with age or peripheral neuropathy. One sided loss is what points to a root.
- **Missing myelopathy in neck pain.** A brisk reflex, Hoffmann sign or sustained clonus changes the plan to imaging and referral.
- **Assuming compression alone causes pain.** A healthy compressed nerve goes numb or weak. Pain needs inflammation as well.

Chapter 5 self-test · ten items

1. Imaging shows a soft posterolateral disc protrusion between the sixth and seventh cervical vertebrae. Which root is it most likely to irritate?

A. C6
B. T1
C. C7
D. C8

C. C7 Cervical roots exit above the vertebra with the same number, so C7 leaves through the C6 to C7 foramen.

2. Which posture tends to open the lumbar intervertebral foramen?

A. Same side rotation
B. Backward extension
C. Same side bending
D. Forward flexion

D. Forward flexion Flexion separates the pedicles and thins the ligamentum flavum. Extension, same side bending and rotation narrow it.

3. A patient reports numbness over the dorsum of the foot and the big toe. Which dermatome fits best?

A. L5
B. L3
C. L4
D. S1

A. L5 The dorsum of the foot and the big toe belong to L5. L4 runs to the medial malleolus and S1 covers the lateral foot and heel.

4. Why is the patellar reflex described as monosynaptic?

A. Golgi tendon organs synapse on the antagonist
B. Ia afferents synapse directly on alpha motor neurons
C. Gamma motor neurons relay through a single interneuron
D. Dorsal horn interneurons link the two roots

B. Ia afferents synapse directly on alpha motor neurons The spindle's Ia fiber enters through the dorsal root and synapses directly on alpha motor neurons of the same muscle, with no interneuron in the main loop.

5. A 68 year old with neck pain drops objects, has trouble with buttons and an unsteady gait. Flicking the middle fingernail makes the thumb flex. What does this suggest?

A. Cervical myelopathy needing imaging and referral
B. C6 radiculopathy suited to conservative care
C. Carpal tunnel syndrome needing a wrist night splint
D. Normal aging that needs no further workup

A. Cervical myelopathy needing imaging and referral A Hoffmann sign with clumsy hands and gait change points to upper motor neuron involvement, most often cervical spondylotic myelopathy.

6. A patient has deep, dull, aching pain in the buttock and posterior thigh that stops above the knee, with normal strength, sensation and reflexes. What is it most likely?

A. S1 radicular pain
B. L5 radiculopathy
C. Cauda equina syndrome
D. Somatic referred pain

D. Somatic referred pain Deep, vague pain above the knee without neurological deficit fits somatic referred pain from a spinal structure, explained by dorsal horn convergence.

7. A far lateral (extraforaminal) disc herniation at L4 to L5 is most likely to compress which root?

A. The traversing L5 root
B. The traversing S1 root
C. The exiting L4 root and its DRG
D. Several roots of the cauda equina

C. The exiting L4 root and its DRG Outside the canal the herniation meets the root leaving at that level, L4, often at its dorsal root ganglion, which tends to be very painful.

8. Raising a patient's asymptomatic left leg reproduces pain down the right leg. What does this suggest?

A. A normal finding in most healthy adults
B. A specific sign, often of a large herniation
C. Hamstring tightness on the raised left side
D. A sensitive sign that rules out a herniation

B. A specific sign, often of a large herniation This is a positive crossed straight leg raise. It is insensitive but quite specific and suggests a large, often central or axillary herniation.

9. Nerve conduction studies in a patient with a numb C6 distribution show normal sensory nerve action potentials. Why does this fit a root lesion?

A. The lesion is proximal to the DRG cell bodies
B. The DRG sits outside the nervous system
C. Sensory axons regrow within a week of injury
D. Root lesions affect only motor fibers

A. The lesion is proximal to the DRG cell bodies In radiculopathy the dorsal root ganglion and its peripheral axons are intact, so distal sensory potentials stay normal. Plexus and nerve lesions reduce them.

10. A 50 year old with low back pain now has numbness around the anus, new difficulty passing urine and weakness in both legs. What is the right action?

A. Gentle manipulation, then review in one week
B. Same day emergency imaging and surgical review
C. A routine MRI if symptoms last six more weeks
D. Straight leg raise testing at the next visit

B. Same day emergency imaging and surgical review Saddle numbness, new urinary retention and bilateral leg weakness suggest cauda equina syndrome, a surgical emergency where outcome depends on speed.

CHAPTER 6

Pain Neuroscience

Read it in full: **Chapter 6 in the textbook**. See it in motion: **Pain Neuroscience Walkthrough** and **Pain Neuroscience Lab**.

What to know

The IASP defines pain as an unpleasant sensory and emotional experience associated with, or resembling that associated with, actual or potential tissue damage. Pain is an experience in a person, it is both sensory and emotional, and it can warn before harm and persist after healing. **Nociception** is the neural encoding of noxious stimuli. Nociception is input; pain is one possible output. Wounded soldiers who report little pain show nociception without pain; phantom limb pain and the builder whose nail passed between his toes show pain without nociception. Congenital insensitivity to pain (often loss of Nav1.7) shows that pain protects.

Four processes: **transduction** at nociceptor endings (TRPV1 for heat above about 43°C, acid and capsaicin; TRPA1; acid sensing channels; P2X3 for ATP; then Nav1.7, 1.8 and 1.9 fire), **transmission** to the dorsal horn (glutamate, substance P, CGRP), **modulation** at every relay and **perception**, built by the brain with context, memory, attention, emotion and expectation.

Aδ fibers (thin myelin, about 5 to 30 m/s) carry sharp, well localized first pain. **C fibers** (unmyelinated, about 0.5 to 2 m/s) carry dull, burning second pain; many are polymodal and some are silent nociceptors that wake in inflamed tissue. **Aβ fibers** (thick myelin, about 35 to 75 m/s) carry touch and vibration. Lamina I has nociceptive specific neurons; lamina V has wide dynamic range neurons with convergent input from skin, muscle, joints and viscera. Projection axons cross within a segment or two and climb in the spinothalamic tract, so a cord hemisection loses pain and temperature on the opposite side below the lesion. There is no single pain center; a distributed network (the neuromatrix) builds pain.

Mechanisms: **nociceptive** pain comes from actual or threatened damage to non neural tissue and is localized, proportionate and mechanical. **Neuropathic** pain comes from a lesion or disease of the somatosensory system and is burning, shooting or electric in a nerve or root territory. **Nociplastic**

pain comes from altered nociception without clear tissue damage or a nerve lesion and is widespread or disproportionate with fatigue and poor sleep. They often mix in one person.

Allodynia is pain from a stimulus that is not normally painful. **Hyperalgesia** is more pain from a stimulus that is normally painful. Primary hyperalgesia lives in the injured tissue (peripheral); secondary hyperalgesia lives in the uninjured tissue around it, so the change is in the cord. **Peripheral sensitization** comes from the inflammatory soup (bradykinin, PGE2, histamine, serotonin, ATP, H+, NGF, cytokines), which lowers TRPV1 and sodium channel thresholds and recruits silent nociceptors. Nociceptors also release substance P and CGRP into tissue: neurogenic inflammation. NSAIDs block cyclooxygenase and prostaglandins.

Central sensitization is increased responsiveness of central nociceptive neurons to normal or subthreshold input. The NMDA receptor is blocked by magnesium at rest; repeated C fiber input with substance P and CGRP depolarizes the neuron enough to expel it, and calcium entry raises excitability. **Wind-up** is a growing response to repeated identical C fiber stimuli at about one per second or faster; its perceptual twin is temporal summation. Long term potentiation, receptive field expansion, disinhibition (weaker GABA and glycine), glial activation and descending facilitation add to it. Look for a pattern: disproportionate, spreading pain, many sensitivities, poor sleep and fatigue. It does not mean the pain is not real.

Melzack and Wall's **gate control theory** (1965): large Aβ fibers and small Aδ and C fibers both excite transmission (T) cells; large fibers excite inhibitory interneurons in the substantia gelatinosa (lamina II) and close the gate; small fibers inhibit those interneurons and open it; central control from the brain sets the gate too. Large closes, small opens. The wiring was too simple, but the spinal cord is a processor, which explains rubbing, vibration and TENS.

The **descending system**: higher centers project to the **periaqueductal gray** (PAG), which acts through the **rostral ventromedial medulla** (RVM, serotonin, nucleus raphe magnus) and works with the noradrenergic **locus coeruleus** to inhibit or facilitate the dorsal horn. Opioids act presynaptically (closing calcium channels) and postsynaptically (opening potassium channels). The RVM has OFF cells (inhibit) and ON cells (facilitate). Acute danger brings stress induced analgesia; chronic stress, poor sleep and nerve injury can tip it toward facilitation. SNRIs such as duloxetine and tricyclics boost descending serotonin and norepinephrine.

Everyday modulators: **conditioned pain modulation** (pain in one place reduces pain elsewhere; often weaker in chronic pain), **placebo** analgesia (partly blocked by naloxone, so it releases endogenous opioids), **nocebo** hyperalgesia (anxiety releases cholecystokinin, which opposes opioids), attention, mood, sleep (one night of restriction lowers thresholds) and exercise induced hypoalgesia. Manipulation produces short term threshold changes in small studies, but similar effects follow exercise and touch, so they are probably not technique specific.

Chronic pain persists or recurs beyond three months. About one in five US adults has it and about 7 to 8% have high impact chronic pain; low back pain is the leading cause of years lived with disability. Chronic **primary** pain (fibromyalgia, chronic primary low back pain, IBS) is a condition in its own right; chronic **secondary** pain is linked to another disease. Engel's **biopsychosocial model** (1977) says every pain has biological, psychological and social dimensions; it does not say pain is psychological.

Catastrophizing has three parts: rumination, magnification and helplessness, and it is one of the most consistent predictors of poor outcome. The **fear avoidance model**: pain read as threatening leads to catastrophizing, fear, avoidance and hypervigilance, then disuse, low mood and disability, which feed more pain; pain read as manageable leads to graded activity and recovery. Guidelines put nonpharmacological care first (education, exercise, CBT, ACT, mindfulness; also manipulation, massage, acupuncture, yoga and tai chi as options). Opioids are not first line for chronic noncancer pain. Graded activity, graded exposure and pacing put the model into practice. Risk stratification tools match care intensity to psychosocial risk.

Pain neuroscience education aims at reconceptualization: pain as a protective, changeable output, not a measure of damage. Core messages: pain is real and always produced by the brain; hurt does not always mean harm; the system can become oversensitive like a car alarm and can be retrained. Tools: the alarm, the volume knob, the protectometer with DIMs and SIMs, teach back. Avoid nocebo phrases such as degenerating spine, slipped disc, back out of alignment, never bend. In people **without** back pain, disc degeneration is found in about 37% at age 20 and 96% at 80, and bulges in about 30% at 20 and 84% at 80. Education gives small to moderate short term benefit and works best with exercise.

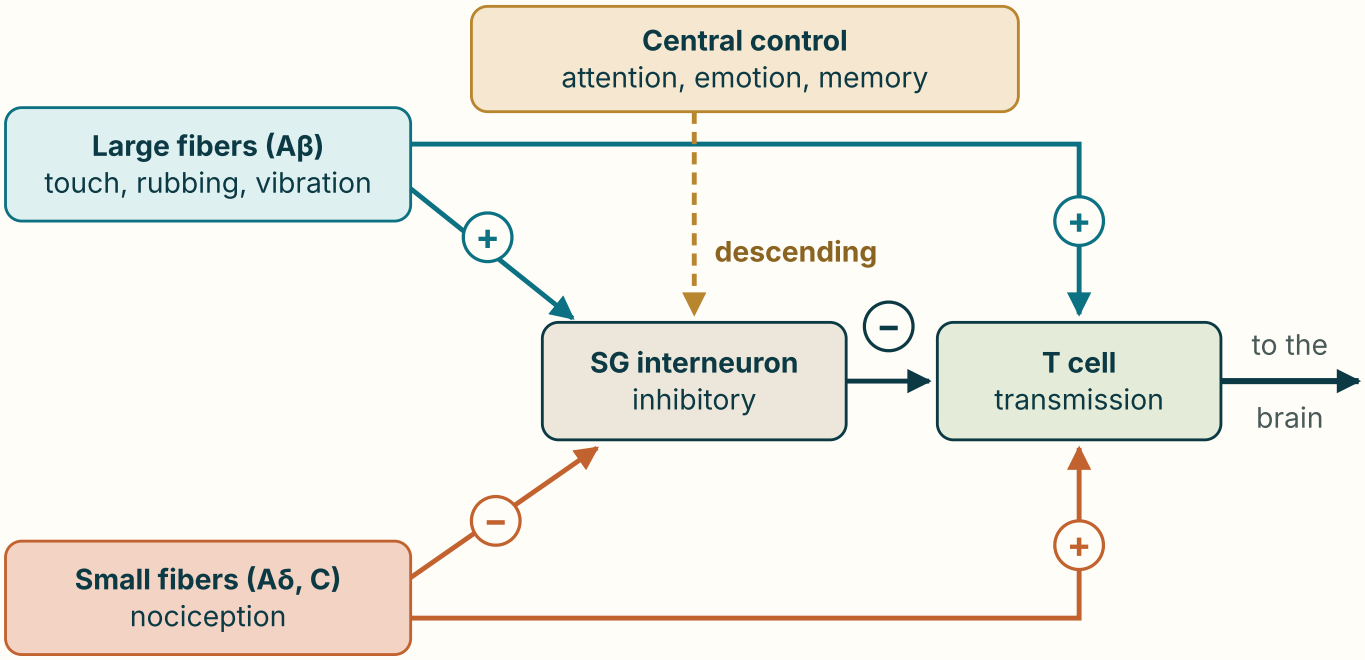

Large fibers close the gate, small fibers open it, and descending control from the brain sets it. Pain depends on the balance of all three inputs, not on the nociceptive signal alone.

Large closes, small opens. Melzack and Wall placed a gate in the dorsal horn: touch fibers excite an inhibitory interneuron that damps the transmission cell, nociceptive fibers inhibit that interneuron, and the brain reaches down to set the gate.

LOCK THESE IN

- Nociception is input; pain is output. Each can occur without the other.
- Aδ: fast, thinly myelinated, first pain. C: slow, unmyelinated, second pain. Aβ: touch.
- Spinothalamic tract crosses within a segment or two: hemisection loses pain and temperature on the opposite side.
- Allodynia: harmless stimulus hurts. Hyperalgesia: painful stimulus hurts more.
- Primary hyperalgesia is peripheral; secondary hyperalgesia is central.
- Gate control: large closes, small opens, brain sets it.
- Descending chain: PAG to RVM (serotonin) plus locus coeruleus (norepinephrine) to the dorsal horn.
- Chronic means more than three months. Catastrophizing: rumination, magnification, helplessness.

Fibers and pain mechanisms

Item	Key facts	Example or note
Aβ fiber	Thick myelin, about 35 to 75 m/s; touch, vibration	Closes the gate; drives allodynia when disinhibited
Aδ fiber	Thin myelin, about 5 to 30 m/s; first pain, cold	Laminae I and V
C fiber	Unmyelinated, about 0.5 to 2 m/s; second pain, warmth, itch	Laminae I and II (substantia gelatinosa)
Nociceptive pain	Damage to non neural tissue; localized, proportionate	Ankle sprain, facet strain
Neuropathic pain	Lesion or disease of the somatosensory system	Radiculopathy, postherpetic neuralgia
Nociplastic pain	Altered nociception without clear damage or lesion	Fibromyalgia, some chronic low back pain
Peripheral sensitization	Inflammatory mediators at nociceptor terminals	Primary hyperalgesia
Central sensitization	NMDA, wind-up, disinhibition, glia, facilitation	Allodynia, secondary hyperalgesia

Modulators and the words we use

Item	What it does	Clinical link
Endogenous opioids	Inhibit at PAG, RVM, dorsal horn, terminals	Opioid drugs; part of placebo
Serotonin and norepinephrine	Descending inhibition (norepinephrine via α2)	SNRIs, tricyclics
Cholecystokinin	Facilitates pain, opposes opioids	Nocebo
Conditioned pain modulation	Pain elsewhere reduces pain here	Often weaker in chronic pain
"Your spine is degenerating"	Implies inevitable decline	"Normal age changes, like wrinkles on the inside"
"You have a slipped disc"	Suggests something out of place	"A disc is irritating a nerve; most settle well"
"Avoid bending and lifting"	Teaches fear of movement	"Your back is strong; build up step by step"
"It is all in your head"	Dismisses the pain	"Your pain is real; your nervous system is extra protective"

Worked cases

WORKED CASE 1 · NAMING THE PAIN MECHANISM

Three patients: (1) an acute ankle sprain that hurts with weight bearing and eases with rest; (2) burning, electric pain in the S1 distribution with a reduced Achilles reflex; (3) widespread pain, poor sleep, fatigue and sensitivity to light and sound with no clear lesion. Classify each.

STEP 1 · PATIENT 1

Damage to non neural tissue, localized and mechanical: **nociceptive**.

STEP 2 · PATIENT 2

A lesion of the somatosensory system (the S1 root) with burning, shooting pain in its territory: **neuropathic**.

STEP 3 · PATIENT 3

Altered nociception without clear damage or a nerve lesion, with widespread hypersensitivity: **nociplastic**.

REMEMBER THE OVERLAP

One person with chronic low back pain may have all three contributions, in proportions that change over time.

WORKED CASE 2 · READING IMAGING IN A PERSON WITH NO PAIN

Using the pooled estimates for people without back pain, how many of 100 pain free 50 year olds would show disc degeneration, and how many disc bulges? What does that mean for a 50 year old patient whose report shows both?

STEP 1 · FIND THE RATES

At age 50 the estimates are about 80% for disc degeneration and about 60% for disc bulge.

STEP 2 · APPLY THEM

Of 100 pain free 50 year olds, about **80** would show degeneration and about **60** a bulge.

STEP 3 · INTERPRET

These findings are the norm at that age, so they cannot by themselves explain one person's pain.

STEP 4 · CHOOSE WORDS

Explain them as normal age changes, like wrinkles on the inside, and match any finding to the clinical picture. Guidelines advise against routine imaging without red flags.

WORKED CASE 3 · BREAKING THE FEAR AVOIDANCE CYCLE

A warehouse worker hurt his back lifting six weeks ago. He believes his disc slipped, has stopped bending, checks his back all day and has given up coaching his son's team. Map him onto the model and plan a response.

STEP 1 · FIND THE APPRAISAL

He reads the pain as damage ("my disc slipped"): a threatening appraisal that feeds catastrophizing.

STEP 2 · TRACE THE CYCLE

Fear leads to avoidance (no bending) and hypervigilance (checking all day), then disuse and loss of a valued role, which feed more pain.

STEP 3 · REFRAME

Use pain neuroscience education: pain is real, hurt does not always mean harm, and his back is strong. Replace "slipped disc" with accurate, low threat language.

STEP 4 · ACT

Build graded exposure to bending, starting low on his fear hierarchy, plus graded activity toward coaching again. Education works best when paired with movement.

TRAPS PEOPLE FALL INTO

- **Equating nociception with pain.** Nociception is input; pain is a constructed output that can occur without it.
- **Mixing up the two hyperalgesias.** Primary lives in the injured tissue; secondary lives around it and reflects cord changes.
- **Reversing the gate.** Large fibers close the gate. Small fibers open it.
- **Putting the lesion on the wrong side.** Spinothalamic fibers cross early, so a right hemisection loses pain and temperature on the left.
- **Reading biopsychosocial as all in the head.** The model keeps biology and adds psychological and social factors.
- **Calling central sensitization proven in one patient.** No single test proves it. Look for a consistent pattern.
- **Using frightening anatomy words.** Degenerating, slipped and out of alignment act as nocebos.
- **Thinking education alone is enough.** Effects are larger when education is paired with exercise or graded activity.

Chapter 6 self-test · ten items

1. A soldier with a serious leg wound reports little pain until he reaches the field hospital. What does this best illustrate?

A. Nociceptors switch off during stress
B. Nociception can occur without much pain
C. C fibers cannot fire in severe injury
D. Pain always matches the tissue damage

B. Nociception can occur without much pain Nociceptors were firing, but the brain weighed context and meaning and produced little pain until the threat passed.

2. After stubbing a toe, a person feels a sharp prick, then a slow, burning ache. Which fibers carry the second sensation?

A. Myelinated Aβ fibers
B. Myelinated Aδ fibers
C. Unmyelinated C fibers
D. Ia spindle afferents

C. Unmyelinated C fibers C fibers conduct slowly (about 0.5 to 2 m/s) and carry dull, burning second pain. Aδ fibers carry the first sharp prick.

3. A patient has a right sided cord hemisection at T10. Where is pain and temperature sensation lost?

A. On the right, below the lesion
B. On both sides, at T10 only
C. On the right, above the lesion
D. On the left, below the lesion

D. On the left, below the lesion Spinothalamic fibers cross within a segment or two of entry, so the right tract carries the left side of the body.

4. Light touch from a shirt hurts on sunburned skin. What is this called?

A. Allodynia
B. Paresthesia
C. Hyperalgesia
D. Hypoesthesia

A. Allodynia Allodynia is pain from a stimulus that does not normally provoke pain. Hyperalgesia is increased pain from a stimulus that is normally painful.

5. Repeated identical C fiber stimuli at about one per second produce a growing dorsal horn response. Which receptor change is central to this?

A. Mu opioid receptors are activated by CCK
B. Magnesium is expelled from the NMDA receptor
C. TRPV1 is closed by prostaglandin E2
D. AMPA receptors are blocked by spinal glycine

B. Magnesium is expelled from the NMDA receptor Repeated input depolarizes the neuron enough to remove magnesium from the NMDA channel. Calcium entry then raises excitability: wind-up.

6. Using gate control theory, why does rubbing a bumped elbow help?

A. Aβ input excites inhibitory interneurons
B. C fiber input closes the gate on T cells
C. Rubbing blocks the spinothalamic tract
D. Rubbing releases prostaglandins locally

A. Aβ input excites inhibitory interneurons Large fiber input excites inhibitory interneurons in the substantia gelatinosa, which reduce transmission cell output.

7. A patient with chronic pain starts duloxetine. Through which system is it thought to help?

A. Activation of dorsal horn NMDA receptors
B. Peripheral blockade of cyclooxygenase
C. Descending serotonin and norepinephrine
D. Stronger ascending spinothalamic signals

C. Descending serotonin and norepinephrine SNRIs block reuptake of serotonin and norepinephrine, boosting pathways from the RVM and locus coeruleus that inhibit the dorsal horn.

8. Part of placebo analgesia is blocked by naloxone. What does this show?

A. Placebo relief is imagined, not real relief
B. Placebo works only through serotonin
C. Naloxone directly increases pain on its own
D. Expectation can release endogenous opioids

D. Expectation can release endogenous opioids If an opioid antagonist reduces the effect, opioid pathways must be part of the mechanism. Other parts involve endocannabinoids and dopamine.

9. A patient keeps thinking about her pain, worries it means something serious and feels nothing can help. What is this pattern?

A. Pain catastrophizing
B. Central sensitization
C. Kinesiophobia
D. Conditioned pain modulation

A. Pain catastrophizing Catastrophizing has three parts: rumination, magnification and helplessness. It is one of the strongest predictors of poor recovery and can be changed.

10. A 45 year old with three weeks of back pain and no red flags asks for an MRI. What is the best explanation?

A. MRI reliably shows which tissue produces pain
B. Such findings are common and rarely change care
C. MRI is needed first to rule out a slipped disc
D. MRI should be done before any exercise starts

B. Such findings are common and rarely change care Disc degeneration and bulges are common in people without pain. Routine imaging without red flags rarely changes care and its labels can increase fear.

Cram sheet

Everything from chapters 5 and 6 in one place. Cover the right column and see if you can rebuild each row.

Levels and numbers to know

Item	Value	Note
Spinal nerves	31 pairs: 8 C, 12 T, 5 L, 5 S, 1 Co	C8 exits between C7 and T1
Plexuses	Cervical C1 to C4; brachial C5 to T1; lumbar L1 to L4; sacral L4 to S4	Formed by ventral rami
White rami	T1 to L2 only	Gray rami reach every spinal nerve
Trunk anchors	Nipple T4; xiphoid T6; umbilicus T10; inguinal ligament T12 to L1	C4 sits next to T2
Hand anchors	C6 thumb; C7 middle finger; C8 little finger	T1 medial antecubital fossa
Leg anchors	L3 medial knee; L4 medial malleolus; L5 dorsum and big toe; S1 lateral heel	S3 to S5 saddle
Reflexes	Biceps C5; brachioradialis C6; triceps C7; patellar L4; Achilles S1	Medial hamstring L5, unreliable
Reflex grades	0, 1+, 2+ normal, 3+, 4+ with clonus	Asymmetry matters most
MRC strength	0 none to 5 normal; 3 = against gravity	Most root weakness is grade 4
Lumbar herniation levels	90 to 95% at L4 to L5 or L5 to S1	C7, then C6, in the neck
SLR	Positive at about 30 to 70 degrees; sensitivity about 0.9	Crossed SLR specific
Natural history	Most improve in 6 to 12 weeks	Extruded fragments most likely to regress
EMG timing	Denervation after about 2 to 3 weeks	SNAPs normal in radiculopathy
Entrapment pressure	About 20 to 30 mmHg slows venous outflow	Axon regrowth about 1 mm a day
Fiber speeds	Aβ 35 to 75; Aδ 5 to 30; C 0.5 to 2 m/s	TRPV1 heat above about 43°C

Item	Value	Note
Chronic pain	Over 3 months; about 1 in 5 US adults	High impact about 7 to 8%
Imaging without pain	Degeneration 37% at 20 to 96% at 80; bulge 30% to 84%	Normal age changes

Rules that are not equations

Topic	The rule
Exit rule	C1 to C7 exit above their vertebra; C8 at C7 to T1; T1 down exit below.
Herniation	Paracentral hits the traversing root; far lateral hits the exiting root; central can hit several.
Radiculopathy	Defined by objective signs (numbness, weakness, reflex loss), not by pain.
Referred pain	Somatic: deep, vague, above the knee, no deficit. Visceral: follows the organ's segment.
UMN versus LMN	UMN: spasticity, hyperreflexia, Babinski, Hoffmann, clonus. LMN: flaccid, hyporeflexia, atrophy.
Test logic	SnNout: negative SLR rules out. SpPin: positive crossed SLR or Spurling rules in.
Red flags	Saddle numbness, new bladder or bowel change, progressive weakness, myelopathy, fever or cancer history.
Gate control	Large fibers close the gate, small fibers open it, the brain sets it.
Descending system	PAG to RVM (serotonin) plus locus coeruleus (norepinephrine); can inhibit or facilitate.
Hyperalgesia	Primary in injured tissue (peripheral); secondary around it (central).
Fear avoidance	Catastrophizing, fear, avoidance, disability; graded exposure breaks the loop.
Explaining pain	True and enabling; avoid nocebo words; pair education with movement.

Dr. Garg Learning · CC BY-SA 4.0