Study Guide 1

This guide covers the first two chapters. First you build the spine in three dimensions: regions and curves, the motion segment, the disc, the ligaments, the muscles and the roots. Then you put it in motion: planes and coupling, loads on the disc and facets, stability and the lever math of lifting. Work one chapter at a time. Read the "what to know" paragraphs, study the diagram, copy the tables out by hand, then try each worked case with the steps covered. Finish each chapter with its ten board style self-test items. The cram sheet at the end puts every number in one place.

WHAT THIS GUIDE COVERS

- Chapter 1 · regions and counts, primary and secondary curves, the motion segment and three joint complex, vertebrae by region, the disc and its nutrition, facets, ligaments, back muscle layers, the cord, nerve numbering and exiting versus traversing roots.
- Chapter 2 · planes and axes, six degrees of freedom, coupled motion and Fryette, regional range, lumbopelvic rhythm, viscoelasticity, disc and facet loading, intradiscal pressure, Panjabi and the neutral zone, instability, posture and moment arms.

CHAPTER 1

The Spine in Three Dimensions

Read it in full: **Chapter 1 in the textbook**. See it in motion: **Spine in Three Dimensions** and **Spine Lab**.

What to know

The adult column has five regions. Learn the counts exactly: 7 cervical, 12 thoracic, 5 lumbar, 5 sacral segments fused into one sacrum, and usually 4 coccygeal segments (the range is 3 to 5). That is 33 vertebrae at birth and about 24 separate movable vertebrae above the sacrum in the adult. In a typical adult the column is about 70 cm long in men and 60 cm in women, and roughly a quarter of that length is disc.

Variation is common. A lowest lumbar vertebra partly fused to the sacrum is **sacralization**. A first sacral segment that behaves like a lumbar vertebra is **lumbarization**. Both are **transitional segments**, and both matter because they can make a practitioner miscount levels on an image.

Seen from the side, the healthy spine has four curves. The thoracic and sacral curves are **kyphoses** (concave forward) and are **primary**: the fetus is one long C. The cervical and lumbar curves are **lordoses** (concave backward) and are **secondary**: the neck curve forms as the infant lifts the head, and the lumbar curve forms as the child crawls, stands and walks, near age one. Secondary curves come mostly from wedging of the discs. The thoracic kyphosis is more built into the bone, which is one reason it changes less with posture. Commonly cited values are about 20 to 45 degrees of thoracic kyphosis and 40 to 60 degrees of lumbar lordosis, but a curve outside a range is a finding to interpret, not a diagnosis.

The **motion segment** (functional spinal unit) is two vertebrae plus the disc, two facet joints and the ligaments between them. Its three joints, one cartilaginous interbody joint (a symphysis) in front and two synovial facet joints behind, form the **three joint complex**. They share load and motion, so when a disc loses height the facets carry more load. That is the logic of the degenerative cascade. The anterior column (bodies and discs) handles compression; the posterior column (arches, facets and their ligaments) guides motion and resists shear, rotation and flexion. In the fracture model with three columns, damage to two or more columns suggests instability.

A typical vertebra has a body for weight bearing and an arch made of two **pedicles** and two **laminae** around the vertebral foramen. Seven processes hang off the arch: one spinous, two transverse and four articular. The **pars interarticularis** is the narrow bone between the superior and inferior articular processes; a stress fracture there is spondylolysis, most common at L5.

Identify a vertebra in three questions. A transverse foramen means cervical. Rib facets on the body mean thoracic. A large kidney shaped body with neither means lumbar. The special cases are the **atlas** (C1, no body and no spinous process; the yes joint above it), the **axis** (C2, with the dens, which is the body of C1 fused to C2; about half of cervical rotation happens at C1 to C2) and C7, the vertebra prominens. The vertebral artery usually enters the transverse foramen at C6 and climbs through C1. Typical cervical vertebrae have uncinate processes forming the uncovertebral joints, and spurs from these can narrow the foramen.

The disc has three parts. The **nucleus pulposus** is 70 to 90% water in a young adult, held by proteoglycans such as aggrecan. The **annulus fibrosus** has 15 to 25 lamellae with fibers about 60 to 65 degrees from vertical, alternating direction like the plies of a tire. The **endplates** are about 1 mm of hyaline cartilage and are the weakest part under pure compression; nucleus pushed through an endplate is a **Schmorl's node**. There are 23 discs; the first is C2 to C3. The disc is the largest structure in the body without its own blood supply, so the inner disc is fed by diffusion through the endplates. Only the outer third of the annulus is innervated, by the sinuvertebral nerve and gray rami branches.

Facet orientation is the biggest reason each region moves differently: about 45 degrees in the neck (motion in all directions), near the frontal plane in the thorax (rotation and side bending, held back by the ribs) and near the sagittal plane in the low back (flexion and extension, little rotation). Each facet joint gets medial branches from the dorsal rami at its level and the level above, so L4 to L5 is supplied by L3 and L4.

Ligaments limit the motion that pulls their ends apart. The **ALL** is in front and limits extension. Everything behind the bodies limits flexion: the PLL, ligamentum flavum (high in elastin, can thicken in stenosis), interspinous and supraspinous ligaments and the facet capsules. The lumbar PLL is narrow, which with the thin posterior annulus explains why herniations go **posterolateral**. In the upper neck, the transverse ligament holds the dens and the alar ligaments limit head rotation. Rheumatoid arthritis and Down syndrome can weaken the transverse ligament, making atlantoaxial instability a contraindication to forceful upper neck manipulation.

Back muscles come in layers. Superficial and intermediate muscles move the limbs and ribs and are supplied by **ventral rami**. The intrinsic muscles (splenius, erector spinae as iliocostalis, longissimus and spinalis from lateral to medial, transversospinalis, the small segmental muscles and the suboccipitals) move the spine and are supplied by **dorsal rami**. Transversospinalis fibers run up and medial, so the right side rotates the trunk to the left. The thoracolumbar fascia has three layers that meet at the lateral raphe, where the transversus abdominis and internal oblique pull on it.

The cord ends at the **conus medullaris** near L1 to L2 in adults (about L3 at birth); the dural sac ends near S2, and the **cauda equina** fills the canal between. Compression of the cauda equina

causes saddle numbness, new bladder or bowel dysfunction and leg weakness: a surgical emergency. There are 31 pairs of spinal nerves. Cervical nerves exit above the vertebra of the same number, C8 exits between C7 and T1, and from T1 down each nerve exits below its vertebra.

At the L4 to L5 disc, the L4 root has already left high in its foramen while the L5 root is still traversing the lateral recess. So a posterolateral L4 to L5 herniation usually compresses L5 (the traversing root) and a far lateral one compresses L4 (the exiting root). In the neck, a C5 to C6 herniation usually affects C6. The cord gets one anterior spinal artery (front two thirds) and two posterior spinal arteries; the artery of Adamkiewicz usually enters on the left between T9 and T12.

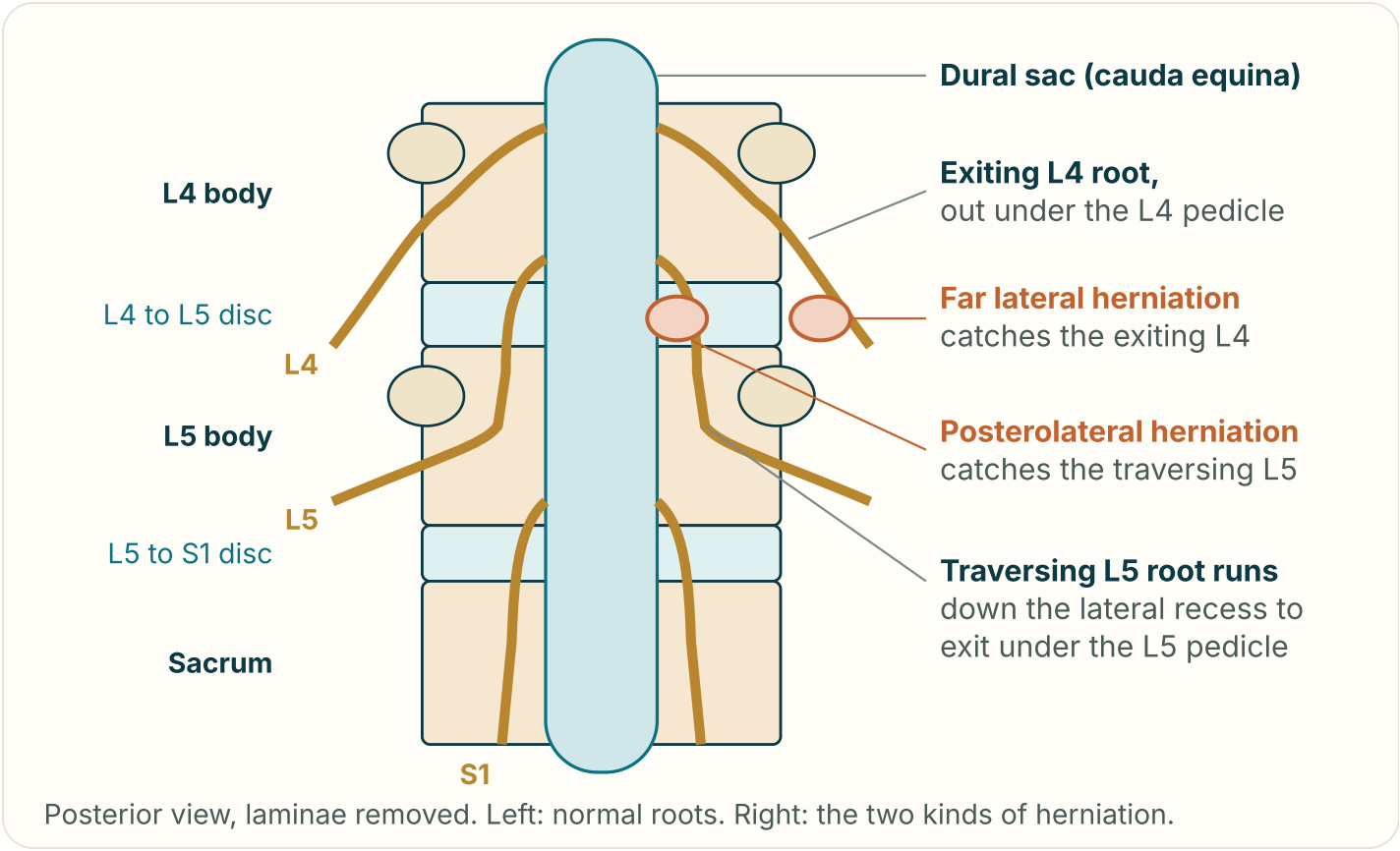

Which root a herniation catches. At the L4 to L5 disc the L4 root has already left under its pedicle, so a posterolateral herniation hits the traversing L5 root and only a far lateral herniation hits the exiting L4 root.

LOCK THESE IN

- Counts: 7 cervical, 12 thoracic, 5 lumbar, 5 fused sacral, usually 4 coccygeal; 33 at birth, about 24 movable above the sacrum.
- Primary curves (present before birth) are the kyphoses: thoracic and sacral. Secondary curves are the lordoses: cervical (head control) and lumbar (standing).
- Motion segment = two vertebrae + disc + two facets + ligaments; three joint complex = one symphysis in front, two synovial facets behind.
- Transverse foramen = cervical; costal facets = thoracic; large kidney shaped body = lumbar. Atlas has no body; the dens belongs to C2.
- 23 discs, the first at C2 to C3. Endplate fails first under pure compression. Inner disc is fed by diffusion; only the outer third of the annulus has nerves.
- ALL limits extension; PLL, flavum, interspinous, supraspinous and capsules limit flexion.
- Intrinsic back muscles: dorsal rami. Superficial and intermediate: ventral rami (trapezius: spinal accessory nerve).
- Conus near L1 to L2, dural sac to S2. Posterolateral L4 to L5 herniation hits L5; far lateral hits L4.

Regions at a glance

Region	Count	Adult curve	Signature features	Facet plane and favored motion
Cervical	7	Lordosis (secondary)	Transverse foramina; bifid spinous C2 to C6; uncinate processes	About 45 degrees; all directions, rotation at C1 to C2
Thoracic	12	Kyphosis (primary)	Costal facets; long downward spinous processes; small round canal	Near frontal; rotation and side bending, limited by ribs
Lumbar	5	Lordosis (secondary)	Large kidney shaped bodies; mammillary and accessory processes	Near sagittal, curved; flexion and extension
Sacral	5 fused	Kyphosis (primary)	Four pairs of foramina; auricular surfaces; hiatus at S5	Load transfer to the pelvis
Coccygeal	3 to 5 (usually 4)	Continues sacral curve	Rudimentary segments	Pelvic floor attachment

Ligaments and nerve roots

Structure	Key fact	Clinical note
ALL	Front of bodies and discs; limits extension	Torn in hyperextension injury
PLL	Inside the canal, C2 to sacrum; limits flexion	Narrow in the lumbar spine, so herniations go posterolateral
Ligamentum flavum	Lamina to lamina; elastic; limits flexion	Thickening adds to stenosis
Transverse ligament	Holds the dens against the atlas	Weakened in rheumatoid arthritis and Down syndrome
Alar ligaments	Dens to occipital condyles; limit head rotation	Tested in upper cervical stability screening
C5 to C6 disc	Usually affects C6	Cervical roots exit above their vertebra
C6 to C7 disc	Usually affects C7	Most common cervical root level
L4 to L5 disc	Posterolateral: L5. Far lateral: L4	Traversing versus exiting root
L5 to S1 disc	Posterolateral: S1. Far lateral: L5	Same rule one level lower

Worked cases

WORKED CASE 1 · NAMING THE ROOT FROM THE DISC LEVEL

An MRI shows a posterolateral disc herniation at L5 to S1 on the right. Which root is most likely compressed? What if the same disc herniated far laterally?

STEP 1 · FIND THE ROOTS AT THAT LEVEL

At the L5 to S1 disc, the L5 root has already turned out under the L5 pedicle into its foramen. The S1 root is still running down the lateral recess.

STEP 2 · PLACE THE HERNIATION

A posterolateral herniation pushes into the lateral recess, just beside the PLL, where the traversing root runs.

STEP 3 · NAME THE ROOT

So the right **S1** root is the likely one. The quick rule: one number lower than the upper vertebra.

STEP 4 · APPLY THE EXCEPTION

A far lateral (foraminal) herniation meets the root that is exiting at that level, so it would compress the right **L5** root.

CHECK IT

The book gives the same pattern one level up: posterolateral L4 to L5 hits L5, far lateral L4 to L5 hits L4.

WORKED CASE 2 · IDENTIFYING A VERTEBRA IN HAND

A student is handed an isolated bone. It has no transverse foramen. There are small half facets on the sides of the body, and the spinous process slopes steeply downward. Which region is it from, and what motion does that region favor?

STEP 1 · ASK THE FIRST QUESTION

Is there a transverse foramen? No, so it is not cervical.

STEP 2 · ASK THE SECOND QUESTION

Are there facets on the body for ribs? Yes, costal demifacets, so it is **thoracic**.

STEP 3 · CONFIRM WITH OTHER FEATURES

A long, steeply sloping spinous process fits the middle thoracic region, about T5 to T8.

STEP 4 · LINK TO MOTION

Thoracic facets lie near the frontal plane, which favors rotation and lateral flexion, but the rib cage stiffens the region overall.

WORKED CASE 3 · COUNTING NERVES AGAINST VERTEBRAE

Through which foramen does each of these nerves exit: C6, C8, T1 and L4?

STEP 1 · APPLY THE CERVICAL RULE

Cervical nerves exit above the vertebra of the same number. C6 exits between C5 and C6.

STEP 2 · HANDLE THE EXTRA NERVE

There are 8 cervical nerves but 7 cervical vertebrae. C8 has no vertebra of its own and exits between **C7 and T1**.

STEP 3 · SWITCH RULES AT T1

From T1 down, each nerve exits below its vertebra. T1 exits between T1 and T2.

STEP 4 · FINISH IN THE LOW BACK

L4 exits through the **L4 to L5** foramen, beneath the L4 pedicle.

TRAPS PEOPLE FALL INTO

- **Calling the lordoses primary.** The primary curves are the kyphoses, present before birth. The lordoses are secondary.
- **Putting the dens on the atlas.** The dens rises from C2. Developmentally it is the body of C1, which is why the atlas has no body.
- **Counting a disc between C1 and C2.** There is no disc between the occiput and atlas or between atlas and axis. The first disc is C2 to C3, for 23 in all.
- **Saying the PLL limits extension.** Only the ALL lies in front of the bodies. Everything behind the bodies, including the PLL, limits flexion.
- **Assuming every herniation hits the exiting root.** A posterolateral lumbar herniation hits the traversing root. Only a far lateral one hits the exiting root.
- **Mixing up the rami.** Intrinsic back muscles and facets get dorsal rami. The limbs and the front of the trunk get ventral rami.
- **Reading a curve outside a range as a diagnosis.** The book says many people with large or small curves have no pain. It is a finding to interpret.
- **Assuming five lumbar vertebrae.** Transitional segments are common and can make you mislabel a level on an image.

Chapter 1 self-test · ten items

1. An infant has just begun to hold the head up against gravity. Which curve is forming?

A. The sacral kyphosis, a secondary curve
B. The cervical lordosis, a secondary curve
C. The lumbar lordosis, a secondary curve
D. The thoracic kyphosis, a primary curve

B. The cervical lordosis, a secondary curve Head control shapes the cervical lordosis. The lumbar lordosis comes later with crawling, standing and walking, and the kyphoses are primary.

2. A bone has a transverse foramen, a bifid spinous process and small uncinate lips on its body. Where does it come from?

A. A typical cervical vertebra, C3 to C6
B. The vertebra prominens with a long spine
C. An upper thoracic vertebra near T2
D. The atlas, C1, with its lateral masses

A. A typical cervical vertebra, C3 to C6 A transverse foramen means cervical. Bifid spinous processes and uncinate processes mark the typical cervical vertebrae; C1 has no spinous process and C7 has a long non bifid one.

3. Why do most lumbar disc herniations go posterolaterally rather than straight back?

A. The nucleus sits in the front half of the disc
B. The ligamentum flavum blocks the midline route
C. Thin posterior annulus and a narrow lumbar PLL
D. The ALL is weakest along its posterior border

C. Thin posterior annulus and a narrow lumbar PLL The posterior annulus is thinner than the anterior, and the lumbar PLL narrows and covers mainly the midline, leaving the posterolateral corners least protected. The nucleus sits slightly behind center.

4. Which structure usually fails first when a healthy lumbar segment is loaded in pure compression?

A. The outer annulus
B. The facet capsule
C. The pars interarticularis
D. The vertebral endplate

D. The vertebral endplate The endplate is the weakest part under pure compression, so it cracks before a healthy annulus ruptures. Disc material pushed through it forms a Schmorl's node.

5. A patient has a far lateral disc herniation at L4 to L5. Which root is most likely compressed?

A. The traversing S1 root
B. The traversing L5 root
C. The exiting L3 root
D. The exiting L4 root

D. The exiting L4 root In the foramen the herniation meets the root leaving at that level, L4. A typical posterolateral herniation at the same disc would hit the traversing L5 root.

6. How is the inner disc mainly nourished in an adult?

A. By branches of the sinuvertebral artery
B. By diffusion through the vertebral endplates
C. By cerebrospinal fluid in the dural sac
D. By radicular arteries entering the nucleus

B. By diffusion through the vertebral endplates The adult disc has blood vessels only in the outer annulus. Glucose and oxygen diffuse from vertebral body capillaries through the endplates, helped by the pumping effect of changing loads.

7. Which nerves supply the L4 to L5 facet joint?

A. Gray rami communicantes from L4 and L5
B. Medial branches of the L4 and L5 dorsal rami
C. Medial branches of the L3 and L4 dorsal rami
D. The L4 sinuvertebral nerve alone

C. Medial branches of the L3 and L4 dorsal rami Each facet joint gets medial branches from the level at and the level above the joint. That dual supply is why medial branch blocks target two nerves for one joint.

8. A right sided muscle runs upward and medially from transverse processes to spinous processes. Which way does it turn the trunk?

A. Toward the left, the opposite side
B. It only side bends without rotation
C. It only extends and does not rotate
D. Toward the right, the same side

A. Toward the left, the opposite side This is the transversospinalis pattern (semispinalis, multifidus, rotatores). Fibers that run up and toward the midline turn the trunk to the opposite side.

9. A lumbar puncture is done at L3 to L4 or L4 to L5 rather than at T12 to L1. What is the reason?

A. CSF pressure is lowest at the thoracolumbar junction
B. The cord ends near L1 to L2, leaving only roots below
C. The dural sac ends at L2, leaving the canal empty below
D. The epidural space is widest above the L1 level

B. The cord ends near L1 to L2, leaving only roots below The conus medullaris sits near L1 to L2 in adults. Below that the needle meets freely floating roots, and the dural sac continues to about S2.

10. A patient with rheumatoid arthritis is being considered for manipulation. Which ligament concern makes forceful upper neck manipulation contraindicated?

A. Thickening of the ligamentum flavum at C5
B. Ossification of the posterior longitudinal ligament
C. Laxity of the supraspinous ligament at C7
D. Weakness of the transverse ligament of the atlas

D. Weakness of the transverse ligament of the atlas Rheumatoid arthritis and Down syndrome can weaken the transverse ligament, allowing atlantoaxial instability. The book names this as a contraindication to forceful upper neck manipulation.

CHAPTER 2

Spinal Biomechanics

Read it in full: **Chapter 2 in the textbook**. See it in motion: **Spinal Biomechanics Walkthrough** and **Spinal Biomechanics Lab**.

What to know

Motion is described with three planes, each with an axis perpendicular to it. Flexion and extension happen in the **sagittal plane** around a frontal (side to side) axis. Lateral flexion happens in the **frontal plane** around an anteroposterior axis. Axial rotation happens in the **transverse plane** around a vertical axis. The trick: picture a skewer through the moving joint. For nodding, it runs ear to ear.

A motion segment has **six degrees of freedom**: three rotations and three translations (forward and back glide, side glide, and compression or distraction). Translations are usually a few millimeters at most and matter when they are excessive, as in spondylolisthesis. **Osteokinematics** is the motion of whole bones; **arthrokinematics** is what the joint surfaces do. In lumbar flexion the inferior facets glide up and forward and the surfaces partly separate; in extension they glide down and back and press together. The point that is momentarily still, the **instantaneous axis of rotation**, migrates during motion and becomes erratic in degenerated segments.

Coupled motion is a consistent secondary motion that goes with a primary one. In the lower cervical spine (C2 to C7) it is reliable: lateral flexion couples with rotation to the **same side**, so the bodies turn toward the bend and the spinous processes swing toward the convexity. At C1 to C2, rotation couples with a small vertical translation. In the lumbar spine coupling is small and inconsistent. Fryette's Law III (motion in one plane reduces motion in the others) fits the evidence. Laws I and II have not held up as universal rules, so treatment that depends on a fixed lumbar coupling pattern rests on an uncertain base.

Three things set how much a region moves: facet orientation, the disc to body height ratio (about 2:5 cervical, 1:5 thoracic, 1:3 lumbar) and attached structures, above all the rib cage. The neck is the most mobile region; about half of all cervical rotation, roughly 40 degrees each way, happens at C1 to C2, limited mainly by the alar ligaments. Lower cervical flexion and extension peak at C4

to C5 and C5 to C6, where degeneration is also most common. Normal active neck range in young adults is roughly 45 to 60 degrees of flexion, 60 to 75 of extension, about 45 of lateral flexion and 70 to 80 of rotation each way.

The thoracic spine rotates moderately but is stiffened by the ribs. The thoracolumbar junction (T11 to L1) is a transition from thoracic to lumbar facets, and that stiff to mobile change makes it the most common site of traumatic spinal fractures. Lumbar segments favor flexion and extension, which rises from L1 to L2 down to L5 to S1. Lumbar rotation is only about 1 to 2 degrees per segment, about 10 degrees each way for the whole region, because the curved sagittal facets jam. Most of what people call twisting the low back happens at the hips and thoracic spine.

Lumbopelvic rhythm shares forward bending between lumbar flexion and hip flexion. Tight hamstrings limit pelvic rotation, so the lumbar spine has to flex more. Fingertip to floor distance therefore measures hips and spine together, which is why clinicians use the modified Schober test or inclinometers for lumbar flexion.

Five load types act on the spine: compression, tension, shear, bending and torsion. A 1 kg mass weighs about 10 N. A moment is force times its perpendicular distance from the axis (the moment arm), in N·m. Spinal tissues are **viscoelastic**. **Creep** is continued deformation under a constant load. **Stress relaxation** is falling stress when a tissue is held at a fixed length. **Hysteresis** is energy lost as heat in a load and unload cycle. Viscoelastic tissue is stiffer when loaded fast.

Under compression a healthy nucleus pressurizes and pulls the annulus into **hoop tension** while the endplates bow; the endplate fails first, with young adult failure loads often about 5 to 10 kN. Flexion stretches the posterior annulus and posterior ligaments and unloads the facets; repeated loaded flexion in the lab produced posterior annular tears and herniation. Extension loads the facets and narrows the foramina and canal, which is why stenosis feels worse standing and better sitting. In right rotation of a lumbar segment the **left** facet is compressed. Shear at the low lumbar levels leans on the pars; a pars fracture can allow isthmic spondylolisthesis, most often L5 on S1. In standing the facets carry about 10 to 20% of compression, more in extension, with creep and with disc degeneration.

Nachemson's 1960s needle data put pressure (as a share of standing) at about 25% supine, 75% side lying, 140% sitting unsupported, 185% sitting bent forward and over 200% lifting with a flexed spine. Wilke's late 1990s in vivo sensor at L4 to L5 agreed on lying (about 0.1 MPa), standing (0.5) and lifting, with a rounded back lift of 20 kg at about 2.3 MPa versus about 1.7 MPa close with bent knees. The difference was sitting: relaxed sitting was similar to or lower than standing. Both data sets come from very few subjects.

An isolated cadaver lumbar spine buckles at about 90 N and a thoracolumbar spine at about 20 N, so stability in life depends on muscles and the nervous system. **Panjabi's model** (1992) has three subsystems: **passive** (bones, discs, facets, capsules, ligaments, stiff near end range), **active** (muscles and tendons, stiffness through the range) and **neural control** (sets activation in anticipation of and in response to load). They can compensate for each other. The **neutral zone** is the lax part of the range near neutral; the elastic zone runs from there to end range. The neutral zone widens with injury and degeneration and narrows with muscle activity.

Delayed transversus abdominis activity in back pain inspired motor control exercise, but later work showed that altered control is variable and that motor control exercise helps chronic low back pain about as much as other exercise, not clearly more. **Clinical instability** (White and Panjabi) is loss of the ability under physiologic loads to protect the cord and roots and prevent deformity or incapacitating pain; cervical warning signs on flexion and extension films are more than about 3.5 mm of translation or 11 degrees of angulation between segments. Functional instability is poor control within normal range. Hypomobility is too little motion.

In ideal standing the plumb line passes near the earlobe, the cervical bodies, the shoulder, the lumbar bodies, slightly behind the hip, slightly in front of the knee and slightly in front of the lateral malleolus. Back extensors work at a moment arm of only about 5 cm, so loads held forward multiply spinal compression; distance matters more than weight. An occupational guideline set an action limit near 3,400 N at L5 to S1, with about 6,400 N intolerable for most workers. The 27 kg forward head figure came from a computer model, not people, and head position has not been consistently linked to neck pain. No single posture has been shown to prevent back pain: the best posture is the next posture.

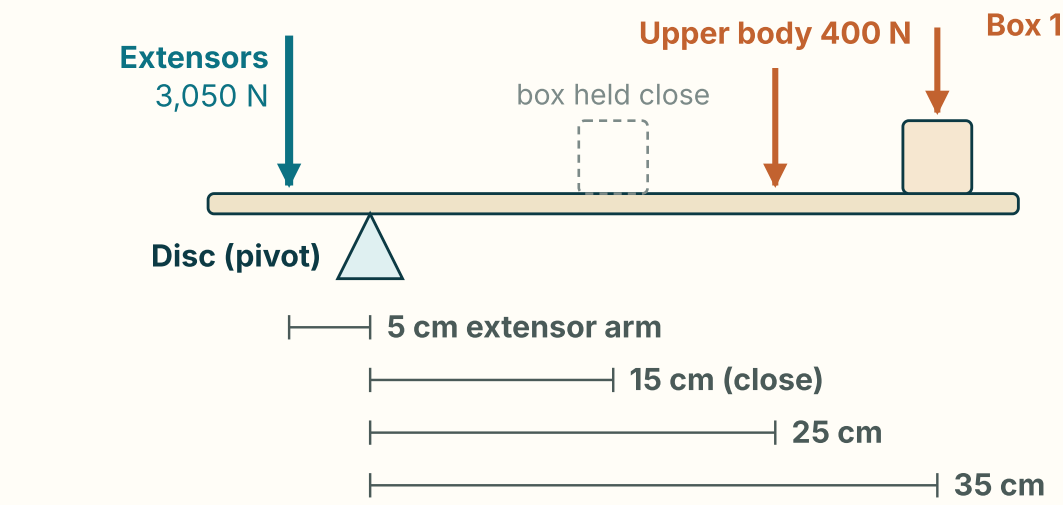

Moment	400 × 0.25 + 150 × 0.35 = 152.5 N·m
Extensor force	152.5 ÷ 0.05 = 3,050 N
Disc compression	3,050 + 500 above the disc = about 3,550 N
Box at 15 cm	122.5 N·m, 2,450 N, about 2,950 N of compression

Distance matters more than weight. The extensors act only 5 cm behind the disc, so every load held in front is multiplied. Moving the same 150 N box from 35 cm to 15 cm cuts the estimated compression by about 600 N.

LOCK THESE IN

- Sagittal plane: flexion and extension around a frontal axis. Frontal plane: lateral flexion around an AP axis. Transverse plane: rotation around a vertical axis.
- Six degrees of freedom: three rotations, three translations.
- Lower cervical coupling is same side and reliable. Lumbar coupling is small and variable; only Fryette's Law III fits the evidence.
- About 40 degrees of rotation each way at C1 to C2, about half of all neck rotation. Lumbar rotation is 1 to 2 degrees per segment.
- Creep, stress relaxation and hysteresis are the three viscoelastic behaviors.
- Flexion opens the back (posterior annulus); extension closes it (facets, pars); rotation jams the opposite facet; shear leans on the pars.
- Wilke: lying 0.1, standing 0.5, relaxed sitting about 0.46, rounded back 20 kg lift 2.3 MPa.
- Panjabi: passive, active, neural control. Neutral zone widens with injury, narrows with muscle.

Representative segmental motion (degrees)

Segment	Flexion plus extension	Lateral flexion, one side	Rotation, one side
Occiput to C1	About 25	About 5	About 5 or less
C1 to C2	About 20	About 5	About 40
C2 to C7, each	About 10 to 20, most at C5 to C6	About 5 to 10	About 5 to 10
Upper thoracic, each	About 4	About 6	About 8 to 9
Lower thoracic, each	About 6 to 12, rising toward T12	About 8 to 9	Falling to about 2 at T12 to L1
L1 to L5, each	About 12 to 16, rising caudally	About 6	About 2
L5 to S1	About 17 to 20	About 3	About 1

Key terms and comparisons

Term	Meaning	Remember it by
Creep	Deformation keeps growing under a constant load	Disc height lost through a day of sitting
Stress relaxation	Internal stress falls at a fixed length	A held stretch eases
Hysteresis	Energy lost as heat in a load and unload cycle	The loop on the curve; shock absorption
Moment	Force times perpendicular distance from the axis	N·m; distance matters more than weight
Neutral zone	Lax range near neutral with little resistance	Widens with injury, narrows with muscle
Clinical instability	Cannot protect neural tissue or prevent deformity under normal loads	Imaging, bracing, surgery, urgent referral
Functional instability	Poor control within normal range	Aberrant motion; exercise and motor control
Hypomobility	Less motion than expected at a segment	Mobilization, manipulation, exercise
Flexion relaxation	Extensors go quiet near full flexion	Often lost in chronic back pain

Worked cases

WORKED CASE 1 · ESTIMATING COMPRESSION WITH MOMENT ARMS

A worker leans forward so that 400 N of upper body weight acts 25 cm in front of the L5 to S1 disc. She holds a 150 N box 35 cm in front of the disc. The extensors act at 5 cm, and about 500 N of body weight sits above the disc. Estimate the compression, then redo it with the box held at 15 cm.

STEP 1 · FIND THE FLEXION MOMENT

(400 N × 0.25 m) + (150 N × 0.35 m) = 100 + 52.5 = **152.5 N·m**.

STEP 2 · FIND THE EXTENSOR FORCE

152.5 ÷ 0.05 = **3,050 N**.

STEP 3 · ADD THE WEIGHT ABOVE THE DISC

3,050 + 500 = about **3,550 N** of compression, just over the 3,400 N action limit the book quotes.

STEP 4 · BRING THE BOX CLOSE

Box moment 150 × 0.15 = 22.5 N·m. Total 100 + 22.5 = 122.5 N·m; extensor force 2,450 N; compression about **2,950 N**.

WHAT IT SHOWS

Moving the same box 20 cm closer cut the estimate by about 600 N. The model is two dimensional and ignores abdominal pressure and co-contraction, but it shows why distance matters more than weight.

WORKED CASE 2 · READING COUPLED MOTION IN THE NECK

A patient side bends the neck to the right. Viewed from behind, which way do the C3 to C6 bodies rotate and which way do the spinous processes move? Would the same rule apply at L3?

STEP 1 · RECALL THE CERVICAL RULE

Below C2, lateral flexion couples with rotation to the same side.

STEP 2 · MOVE THE BODIES

The bodies rotate to the **right**, toward the bend.

STEP 3 · MOVE THE SPINOUS PROCESSES

The spinous processes sit behind the axis, so they swing the other way, to the **left**, toward the convexity.

STEP 4 · TEST THE LOW BACK

No. Lumbar coupling is small and varies with person, level and starting posture, so the book says not to apply a fixed rule there.

WORKED CASE 3 · SORTING AN INSTABILITY LABEL

Two patients are described as unstable. One has a fracture through two columns after a fall, with normal range. The other has painful catching during forward bending and normal imaging. Which kind of instability fits each?

STEP 1 · DEFINE THE TERMS

Clinical instability is loss of the ability under normal loads to protect neural tissue and prevent deformity or disabling pain. Functional instability is poor control within the normal range.

STEP 2 · PLACE THE FRACTURE

Damage to two or more columns suggests structural instability even if range looks normal. This is **clinical instability**, which needs immobilization, imaging and referral.

STEP 3 · PLACE THE CATCHING

Aberrant motion with normal imaging fits **functional instability**, managed with exercise and motor control training.

THE LESSON

Stability is about control and protection, not range. A very flexible gymnast can be stable.

TRAPS PEOPLE FALL INTO

- **Swapping planes and axes.** Sagittal plane motion turns around a frontal axis, and frontal plane motion turns around a sagittal (AP) axis.
- **Applying cervical coupling to the low back.** Same side coupling is reliable only below C2 in the neck. Lumbar coupling is variable.
- **Teaching Fryette's Laws I and II as fact.** Systematic reviews did not confirm them. Only Law III fits the evidence.
- **Saying sitting is far harder on the disc than standing.** That came from older needle data. In vivo data showed relaxed sitting similar to standing.
- **Thinking twisting happens in the lumbar spine.** Lumbar rotation is only 1 to 2 degrees per segment. Most trunk twist is hips and thoracic spine.
- **Equating unstable with mobile.** Stability is control and protection. A fracture with normal range can be dangerously unstable.
- **Treating a load study as a pain study.** Many tips lower tissue load, but posture measures and lifting training have not been shown to prevent back pain.
- **Getting the facet side wrong in rotation.** In right rotation of a lumbar segment the left facet is compressed.

Chapter 2 self-test · ten items

1. A patient bends the trunk sideways to the left. In which plane and around which axis does this happen?

A. Frontal plane, around a vertical (long) axis
B. Sagittal plane, around a frontal axis
C. Frontal plane, around an anteroposterior axis
D. Transverse plane, around a vertical axis

C. Frontal plane, around an anteroposterior axis Lateral flexion happens in the frontal plane. The axis is always perpendicular to the plane, so it runs front to back.

2. A patient side bends the neck to the left. What happens at C4?

A. The body rotates right and the spinous process swings left
B. The body rotates left and the spinous process swings right
C. The body rotates left and the spinous process swings left
D. No rotation occurs because coupling begins below C7

B. The body rotates left and the spinous process swings right Lower cervical coupling is same side. The spinous process sits behind the axis, so it moves opposite to the body, toward the convex side.

3. A classmate says lumbar side bending in neutral always couples with opposite side rotation. What does the book conclude?

A. It holds only once the lumbar spine is fully flexed forward
B. It is correct, but only at the L5 to S1 segment
C. It is correct, and it is known as Fryette's Law II
D. Lumbar coupling is small and variable, so it is not a rule

D. Lumbar coupling is small and variable, so it is not a rule That statement is Fryette's Law I. Reviews found lumbar coupling varies between people, levels and starting postures.

4. Why does each lumbar segment rotate only about 1 to 2 degrees?

A. Its curved, sagittal facets jam together
B. The iliolumbar ligaments stop all rotation
C. Its tall discs resist all torsion completely
D. Its long, steep spinous processes overlap

A. Its curved, sagittal facets jam together As a lumbar vertebra turns, the facet opposite the direction of rotation presses into its partner within a few degrees, which protects the annulus.

5. A runner whose hamstrings are short reaches down toward her shoes. According to lumbopelvic rhythm, which region takes up the extra bending?

A. The lumbar spine flexes more than usual
B. The thoracic spine extends to compensate
C. The hips flex more than usual
D. Fingertip to floor distance becomes a pure lumbar measure

A. The lumbar spine flexes more than usual Tight hamstrings limit forward pelvic rotation at the hips, so more of the bend has to come from the lumbar spine.

6. A disc slowly loses height over hours of sitting under a steady load. Which viscoelastic behavior is this?

A. Hysteresis in a load cycle
B. Stress relaxation at fixed length
C. Creep under constant load
D. Plastic failure past the range

C. Creep under constant load Creep is continued deformation under a constant load. Stress relaxation is falling stress at a fixed length, and hysteresis is energy lost in a cycle.

7. According to the in vivo L4 to L5 measurements, which activity produced the highest disc pressure?

A. Standing bent forward without a load
B. Relaxed sitting without a backrest
C. Lifting 20 kg close with bent knees
D. Lifting 20 kg with a rounded back

D. Lifting 20 kg with a rounded back The rounded back lift reached about 2.3 MPa, compared with about 1.7 MPa for the close, bent knee lift and about 1.1 MPa for standing bent forward.

8. An older adult with spinal stenosis feels worse standing upright and better leaning on a shopping cart. What explains this?

A. Flexion raises facet load, which relieves roots
B. Extension narrows the canal; flexion opens it
C. Leaning forward drops disc pressure to near zero
D. Upright standing compresses the conus at L1

B. Extension narrows the canal; flexion opens it Extension brings the facets together and slightly narrows the foramina and central canal. Sitting or leaning forward enlarges them.

9. In Panjabi's model, what happens to the neutral zone after a ligament injury, and what does muscle activity do?

A. It widens after injury and narrows with muscle activity
B. It stays fixed, and only the elastic zone changes
C. It widens after injury and is unaffected by muscle
D. It narrows after injury and widens with muscle activity

A. It widens after injury and narrows with muscle activity Laboratory work found the neutral zone is a sensitive marker of lost passive restraint, and simulated muscle forces reduced it.

10. Using a 5 cm extensor moment arm and ignoring body weight, what extensor force holds a 50 N object 30 cm in front of the spine?

A. About 1,500 N
B. About 150 N
C. About 300 N
D. About 600 N

C. About 300 N Moment = 50 N × 0.30 m = 15 N·m. Force = 15 ÷ 0.05 = 300 N, six times the object's weight.

ONE PAGE

Cram sheet

Everything from chapters 1 and 2 in one place. Cover the right column and see if you can rebuild each row.

Numbers to know

Item	Value	Note
Vertebral counts	7 C, 12 T, 5 L, 5 fused S, usually 4 coccygeal	33 at birth; about 24 movable above the sacrum
Discs	23; first at C2 to C3	About a quarter of column height; 1 to 2 cm taller in the morning
Nucleus water	70 to 90% in a young adult	Held by proteoglycans such as aggrecan
Annulus	15 to 25 lamellae, fibers 60 to 65 degrees from vertical	Alternating direction; thinner behind
Curves	Thoracic kyphosis about 20 to 45; lumbar lordosis about 40 to 60 degrees	A finding, not a diagnosis
Sacral base angle	About 30 to 40 degrees standing	Steeper sacrum, deeper lordosis
Cord and sac	Conus near L1 to L2 (L3 at birth); sac ends near S2	31 pairs of spinal nerves
C1 to C2 rotation	About 40 degrees each way	About half of all neck rotation
Lumbar rotation	1 to 2 degrees per segment	About 10 degrees each way in all
Disc to body height	2:5 cervical, 1:5 thoracic, 1:3 lumbar	Taller disc, more motion
Facet load share	About 10 to 20% standing	Rises with extension, creep, degeneration
Wilke disc pressure	Lying 0.1; sitting 0.46; standing 0.5; bent forward 1.1; lifts 1.7 and 2.3 MPa	Single subject; illustrative
Buckling load	Isolated thoracolumbar about 20 N; lumbar about 90 N	Muscles make the difference
Cervical instability signs	Over about 3.5 mm translation or 11 degrees angulation	On flexion and extension films

Item	Value	Note
Lifting limits	Action limit about 3,400 N; about 6,400 N intolerable	At L5 to S1
Extensor moment arm	About 5 to 6 cm	Load arms are far longer

Equations and rules

Name	Rule	Units or note
Weight	1 kg weighs about 10 N	N
Moment	Force × perpendicular distance from the axis	N·m
Extensor force	Total flexion moment ÷ extensor moment arm	N
Compression estimate	Extensor force + body weight above the disc	N; ignores co-contraction
Ligament rule	A ligament limits the motion that pulls its ends apart	ALL: extension; the rest: flexion
Nerve exit rule	C1 to C7 above their vertebra; C8 at C7 to T1; T1 down below	31 pairs
Root rule	Posterolateral hits the traversing root; far lateral hits the exiting root	L4 to L5: L5 versus L4
Cervical coupling	Side bend and rotation to the same side below C2	Spinous processes toward the convexity

Rules that are not equations

Topic	The rule
Curves	Kyphoses are primary; lordoses are secondary (head control, then standing).
Identify a vertebra	Transverse foramen: cervical. Costal facets: thoracic. Big kidney body: lumbar.
Rami	Intrinsic back muscles and facets: dorsal rami. Limbs and front of trunk: ventral rami.
Loads	Flexion opens the back; extension closes it; rotation jams the opposite facet; shear leans on the pars.
Fryette	Law III fits the evidence; Laws I and II are not reliable rules.
Stability	Passive, active and neural control subsystems; stability is control, not range.
Posture	The best posture is the next posture; no single posture prevents pain.

Dr. Garg Learning · CC BY-SA 4.0