NPTE REVIEW · STUDY GUIDE

Study Guide 2

This guide goes with Practice Exam 2 and covers the two extremity chapters. Chapter 3 works from the shoulder to the fingertips: how to sort shoulder pain, what each operation puts at risk, and how to place a nerve lesion from its motor and sensory pattern. Chapter 4 does the same for the lower limb and then asks the question behind most of it: can this patient bear weight and walk safely? Work one chapter at a time, study the diagram, then try each worked case with the steps covered before checking yourself with the ten board-style items.

WHAT THIS GUIDE COVERS

- Chapter 3 · scapulohumeral rhythm and force couples, cuff tendinopathy versus tear versus capsulitis, instability, shoulder special tests, precautions after cuff repair, Bankart, anatomic and reverse arthroplasty, the elbow and its nerves, carpal tunnel and de Quervain, wrist fractures, flexor zones, deformities, splints, the brachial plexus and Seddon grades.
- Chapter 4 · hip OA, FAI and labral tears, hip fractures, THA precautions by approach, knee ligament and meniscus tests, patellofemoral pain, ACL and TKA rehabilitation, Ottawa ankle rules, Achilles and plantar heel pain, foot mechanics, the gait cycle, deviations, weight bearing orders, osteoporosis, RA and amputation levels.

CHAPTER 3

Musculoskeletal: The Upper Extremity

Read it in full: **Chapter 3 in the textbook**. Practice it: **Practice Exam 2** and the **flashcards**.

What to know

Full elevation is about 180 degrees, shared roughly **2:1**: about 120 degrees at the glenohumeral joint and 60 degrees of scapular upward rotation. The upper trapezius, lower trapezius and serratus anterior form the upward rotation force couple; the cuff compresses and depresses the humeral head so the deltoid can rotate it rather than shear it upward. Medial winging suggests long thoracic

nerve (serratus) palsy; lateral winging with a depressed scapula suggests spinal accessory (trapezius) injury.

Sort shoulder pain by comparing active, passive and resisted motion. Full passive range with a **painful arc** (about 60 to 120 degrees) and painful resisted tests is cuff related pain. Active far below passive with weakness means a tear or a nerve palsy (drop arm, external rotation lag, hornblower). Equal active and passive loss in a capsular pattern (external rotation first, then abduction, then internal rotation) is **adhesive capsulitis** or arthritis; capsulitis is linked to diabetes and is treated by irritability.

About 95 percent of dislocations are anterior. Look for a Bankart lesion (anteroinferior labrum), a Hill Sachs lesion (posterolateral humeral head) and **axillary nerve** injury (deltoid weakness, numb regimental badge area). TUBS instability usually needs surgery; AMBRI is rehabilitated. Posterior dislocation follows seizures or electric shock. Apprehension and relocation are used together for anterior instability.

Each shoulder operation has a tissue at risk. After **rotator cuff repair**: no active elevation for about 6 weeks, no resisted loading until about 12 weeks. After a **Bankart repair**: no combined abduction and external rotation for about 6 weeks. After **anatomic TSA** (needs an intact cuff): protect the subscapularis, limiting passive external rotation and active internal rotation for about 6 weeks. After **reverse TSA** (the deltoid substitutes for the cuff): avoid extension, adduction and internal rotation together, the hand behind the back, for about 12 weeks.

Lateral epicondylalgia is an ECRB tendinopathy; pain free grip strength is the best outcome measure, and corticosteroid injection helps short term but does worse at one year. The UCL is the main restraint to valgus stress and fails in throwers. Supracondylar fractures in children threaten the brachial artery and forearm compartments: **pain with passive finger extension** is an emergency, and Volkmann contracture is the result if it is missed.

Carpal tunnel syndrome numbs the thumb to the radial ring finger, worse at night, but spares the thenar eminence because the palmar cutaneous branch leaves above the tunnel. Splint the wrist in neutral at night. De Quervain involves APL and EPB (Finkelstein, Eichhoff); use a thumb spica

with the IP free. Snuffbox tenderness is a scaphoid fracture until proven otherwise, because proximal pole fractures risk avascular necrosis.

Zone II flexor tendon repairs sit inside a tight sheath and form adhesions easily. They are protected in a **dorsal blocking orthosis**, with rupture risk highest at days 5 to 21; no active gripping or resisted flexion for about 6 to 8 weeks. A mallet finger is splinted with the DIP in extension for about 6 to 8 weeks, and any DIP flexion restarts the clock. The safe immobilization position is wrist extended, MCPs flexed 70 to 90 degrees, IPs extended.

The plexus runs roots, trunks, divisions, cords, branches. Erb palsy (C5, C6, upper trunk) gives the waiter's tip; Klumpke (C8, T1, lower trunk) weakens the intrinsics and may include Horner syndrome, a sign of root avulsion. Radial nerve: wrist drop with intact triceps localizes to the spiral groove, wrist drop plus weak triceps to the axilla, finger drop with intact wrist extension and no sensory loss to the posterior interosseous nerve. Median: ape hand at the wrist, benediction above the elbow. Ulnar: claw hand, Froment and Wartenberg signs, and the ulnar paradox.

Seddon grades predict recovery. **Neurapraxia** is a conduction block that recovers fully in days to about 12 weeks. **Axonotmesis** disrupts the axon with sheaths intact and regrows about **1 mm per day** (about 1 inch a month). **Neurotmesis** needs surgical repair. Delay needle EMG about 3 weeks, when fibrillations appear. Meanwhile protect insensate skin, prevent contracture with orthoses and avoid overstretching denervated muscle.

Radial nerve, top to bottom

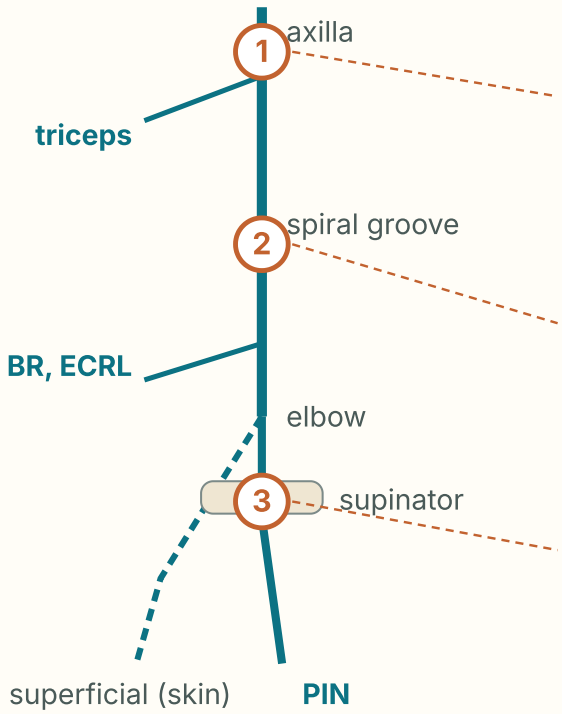

1 Axilla (crutch palsy)

Triceps weak AND wrist drop
Numb posterior arm, forearm and dorsal radial hand

2 Spiral groove (midshaft fracture)

Wrist drop; triceps spared (its branch leaves above)
Numb dorsal first web space

3 PIN at the supinator

Finger drop; wrist still extends, drifting radially (ECRL spared)
No sensory loss

One nerve, three lesion levels. Each branch that leaves above a lesion is spared. Triceps tells axilla from spiral groove, and the PIN has no skin branch.

LOCK THESE IN

- Elevation 2:1: about 120 degrees glenohumeral and 60 scapular.
- Active equals passive loss = capsule; active much less than passive = tear or nerve.
- Capsulitis: external rotation lost first; diabetes; treat by irritability.
- Cuff repair: no active elevation about 6 weeks. Reverse TSA: no extension plus adduction plus IR about 12 weeks.
- Carpal tunnel spares thenar sensation; splint in neutral at night.
- Zone II flexor repair: rupture risk peaks days 5 to 21; no gripping 6 to 8 weeks.
- Radial nerve: spiral groove spares triceps; axilla adds triceps; PIN spares wrist extension and sensation.
- Axonotmesis regrows about 1 mm per day; EMG after about 3 weeks.

Shoulder sorting and surgery

Item	Rule
Painful arc	About 60 to 120 degrees: subacromial pain or cuff tendinopathy
Drop arm, ER lag	Full thickness cuff tear
Lift off, belly press	Subscapularis tear
Apprehension then relocation	Anterior instability confirmed when relocation relieves apprehension
O'Brien	Deep pain thumb down, relieved palm up: SLAP
Cuff repair	Passive range within limits 0 to 6 weeks; active 6 to 12; resisted after about 12
Anatomic TSA	Intact cuff needed; protect subscapularis about 6 weeks
Reverse TSA	Deltoid powered; dislocation in extension, adduction and IR

Upper limb nerve lesions

Nerve and level	Finding
Axillary	Weak abduction and ER; numb lateral shoulder
Radial, axilla	Triceps weak plus wrist drop
Radial, spiral groove	Wrist drop, triceps spared, numb dorsal first web
Posterior interosseous	Finger drop, wrist extends radially, no sensory loss
Median, above elbow	Benediction on attempted fist; thenar skin numb
Median, wrist	Ape hand; thenar skin spared
Anterior interosseous	No OK sign; purely motor
Ulnar, elbow versus wrist	Elbow: less claw, dorsal hand numb. Guyon: more claw, dorsal hand spared

Worked cases

WORKED CASE 1 · CAPSULE OR CUFF?

A 52 year old woman with type 2 diabetes has four months of shoulder pain and stiffness without injury. Active and passive external rotation are both about 20 degrees, abduction 80. Resisted tests are strong. Night pain and pain before end feel. What is the plan?

STEP 1 · COMPARE ACTIVE AND PASSIVE

Equal loss means a capsular problem, not a tear.

STEP 2 · CHECK THE PATTERN

External rotation is worst: the shoulder capsular pattern.

STEP 3 · ADD THE HISTORY

Middle aged, female, diabetes: **adhesive capsulitis**.

STEP 4 · GRADE IRRITABILITY

Night pain and pain before resistance mean high irritability.

STEP 5 · CHOOSE

Pain control, grade I and II mobilization, pain free range and education, with referral for an intra-articular injection combined with therapy. Grade IV stretching now would flare it.

WORKED CASE 2 · LIVING WITH A REVERSE TSA

A 76 year old man is 3 weeks after reverse TSA. He asks how to manage toileting and getting up from his recliner.

STEP 1 · NAME THE DANGER POSITION

Extension, adduction and internal rotation together: the hand behind the back.

STEP 2 · MATCH IT TO HIS TASKS

Reaching behind for hygiene and pushing up with the arm behind him both use it.

STEP 3 · TEACH

Hygiene with the other hand or from the front with adaptive equipment; scoot forward and push up through the uninvolved arm.

SAFETY

A sudden clunk with loss of motion suggests dislocation: support the arm and notify the surgeon.

WORKED CASE 3 · COMPARTMENT SYNDROME AFTER A SUPRACONDYLAR FRACTURE

A 7 year old had a displaced supracondylar fracture pinned yesterday. Pain is not relieved by medication, the forearm is tense and passive finger extension causes severe pain.

STEP 1 · READ THE EARLY SIGNS

Pain out of proportion and pain with passive stretch of the forearm flexors.

STEP 2 · DO NOT WAIT

Pulselessness and pallor are late signs.

STEP 3 · ACT

Stop, keep the arm at heart level, loosen anything constrictive if allowed and notify the physician at once. Elevating above the heart lowers perfusion.

WORKED CASE 4 · HOW LONG UNTIL THE WRIST EXTENSORS WAKE UP?

A 28 year old has a midshaft humerus fracture with wrist and finger drop, numb dorsal first web space and strong triceps. About how long could reinnervation of the wrist extensors take if the lesion is about 12 cm from them?

STEP 1 · LOCALIZE

Wrist drop with triceps spared: radial nerve at the spiral groove.

STEP 2 · CONVERT

12 cm = 120 mm.

STEP 3 · DIVIDE BY THE RATE

120 mm ÷ 1 mm per day = **120 days, about 4 months**.

STEP 4 · TREAT MEANWHILE

Wrist cock up or dynamic extension orthosis, passive range and education; EMG after about 3 weeks.

TRAPS PEOPLE FALL INTO

- **Starting active elevation after cuff repair.** The first 6 weeks are passive range within limits, pendulums and distal joints.
- **Strengthening the cuff after reverse TSA.** The deltoid and scapular muscles do the work; the cuff is absent.
- **Calling thenar numbness carpal tunnel.** The palmar cutaneous branch leaves above the tunnel, so thenar numbness points higher.
- **Elevating a limb with suspected compartment syndrome.** Keep it at heart level and call the physician.
- **Ordering EMG on day 3.** Denervation potentials take about 3 weeks to appear.
- **Expecting more claw with a high ulnar lesion.** The ulnar paradox: FDP is also weak, so clawing is less.

Chapter 3 self-test · ten items

1. A 58 year old has lateral shoulder pain with overhead reaching, a painful arc from 70 to 115 degrees, full passive range and painful but strong resisted abduction. What is most likely?

A. Long thoracic nerve palsy
B. Rotator cuff related shoulder pain
C. Adhesive capsulitis in the frozen stage
D. Full thickness supraspinatus tear

B. Rotator cuff related shoulder pain Full passive range with a painful arc and painful but strong resisted tests is cuff tendinopathy. A tear would show weakness and active less than passive.

2. After an anterior shoulder dislocation, which finding should be checked first for nerve injury?

A. Sensation over the medial elbow
B. Strength of wrist and finger extension
C. Sensation over the lateral shoulder
D. Strength of finger abduction and grip

C. Sensation over the lateral shoulder The axillary nerve is the nerve most often injured. Check deltoid strength and the regimental badge area.

3. Four weeks after rotator cuff repair, which activity is appropriate?

A. Passive scaption within the surgeon's limits
B. Active elevation against gravity in standing
C. Pushing up from a chair with both arms
D. Resisted external rotation with a band

A. Passive scaption within the surgeon's limits Phase I (0 to about 6 weeks) allows passive range within limits, pendulums and distal joint motion. Active elevation and resisted work come later.

4. Which precaution is specific to anatomic total shoulder arthroplasty through a deltopectoral approach?

A. Avoid combined abduction and ER for 6 weeks
B. Avoid resisted elbow flexion for 6 weeks
C. Avoid hand behind back for about 12 weeks
D. Limit passive ER and active IR about 6 weeks

D. Limit passive ER and active IR about 6 weeks The subscapularis is detached and repaired, so external rotation stretch and active internal rotation are limited. Hand behind back is the reverse TSA precaution.

5. A carpenter has pain 4 cm distal to the lateral epicondyle over the supinator, pain with resisted supination, normal strength and no numbness. What is most likely?

A. Posterior interosseous nerve palsy
B. Radial tunnel syndrome
C. Lateral epicondylalgia
D. Cubital tunnel syndrome

B. Radial tunnel syndrome Tenderness distal to the epicondyle over the supinator with pain on resisted supination and normal strength is radial tunnel syndrome. PIN palsy would cause finger drop.

6. A patient cannot make an OK sign; the tip pinch is flat. Sensation is normal. Which nerve is involved?

A. Anterior interosseous nerve
B. Ulnar nerve at Guyon canal
C. Posterior interosseous nerve
D. Median nerve at the carpal tunnel

A. Anterior interosseous nerve The anterior interosseous nerve supplies FPL, index FDP and pronator quadratus and has no sensory branch.

7. A 30 year old new parent has pain at the radial styloid, worse when the wrist is ulnarly deviated with the thumb held in a fist. Which orthosis fits?

A. DIP extension splint with the PIP free
B. Dorsal blocking orthosis with MCPs flexed
C. Neutral wrist orthosis worn at night
D. Thumb spica including the wrist, IP free

D. Thumb spica including the wrist, IP free This is de Quervain tenosynovitis of APL and EPB. A thumb spica that includes the wrist and leaves the IP free rests the first compartment.

8. Ten days after a zone II flexor tendon repair, the patient wants to make a tight fist. What is correct?

A. Yes, if the orthosis is worn after
B. Yes, once pain is under 3 out of 10
C. Not yet; rupture risk is highest now
D. Yes, if done slowly and only once

C. Not yet; rupture risk is highest now Days 5 to 21 are the window of greatest rupture risk. Active gripping waits about 6 to 8 weeks.

9. A woman has weak finger abduction, clawing of the ring and little fingers and numbness of the palmar little finger, but normal dorsal hand sensation. Where is the lesion?

A. Median nerve at the carpal tunnel
B. Ulnar nerve at the cubital tunnel
C. Lower trunk of the brachial plexus
D. The ulnar nerve at Guyon canal

D. The ulnar nerve at Guyon canal The dorsal cutaneous branch leaves above the wrist, so a spared dorsal hand points to the wrist. Clawing is more marked distally (the ulnar paradox).

10. A nerve is crushed 25 cm above the muscle it supplies, with sheaths intact. Roughly how long until that muscle could be reinnervated?

A. About 8 months
B. About 2 years
C. About 3 weeks
D. About 2 months

A. About 8 months Axonotmesis regrows about 1 mm per day: 250 mm ÷ 1 mm per day = 250 days, a little over 8 months.

CHAPTER 4

Musculoskeletal: The Lower Extremity and Gait

Read it in full: **Chapter 4 in the textbook**. Practice it: **Practice Exam 2** and the **flashcards**.

What to know

Hip OA brings groin or anterior thigh pain, morning stiffness under an hour and a capsular pattern with **internal rotation and flexion** lost first. Treat with education, weight management, manual therapy, strengthening and a device. A **cane goes in the opposite hand**: it moves with the painful leg and lowers the abductor force on the stance side. Cam FAI (young athletic men) and pincer FAI (middle aged women) cause groin pain with sitting and pivoting; FADIR is sensitive, so a negative helps rule out.

Femoral neck fractures are intracapsular and threaten the blood supply from the medial circumflex femoral artery, so displaced ones get arthroplasty. Intertrochanteric fractures heal well and are fixed. Most repairs allow weight bearing as tolerated, with mobilization in 24 to 48 hours. THA precautions follow the approach. **Posterior**: no flexion past 90, no adduction past midline, no internal rotation. **Anterior**: no extension past neutral, no external rotation. Up with the good, down with the bad.

At the knee: **Lachman** is the most sensitive ACL test and the **pivot shift** the most specific; the **posterior drawer** is the best PCL test. Valgus gapping at 30 degrees only is the MCL; at 0 degrees it adds a cruciate or capsule. For a PCL tear, emphasize the quadriceps and delay isolated hamstring resistance. Meniscus tears give delayed swelling, joint line pain and locking; only the outer red zone heals after repair.

Patellofemoral pain responds to **combined hip and knee strengthening**, plus taping and orthoses for short term relief. After ACL reconstruction the graft is weakest at about 6 to 12 weeks. Restore full extension and quadriceps activation first; limit open chain extension to 90 to 45 degrees early and use closed chain work in about 0 to 60. Running starts around 3 months; return to sport no earlier than about 9 months with **limb symmetry of 90 percent or more** on strength and hop tests.

After TKA, extension loss is functionally worst: no pillow under the knee, a towel roll under the ankle instead. Aim for at least about 90 degrees of flexion early and use progressive quadriceps strengthening with NMES; continuous passive motion adds little. The **Ottawa ankle rules** call for films with malleolar pain plus tenderness at the posterior edge or tip of either malleolus (distal 6 cm), or inability to bear weight four steps; the foot series uses the base of the fifth metatarsal and the navicular.

Lateral sprains tear the ATFL first (anterior drawer), then the CFL (talar tilt). A high ankle sprain injures the syndesmosis (squeeze test, external rotation test) and takes about twice as long. Midportion Achilles tendinopathy (2 to 6 cm above the insertion) uses heavy slow or eccentric loading; insertional cases do not drop the heel below the step. The **Thompson test** detects rupture. Plantar heel pain is worst with the first morning steps; the windlass test is specific.

Stance is about **60 percent** of the gait cycle and swing 40, with two periods of double support of about 10 percent each. Stance muscles mostly work eccentrically. Weakness shows in the phase where the muscle should work: quadriceps and dorsiflexors at loading response, gluteus medius in single limb stance (Trendelenburg, pelvis drops on the swing side), plantarflexors in terminal stance, dorsiflexors in swing (steppage). A functionally long swing limb causes circumduction, hip hiking or vaulting.

Comfortable gait speed is about 1.2 to 1.4 m/s and cadence about 100 to 120 steps a minute. For stroke: under 0.4 m/s household, 0.4 to 0.8 limited community, over 0.8 community. Normal walking needs about 60 degrees of knee flexion, 10 degrees of dorsiflexion and about 60 degrees of first MTP extension.

Weight bearing orders run NWB, toe touch, partial, WBAT and full; teach partial with a scale. Use a three point gait for a restricted limb. Clinical union is around 6 to 8 weeks in many adult fractures. **Osteoporosis** is a T score at or below negative 2.5: load the bones but avoid loaded spinal flexion. In RA flares, rest and splint and use gentle range; watch the upper cervical spine. Transfemoral amputees develop hip flexion and abduction contractures; transtibial amputees develop knee flexion contractures.

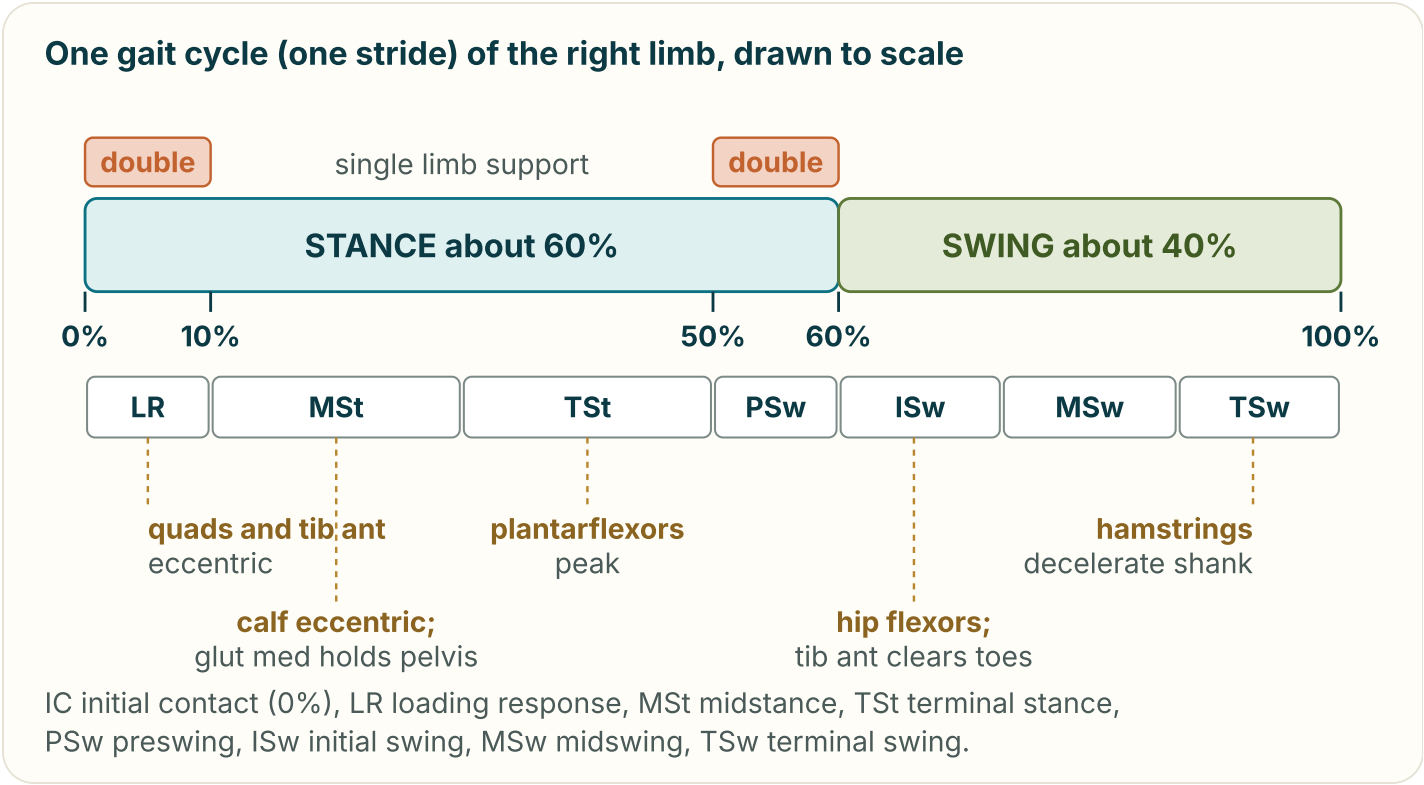

The gait cycle, drawn to scale. A weak muscle shows up in the phase where it is supposed to work, so learn each phase with its muscle.

LOCK THESE IN

- Hip capsular pattern: IR and flexion first. Cane in the opposite hand.
- Posterior THA: no flexion past 90, adduction or IR. Anterior THA: no extension or ER.
- Lachman most sensitive ACL test; pivot shift most specific; posterior drawer for PCL.
- ACL return to sport: about 9 months and 90 percent limb symmetry.
- After TKA: full extension first, quadriceps with NMES, at least 90 degrees flexion.
- Ottawa: posterior edge or tip of either malleolus, base of 5th metatarsal, navicular, or four steps.
- Stance 60, swing 40; double support about 10 percent twice.
- Osteoporosis T score ≤ −2.5; avoid loaded spinal flexion.

Gait deviations and their causes

Deviation	Cause
Trendelenburg	Weak gluteus medius on the stance side; pelvis drops on the swing side
Backward trunk lean at contact	Weak gluteus maximus
Forward lean or hand on thigh in loading	Weak quadriceps
Foot slap	Mild dorsiflexor weakness at loading response
Steppage	Foot drop: common fibular nerve, L4 to L5, neuropathy
Circumduction, hip hiking, vaulting	Functionally long swing limb
No heel rise, short opposite step	Weak plantarflexors
Scissoring	Hip adductor spasticity

Weight bearing and bone

Item	Rule
NWB	Foot off the floor; three point gait with walker or axillary crutches
TTWB	Foot touches for balance only
PWB	A stated amount; teach with a bathroom scale
WBAT, FWB	As tolerated; no restriction
Stairs with crutches	Up with the good limb, down with crutches and involved limb
T score	Normal ≥ −1.0; osteopenia −1.0 to −2.5; osteoporosis ≤ −2.5
Transtibial energy cost	About 20 to 40% above normal
Transfemoral energy cost	About 60 to 100% above normal

Worked cases

WORKED CASE 1 · POSTERIOR HIP PRECAUTIONS AT HOME

An 80 year old woman is 1 day after a posterior approach THA, WBAT. She needs to use a standard height toilet and put on socks.

STEP 1 · LIST THE PRECAUTIONS

No flexion past 90, no adduction past midline, no internal rotation.

STEP 2 · TEST EACH TASK

A low toilet flexes the hip past 90. Reaching to the foot adds flexion and often internal rotation.

STEP 3 · CHOOSE

Raised toilet seat or commode, back up until she feels it, slide the operated leg forward as she sits; sock aid and reacher.

SAFETY

Sudden severe pain with a short, internally rotated leg suggests dislocation: stop and notify the surgeon.

WORKED CASE 2 · IS SHE READY TO CUT?

A 17 year old is 10 weeks after BTB ACL reconstruction with full motion and no effusion. Her quadriceps limb symmetry index is 72 percent. She wants to start cutting drills.

STEP 1 · PLACE THE GRAFT IN TIME

At 10 weeks the graft is still near its weakest point (6 to 12 weeks).

STEP 2 · COMPARE TO CRITERIA

72 percent is far below the 90 percent target.

STEP 3 · CHOOSE

Keep building the quadriceps (closed chain and open chain in a protected arc), neuromuscular and landing training, and a straight line running progression around 3 months if criteria are met.

WHY IT MATTERS

Early return and asymmetry predict a second ACL injury in either knee.

WORKED CASE 3 · APPLYING THE OTTAWA ANKLE RULES

A 24 year old inverted his ankle an hour ago and limps four steps in the clinic. He is tender over the ATFL but not on the posterior edge or tip of either malleolus, the base of the fifth metatarsal or the navicular.

STEP 1 · WEIGHT BEARING

He took four steps: that criterion is not met.

STEP 2 · BONE TENDERNESS

None at the four Ottawa points.

STEP 3 · DECIDE

No radiographs needed. **Semirigid or lace up brace, early WBAT, edema control and range, then strengthening and balance.**

RECHECK

A positive squeeze or external rotation test would point to the syndesmosis.

WORKED CASE 4 · NAMING A GAIT DEVIATION

Three weeks after a fibular head fracture, a 58 year old lifts his left knee high in swing and lands toe first. The dorsum of his foot is numb.

STEP 1 · DESCRIBE

Excess hip and knee flexion in swing with toe first contact: **steppage gait**.

STEP 2 · LOCALIZE

The common fibular nerve wraps the fibular neck; dorsal foot numbness fits.

STEP 3 · TREAT

An ankle foot orthosis such as a posterior leaf spring, plus skin protection education.

TRAPS PEOPLE FALL INTO

- **Cane in the same hand as the painful hip.** It goes in the opposite hand to lower abductor demand.
- **Mixing up approach precautions.** Posterior: flexion, adduction, IR. Anterior: extension and ER.
- **Clearing an ACL patient on time alone.** Use strength and hop symmetry of at least 90 percent, full motion and no effusion.
- **A pillow under the knee after TKA.** It feeds a flexion contracture; use a towel under the ankle.
- **Placing Trendelenburg weakness on the dropping side.** The weak gluteus medius is on the stance side.
- **Sit ups for a patient with osteoporosis.** Loaded spinal flexion raises vertebral fracture risk.

Chapter 4 self-test · ten items

1. A 64 year old has right hip OA. On which side should she use a single point cane?

A. In her right hand only
B. In either hand equally
C. In her left hand only
D. Right hand, on stairs only

C. In her left hand only The cane goes opposite the painful hip so it moves with the involved leg and lowers abductor force.

2. Two days after an anterior approach THA, which movement should the patient avoid?

A. Sitting in a chair with hips at 85 degrees
B. Stepping back with the leg turned out
C. Lying on the back with a pillow between knees
D. Ankle pumps and quadriceps sets in bed

B. Stepping back with the leg turned out Anterior approach precautions limit extension past neutral and external rotation, especially combined.

3. A soccer player twisted his knee, felt a pop and had a large effusion within 2 hours. Which test is most sensitive for the likely injury?

A. McMurray test with rotation
B. Posterior sag test at 90 degrees
C. Pivot shift test from extension
D. Lachman test at 20 to 30 degrees

D. Lachman test at 20 to 30 degrees A noncontact pivot with a pop and rapid hemarthrosis suggests ACL tear. Lachman is the most sensitive; pivot shift is the most specific.

4. Which exercise is the best early choice after an isolated PCL tear?

A. Progressive quadriceps strengthening
B. Isolated resisted hamstring curls
C. Full depth squats to 120 degrees
D. Prone hamstring curls with a cuff weight

A. Progressive quadriceps strengthening The quadriceps pulls the tibia forward. Isolated hamstring work pulls it back and stresses the healing PCL.

5. Three weeks after TKA a patient lacks 12 degrees of extension. Which instruction helps most?

A. Stop quadriceps work until pain settles
B. Towel roll under the ankle, not the knee
C. Pillow under the knee while sleeping
D. Continuous passive motion all night

B. Towel roll under the ankle, not the knee Extension loss is functionally worst. A pillow under the knee holds it flexed; a towel under the ankle lets it extend.

6. A 45 year old felt "kicked" in the calf while pushing off in tennis. Squeezing the calf produces no plantarflexion. What is the likely problem?

A. Complete Achilles tendon rupture
B. Medial gastrocnemius strain only
C. Midportion Achilles tendinopathy
D. High ankle (syndesmosis) sprain

A. Complete Achilles tendon rupture A positive Thompson test means the tendon is ruptured. Active plantarflexion can remain through other muscles.

7. During right single limb stance the left side of the pelvis drops. Which muscle is weak?

A. Right gluteus maximus
B. Left gluteus medius
C. Right gluteus medius
D. Left hip adductors

C. Right gluteus medius The weak gluteus medius is on the stance side; the pelvis drops on the opposite, swing side.

8. A patient with a knee locked in extension in a brace swings the leg out to the side. What is this deviation?

A. Scissoring gait
B. Steppage gait
C. Trendelenburg gait
D. Circumduction

D. Circumduction A functionally long swing limb leads to circumduction, hip hiking or vaulting.

9. A woman has a DXA T score of −2.8 and no fractures. How is this classified?

A. Severe osteoporosis
B. Osteopenia
C. Normal for her age
D. Osteoporosis

D. Osteoporosis Osteoporosis is a T score at or below −2.5. Severe osteoporosis adds a fragility fracture.

10. Which positioning advice fits a new transfemoral amputee?

A. Lie prone daily; nothing under the limb
B. Pillow between the thighs in side lying
C. Pillow under the residual limb at night
D. Sit with the hip flexed most of the day

A. Lie prone daily; nothing under the limb Transfemoral amputees develop hip flexion, abduction and ER contractures. Prone lying counters them.

Cram sheet

One page for Study Guide 2. Cover the right column and say the answer before you look.

Upper extremity

Topic	Rule
Rhythm	2:1, about 120 GH and 60 scapular
Sorting	Full passive + arc = tendinopathy; active < passive = tear or nerve; equal loss = capsule
Dislocation	95% anterior; Bankart, Hill Sachs, axillary nerve
Cuff repair	No active elevation about 6 weeks; resisted about 12
Reverse TSA	No extension + adduction + IR about 12 weeks
Elbow	ECRB tendinopathy; UCL for valgus; supracondylar = compartment watch
Wrist	CTS spares thenar skin; de Quervain = APL, EPB; snuffbox = scaphoid
Flexor zone II	Dorsal blocking orthosis; days 5 to 21 riskiest
Nerves	Radial wrist drop; median ape or benediction; ulnar claw
Seddon	Neurapraxia full; axonotmesis 1 mm/day; neurotmesis surgery

Lower extremity and gait

Topic	Rule
Hip OA	IR and flexion lost; cane opposite
THA	Posterior: flexion > 90, adduction, IR. Anterior: extension, ER
Knee tests	Lachman, pivot shift, posterior drawer, McMurray, Thessaly
ACL	Graft weakest 6 to 12 weeks; RTS about 9 months, LSI ≥ 90%
TKA	Extension first; at least 90 degrees flexion; NMES
Ottawa	Malleoli posterior edge or tip, 5th MT base, navicular, four steps
Gait	Stance 60, swing 40; speed 1.2 to 1.4 m/s
Stroke speed	< 0.4 household; 0.4 to 0.8 limited; > 0.8 community
Bone	Clinical union about 6 to 8 weeks; T ≤ −2.5 osteoporosis
Amputation	TF: hip flexion and abduction contracture; TT: knee flexion

Dr. Garg Learning · CC BY-SA 4.0