# Final Study Guide

The final guide covers all fourteen chapters. Each chapter here is shorter than in its study guide: three paragraphs of what to know, the diagram, the points to lock in, one table, one worked case, the traps and six new self-test items. If a chapter feels shaky, go back to its study guide for the full treatment. The long cram sheet at the end pulls the routines, numbers, red flags and set ups into one place. Station formats and timings change, so confirm current details in the official candidate materials.

**WHAT THIS GUIDE COVERS**

- Foundations: chapters 1 and 2 (how the practical works; reading films under time).
- High yield films: chapters 3 and 4 (trauma; arthritis, tumors, infection, metabolic and soft tissue findings).
- The case station: chapters 5, 6, 7 and 8 (history, examination, decisions, documentation and communication).
- Technique: chapters 9, 10, 11 and 12 (principles, cervical and thoracic, lumbopelvic, extremity set ups).
- Practice stations: chapters 13 and 14 (imaging and case walk throughs; technique walk throughs and the final week).
- Every chapter carries what to know, a diagram, a table, a worked case, the traps and a six item self-test, and the cram sheet holds the rest.

CHAPTER 1

## How the Practical Exam Works and How to Prepare

Read it in full: **Chapter 1 in the textbook**. Practice it: **the practice exams** and **the flashcards**.

### What to know

Part IV is an OSCE style practical exam: short, standardized, timed stations in technique, case management and imaging. The door card gives the patient, the complaint and the task, and the task verb defines the checklist. SPs answer only what you ask. Confirm current station details in the official candidate materials.

Stations are scored by checklists of observable actions, critical actions and global ratings. Verbalizing makes your reasoning scorable: state each result, the pertinent negatives, and in technique stations the listing, contact point, segmental contact, stabilization and line of drive. Most lost points come from habit failures such as a skipped opening, silent testing and time mismanagement.

Every station runs open, explain, consent, perform, check, close. Consent covers nature, material risks, benefits and alternatives, and it can be withdrawn at any time. The stop rule is stop, release, reassess, and refer when warning signs appear. A red flag outranks the planned task, and the note records only what you did.

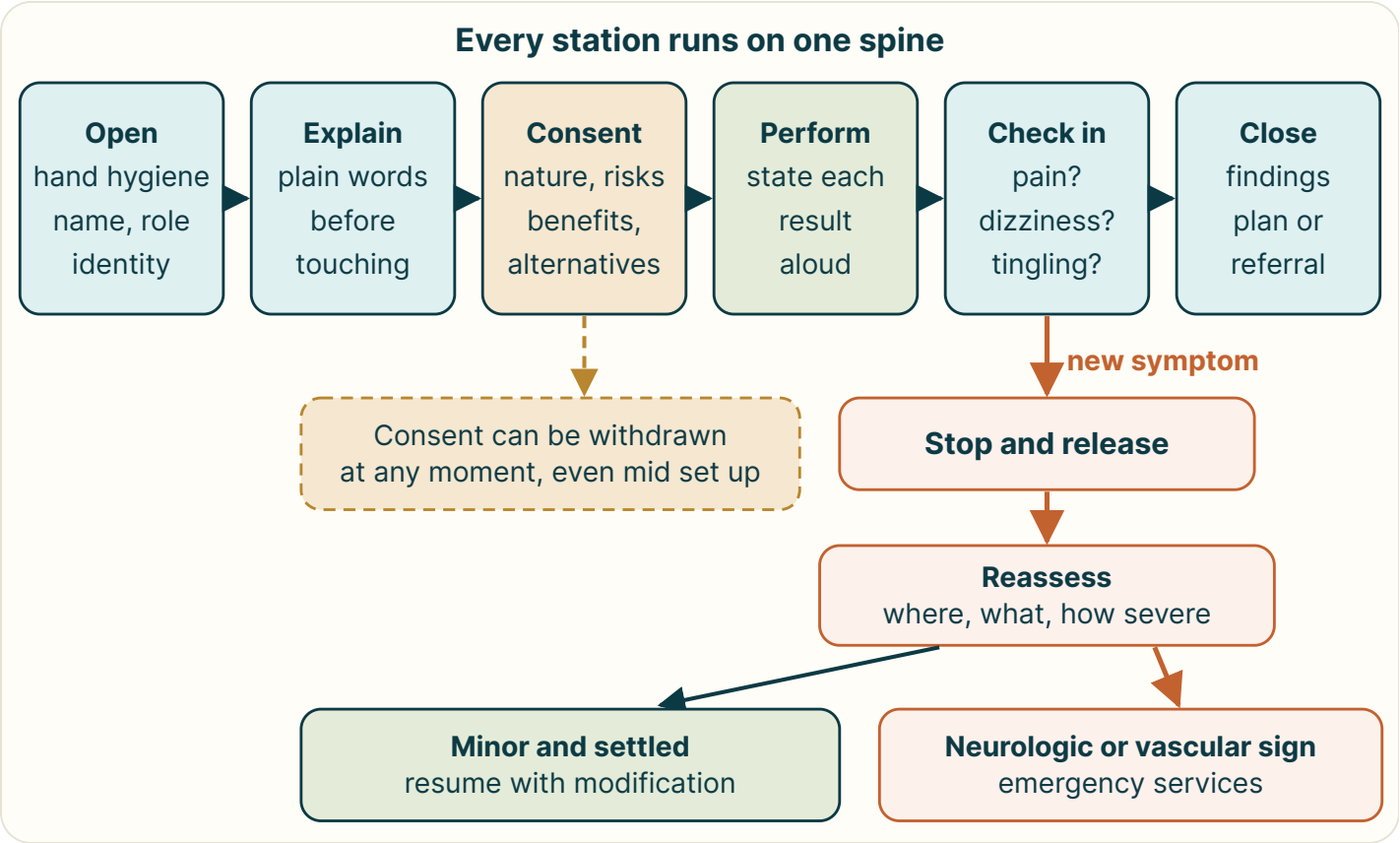


**The communication spine and the stop rule.** Every station, whatever its content, runs open, explain, consent, perform, check, close. Any new symptom during a test or set up triggers the same stop rule.

**LOCK THESE IN**

- The door card verb tells you what is scored.
- SPs reveal only what is asked.
- If it is not said aloud, it cannot be scored.
- Move to the close at the time warning.
- Stop rule: stop, release, reassess, refer if needed.
- Red flags outrank the task: do not treat the region, refer at the right urgency.

## Chapter 1 essentials

| Item | Key point |
|---|---|
| **Content areas** | Technique, case management, imaging interpretation |
| **Scoring** | Checklists, critical actions, global ratings |
| **Door card routine** | Name, age, sex; complaint; vitals; task verbs; first three steps |
| **Opening** | Hygiene, name and role, identity, agenda, comfort |
| **Consent** | Nature, material risks, benefits, alternatives, right to stop |
| **SOAP** | Subjective with negatives, objective with named tests, assessment, plan with referral |

## Worked cases

**CASE 1.1 · PLANTED VITAL SIGNS**

A door card for shoulder pain lists BP 182/112. What changes?

**STEP 1 · RECHECK**

Correct cuff, arm at heart level, seated and rested.

**STEP 2 · SCREEN**

Headache, chest pain, dyspnea, visual change, confusion, weakness.

**STEP 3 · PLAN**

Same day medical referral if confirmed without symptoms, emergency referral if target organ symptoms; defer spinal manipulation.

**TRAPS PEOPLE FALL INTO**

- **Doing an untasked skill.** It earns nothing and costs time.
- **Silent results.** The observer has nothing to mark.
- **Leading questions.** They invite a reflexive no.
- **Repeating a painful test.** Stop and note it instead.

## Chapter 1 self-test · six items

### 1. What is the main purpose of the door card in a practical station?

A. It states the patient details and the task that will be scored
B. It lists the exact checklist items the examiner will use
C. It gives the diagnosis that the candidate should confirm
D. It replaces the need to ask the patient for any identification in the room

**A. It states the patient details and the task that will be scored** The door card tells you who the patient is and what you must do. Its verbs point to the checklist, but it does not list the items.

### 2. Which behavior is most likely to be treated as a critical action?

A. Sitting at eye level while taking the patient history
B. Using the patient's preferred name during the encounter
C. Screening for contraindications before any manipulation
D. Finishing every orthopedic test before the time warning

**C. Screening for contraindications before any manipulation** Safety screening, red flags, referral, consent, modesty and stopping on pain are the classic critical actions.

### 3. Why should pertinent negatives be stated aloud?

A. They shorten the station by replacing the positive findings in the report
B. They show that dangerous causes were looked for and found absent
C. They let the candidate skip the neurologic screening tests
D. They are required only when the door card asks for a note

**B. They show that dangerous causes were looked for and found absent** "No saddle anesthesia reported" shows the examiner you screened for cauda equina. Pertinent negatives often sit on the checklist.

### 4. A patient says "wait" midway through a side posture set up. What is the correct response?

A. Finish the set up quickly and then ask the question
B. Hold the preload while you reassure the patient
C. Ask the examiner whether the station may continue
D. Stop, release the contact and ask what is wrong

**D. Stop, release the contact and ask what is wrong** Consent can be withdrawn at any moment. Stop and release first, then reassess.

### 5. What is the best way to spend most practical exam study hours?

A. Performing stations aloud with a partner, a timer and a checklist
B. Rereading the textbook chapters again and again until the details are memorized
C. Watching recorded sample stations without rehearsing them
D. Writing summary notes of every orthopedic test in the course

**A. Performing stations aloud with a partner, a timer and a checklist** Retrieval under pressure and smooth motor performance come from rehearsal with feedback. Reading repairs gaps found in rehearsal.

**6. A door card asks for a demonstration of a set up only. Which sensitive examination may be done in the station?**

A. A brief breast examination if the case history suggests it
B. None; state that you would perform it with consent and a chaperone, or refer
C. A rectal examination if cauda equina is a real concern in the case on the door card
D. Any examination the standardized patient verbally agrees to

**B. None; state that you would perform it with consent and a chaperone, or refer** Rectal, genital and breast examinations are never performed in a station. You state what you would do, or refer.

CHAPTER 2

# Reading Films Under Time: Approach and Normal Anatomy

Read it in full: **Chapter 2 in the textbook**. Practice it: **the practice exams** and **the flashcards**.

## What to know

Run every film the same way: label check (name, age, date, view, marker, quality), a global look, then ABCS (alignment, bone, cartilage, soft tissue) and the review areas and edges. Finish the pattern after the first finding to beat satisfaction of search, and count pedicles on AP lumbar films.

On the lateral cervical film, four smooth lines (anterior vertebral, George's, spinolaminar, posterior spinous); ADI 3 mm or less in adults, up to 5 mm in children; prevertebral tissue about 7 mm at C2 and 22 mm at C6. Know the mimics: Mach band, subdental synchondrosis, ossiculum terminale, pseudosubluxation, limbus vertebra, Schmorl nodes, Hahn clefts and transitional segments. Os odontoideum is not a variant. On the AP hip, Shenton is smooth, Klein cuts the epiphysis and the acetabulum stays lateral to Kohler.

Chest films: PA erect, no rotation, 9 to 10 posterior ribs, cardiothoracic ratio under 0.5 on PA only. The silhouette sign localizes disease. Describe lesions by location, zone of transition, matrix and periosteal reaction, give a one line impression and recommend imaging, referral urgency and whether the region can be manipulated.

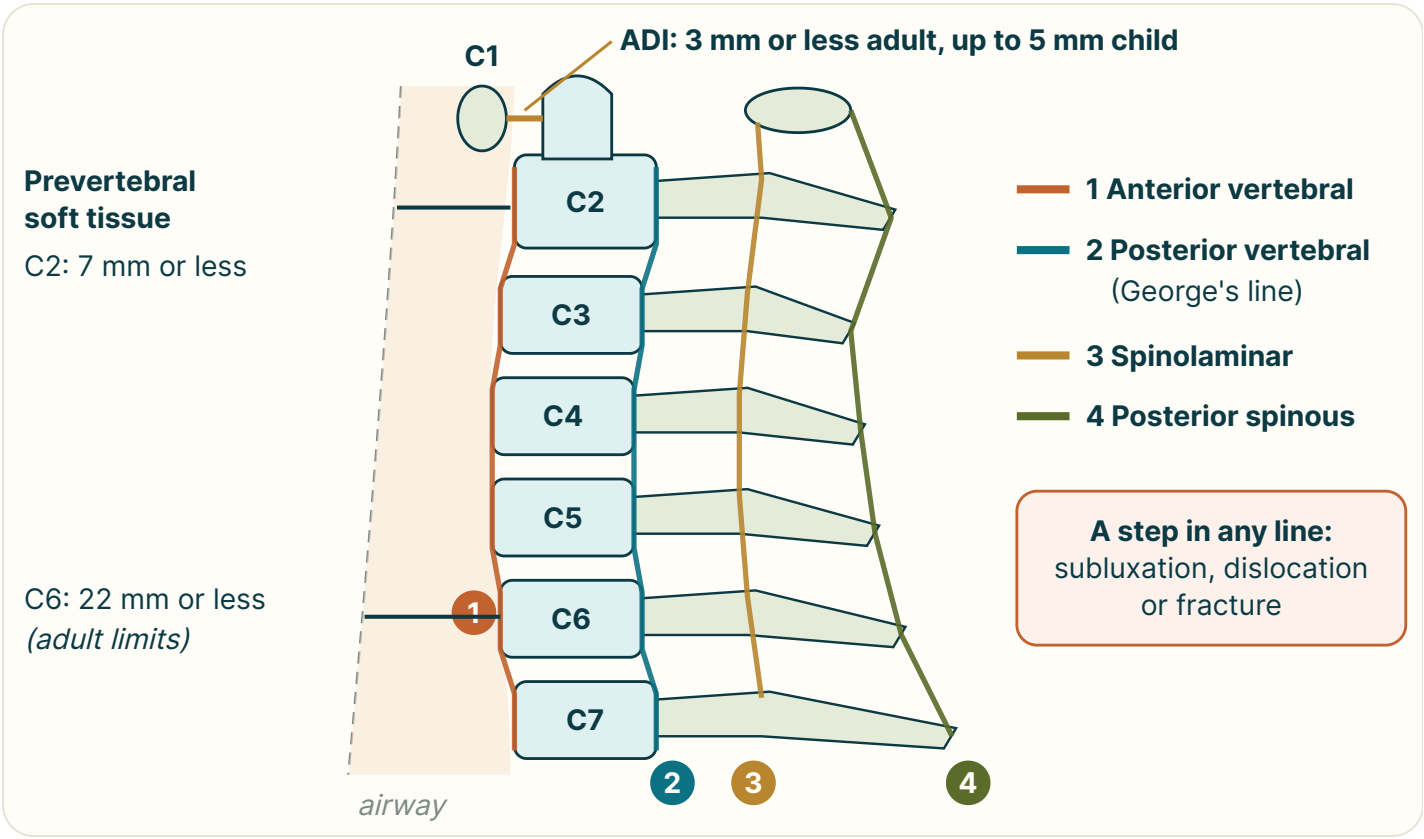


**Lines and spaces on the lateral cervical film.** Trace four smooth curves on every lateral cervical film and check the two spaces most often tested. A step in any line suggests subluxation, dislocation or fracture.

**LOCK THESE IN**

- Label, global look, ABCS, review areas.
- ADI 3 mm adult, 5 mm child.
- Prevertebral 7 mm at C2, 22 mm at C6.
- Pseudosubluxation: C2 spinous within about 2 mm of the line.
- CT ratio under 0.5 on a PA film only.
- Wide zone of transition means aggressive.

## Chapter 2 essentials

| Item | Key point |
|---|---|
| **Search** | Label, global look, ABCS, review areas, edges |
| **Lateral cervical** | Four lines; ADI; prevertebral tissue |
| **Mimics** | Mach band, synchondrosis, ossiculum terminale, limbus, Schmorl, Hahn clefts |
| **Hip lines** | Shenton, Klein, Kohler |
| **Elbow** | CRITOE; anterior humeral line through middle third of capitellum |
| **Chest** | Rotation, inspiration, penetration; CT ratio under 0.5 on PA |
| **Recommendation** | Imaging, referral urgency, safety of manipulation |

## Worked cases

CASE 2.1 · APEX ON A SPINE FILM

A 61 year old former smoker has 2 months of right shoulder and arm pain and a droopy right eyelid. The AP cervicothoracic film shows mild uncovertebral change.

STEP 1 · KEEP SEARCHING

The right lung apex shows a soft tissue density with destruction of the posterior second rib.

STEP 2 · LINK THE HISTORY

Ptosis is part of Horner syndrome; with arm pain and smoking, think superior sulcus (Pancoast) tumor.

STEP 3 · RECOMMEND

Urgent medical referral with chest CT; no manipulation of the cervicothoracic region or ribs.

TRAPS PEOPLE FALL INTO

- **Searching only the named region.** Review areas hide the finding.
- **Cardiomegaly on an AP film.** The heart is magnified.
- **A child's normal lucencies.** Use comparison views when unsure.
- **Naming before describing.** Describe first.

## Chapter 2 self-test · six items

### 1. What is the first step of the film reading routine?

A. The label check of name, age, date, view and marker
B. The alignment pass along the contour lines
C. The review areas at the edges of the film
D. The one line impression of the main finding on the film

**A. The label check of name, age, date, view and marker** The label check comes first. Age shapes the differential more than any other single fact.

### 2. A 70 year old's AP lumbar film shows one pedicle missing at L2. What is the leading concern?

A. Multiple myeloma
B. Metastasis
C. A normal variant
D. Spina bifida occulta

**B. Metastasis** A unilateral missing pedicle in an older adult is metastasis until proven otherwise. Myeloma tends to spare the pedicle early.

### 3. On the AP pelvis, the acetabular floor crosses medial to Kohler's line. What is the finding?

A. Slipped capital epiphysis
B. A femoral neck fracture
C. Acetabular dysplasia
D. Protrusio acetabuli

**D. Protrusio acetabuli** Kohler's (ilioischial) line marks the medial limit. A floor medial to it is protrusio acetabuli.

### 4. After an elbow injury, a posterior fat pad is visible on a true lateral. What does this indicate?

A. A normal finding in children under ten
B. Early ossification of the medial epicondyle
C. A joint effusion and likely occult fracture
D. A dislocated radial head on that view

**C. A joint effusion and likely occult fracture** A visible posterior fat pad, or a raised anterior sail sign, means effusion and, after trauma, occult fracture.

### 5. Which periosteal reaction suggests the slowest process?

A. Lamellated onion skin layers
B. Spiculated sunburst pattern
C. Solid, thick and uninterrupted
D. A Codman triangle at the lesion edge

**C. Solid, thick and uninterrupted** Solid reaction means the bone had time to respond. Interrupted patterns signal aggressive growth.

### 6. Which three questions should every film recommendation answer?

A. Patient age, film quality and the side marker on the view
B. More imaging, referral urgency and safety of manipulation
C. Alignment, bone density and the disc space heights
D. Diagnosis, prognosis and the expected length of care

**B. More imaging, referral urgency and safety of manipulation** A safe recommendation covers further imaging or tests, whether and how urgently to refer, and whether the region may be manipulated.

# High Yield Films I: Trauma

Read it in full: **Chapter 3 in the textbook**. Practice it: **the practice exams** and **the flashcards**.

## What to know

Read the lateral cervical film to the top of T1, trace the four lines, check the ADI and prevertebral tissue. Unstable injuries: Jefferson with over 7 mm overhang, odontoid types II and III, hangman, flexion teardrop, bilateral facet dislocation (50% or more slip) and transverse ligament failure. A unilateral facet dislocation shows about 25% slip and a bow tie. Never order stress films with a fracture, deficit or altered alertness.

In the thoracolumbar spine, count the Denis columns. A straight posterior wall means wedge; a convex or broken wall, retropulsion or widened pedicles means burst and CT; a horizontal line through all three columns means Chance. Pathologic fractures show destroyed pedicles and a convex wall. Spondylolysis is the collar on the Scotty dog; Meyerding grades by quarters. Isthmic slips widen the canal, degenerative slips narrow it.

Hip and scaphoid fractures can be invisible at first, so protect and image further. SCFE means non weight bearing and same day referral. Every trauma answer ends with the decision: no manipulation of the region, protect, check neurologic status, refer at the right speed, document.

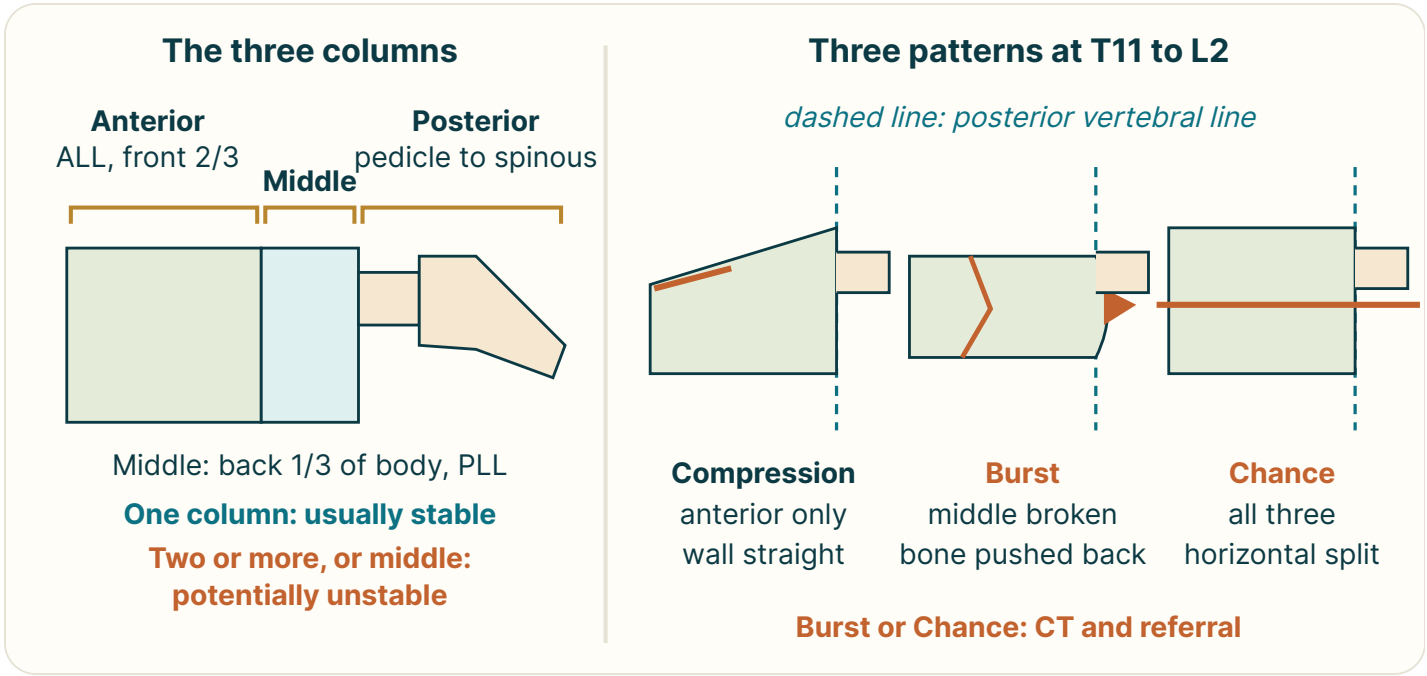


**Count the columns.** A compression fracture breaks the anterior column only. A burst fracture breaks the middle column and pushes bone back toward the canal. A Chance fracture splits all three columns horizontally.

**LOCK THESE IN**

- Film to T1 or it is not adequate.
- Bow tie and 25%: unilateral; 50%: bilateral.
- Posterior wall decides wedge versus burst.
- Meyerding I to V by quarters.
- Occult hip and scaphoid fractures need MRI or repeat films.
- EMS for unstable injuries or any deficit.

## Chapter 3 essentials

| Item | Key point |
|---|---|
| **Rule of Spence** | Combined C1 overhang over 7 mm |
| **Odontoid** | Type II most common, poor union |
| **Three columns** | Middle column injury is potentially unstable |
| **Meyerding** | I 25, II 50, III 75, IV 100%, V beyond |
| **Canadian C spine** | High risk: 65+, dangerous mechanism, paresthesias |
| **Ottawa foot** | Fifth metatarsal base or navicular tenderness |
| **Absolute contraindications** | Fracture, instability, dislocation, pathologic bone, high grade slip |

## Worked cases

**CASE 3.1 · A CURB AND A FIFTH METATARSAL**

A 30 year old rolled her ankle and is tender at the fifth metatarsal base. Films show a transverse lucency about 2 cm distal to the tuberosity.

**STEP 1 · JUSTIFY THE FILM**

The Ottawa foot rule is positive.

**STEP 2 · NAME IT**

Jones fracture at the metaphyseal diaphyseal junction.

**STEP 3 · PLAN**

Non weight bearing with crutches, protective boot, no foot manipulation, orthopedic referral within a few days, neurovascular check documented.

**TRAPS PEOPLE FALL INTO**

- **Stress films too early.** Exclude fracture and deficit first.
- **Normal neuro means stable.** Not in a hangman fracture.
- **Wedge versus burst.** Look at the posterior wall.

- **Letting a high risk patient drive.** Arrange EMS.

## Chapter 3 self-test · six items

### 1. A hyperextension injury pulls a small triangular fragment from the anteroinferior corner of C2. Which statement fits?

A. It is a flexion teardrop with the body driven back into the canal
B. It is a clay shoveler fracture of the spinous process at that same level
C. It is an extension teardrop, stable in flexion and unstable in extension
D. It is a hangman fracture through both pars of the C2 vertebra

**C. It is an extension teardrop, stable in flexion and unstable in extension** The extension teardrop is an anterior longitudinal ligament avulsion with intact posterior structures.

### 2. An alert patient after a car crash has no midline tenderness, no deficit, no intoxication and no distracting injury. Under NEXUS, what follows?

A. CT is still required because of the mechanism
B. Flexion and extension films should be taken first
C. An open mouth view alone should be taken
D. The neck can be cleared without imaging

**D. The neck can be cleared without imaging** When all five NEXUS criteria are absent in an alert patient, the cervical spine can be cleared clinically.

### 3. A Chance fracture is found at L2 after a crash with a lap belt. Which associated injury must be considered?

A. Calcaneal fracture
B. Bowel or mesenteric injury
C. Scaphoid fracture
D. Cervical rib fracture on the left

**B. Bowel or mesenteric injury** Lap belt flexion distraction injuries travel with abdominal visceral injury. Burst fractures from falls travel with calcaneal fractures.

### 4. The oblique lumbar film shows a dark collar around the Scotty dog's neck at L5. What is it?

A. A pars defect
B. A pedicle fracture
C. A facet dislocation
D. A transverse process fracture

**A. A pars defect** The neck of the Scotty dog is the pars interarticularis; the collar is spondylolysis.

### 5. An overweight 13 year old has knee pain and a limp, and Klein's line misses the left epiphysis. What is the plan?

A. Knee films and a trial of conservative care
B. Hip mobilization to restore the lost internal rotation
C. Non weight bearing and same day orthopedic referral
D. Repeat pelvis films in two weeks to confirm

**C. Non weight bearing and same day orthopedic referral** SCFE needs urgent pinning; further slip risks AVN of the femoral head.

**6. Which hip fracture carries the highest risk of avascular necrosis?**

A. An intertrochanteric fracture
B. A subtrochanteric fracture
C. A greater trochanter avulsion from a fall
D. A displaced subcapital femoral neck fracture

**D. A displaced subcapital femoral neck fracture** Intracapsular fractures can tear the retinacular vessels, especially displaced Garden III and IV. Extracapsular fractures rarely cause AVN.

CHAPTER 4

# High Yield Films II: Arthritides, Tumors, Infection, Metabolic Disease and Soft Tissue

Read it in full: **Chapter 4 in the textbook**. Practice it: **the practice exams** and **the flashcards**.

## What to know

Describe arthritis by alignment, bone density, cartilage space, distribution and soft tissue, plus erosions and new bone. OA narrows unevenly; RA narrows evenly with marginal erosions and threatens C1 to C2; AS starts at the SI joints and builds thin syndesmophytes; DISH flows over four or more levels with discs preserved; gout punches out bone beside a preserved joint; CPPD calcifies cartilage. Fused AS and DISH spines fracture easily.

Know anomalies so you never call them fractures: block vertebra (wasp waist), hemivertebra, butterfly vertebra, transitional segment, spina bifida occulta, occipitalization. Scoliosis is Cobb 10 degrees or more; Risser grades maturity; refer by angle and growth left, and get MRI for atypical curves.

Decide aggressive or not, then age, location and matrix. Missing pedicle means metastasis; myeloma spares the pedicle early and is cold on bone scan. Infection destroys the disc; tumor

spares it. Finish with the soft tissues: aorta 3 cm or more is an aneurysm, apical mass with arm pain is Pancoast until proven otherwise.

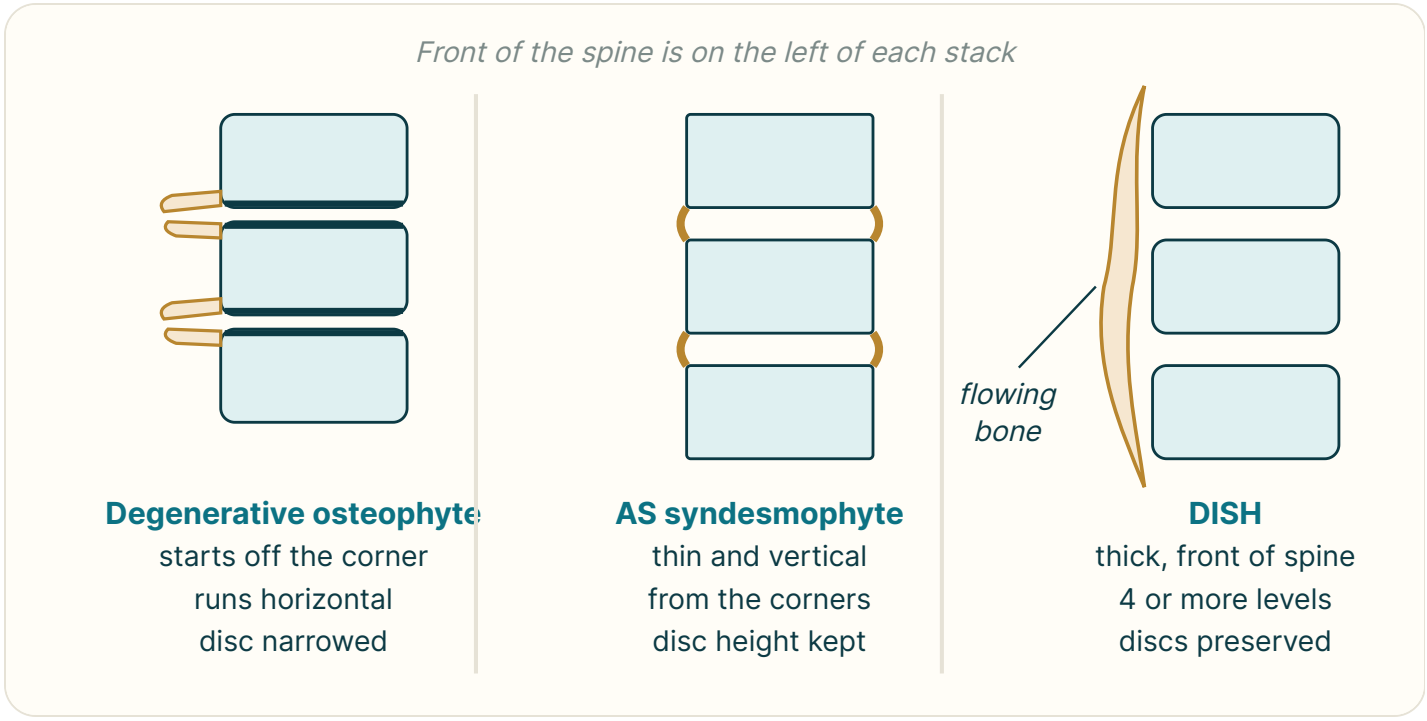


**Osteophyte, syndesmophyte or DISH.** Degenerative osteophytes start off the corner and run horizontally; syndesmophytes of ankylosing spondylitis are thin, vertical and marginal; DISH lays thick flowing bone along the front of four or more levels with the discs preserved.

**LOCK THESE IN**

- RA neck instability forbids cervical manipulation.
- Fused spine plus fall means CT.
- Cobb 10 degrees defines scoliosis.
- Winking owl means metastasis.
- Infection eats the disc.
- Aorta 3 cm or more is an aneurysm.

## Chapter 4 essentials

| Item | Key point |
|---|---|
| Gout | Punched out, overhanging edge, joint preserved |
| AS | SI joints first, bamboo spine |
| Bracing range | 25 to 40 degrees, Risser 0 to 2 |
| Ivory vertebra | Blastic metastasis, Hodgkin, Paget (Paget enlarges) |
| Shapes | H vertebra sickle cell; picture frame Paget; rugger jersey renal |
| Pneumothorax | Pleural line, no markings beyond it |

## Worked cases

CASE 4.1 · A PULLED RIB THAT IS NOT

A tall 24 year old man has sudden right chest pain and mild breathlessness after lifting. The thoracic film shows a thin pleural line 2 cm inside the right chest wall with no markings beyond it.

STEP 1 · LOOK BEYOND THE SPINE

No rib fracture; the pleural line has no lung markings lateral to it.

STEP 2 · IMPRESSION

Right spontaneous pneumothorax.

STEP 3 · ACT

No thoracic manipulation; check vitals; send to the emergency department now; 911 if breathlessness worsens, pressure falls or the trachea shifts.

TRAPS PEOPLE FALL INTO

- **Wasp waist called a fracture.** It is a block vertebra.
- **Normal film excludes tumor.** Not until 30 to 50% bone loss.
- **Vacuum gas in infection.** Gas effectively excludes it.
- **Stopping at the bones.** Sweep the soft tissues.

## Chapter 4 self-test · six items

### 1. Which spinal change is typical of ankylosing spondylitis?

A. Horizontal osteophytes starting off the corners
B. Flowing anterior bone with normal SI joints
C. Bulky, asymmetric, nonmarginal new bone
D. Thin marginal syndesmophytes bridging the discs

**D. Thin marginal syndesmophytes bridging the discs** AS syndesmophytes are thin, vertical and marginal, building a bamboo spine after squaring and Romanus lesions.

### 2. Where does CPPD most typically show chondrocalcinosis?

A. Knee menisci, wrist TFCC and the pubic symphysis
B. First MTP joint and the olecranon bursa
C. DIP joints of the hands with pencil in cup changes
D. SI joints with bilateral symmetric fusion

**A. Knee menisci, wrist TFCC and the pubic symphysis** CPPD calcifies fibrocartilage and hyaline cartilage, classically the knee menisci, the TFCC and the symphysis.

### 3. What does the Risser sign measure?

A. Rotation of the apical vertebra in the curve
B. The size of the Cobb angle
C. Ossification of the iliac crest apophysis
D. Leg length on a standing film

**C. Ossification of the iliac crest apophysis** Risser grades 0 to 5 as the apophysis ossifies from ASIS to PSIS and fuses, marking remaining growth.

### 4. A dense vertebra is larger than its neighbors, with a thick cortical frame. What is the likely cause?

A. Blastic metastasis
B. Paget disease
C. Hodgkin lymphoma
D. Renal osteodystrophy

**B. Paget disease** Of the ivory vertebra causes, only Paget enlarges the bone, giving a picture frame appearance.

### 5. Which plan fits suspected pyogenic discitis in a patient with diabetes?

A. Low force care and repeat lateral lumbar films in three weeks' time
B. Flexion distraction to reduce pressure on the disc
C. Reassurance, since disc narrowing is degenerative
D. No manipulation; same day MRI, ESR, CRP, CBC and blood cultures

**D. No manipulation; same day MRI, ESR, CRP, CBC and blood cultures** Films lag the disease, so MRI and labs come first. Fever with deficit raises concern for epidural abscess, an emergency.

### 6. A smoker has shoulder and arm pain and ptosis. Where should you look on the cervical film?

A. The lung apex
B. The dens
C. The facet joints
D. The prevertebral space at C6

**A. The lung apex** A Pancoast tumor at the apex mimics cervical radiculopathy and can cause Horner syndrome.

# The History in a Standardized Patient Encounter

Read it in full: **Chapter 5 in the textbook**. Practice it: **the practice exams** and **the flashcards**.

## What to know

Read the door card for who, what, task and data, and build three to five hypotheses with one must not miss. Open with hand hygiene, name and role, two identifiers stated by the patient, preferred name, comfort, consent and the agenda question. Start open, listen, then funnel through OPQRST with associated symptoms, discriminating questions and closed red flags.

Ask neutrally and one item at a time; closed is fine, leading and stacked are not. Chase every cue. Touch seven red flag families every time: cancer, infection, fracture, cauda equina and cord, vascular, visceral and medications. Cauda equina questions belong in every lumbar or leg case. Neck and headache cases add the 5 D's and 3 N's and SNOOP.

Keep the past, family, social and occupational history brief, and ask what the patient thinks and hopes. Summarize key positives and red flag negatives aloud, check accuracy, then explain the exam and get consent. An emergency in the history means referral, not testing.

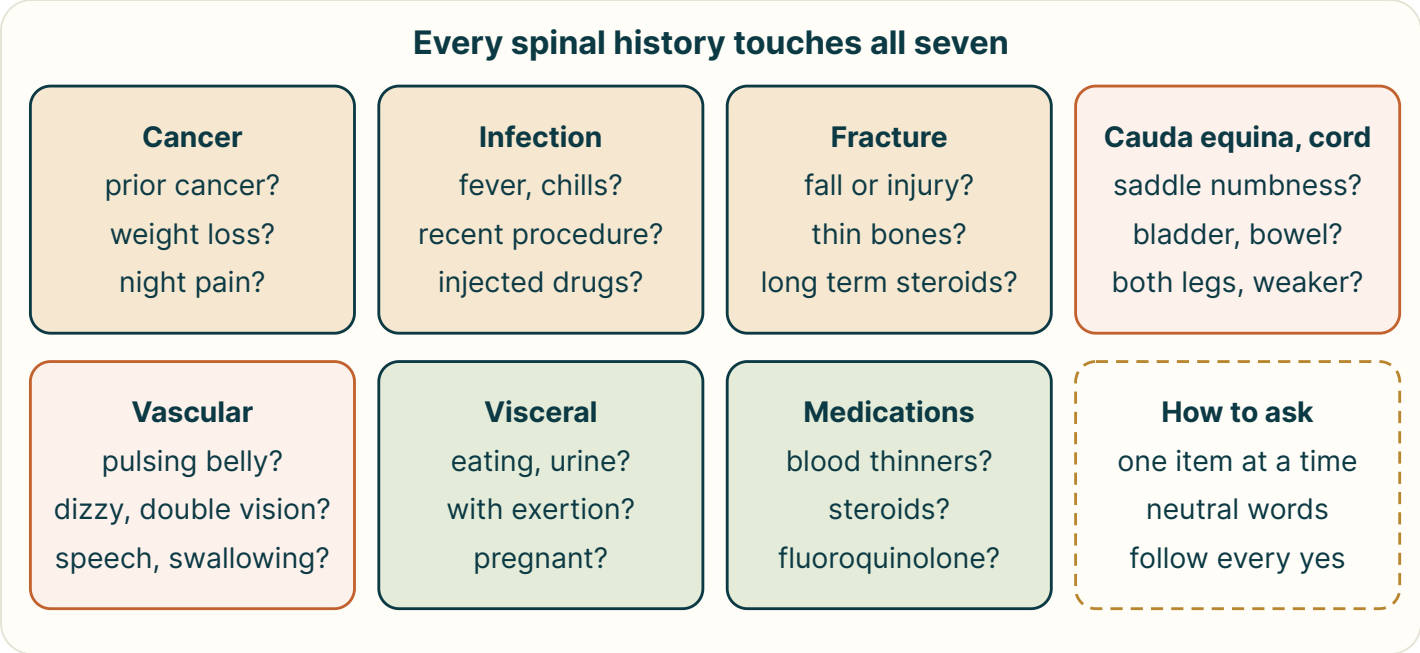


**Seven families in every spinal history.** Touch every family, even briefly. Age, sex and the story decide which family gets the deepest questioning, and any yes is followed up before you move on.

**LOCK THESE IN**

- Two identifiers, agenda question.
- Open, then funnel.
- Neutral, single item red flags.
- Seven families every spinal case.
- Negatives aloud in the summary.
- Emergency history means referral.

## Chapter 5 essentials

| Item | Key point |
|---|---|
| Door card | Who, what, task, data |
| Funnel | Open, OPQRST plus associated, discriminating, closed |
| Cauda equina | Saddle, bladder, bowel, sexual, both legs, weakness |
| Dissection | 5 D's and 3 N's, plus ataxia |
| SNOOP | Systemic, neurological, onset sudden, older, pattern change |
| Flags | Yellow psychological, blue work, black system, orange psychiatric |

## Worked cases

**CASE 5.1 · INFLAMMATORY BACK PAIN IN A YOUNG MAN**

Dorian, 27, has six months of low back stiffness lasting an hour each morning, better with a shower and exercise, waking him late at night.

**STEP 1 · NAME THE PROFILE**

Inflammatory back pain.

**STEP 2 · USE THE PFSH**

A past red, painful eye (uveitis), a swollen Achilles (enthesitis), and a father with a stiff back and psoriasis.

**STEP 3 · PLAN**

Ask about bowel symptoms, then examine chest expansion, Schober and the SI joints, and explain likely blood work, imaging and rheumatology co management.

**TRAPS PEOPLE FALL INTO**

- **Stacked questions.** The patient answers only the last item.
- **Leading phrasing.** It corrupts the data.
- **Silent negatives.** Say them in the summary.
- **Ignored cues.** They are scripted on purpose.

## Chapter 5 self-test · six items

### 1. What is the safest way to confirm a patient's identity?

A. Read the name aloud and then wait for a nod
B. Check the door card before you knock
C. Ask the patient to state two identifiers
D. Ask only for the patient's first name

**C. Ask the patient to state two identifiers** Two identifiers, usually full name and date of birth, stated by the patient, is the safer habit.

### 2. Why let the patient finish the opening statement?

A. Interrupting early makes the history longer
B. It is required before any red flag question
C. It replaces the need for OPQRST questions
D. It gives time to plan the examination tests

**A. Interrupting early makes the history longer** Uninterrupted openings usually take well under two minutes and volunteer much of the history.

### 3. A man with leg pain on walking needs to sit or lean forward on a cart for relief. What does this suggest?

A. Vascular claudication
B. Neurogenic claudication
C. Hip osteoarthritis
D. Peripheral neuropathy only

**B. Neurogenic claudication** Neurogenic claudication needs flexion or sitting and is often easier walking uphill or leaning on a cart.

### 4. Which question is part of the medication family of the red flag screen?

A. "Have you lost weight without trying?"
B. "Do you take any blood thinners?"
C. "Any fever, chills or sweats lately?"
D. "Is the pain worse after you eat?"

**B. "Do you take any blood thinners?"** Ask high yield drug classes by name; anticoagulants change force, technique and the imaging threshold.

### 5. What should the history summary include besides key positives?

A. Red flag negatives, the patient's concerns, and an accuracy check
B. A full list of every answer given, read back in order
C. The final diagnosis and the full treatment plan for the visit today
D. The examiner's checklist items and the time remaining

**A. Red flag negatives, the patient's concerns, and an accuracy check** A short summary of positives, cleared red flags and concerns, then "Did I get that right?", proves the data and invites correction.

**6. A patient discloses thoughts of harming herself during the social history. What is the correct response?**

A. Note it in the chart and then continue with the planned physical exam
B. Change the subject gently back to the back complaint
C. Advise her to mention it at her next doctor's visit
D. Respond with empathy and ask directly about intent, plan and safety

---

**D. Respond with empathy and ask directly about intent, plan and safety** A disclosure of suicidal thoughts is a safety emergency, scored like a cauda equina finding.

CHAPTER 6

# Performing the Examination in a Station

Read it in full: **Chapter 6 in the textbook**. Practice it: **the practice exams** and **the flashcards**.

## What to know

Measure blood pressure with the right cuff, the arm at heart level, a palpated estimate first and deflation at 2 to 3 mmHg per second; read phases I and V. Small cuffs and low arms read high. Over 180/120 means no manual care that day, and emergency services if symptoms. Count an irregular pulse for a full minute.

Every test is explain, position, perform, ask, state. Positive means the patient's own symptom in the expected place. Use clusters: Wainner for cervical radiculopathy, Laslett for the SI joint. SLR is sensitive, crossed SLR specific; Lachman is sensitive, pivot shift specific. Never use a negative vertebral artery test as clearance.

Screen each root with a dermatome, myotome and reflex. Biceps C5, brachioradialis C6, triceps C7, patellar L4, Achilles S1; L5 has none reliable. UMN signs are hyperreflexia, clonus, Babinski and Hoffmann. Romberg tests proprioception. Choose tests from hypotheses and group them by position.

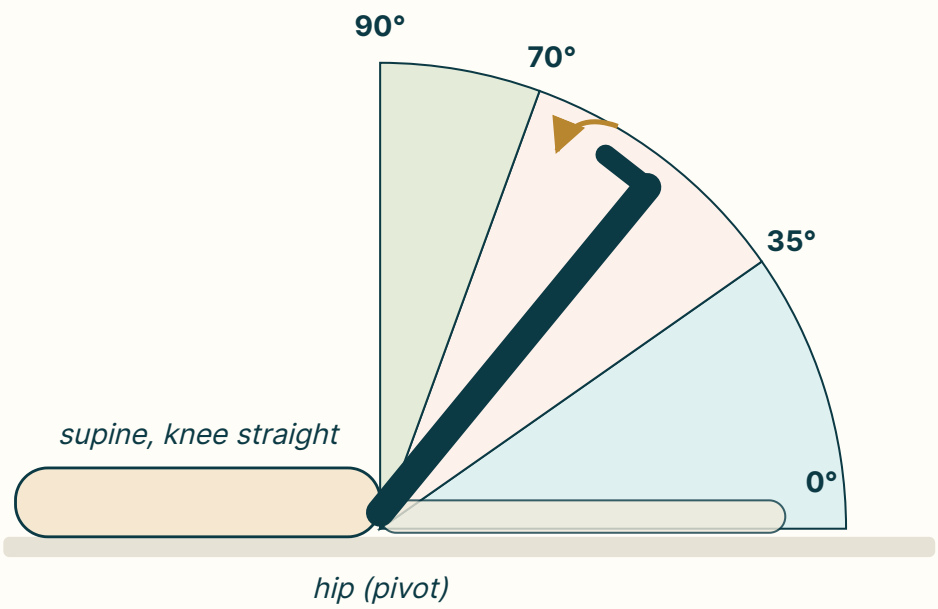


### Read the zone

**0 to 35°**
takes up slack

**35 to 70°**
L5 and S1 root tension: radiating pain below the knee is positive

**over 70°**
hamstring, SI joint or lumbar joints

**Braggard:**
lower until pain eases, then dorsiflex the foot

**Where the straight leg raise is read.** Radiating pain below the knee between about 35 and 70 degrees suggests L5 or S1 root tension. Local back pain or hamstring tightness is not a positive radicular test.

**LOCK THESE IN**

- Palpate before you auscultate.
- Over 180/120: no treatment that day.
- Positive is the patient's own symptom.
- Clusters beat single tests.
- L5 has no reliable reflex.
- SnNout and SpPin.

## Chapter 6 essentials

| Item | Key point |
|---|---|
| **BP deflation** | 2 to 3 mmHg per second |
| **Orthostatic** | Fall of 20 systolic or 10 diastolic within 3 minutes |
| **Wainner** | ULTT A, Spurling, distraction, rotation under 60 degrees |
| **Laslett** | 3 or more of 5 SI provocation tests |
| **Ottawa knee** | 55+, patella, fibular head, flex under 90, four steps |
| **Position order** | Standing, seated, supine, side lying, prone |

## Worked cases

**CASE 6.1 · SIX WEEKS OF BUTTOCK PAIN**

Lorraine, 47, has right buttock pain into the back of the thigh. SLR to 80 degrees gives only hamstring tightness, slump is negative, reflexes and strength are normal, FABER gives posterior pain, and four of five SI provocation tests are positive.

**STEP 1 · RULE OUT**

A negative sensitive SLR and slump with a normal neuro screen make radiculopathy unlikely.

**STEP 2 · RULE IN**

Four of five Laslett tests positive supports right SI joint pain.

**STEP 3 · STAY SAFE**

Ask about night pain and trauma to address a sacral stress fracture or tumor.

**TRAPS PEOPLE FALL INTO**

- **Arm hanging below the heart.** The reading is falsely high.
- **Distraction pain called positive.** Relief is positive.
- **Romberg as a cerebellar test.** It is proprioception.
- **Unfocused test batteries.** Choose from hypotheses.

## Chapter 6 self-test · six items

### 1. Which reading pattern defines orthostatic hypotension?

A. A rise of 20 systolic or 10 diastolic within about 3 minutes of standing
B. A difference of 10 to 15 mmHg between the two arms at the first visit
C. A systolic reading under 120 with a diastolic reading under 80 seated
D. A fall of 20 systolic or 10 diastolic within about 3 minutes of standing

**D. A fall of 20 systolic or 10 diastolic within about 3 minutes of standing** Orthostatic hypotension is a fall of 20 mmHg systolic or 10 mmHg diastolic within about three minutes of standing.

### 2. Which reflex tests the C6 root?

A. Biceps
B. Triceps
C. Brachioradialis
D. Patellar reflex

**C. Brachioradialis** Biceps is C5, brachioradialis C6, triceps C7, patellar L4 and Achilles S1.

### 3. Which finding is an upper motor neuron sign?

A. An upgoing Babinski response
B. Fasciculations in the calf
C. Early, marked muscle atrophy
D. A reduced Achilles reflex

**A. An upgoing Babinski response** Babinski, Hoffmann, clonus and hyperreflexia point to the brain or spinal cord.

**4. A soccer player has a knee effusion after a pivot and a pop. Which test is the most sensitive office test for an ACL tear?**

A. Pivot shift
B. Lachman
C. McMurray
D. Thompson

**B. Lachman** Lachman is the most sensitive ACL test; the pivot shift is the most specific but hard on a guarding patient.

**5. Which arrangement of tests shows an examiner that the exam was planned?**

A. Testing every region in alphabetical order
B. Grouping tests by position from standing to prone
C. Repeating each test three times on each side
D. Doing the most painful tests first to save the most time

**B. Grouping tests by position from standing to prone** Standing, seated, supine, side lying, prone saves time and reduces discomfort for a patient in pain.

**6. A neck pain patient has a negative positional vertebral artery test. What does this mean for cervical manipulation?**

A. It confirms that manipulation is safe at every single cervical level
B. It means the cranial nerve screen can be skipped today
C. It is not clearance; the history and neurological screen matter more
D. It rules out dissection for the following twelve months

**C. It is not clearance; the history and neurological screen matter more** Positional tests have poor accuracy and do not predict who will have an adverse event.

# Diagnosis, Orders and Management Decisions

Read it in full: **Chapter 7 in the textbook**. Practice it: **the practice exams** and **the flashcards**.

## What to know

State one specific working diagnosis (tissue, level, side, qualifiers) and two to four ranked differentials with a cannot miss condition, each linked to pertinent positives and negatives. A positive test is a finding, not a diagnosis. Decide mechanical versus nonmechanical and let red flags change "treat" into "investigate or refer."

Order only what changes management, with a one sentence reason. Use the Canadian C spine rule, NEXUS and the Ottawa rules for trauma, and red flag clusters for nontraumatic pain. Cauda equina goes straight to the emergency department. Match the modality and lab to the suspected condition.

Choose a lane (treat, co-manage, refer) and give a complete plan: procedures, frequency, measurable goals, outcome measures, home care, re-examination and safety net. Know absolute versus relative contraindications, and match each red flag to one of four urgency levels before you speak.

| Urgency | Typical station triggers |
| --- | --- |
| 1 **Call 911 now** stay with the patient | Stroke or dissection signs, thunderclap headache, cardiac chest pain, shock with mass |
| 2 **Emergency dept** today, same day | Cauda equina signs, unstable fracture, fever with spine pain, arteritis signs |
| 3 **Prompt referral** phone and letter, days | Suspected cancer without deficit, inflammatory arthritis, stable aneurysm on imaging |
| 4 **Routine referral** letter, days to weeks | Failed trial of care, medication needs, stable comorbidity to co-manage |

**Decide the level first, then the words. An emergency patient never drives.**

**Match the response to the threat.** Decide the urgency level before you speak. Under-reacting endangers the patient, and over-reacting to a routine finding wastes resources and frightens people.

**LOCK THESE IN**

- Specific, defensible, safe.
- Every order has a reason.
- Cauda equina skips outpatient ordering.
- Treat, co-manage or refer.
- Functional, measurable, timed goals.
- 911, ED today, prompt, routine.

## Chapter 7 essentials

| Item | Key point |
|---|---|
| Canadian C spine high risk | 65+, dangerous mechanism, paresthesias |
| Radiograph limit | 30 to 50% bone loss before lysis shows |
| EMG timing | Denervation about 3 weeks after onset |
| Trial of care | About 2 weeks; two failed trials, change course |
| BE FAST | Balance, eyes, face, arm, speech, time |
| Absolute contraindication | No thrust in that region |

## Worked cases

**CASE 7.1 · LEG PAIN ON WALKING AT 71**

Helen, 71, has bilateral leg heaviness on walking for 6 months, eased by sitting. Pedal pulses are good.

**STEP 1 · DISCRIMINATE**

Flexion relief, easier uphill and good pulses favor neurogenic claudication; vascular pain eases with standing still.

**STEP 2 · CHECK THE VASCULAR SIDE**

An ankle brachial index of 0.9 or lower would suggest arterial disease.

**STEP 3 · PLAN**

Lumbar stenosis: flexion based exercise, cycling, walking program, low force care, co-management, safety net for bladder change or weakness.

**TRAPS PEOPLE FALL INTO**

- **"Sciatica" as an impression.** Name the root and cause.
- **Imaging without a reason.** Say what would change.
- **Outpatient MRI for cauda equina.** Emergency today.
- **Vague goals.** Make them measurable.

## Chapter 7 self-test · six items

### 1. What makes a differential diagnosis useful in a station?

A. Every condition that could possibly cause the complaint, listed alphabetically
B. A single alternative diagnosis that matches the patient's age group
C. Only the conditions that the examination has fully confirmed today
D. Two to four ranked items, including a cannot miss condition with reasons

**D. Two to four ranked items, including a cannot miss condition with reasons** A short ranked list with a dangerous alternative and the reason it is less likely shows a deliberate safety screen.

### 2. Which imaging test best shows early vertebral infection?

A. Plain radiographs
B. DEXA scanning
C. Diagnostic ultrasound
D. MRI with contrast

**D. MRI with contrast** Radiographs lag the disease; MRI shows marrow and disc changes early, with contrast for infection.

### 3. What should happen after two well run trials of care fail to produce measurable change?

A. Continue the same plan at a higher visit frequency
B. Change the approach, investigate further or refer
C. Discharge the patient without further investigation
D. Add more home exercises and repeat the same trial

**B. Change the approach, investigate further or refer** A failed trial of care is a reason to change course, not to continue.

### 4. A patient becomes dizzy after a cervical adjustment. What comes first?

A. Stop, position safely, and check ABCs, vitals and a neurologic screen
B. Reassure the patient that this is only a normal vasovagal reaction
C. Repeat the adjustment more gently to settle the symptoms
D. Ask the patient to drive home and rest for the afternoon

**A. Stop, position safely, and check ABCs, vitals and a neurologic screen** Any new symptom after care triggers stop, safety, ABCs, vitals and BE FAST. Call 911 for any focal sign.

### 5. Which presentation belongs on the prompt referral rung, not the emergency rungs?

A. Cauda equina signs with new urinary retention
B. Thunderclap headache with neck stiffness
C. Suspected cancer without neurologic compromise
D. Cardiac chest pain with sweating

**C. Suspected cancer without neurologic compromise** Suspected cancer without deficit needs prompt referral within days. The others are same day or 911 emergencies.

### 6. Which statement about EMG and nerve conduction studies is correct?

A. They are the first test for acute low back pain
B. They image the disc and the nerve root directly and clearly
C. Denervation changes may take about 3 weeks to appear
D. They replace the need for a neurologic exam

**C. Denervation changes may take about 3 weeks to appear** EMG and NCS separate radiculopathy from entrapment, but early studies can be falsely normal.

CHAPTER 8

# Documentation, Consent, Communication and Referral

Read it in full: **Chapter 8 in the textbook**. Practice it: **the practice exams** and **the flashcards**.

## What to know

Write SOAP notes that let another clinician continue care: specific, measurable, lateralized findings, named tests, neuro grades, pertinent negatives, a full assessment with differentials, and a plan with frequency, goals, orders with reasons, consent and re-examination. Correct with a single line, date and initials; label late entries.

Consent needs capacity, disclosure, understanding, a voluntary choice and documentation, renewed when the plan changes. Disclose with PARQ under the material risk standard, naming the dissection risk for neck work calmly and accurately. Give the report of findings in plain, non-threatening words and confirm with teach-back.

Match the referral channel to urgency, use SBAR on the phone, and write letters that open with reason and urgency and end with a request. Use SPIKES and NURSE for hard news, document informed refusals, keep boundaries, and use professional interpreters.

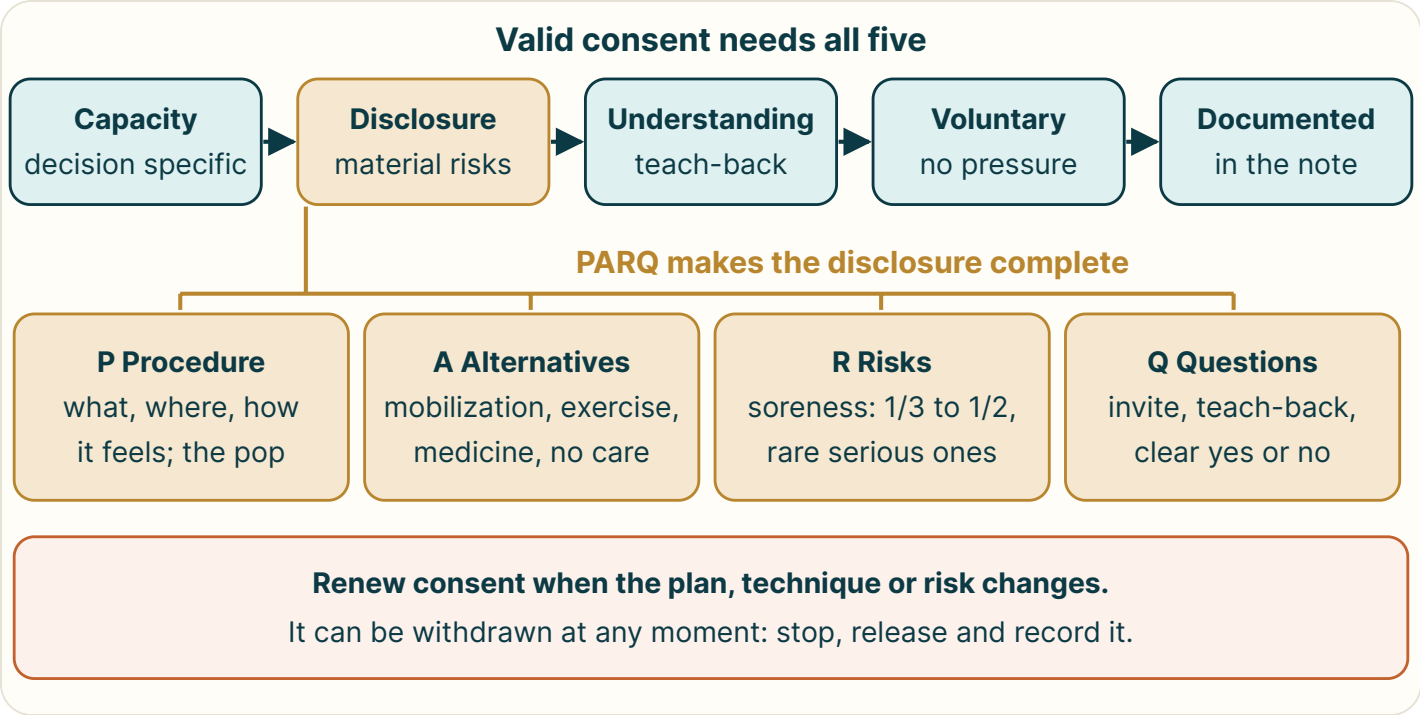


**Five requirements, four disclosure elements.** A signature without capacity, disclosure, understanding and a free choice is not valid consent. PARQ makes the disclosure complete, and consent is renewed when the plan changes.

**LOCK THESE IN**

- Trace every plan item to a finding.
- Single line corrections.
- Five parts of valid consent.
- PARQ, then yes or no.
- Teach-back.
- Phone first when urgent.

## Chapter 8 essentials

| Item | Key point |
|---|---|
| Late entry | Current date and time plus visit date |
| Capacity | Understand, appreciate, reason, communicate |
| Implied consent | True emergencies only, never elective manipulation |
| Benign reactions | 1/3 to 1/2, settle in 24 to 48 hours |
| SBAR | Situation, Background, Assessment, Recommendation |
| NURSE | Name, Understand, Respect, Support, Explore |

## Worked cases

**CASE 8.1 · SUSPECTED METASTASIS CONVERSATION**

Gloria, 61, has 2 months of constant mid back pain, worse at night, 6 kg weight loss and treated breast cancer. T8 is tender; neuro is normal.

**STEP 1 · SET UP**

Sit, face her, ask if she wants anyone present, and ask what she thinks is causing the pain.

**STEP 2 · WARNING SHOT AND KNOWLEDGE**

The night pain, weight loss and cancer history mean the bone must be checked quickly; you do not know that the cancer has returned.

**STEP 3 · EMOTION AND STRATEGY**

Pause and respond with NURSE; call her oncologist today and send a letter for MRI and blood tests; no mid back adjustment; emergency care for new leg weakness, numbness, balance or bladder problems.

**TRAPS PEOPLE FALL INTO**

- **"Neuro WNL."** Grade it by level.
- **Form as consent.** The conversation is the consent.
- **Nocebo language.** It increases fear.
- **"See and treat" letters.** Make a specific request.

## Chapter 8 self-test · six items

### 1. Which section of a written note is most often underwritten in stations?

A. Assessment
B. Subjective
C. Objective
D. Plan

**A. Assessment** Even under time pressure, write the full diagnosis, two differentials and one line on red flags considered.

### 2. When may care proceed under implied consent?

A. Whenever the patient has been treated before
B. For any low risk elective adjustment
C. In a true emergency to prevent serious harm
D. When a family member nods agreement

**C. In a true emergency to prevent serious harm** Implied consent covers emergency care, never elective manipulation.

### 3. Which phrase is an example of nocebo language to avoid?

A. "Your joints are stiff and sore"
B. "Most people improve in weeks"
C. "These are normal age changes"
D. "Your spine is crumbling"

**D. "Your spine is crumbling"** Fear inducing phrases can increase pain, fear avoidance and disability.

### 4. What does the R in SBAR stand for?

A. Recommendation
B. Reason
C. Referral plan
D. Review

**A. Recommendation** SBAR is Situation, Background, Assessment, Recommendation, followed by a read back.

### 5. A patient with suspected cauda equina refuses to go to the hospital and asks for an adjustment. What do you do?

A. Adjust gently as a compromise, then try again to persuade the patient
B. Discharge the patient from care without any further discussion today
C. Treat the low back as requested and record in the chart that the referral was declined
D. Explain the danger, explore barriers, offer to call, document, and do not adjust

**D. Explain the danger, explore barriers, offer to call, document, and do not adjust** Make the refusal informed and never treat through a red flag because a patient insists.

**6. When working with an interpreter, how should you speak?**

A. To the interpreter, in the third person, in full detail
B. To the patient, in the first person, in short sentences
C. To the family member, who then relays it to the patient
D. To the patient, but only in written form for accuracy

---

**B. To the patient, in the first person, in short sentences** Face the patient and say "Where does it hurt?", not "Ask her where it hurts."

CHAPTER 9

# Technique Station Principles and Scoring

Read it in full: **Chapter 9 in the textbook**. Practice it: **the practice exams** and **the flashcards**.

## What to know

State the seven elements in order every time: listing, patient position, doctor stance, contact point, segmental contact, stabilization, line of drive, wrapped in the safety screen and consent before and preload and a spoken thrust after. Read the door card for the listing, the set up that fits, and anything that says do not adjust.

The spinous and body rotate in opposite directions. TP, lamina, pillar and mammillary contacts go on the posterior body side and drive P to A; spinous contacts go on the spinous side and push toward midline. Facet planes set the angle: cervical 45 degrees, thoracic near frontal, lumbar near sagittal. ASRP reads tilt, laterality, rotation of that side.

Position, tissue pull, preload, impulse, resolution; at the station stop at preload. Cavitation is incidental. Screen for absolute and relative contraindications, watch through preload, and stop for any new symptom. Use the rule of threes and two landmarks, and correct errors aloud.

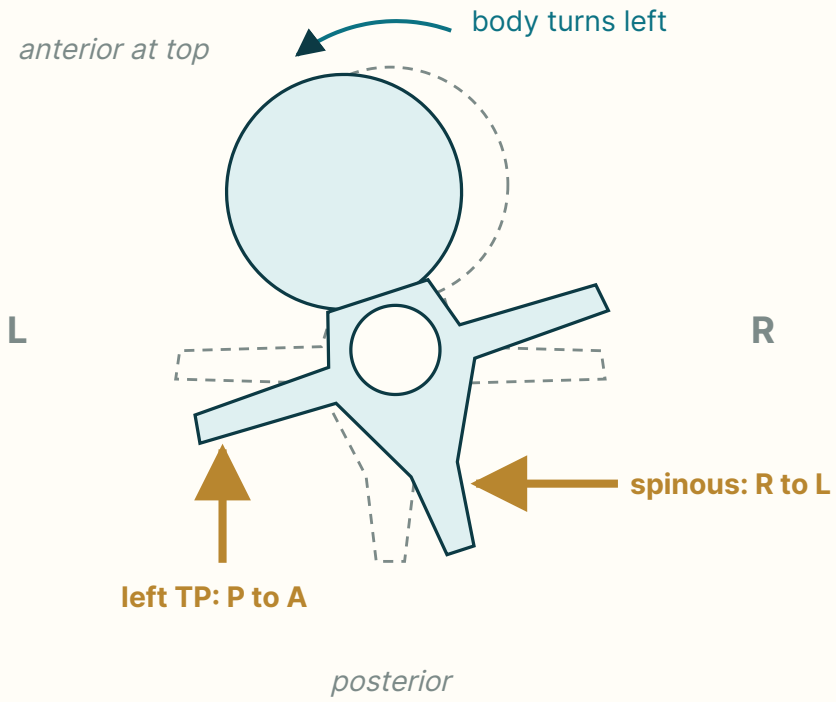


**Three names, one fault**

Gonstead: PR (spinous right)

National: body rotated left

Motion: right rotation restricted

**Correction**

induce right rotation with either contact

**One fault, three names.** When the spinous swings right (PR), the body turns left and the left transverse process becomes posterior. A P to A drive on the left TP, or an R to L push on the spinous, induces the restricted right rotation.

**LOCK THESE IN**

- Seven elements, same order.
- Spinous and body go opposite ways.
- TP contacts on the body side.
- Stop at preload; describe the thrust.
- Rule of threes.
- A safe "no" scores.

## Chapter 9 essentials

| Item | Key point |
|---|---|
| **PR** | Spinous right, body left, right rotation restricted |
| **Spinous contact** | On the spinous side, toward midline |
| **Cervical drive** | P to A, slightly I to S |
| **Thrust phases** | Positioning, tissue pull, preload, impulse, resolution |
| **Refractory period** | About 15 to 20 minutes |
| **Empty end feel** | Stop and evaluate |

## Worked cases

**CASE 9.1 · A TRAP CARD**

A 37 year old has sudden right upper neck pain and an unusual headache since turning to reverse her car, with brief double vision and unsteadiness. Task: set up for C1 right rotation restriction.

**STEP 1 · RECOGNIZE**

Sudden unusual neck pain and headache after minor rotation, with diplopia and unsteadiness, suggests vertebral artery dissection.

**STEP 2 · SCREEN**

Cranial nerves, cerebellar tests, pupils for Horner signs, speech.

**STEP 3 · DECLINE AND REFER**

Say you will not manipulate, explain calmly, arrange emergency evaluation today and document.

**TRAPS PEOPLE FALL INTO**

- **Spinous side TP contact.** The posterior TP is opposite the spinous.
- **End range neck rotation.** Only enough to reach tension.
- **Silent elements.** Say all seven.
- **A real thrust.** Never at the station.

## Chapter 9 self-test · six items

### 1. Which element names the part of the vertebra being contacted?

A. Contact point
B. Stabilization
C. Segmental contact
D. Line of drive used

**C. Segmental contact** The contact point is the part of the doctor's hand; the segmental contact is the part of the patient's vertebra.

### 2. A motion palpation finding reads "L2 left rotation restriction." What is the Gonstead spinous position?

A. Spinous right (PR)
B. Spinous left (PL)
C. Posterior only (P)
D. Anterior body (A)

**B. Spinous left (PL)** Left rotation restricted means the body is held in right rotation, so the spinous has swung left.

### 3. Why does a pisiform contact need an extended wrist?

A. So the contact does not roll off the bone
B. So the elbow can hyperextend for force
C. So the thrust comes from the hand muscles
D. So the table height can be set higher

**A. So the contact does not roll off the bone** A flexed wrist lets the pisiform roll. Force should come from the trunk with elbows slightly flexed.

### 4. Which is an absolute contraindication to HVLA at the region?

A. Os odontoideum for upper cervical work
B. Treated osteopenia in the thoracic spine
C. Pregnancy for lumbar positioning
D. Stable anticoagulation for neck pain

**A. Os odontoideum for upper cervical work** Ligamentous instability such as os odontoideum forbids upper cervical HVLA. The others call for modification.

### 5. How should the thrust be described at a station where it is not delivered?

A. "Then I would push down firmly on the segment as hard as I possibly can"
B. "Now I would adjust it until I hear the joint make a pop"
C. "I would thrust in whatever direction the joint feels stiff"
D. "A high velocity, low amplitude thrust, P to A and slightly I to S"

**D. "A high velocity, low amplitude thrust, P to A and slightly I to S"** Name the thrust type and its direction in anatomical terms after taking the joint to tension.

### 6. You realize mid station that your contact is on the wrong side. What is the best response?

A. Continue, since the examiner may not notice
B. Move it and explain the correction aloud
C. Restart the whole station from the door
D. Move it quietly without saying anything

**B. Move it and explain the correction aloud** Examiners can credit a corrected, explained decision. A silent correction is invisible.

# Cervical and Thoracic Set Ups

Read it in full: **Chapter 10 in the textbook**. Practice it: **the practice exams** and **the flashcards**.

## What to know

Upper cervical work uses minimal rotation, no end range and never rotation with extension, after screening for instability and dissection. ASRP means contact the right side of the atlas: L to M for laterality and P to A for rotation, toward the opposite eye.

In the lower neck, contact the articular pillar, never the TP. Rotary set ups contact the posterior body side and drive P to A and slightly I to S toward the opposite eye; lateral flexion set ups contact the side to flex and drive L to M. Lock above with opposite coupling. At the junction, confirm C7 and T1 with two tests and use the thumb move with the head laterally flexed toward the contact.

In the thoracic spine, bilateral TP contacts induce extension, crossed bilateral, unilateral TP and spinous push contacts induce rotation, and the supine anterior thoracic set up induces flexion with the fulcrum under the lower vertebra. Rib angles sit lateral to the TP; the first rib is driven S to I toward the opposite hip. Rule out cardiac, pulmonary, fracture and malignant causes first.

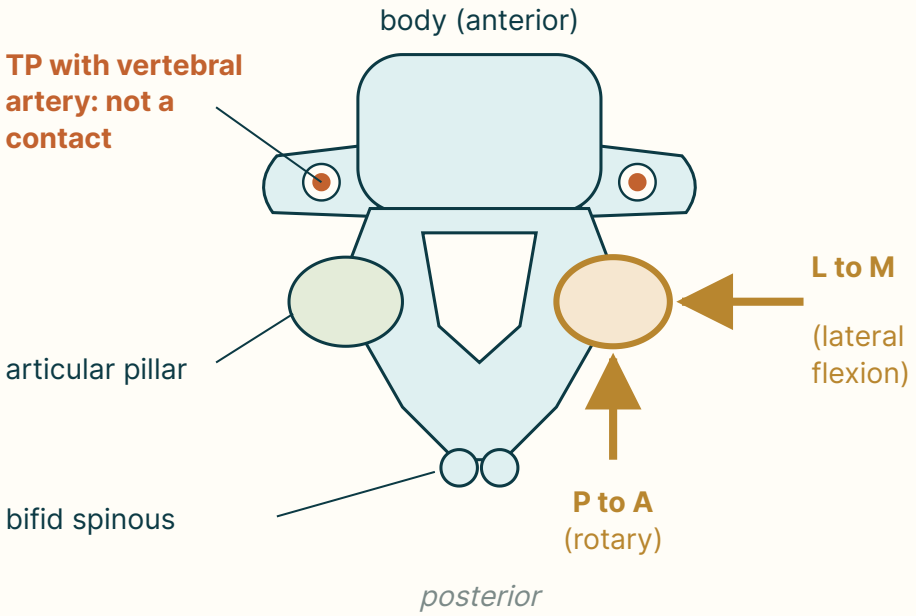


**Rotary**
pillar on posterior body side; toward the opposite eye

**Lateral flexion**
pillar on the side to flex; head bent over contact; L to M

**Lock above**
laterally flex toward the contact, rotate away; never end range

**Pillar contacts in the lower neck.** The articular pillar is the standard segmental contact. The rotary set up drives it P to A toward the opposite eye; the lateral flexion set up drives it L to M. Transverse processes carry the vertebral artery and are not HVLA contacts.

**LOCK THESE IN**

- No rotation with extension at the atlas.
- Pillar, not TP.
- Rotary toward the opposite eye.
- Lock: flex toward, rotate away.
- Fulcrum under the lower vertebra.
- Rib angle lateral to the TP.

## Chapter 10 essentials

| Item | Key point |
|---|---|
| **Atlas rotation** | About 30 degrees head turn only |
| **Rotary range** | About 30 to 45 degrees, never end range |
| **Thumb move** | Spinous side, L to M, head flexed toward |
| **Supine anterior thoracic** | A to P through elbows, slightly S to I |
| **Pump and bucket** | Upper ribs pump handle; lower ribs bucket handle |
| **First rib** | S to I, toward the opposite hip |

## Worked cases

**CASE 10.1 · A ROTATED T1**

A 55 year old carpenter has pain at the base of the neck after overhead work. T1 is PR. No arm symptoms.

**STEP 1 · SCREEN**

Arm neurovascular symptoms, exertional cardiac symptoms, red flags; confirm T1 with the extension test.

**STEP 2 · SET UP**

Prone; stand on the right; thumb on the right side of the T1 spinous; other hand laterally flexing the head right.

**STEP 3 · VERBALIZE**

"A shallow HVLA thrust, R to L with a slight P to A component, pushing the T1 spinous toward the midline."

**TRAPS PEOPLE FALL INTO**

- **End range rotation.** Unsafe and unnecessary.
- **TP contacts in the neck.** The artery runs there.
- **Wrong fulcrum level.** Under the lower vertebra.
- **Rib contact on the TP.** Slide lateral.

## Chapter 10 self-test · six items

### 1. Roughly how much of total cervical rotation occurs at C1 to C2?

A. About a tenth
B. Nearly all
C. About a quarter
D. About half

**D. About half** The atlantoaxial joints provide about half of cervical rotation, roughly 40 degrees to each side.

### 2. Which set up suits a patient anxious about neck rotation with a lateral flexion restriction?

A. A rotary set up with the head rotated fully to end range
B. A seated set up with combined rotation and full extension
C. A lateral flexion set up with the head bent over the contact
D. A supine set up contacting the transverse process directly and firmly

**C. A lateral flexion set up with the head bent over the contact** The lateral flexion set up uses little rotation and fits both the listing and the anxiety.

### 3. In a prone thumb move for a rotated T1, what does the other hand do?

A. Laterally flexes the head toward the contact
B. Rotates the head fully away from the contact
C. Pushes down on the opposite shoulder blade
D. Rests on the table to support the doctor

**A. Laterally flexes the head toward the contact** Lateral flexion toward the contact brings tension down to the junction and fixes the segments above.

### 4. Which modification fits a patient on long term corticosteroids needing thoracic care?

A. Use a stronger body drop to overcome the stiffer thoracic joints and ribs
B. Use the supine anterior thoracic set up for maximal leverage
C. Avoid body drops and supine thrusts through the ribs; use low force
D. Use only rib thrusts, since steroids do not affect the ribs

**C. Avoid body drops and supine thrusts through the ribs; use low force** Long term steroids weaken bone, so forceful thoracic and rib thrusts are avoided.

### 5. Which ribs have no costotransverse joint?

A. Ribs 1 and 2
B. Ribs 11 and 12
C. Ribs 2 to 9
D. Ribs 7 and 8 only

**B. Ribs 11 and 12** Ribs 11 and 12 articulate with a single vertebral body and have no costotransverse joint.

### 6. A rower has posterior rib pain with sudden breathlessness. What is the right step before any rib thrust?

A. Contact the rib angle and thrust at end exhalation as planned
B. Stop and rule out pneumothorax or embolism with referral
C. Use a supine rib set up instead of a prone one to be safe
D. Ask the patient to hold a deep breath and then adjust the rib

**B. Stop and rule out pneumothorax or embolism with referral** Sudden pleuritic pain with dyspnea suggests a pulmonary emergency, not a rib dysfunction.

# Lumbar, Pelvic and Sacroiliac Set Ups

Read it in full: **Chapter 11 in the textbook**. Practice it: **the practice exams** and **the flashcards**.

## What to know

Name six parts in order: listing, position, stance, contacts, stabilization, line of drive. Side posture puts the posterior body side up, flexes the top hip until the target space opens and rotates the trunk back from above; the mammillary push drives P to A on the up side and the spinous pull draws the down side of the spinous to midline. Stop and reassess for any new leg pain.

Choose other methods for an acute disc with radiculopathy, osteoporosis, late pregnancy, spondylolisthesis, fusion or hip replacement. Flexion distraction contacts the spinous above the disc and begins with a tolerance test; peripheralization stops it.

PI ilium: PSIS low, short leg, PSIS contact P to A and I to S. AS: PSIS high, long leg, ischial contact. IN moves the PSIS lateral, EX medial. Confirm with Gillet and three of five provocation tests. Coccyx work on an exam is external only; pregnancy needs side lying, low force and an obstetric red flag screen.

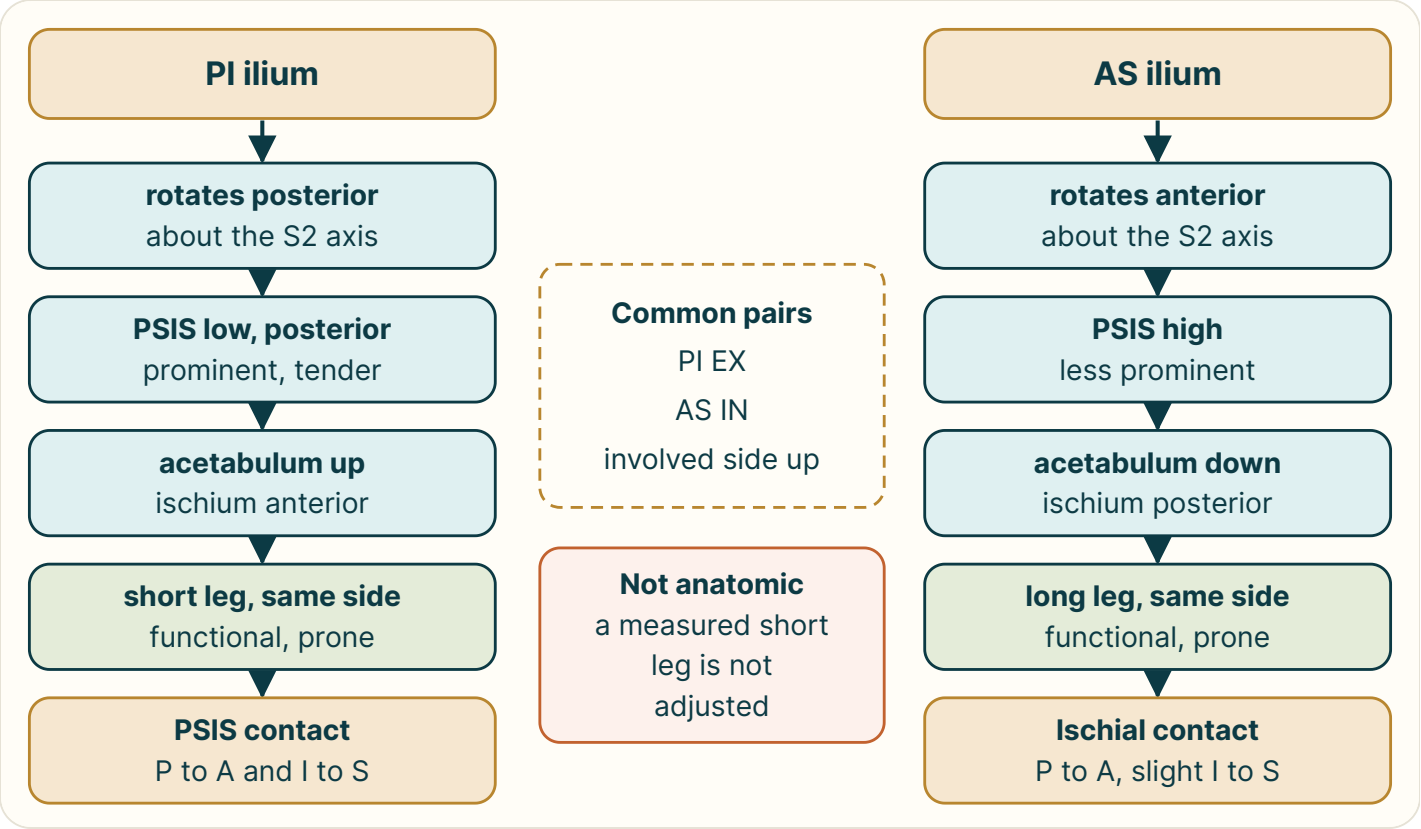


**Follow the PSIS.** A PI ilium drops the PSIS and checks short; an AS ilium raises it and checks long, both on the involved side. The correction drives the bone back through the contact that reaches it best.

**LOCK THESE IN**

- Posterior body side up.
- Contact above the disc.
- Peripheralization stops it.
- PI short, AS long.
- Ischium for AS.
- External coccyx only.

## Chapter 11 essentials

| Item | Key point |
|---|---|
| **Spinous pull** | Down side of spinous, toward ceiling |
| **Lumbar roll** | Nonspecific; not a segmental correction |
| **PI EX contact** | Medial PSIS, slight M to L |
| **AS hip flexion** | About 90 degrees |
| **Base anterior** | Apex contact, encourages counternutation |
| **Supine hypotension** | Tilt to the left |

## Worked cases

**CASE 11.1 · A PREGNANT PATIENT WITH SI PAIN**

A woman at 32 weeks has right SI pain and right PI findings. BP 118/74. No obstetric red flags.

**STEP 1 · SCREEN**

Bleeding, fluid, contractions, fetal movement, headache, vision, upper abdominal pain, swelling, calf pain; confirm obstetric care.

**STEP 2 · POSITION**

Left side down, right side up, pillows between the knees and under the abdomen, moderate hip flexion, minimal rotation.

**STEP 3 · DRIVE**

Pisiform on the right PSIS, P to A and I to S with low force, or a drop piece on a pregnancy table; avoid long supine positions.

**TRAPS PEOPLE FALL INTO**

- **Spinous side up.** Posterior body side up.
- **Wrong FD contact.** The vertebra above the disc.
- **PI and AS swapped.** Follow the PSIS.
- **Internal coccyx on an exam.** Never.

## Chapter 11 self-test · six items

### 1. Why is side posture a poor first choice for an acute disc herniation with radicular pain?

A. Rotation and flexion under load can increase annular stress and root tension
B. The patient cannot lie on the side at all because of the antalgic lean present
C. Side posture works only on the thoracic spine and not the lumbar spine
D. Flexion distraction is always faster than side posture adjustment

**A. Rotation and flexion under load can increase annular stress and root tension** Rotation with flexion under load stresses the annulus. Flexion distraction after a tolerance test is the usual alternative.

### 2. Which hip motions risk dislocating a posterior approach hip replacement in side posture?

A. Extension beyond neutral with abduction and external rotation of the hip
B. Slight flexion with a pillow placed between the two knees
C. Flexion beyond about 90 degrees with adduction and internal rotation
D. Any motion of the hip at all, even in the prone position

**C. Flexion beyond about 90 degrees with adduction and internal rotation** Limit top hip flexion and use a pillow between the knees, or choose prone or supine methods.

### 3. In the standing flexion test, what marks the side of restriction?

A. The PSIS that stays lower
B. The leg that checks longer
C. The PSIS that rises higher
D. The side with more pain

**C. The PSIS that rises higher** The fixed ilium moves with the sacrum, so its PSIS rises higher on forward bending.

### 4. For a right PI ilium in side posture, how is the elbow held?

A. Raised, so the forearm points along the S to I line
B. Lowered, so the forearm points along the I to S line
C. Locked straight at shoulder height toward the table
D. Bent fully so that the thrust comes from the wrist alone

**B. Lowered, so the forearm points along the I to S line** Dropping the elbow sends force inferior to superior, which the PSIS contact for PI needs.

### 5. A patient's sacral base is anterior. Where is the contact?

A. On the sacral base
B. On the coccyx tip
C. On the L5 spinous
D. Near the sacral apex

**D. Near the sacral apex** Base anterior (sacral flexion) is contacted near the apex, P to A and slightly I to S.

### 6. A woman with osteoporosis has sudden thoracolumbar pain after lifting a bag. What is the working assumption?

A. A muscle strain that suits a side posture thrust
B. A facet syndrome that needs a prone body drop
C. A sacroiliac lesion needing an ischial contact
D. A compression fracture until proven otherwise

**D. A compression fracture until proven otherwise** Sudden pain after minimal stress in osteoporosis is a compression fracture until imaging says otherwise.

# Extremity Set Ups

Read it in full: **Chapter 12 in the textbook**. Practice it: **the practice exams** and **the flashcards**.

## What to know

Extremity set ups restore joint play. A convex surface glides opposite to the shaft and a concave surface glides the same way. Shoulder abduction needs an inferior glide; knee extension needs an anterior tibial glide; ankle dorsiflexion needs a posterior talar glide; wrist flexion needs a dorsal carpal glide.

Screen first: instability, fracture and cardiac referral at the shoulder; posterior SC displacement as an emergency; supracondylar and radial head fractures; the scaphoid; SCFE, AVN and prosthetic hips; the Ottawa knee, ankle and foot rules; cruciates before tibial glides; and the common fibular nerve at the neck.

Hip and ankle distraction in the resting position are foundation techniques. A posterior radial head limits supination, a dorsal capitate is corrected dorsal to palmar with traction, a posterior fibular head is driven P to A, and a plantar cuboid is whipped plantar to dorsal.

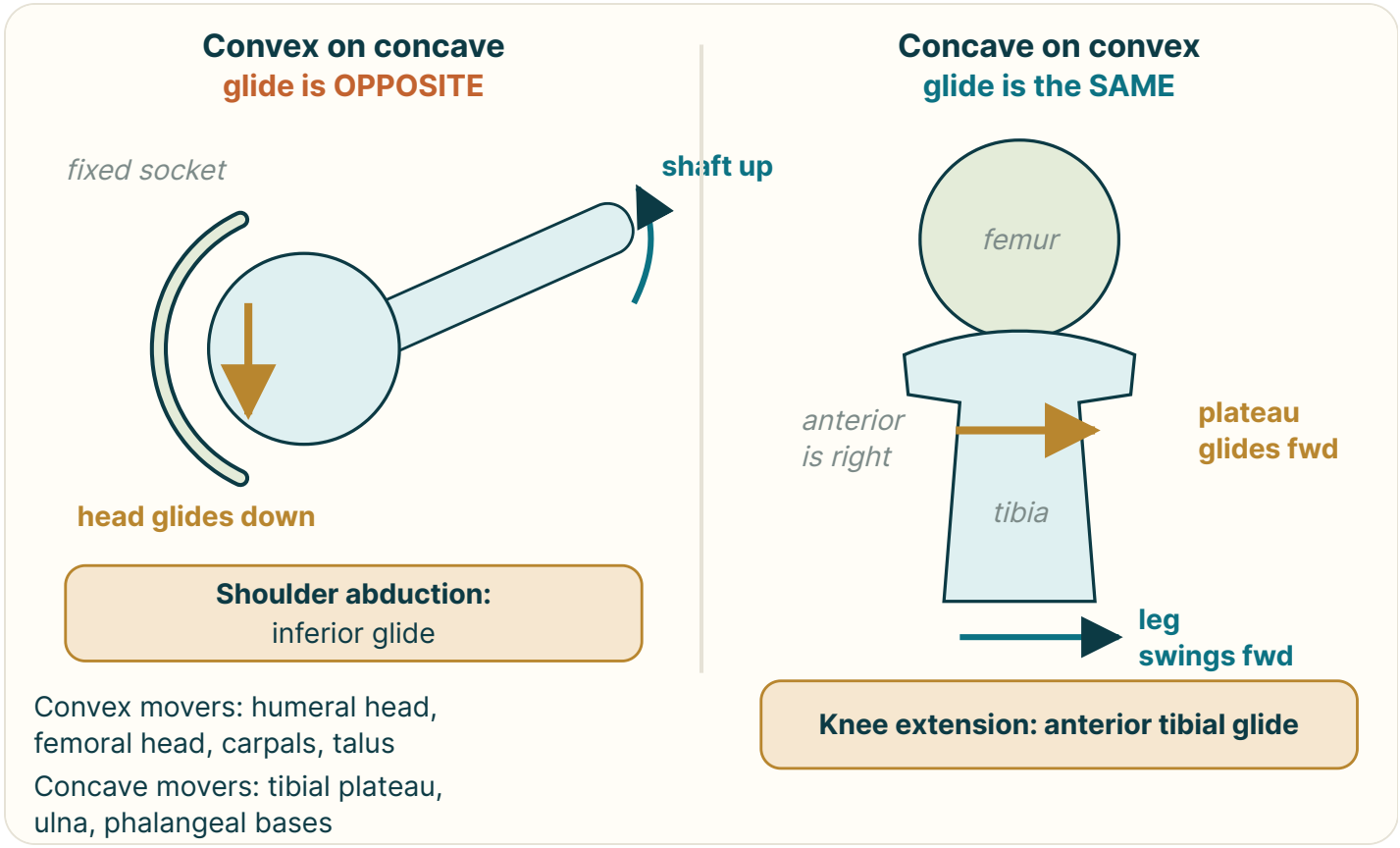


**Which way does the joint glide?** A convex surface glides opposite to the shaft; a concave surface glides the same way. Identify the moving partner and its shape, and the treatment glide follows.

**LOCK THESE IN**

- Convex opposite, concave same.
- Inferior glide for abduction.
- No posterior pressure on a posterior SC.
- Cruciates before tibial glides.
- Head, not neck, at the fibula.
- Ottawa before the foot.

## Chapter 12 essentials

| Item | Key point |
|---|---|
| Glenohumeral resting | About 55 abduction, 30 horizontal adduction |
| Pulled elbow | Ages 1 to 4; pull mechanism |
| Capsular pattern, hip | Internal rotation lost most |
| Hemarthrosis | Effusion within about 2 hours |
| Talus after inversion | Commonly anterior, dorsiflexion limited |
| Kanavel signs | Flexor tenosynovitis, surgical emergency |

## Worked cases

CASE 12.1 · A DANCER'S LATERAL MIDFOOT

A 19 year old dancer has lateral midfoot pain 10 days after rolling her ankle. The plantar cuboid is tender; malleoli, fifth metatarsal base and navicular are not; she walked in unaided.

STEP 1 · APPLY THE RULES ALOUD

Ottawa ankle and foot negative, so radiographs are not required by the rules.

STEP 2 · SCREEN LISFRANC

No plantar bruising or midfoot instability.

STEP 3 · SET UP

Prone, knee flexed about 80 degrees, overlapped thumbs on the plantar medial cuboid, plantar to dorsal at the end of a quick plantarflexion whip.

TRAPS PEOPLE FALL INTO

- **Same direction glide for a convex joint.** Convex glides opposite.
- **Anterior glide with instability.** Avoid it.
- **Tibial glides before ligament tests.** Drawer in disguise.
- **Fibular neck contact.** Nerve risk.

## Chapter 12 self-test · six items

### 1. Which surface moves as a concave partner?

A. The humeral head in the glenoid
B. The tibial plateau on the femur
C. The femoral head in the acetabulum
D. The talus in the ankle mortise

**B. The tibial plateau on the femur** The tibial plateau is concave, so it glides in the same direction as the leg.

### 2. An AC joint shows a step deformity and a piano key sign after a fall. What is the plan?

A. Superior to inferior thrust on the clavicle
B. Posterior to anterior glide of the clavicle
C. Image and refer for orthopedic evaluation
D. Scapulothoracic mobilization and review

**C. Image and refer for orthopedic evaluation** A visible step or piano key sign suggests grade III or higher. These are imaged and referred, not adjusted.

### 3. A palmar lunate with numbness in the thumb, index and middle fingers suggests what?

A. A lunate dislocation needing emergency reduction
B. A dorsal capitate needing a dorsal to palmar thrust
C. Carpal tunnel syndrome suited to arch spreading
D. Kienböck disease suited to long axis distraction

**A. A lunate dislocation needing emergency reduction** A palmar lunate can compress the median nerve and is an emergency.

### 4. An adolescent with a limp shows obligatory external rotation on hip flexion. What do you do?

A. Long axis distraction in the resting position today
B. Posterior glide of the femoral head with the hip flexed
C. Lumbar side posture to address referred hip pain
D. Non weight bearing and urgent orthopedic referral

**D. Non weight bearing and urgent orthopedic referral** This suggests SCFE. No manipulation; protect from weight bearing and refer urgently.

### 5. Sixty minutes after a pivoting injury, a footballer's knee is tensely swollen. What does this suggest?

A. A simple synovitis that suits patellar glides today
B. A Baker cyst that suits tibial distraction
C. A collateral sprain that suits gapping
D. A hemarthrosis, such as an ACL tear or fracture

**D. A hemarthrosis, such as an ACL tear or fracture** A tense effusion within about 2 hours is a hemarthrosis, suggesting ACL tear, fracture or patellar dislocation.

### 6. Hallux limitus is treated with which glide of the proximal phalanx?

A. A dorsal glide after distraction
B. A plantar glide after compression
C. A medial glide during a gout flare
D. A lateral glide over a Morton neuroma

**A. A dorsal glide after distraction** The concave phalanx glides with the motion, so extension needs a dorsal glide. Avoid it in an acute gout flare.

# Practice Stations I: Imaging and Case Management Walk Throughs

Read it in full: **Chapter 13 in the textbook**. Practice it: **the practice exams** and **the flashcards**.

## What to know

Answer every film in five parts (finding, location, view, impression, recommendation) and say whether care proceeds, is modified or stops for referral. Run ABCS and check the corners so the first finding does not end the search.

Run one case sequence: door card plan, entry, OPQRST, red flags, background, summary, narrated exam, findings, plan with consent, close. Cervical roots exit above their pedicle and lumbar roots below, so a posterolateral L4 to L5 disc hits L5 and a far lateral one hits L4. Use the Canadian C spine rule and Quebec grades after neck trauma, SNOOP and a dissection screen for headache, and the cervical and SI clusters.

Separate neurogenic from vascular claudication by posture and pulses, end low back stations with cauda equina safety netting, use decision rules and side comparison in the limbs, look one joint up in children, and treat abnormal door card vitals as a pointer to a medical cause with the urgency named.

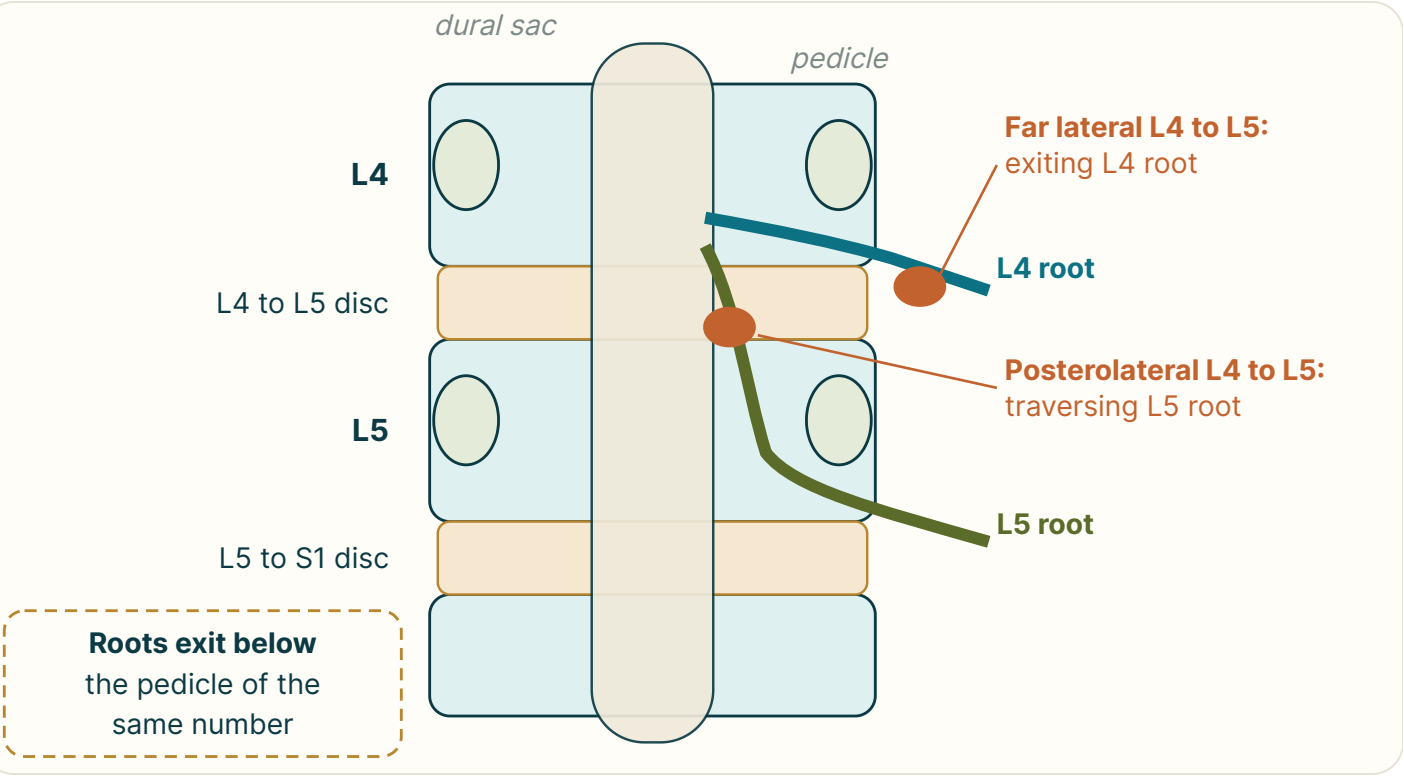


**Disc level to root.** At L4 to L5 the L4 root has already exited under the L4 pedicle, so a posterolateral herniation meets the traversing L5 root. A far lateral herniation at the same disc meets the exiting L4 root.

**LOCK THESE IN**

- Five part film answer.
- Proceed, modify, stop.
- Cervical above, lumbar below.
- 45 degrees each way.
- Pulses separate claudications.
- Vitals point to viscera.

## Chapter 13 essentials

| Item | Key point |
|---|---|
| **Corners of the film** | Ribs, apex, aorta |
| **Myelopathy signs** | Clumsy hands, gait, Hoffmann, clonus, Babinski |
| **Quebec III** | Neurologic signs |
| **Thunderclap headache** | Call 911 |
| **ABI** | Under 0.9 suggests arterial disease |
| **Visceral clue** | Exam cannot reproduce the pain |

## Worked cases

**CASE 13.1 · FEVER AND RIGHT SCAPULAR PAIN**

A 47 year old woman has two days of right scapular pain after dinner, coming in waves, temperature 38.1 °C. Thoracic movement and palpation do not change it.

**STEP 1 · NOTICE THE CUES**

Fever, a link to eating and a nonmechanical exam.

**STEP 2 · EXAMINE THE ABDOMEN**

With consent and draping: right upper quadrant tenderness and a positive Murphy sign.

**STEP 3 · ACT**

Same day urgent care or ED for blood tests and ultrasound for cholecystitis; document and send a note.

**TRAPS PEOPLE FALL INTO**

- **No recommendation.** Half credit.
- **Lumbar rule in the neck.** Cervical exits above.
- **C spine rule in children.** Adults only.
- **Ignoring vitals.** They redirect the station.

## Chapter 13 self-test · six items

### 1. What should you do after finding one abnormality on a film?

A. Finish the ABCS routine and check the corners
B. Stop and give the impression for that finding
C. Ask the examiner whether more findings exist
D. Order advanced imaging before saying anything

**A. Finish the ABCS routine and check the corners** Satisfaction of search is prevented by completing the routine and looking at the corners.

### 2. Two days after hoisting a suitcase overhead, a 41 year old reports an unfamiliar occipital headache, right neck pain, brief double vision and veering on tandem walking. What is the plan?

A. Gentle cervical mobilization and review in two days
B. Vertebral artery provocation tests in the office to confirm it first
C. No neck treatment and emergency transport for vascular imaging
D. Upper cervical adjustment to relieve the headache

**C. No neck treatment and emergency transport for vascular imaging** This is a dissection pattern with neurologic signs. Do not manipulate or provoke; call emergency services and document.

### 3. Which test in the cervical radiculopathy cluster is most sensitive?

A. Spurling's test with full axial load
B. ULTT A, the median nerve tension test
C. Cervical distraction relief
D. Rotation under 60 degrees

**B. ULTT A, the median nerve tension test** ULTT A is sensitive, so a negative result makes radiculopathy much less likely. Spurling's is specific.

### 4. Which root matches weak great toe extension and numbness in the first web space?

A. L4
B. S1
C. L3
D. L5

**D. L5** L5 supplies the extensor hallucis longus and the lateral leg, dorsum and first web space.

### 5. Where is sacroiliac joint pain typically felt?

A. Above L5, across both sides evenly
B. Below L5, near the PSIS, on one side
C. In the groin with limited hip rotation
D. Down the leg below the knee to the foot

**B. Below L5, near the PSIS, on one side** The Fortin finger sign points within about a finger's width of the PSIS.

### 6. Which door card vital sign should redirect a station toward a medical cause?

A. A temperature of 38.4 °C
B. A pulse of 76 per minute
C. Respirations of 14 per minute
D. A blood pressure of 124/78

**A. A temperature of 38.4 °C** A temperature at or above 38 °C, pulse over 100, respirations over 20 or BP of 180/110 or more points to a medical cause.

# Practice Stations II: Technique Walk Throughs and Final Preparation

Read it in full: **Chapter 14 in the textbook**. Practice it: **the practice exams** and **the flashcards**.

## What to know

Run one technique script: screen, consent, confirm, position, stance, contact, stabilize, pre-load with a comfort check, line of drive with both components, re-check. Translate every listing into the posterior side, the restricted motion and the direction to move. In the neck contact the posterior side and drive toward the opposite eye; in the thoracic spine follow the facet slope on exhalation and modify for osteoporosis.

In side posture the posterior structure faces up; PI uses the PSIS and AS the ischium. Extremity set ups start from a joint play comparison and the convex concave rule, with the stabilizing hand near the joint line. Screen for fracture, prosthesis, instability, infection and nerve involvement.

Practice with mock circuits that flag critical items and include surprises. Pace case stations to 40 and 80 percent, and technique screening to the first quarter. Taper the final week, protect sleep, use breathing, reappraisal and a door routine, recover omissions openly, and let safety outrank any task.

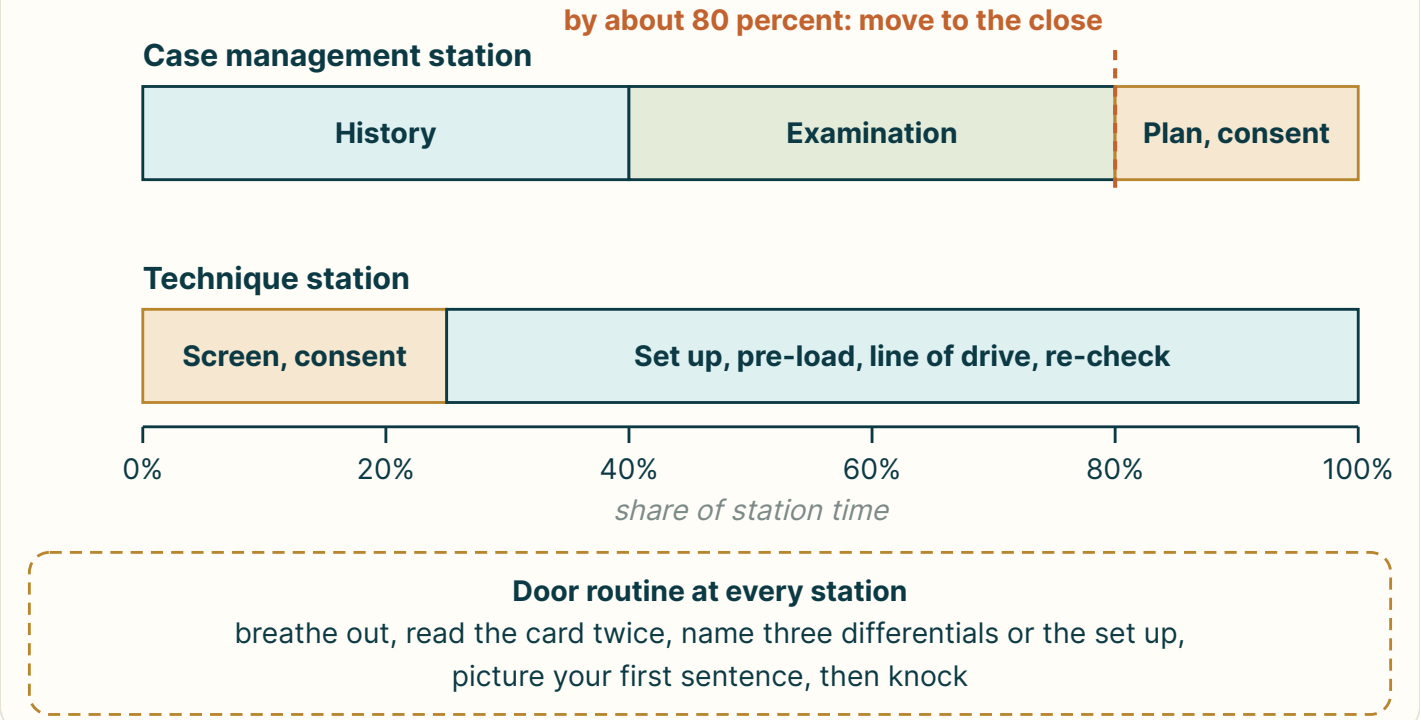


**Pace the station before you enter.** Finish the history by about 40 percent of the time and the exam by about 80 percent, leaving the last fifth for findings, plan and consent. In technique stations, finish screening and consent in the first quarter.

**LOCK THESE IN**

- Two component line of drive.
- Posterior side contact.
- Exhalation for thoracic thrusts.
- PI PSIS, AS ischium.
- 40 and 80 percent.
- Safety outranks the task.

## Chapter 14 essentials

| Item | Key point |
|---|---|
| **Translation** | Posterior side, restricted motion, direction |
| **Lateral break** | L to M, head bent over contact |
| **Joint play** | Compare sides; restricted glide is the listing |
| **Mock roles** | Candidate, SP, examiner, timekeeper |
| **Feedback** | One good, critical misses, one fix |
| **Day before** | 30 to 60 minutes light review |

## Worked cases

**CASE 14.1 · BACK PAIN ON THE STAIRS**

A 58 year old in a technique station for T5 mentions the pain began an hour ago carrying groceries upstairs; he is short of breath and pale.

**STEP 1 · STOP THE PATHWAY**

The set up can wait; this may be cardiac.

**STEP 2 · ASK AND CHECK**

Chest pressure, arm or jaw pain, sweating, cardiac history; pulse and blood pressure if equipment is present.

**STEP 3 · ACT**

"I'm not going to adjust your back today." State that you would call emergency services and stay with him.

**TRAPS PEOPLE FALL INTO**

- **One component lines.** Add the second.
- **Wrong side up.** Posterior up.
- **Contact swap.** PSIS for PI.
- **Talking through a cue.** Hands stop first.

## Chapter 14 self-test · six items

### 1. Which phrase gives a complete thoracic line of drive?

A. "Posterior to anterior, as firmly as the patient allows"
B. "Straight down into the table with a quick push"
C. "P to A and slightly I to S, at the end of exhalation"
D. "Toward the ceiling, timed to a deep inhalation"

**C. "P to A and slightly I to S, at the end of exhalation"** Add the second component that follows the facet slope and say when you would thrust.

### 2. In a spinous pull for L4 right posterior body rotation, where are the finger pads?

A. On the up (right) side of the L4 spinous tip
B. On the down (left) side of the L4 spinous
C. On the right L4 mammillary process
D. On the left L5 transverse process

**B. On the down (left) side of the L4 spinous** The spinous pull draws the down side of the spinous toward the ceiling, rotating the vertebra left like the mammillary push.

### 3. A patient has a left total hip replacement and right hip osteoarthritis. What is the set up?

A. Left hip posterior glide to restore the lost internal rotation of that joint
B. Bilateral hip distraction with both legs pulled at once from the feet
C. Side posture with the left side up and the left hip flexed past 90
D. Right hip long axis distraction, avoiding left hip flexion with adduction

**D. Right hip long axis distraction, avoiding left hip flexion with adduction** Treat only the native hip, in its resting position, and protect the prosthesis from flexion with adduction and internal rotation.

### 4. An SP reports leg tingling during a side posture pre-load. What is the correct response?

A. Finish the pre-load quickly and then ask about the leg symptoms afterward
B. Increase the rotation slightly to move past the tingling sensation
C. Stop, release, ask about distribution and weakness, then change approach
D. Reassure the patient that tingling is normal and continue the set up

**C. Stop, release, ask about distribution and weakness, then change approach** Stopping for symptoms is a critical item. "Stop hands first, then talk."

### 5. What is the purpose of the final week taper?

A. Consolidate skills and protect sleep rather than learn new material
B. Learn as many new film cases as possible before the exam begins
C. Run a full mock circuit every day including the day before the exam
D. Shift study to late nights so the brain adapts to exam pressure

**A. Consolidate skills and protect sleep rather than learn new material** New material in the last days displaces confidence, and late cramming degrades recall and motor precision.

### 6. What is the safest way to recover a forgotten consent mid set up?

A. Continue quietly and hope that the examiner did not notice the omission
B. Release, say so, give the full consent and resume only with permission
C. Ask for consent while holding the pre-load so time is not wasted
D. Skip consent, since the station says not to deliver the thrust

**B. Release, say so, give the full consent and resume only with permission** Many checklists credit the item when it is completed before the procedure.

# Cram sheet

Every routine, number, red flag and set up from the fourteen chapters, in one place. Cover the right columns and rebuild each row from memory, one table a day in the final week.

## Chapters 1 and 2 · Station habits

| Item | The rule | Note |
|---|---|---|
| **Door card** | Name, age, sex; complaint; vitals; task verbs; first three steps | The verb defines the checklist |
| **Opening** | Hygiene, name and role, identity, agenda, comfort | Easy points in the first 20 seconds |
| **Scoring** | Checklists, critical actions, global ratings | If it is not said, it is not scored |
| **Verbalize** | Test, side, result, meaning; listing, contacts, stabilization, line of drive | State pertinent negatives |
| **Simulated thrust** | Full set up, tissue pull, preload, stated line of drive | "I would now deliver a high velocity, low amplitude thrust" |
| **Time warning** | Move to findings, diagnosis, plan, consent, questions | Never return after the end signal |
| **Consent** | Nature, material risks, benefits, alternatives, right to stop | Separate consent to examine and to treat |
| **Stop rule** | Stop, release, reassess | Neuro or vascular signs: emergency services |
| **Sensitive exams** | Never in a station | State you would do it with consent and chaperone, or refer |
| **SOAP** | Negatives in S, named tests in O, reasoning in A, referral in P | Document only what you did |

## Chapters 1 and 2 · Red flags and responses

| Finding | Suspect | Response |
|---|---|---|
| **Saddle anesthesia, retention, bilateral weakness** | Cauda equina | Emergency referral |
| **Sudden neck pain or headache with dizziness, diplopia, dysarthria** | Cervical artery dissection | No manipulation; emergency services |
| **Over 50, cancer, weight loss, night pain** | Malignancy | Urgent imaging and referral |
| **Fever, IV drug use, immunosuppression** | Infection | Urgent referral |
| **Pulsatile mass, tearing pain** | Aortic aneurysm | No lumbar adjusting; emergency if symptomatic |
| **Exertional chest pain** | Acute coronary syndrome | Stop; emergency services |
| **RA, Down syndrome, upper cervical trauma** | Atlantoaxial instability | Imaging clearance before upper cervical work |

## Chapters 1 and 2 · Film numbers

| Item | Value | Note |
|---|---|---|
| **ADI** | 3 mm or less adult; up to 5 mm child | Transverse ligament |
| **Prevertebral tissue** | About 7 mm at C2; 22 mm at C6 | 14 mm at C6 in children |
| **C1 overhang** | Over 7 mm total | Rule of Spence |
| **Pseudosubluxation** | C2 spinous within about 2 mm of C1 to C3 line | Up to 3 to 4 mm slip normal in children |
| **Chest** | 9 to 10 posterior ribs; CT ratio under 0.5 on PA | Mediastinum under about 8 cm |
| **Aorta** | Walls 3 cm or more apart | Suspected aneurysm |
| **CRITOE** | About 1, 3, 5, 7, 9, 11 years | Order matters most |
| **Neck shaft angle** | About 120 to 135 degrees | Vara smaller, valga larger |

## Chapters 3 and 4 · Trauma at a glance

| Finding | Name | Decision |
|---|---|---|
| **C1 overhang over 7 mm combined** | Jefferson with ligament rupture | Unstable; collar, ED, CT |
| **Lucency across dens base** | Odontoid type II | Unstable; EMS |
| **Bilateral C2 pars fracture** | Hangman | Unstable even with normal neuro exam |
| **25% slip, bow tie facets** | Unilateral facet dislocation | Collar, CT, surgery evaluation |
| **50% slip, perched facets** | Bilateral facet dislocation | Emergency |
| **Posterior wall bowed, wide pedicles** | Burst fracture | CT, referral |
| **Horizontal split through all columns** | Chance fracture | Unstable; check abdomen |
| **Collar on Scotty dog** | Spondylolysis | Protect, image, follow |
| **Klein's line misses epiphysis** | SCFE | Non weight bearing, same day referral |
| **Normal films, snuffbox pain** | Occult scaphoid | Spica; MRI or repeat in 10 to 14 days |
| **Transverse lucency 1.5 to 2 cm past tuberosity** | Jones fracture | Non weight bearing, referral |

## Chapters 3 and 4 · Decision rules and grades

| Rule | Content |
|---|---|
| **NEXUS** | Clear if no midline tenderness, deficit, altered alertness, intoxication or distracting injury |
| **Canadian C spine** | High risk (65+, dangerous mechanism, paresthesias) images; low risk who rotates 45 degrees each way does not |
| **Stress films** | Never with fracture, deficit or altered alertness; often at 7 to 14 days |
| **Instability** | Cervical over 3.5 mm or 11 degrees; lumbar slip over about 4 mm |
| **Meyerding** | I to 25%, II to 50%, III to 75%, IV to 100%, V beyond |
| **Salter Harris** | SALTR, I to V; higher means more growth risk |
| **Ottawa ankle** | Distal 6 cm posterior edge or tip of a malleolus, or cannot bear weight for four steps |

## Chapters 3 and 4 · Disease shapes and patterns

| Finding | Think |
|---|---|
| **Uneven narrowing, osteophytes** | Degenerative |
| **Even narrowing, marginal erosions, osteopenia** | Rheumatoid |
| **Overhanging edge, joint preserved** | Gout |
| **Chondrocalcinosis** | CPPD |
| **Bamboo spine, SI fusion** | Ankylosing spondylitis |
| **Flowing bone, 4+ levels, discs kept** | DISH |
| **Missing pedicle** | Metastasis |
| **Pedicle spared, cold scan, CRAB** | Myeloma |
| **Disc and both endplates destroyed** | Infection |
| **H vertebra** | Sickle cell |
| **Picture frame, big bone** | Paget |
| **Rugger jersey** | Renal osteodystrophy |
| **Aorta 3 cm or more** | Aneurysm |

## Chapters 5 and 6 · History habits

| Item | The rule | Note |
|---|---|---|
| **Door card** | Who, what, task, data | Three to five hypotheses, one must not miss |
| **Opening** | Hygiene, name and role, two identifiers, preferred name, comfort, consent, agenda | Agenda question surfaces hidden worries |
| **Funnel** | Open, OPQRST plus associated, discriminating, closed red flags | Let the opening statement finish |
| **Wording** | Closed and neutral is fine | Leading and stacked questions are not |
| **Cues** | Pick them up at once | "My dad had something like this" |
| **Seven families** | Cancer, infection, fracture, cauda equina and cord, vascular, visceral, medications | Every spinal case |
| **Cauda equina** | Saddle, bladder, bowel, sexual, both legs, weakness | One item at a time |
| **Dissection** | 5 D's and 3 N's plus ataxia | Referral, not treatment |
| **SNOOP** | Systemic, neurological, onset sudden, older, pattern change | Headache red flags |
| **Flags** | Yellow, blue, black, orange | Psychological, work, system, psychiatric |
| **Summary** | Positives, negatives aloud, concerns, accuracy check | Then explain, drape, consent |

## Chapters 5 and 6 · Examination numbers

| Item | Value | Note |
|---|---|---|
| **BP categories** | Under 120/80; 120 to 129; 130 to 139 or 80 to 89; 140 or 90 | Normal, elevated, stage 1, stage 2 |
| **Crisis** | Over 180 and/or 120 | Symptoms: emergency services |
| **Cuff** | Bladder 80% around, 40% wide | Lower edge 2 to 3 cm above crease |
| **Deflation** | 2 to 3 mmHg per second | Phase I systolic, phase V diastolic |
| **Arm difference** | Over 10 to 15 mmHg | Subclavian or aortic disease |
| **Pulse** | 60 to 100 | Full minute if irregular |
| **Respirations** | 12 to 20 | Count while holding the pulse |
| **Fever** | 100.4°F (38.0°C) | Infection screen |
| **SLR** | 35 to 70 degrees | Radiating pain below the knee |
| **Chest expansion** | Under 2.5 cm | Ankylosing spondylitis |
| **Schober** | Under 5 cm increase | Reduced lumbar flexion |
| **Strength** | 0 to 5 | 3 against gravity only |
| **Reflexes** | 0 to 4+ | 2+ normal; reinforce before calling absent |
| **Likelihood ratios** | LR+ over 5 to 10; LR minus under 0.1 to 0.2 | Meaningful shift |

## Chapters 7 and 8 · Decisions

| Item | The rule | Note |
|---|---|---|
| **Impression** | Tissue, level, side, qualifiers | Specific, defensible, safe |
| **Differential** | Two to four, ranked, one cannot miss | Each with a reason |
| **Orders** | Only what changes management | One sentence: condition plus trigger |
| **No red flags** | Usually no imaging at first visit | Say why |
| **Cauda equina** | Same day emergency, not outpatient MRI | No manipulation, no driving |
| **Lanes** | Treat, co-manage, refer | Referral is not abandonment |
| **Plan** | Diagnosis, procedures, frequency, goals, measures, home care, re-exam, safety net | Same order every time |
| **Trial of care** | About 2 weeks; two failed trials about 4 weeks | Change, investigate or refer |
| **Absolute contraindication** | No thrust in that region | Dissection, fracture, tumor, infection, instability, myelopathy |
| **Relative contraindication** | Modify | Anticoagulants, osteopenia, stable slip, pregnancy |
| **Urgency** | 911; ED today; prompt days; routine | Decide the level first |
| **BE FAST** | Balance, eyes, face, arm, speech, time | Stroke signs |

## Chapters 7 and 8 · Tests and numbers

| Item | Value | Note |
|---|---|---|
| **Canadian C spine** | 65+, dangerous mechanism, paresthesias | Rotate 45 degrees each way if low risk |
| **Ottawa ankle** | Posterior edge or tip, distal 6 cm; four steps | ATFL tenderness alone is a sprain |
| **Ottawa knee** | 55+, patella, fibular head, flex under 90, four steps | Highly sensitive |
| **Radiograph lysis** | 30 to 50% bone loss | MRI for marrow |
| **Bone scan** | Sensitive, not specific | Myeloma often cold |
| **DEXA** | T score minus 2.5 or lower | Osteoporosis |
| **EMG** | About 3 weeks to denervation | Root versus entrapment |
| **Pain scale** | 2 points or 30% | ODI 10 points; NDI 5 to 7 of 50 |
| **ABI** | 0.9 or lower | Arterial disease |

## Chapters 7 and 8 · Documentation and communication

| Item | The rule |
|---|---|
| **Correction** | Single line, legible, date, initials |
| **Late entry** | Current date and time plus visit date |
| **Consent** | Capacity, disclosure, understanding, voluntary, documented |
| **PARQ** | Procedure, Alternatives, Risks, Questions |
| **Benign reactions** | 1/3 to 1/2, settle in 24 to 48 hours |
| **Teach-back** | Patient explains in own words |
| **SBAR** | Situation, Background, Assessment, Recommendation |
| **SPIKES** | Setting, Perception, Invitation, Knowledge, Emotions, Strategy |
| **NURSE** | Name, Understand, Respect, Support, Explore |
| **Interpreter** | Professional, first person, never a child |

## Chapters 9 and 10 · Technique station rules

| Item | The rule | Note |
|---|---|---|
| **Seven elements** | Listing, patient position, stance, contact point, segmental contact, stabilization, line of drive | Same order, said aloud |
| **Wrap around** | Screen and consent before; preload and spoken thrust after | Then release and reassess |
| **Spinous and body** | Rotate in opposite directions | PR: spinous right, body left |
| **TP, lamina, pillar, mammillary** | Posterior body side, P to A | Opposite the spinous |
| **Spinous contact** | Spinous side, toward midline | L to M |
| **Lateral flexion contact** | Side to flex toward | Head bent over the contact |
| **ASRP** | Tilt, laterality, rotation of that side | Contact right side of atlas |
| **Thrust phases** | Positioning, tissue pull, preload, impulse, resolution | Stop at preload at the station |
| **Cavitation** | Refractory about 15 to 20 minutes | Not proof of the target joint |
| **End feel** | Springy normal; hard fixated; boggy acute; empty serious | Empty: stop and evaluate |
| **Two track script** | Plain words to patient, precise terms to examiner | Correct errors aloud |

## Chapters 9 and 10 · Regional set ups

| Region | Contact | Drive |
|---|---|---|
| **Atlas rotation** | Index MCP on posterior arch, posterior side | P to A, toward opposite eye; head about 30 degrees |
| **Lower cervical rotary** | Pillar on posterior body side | P to A, slightly I to S, toward opposite eye |
| **Lower cervical lateral flexion** | Pillar on side to flex | L to M |
| **Junction thumb move** | Thumb on spinous side | L to M, slight P to A; head flexed toward contact |
| **Thoracic extension** | Bilateral TPs, one vertebra | P to A, slightly I to S |
| **Thoracic rotation** | Posterior TP; crossed with opposite TP below; or spinous push | P to A or L to M |
| **Thoracic flexion** | Supine; fulcrum under the lower vertebra | A to P, slightly S to I |
| **Rib angle** | 2 to 3 fingers lateral to TP | P to A, lateral and slightly inferior |
| **First rib** | Superior surface behind clavicle | S to I, toward opposite hip |

## Chapters 9 and 10 · Numbers and landmarks

| Item | Value |
|---|---|
| **Lower cervical facets** | About 45 degrees |
| **Thoracic facets** | About 60 degrees, near frontal |
| **C1 to C2 rotation** | About half of cervical rotation |
| **Rotary head turn** | About 30 to 45 degrees, never end range |
| **Inferior scapular angle** | About T7 |
| **Rule of threes** | T1 to T3 own; T4 to T6 half; T7 to T10 below; T11 half; T12 own |
| **Impulse** | About a tenth of a second or a little more |

## Chapters 11 and 12 · Lumbopelvic rules

| Item | The rule | Note |
|---|---|---|
| **Six parts** | Listing, position, stance, contacts, stabilization, line of drive | Said aloud in order |
| **Side posture side** | Posterior body side up | Spinous right: left side up |
| **Lock** | Bottom leg straight; top hip flexed until the target space opens; trunk rotated back | Thigh on the top knee |
| **Mammillary push** | Up side mammillary, P to A along the facet plane | Body drop |
| **Spinous pull** | Down side of spinous, toward the ceiling | Same side down |
| **Leg pain at the lock** | Stop, release, neutral, neuro recheck | Change approach |
| **Other tools** | Acute disc, osteoporosis, pregnancy, spondylolisthesis, fusion, hip replacement | Prone drop, flexion distraction, instruments |
| **Flexion distraction** | Spinous above the disc; tolerance test first | Peripheralization stops it |
| **PI ilium** | PSIS low, short leg; PSIS contact P to A, I to S | Involved side up |
| **AS ilium** | PSIS high, long leg; ischial contact, hip about 90 | P to A, slight I to S |
| **IN and EX** | PSIS lateral; PSIS medial | PI EX, AS IN |
| **SI cluster** | 3 or more of 5 provocation tests | Gillet, standing and seated flexion |
| **Coccyx** | External only, over the drape, chaperone | Internal: scope, written consent |
| **Pregnancy** | Side lying, low force, tilt left if supine | Preeclampsia: emergency referral |

## Chapters 11 and 12 · Extremity glides

| Joint | Restriction | Glide |
|---|---|---|
| **Shoulder** | Abduction | Inferior |
| **Shoulder** | Flexion or internal rotation | Posterior |
| **Shoulder** | Extension or external rotation | Anterior (not with instability) |
| **Radial head** | Supination limited | Posterior head driven P to A |
| **Wrist** | Flexion; extension | Dorsal; palmar |
| **Hip** | Flexion and IR; extension and ER | Posterior; anterior |
| **Knee** | Extension; flexion | Anterior tibia; posterior tibia |
| **Fibular head** | Posterior | P to A on the head, not the neck |
| **Ankle** | Dorsiflexion | Posterior talus |
| **Cuboid** | Plantar | Plantar to dorsal whip |
| **First MTP** | Extension | Dorsal glide of the phalanx |

## Chapters 11 and 12 · Red flags before extremity work

| Finding | Meaning |
|---|---|
| **Exertional chest pressure with left shoulder pain** | Cardiac |
| **Posterior SC with hoarseness or dysphagia** | Emergency |
| **Snuffbox tenderness** | Scaphoid fracture until proven otherwise |
| **Palmar lunate with median signs** | Dislocation, emergency |
| **Shortened, externally rotated leg after a fall** | Hip fracture |
| **Adolescent limp, obligatory ER** | SCFE |
| **Effusion within 2 hours** | Hemarthrosis |
| **Springy block to extension** | Locked meniscus |
| **Foot drop after knee injury** | Fibular nerve injury |
| **Warm, red, swollen diabetic foot** | Charcot neuroarthropathy |

## Chapters 13 and 14 · Imaging and case stations

| Item | The rule | Note |
|---|---|---|
| **Film answer** | Finding, location, view, impression, recommendation | Recommendation says proceed, modify or stop |
| **Routine** | Label, ABCS, corners | Beats satisfaction of search |
| **Case plan** | Three differentials, one red flag, two or three tests | Ten seconds at the door |
| **Cervical roots** | Exit above their pedicle | C5 to C6 disc hits C6 |
| **Lumbar roots** | Exit below their pedicle | Posterolateral L4 to L5 hits L5; far lateral hits L4 |
| **Cervical cluster** | Spurling, ULTT A, distraction, rotation under 60 | 3 or 4 of 4 likely |
| **Myelopathy** | Clumsy hands, gait, Hoffmann, clonus, Babinski, Lhermitte | MRI, surgical referral, no manipulation |
| **Canadian C spine** | High risk images; low risk then 45 degree rotation | Alert, stable adults |
| **Quebec WAD** | I symptoms; II MSK signs; III neuro signs; IV fracture | I and II stay active |
| **Claudication** | Neurogenic: flexion relief, pulses normal; vascular: standing relief, ABI under 0.9 | Check pulses |
| **Visceral** | Unchanged by movement, organ linked, abnormal vitals | Name the urgency |
| **Door card vitals** | Pulse over 100, RR over 20, T 38 °C or more, BP 180/110 or more | Medical cause |

## Chapters 13 and 14 · Technique and exam week

| Item | The rule | Note |
|---|---|---|
| **Script** | Screen, consent, confirm, position, stance, contact, stabilize, pre-load, line, re-check | Narrate each |
| **Translation** | Posterior side, restricted motion, direction | Before touching |
| **Neck** | Posterior side, head turned away, toward opposite eye | Avoid end range with extension |
| **Thoracic** | P to A, slightly I to S, end of exhalation | Low force in osteopenia |
| **Side posture** | Posterior structure up | PI PSIS; AS ischium |
| **Extremities** | Compare joint play; convex concave; stabilize near joint | No thrust across a prosthesis |
| **Pacing** | History 40%, exam 80%; technique screen in first quarter | Stop at the signal |
| **Mock critical items** | Screen, consent, pre-load comfort, stopping for symptoms | One fix per candidate |
| **Final week** | Review, mock, fix, short circuit, red flags, logistics, rest | 7 to 9 hours sleep |
| **Nerves** | Box breathing, reappraisal, door routine | Reset between stations |


Dr. Garg Learning · CC BY-SA 4.0