Study Guide 7

This guide covers the practice stations that pull the whole book together. Chapter 13 walks through films and case management for the neck, head, low back, pelvis, extremities and visceral mimics. Chapter 14 walks through technique stations region by region, then shows how to run a mock circuit and how to spend the final week and exam day. Read the "what to know" paragraphs, study the diagram, then run each worked case aloud against a timer with the steps covered.

WHAT THIS GUIDE COVERS

- Chapter 13 · the five part film answer and the proceed, modify or stop buckets, a film drill set, the case station sequence, cervical radiculopathy and myelopathy, the Canadian C spine rule and whiplash grades, headache types and dissection, low back triage, root and disc levels, neurogenic versus vascular claudication, SI pain, extremity and pediatric traps, and visceral referral with urgency levels.
- Chapter 14 · the technique script, translating listings, cervical, thoracic and rib walk throughs, side posture and pelvic walk throughs, extremity walk throughs and safety, the mock circuit with roles, scoring and feedback, pacing targets, the final week taper, sleep, logistics, nerves and recovering omissions.

CHAPTER 13

Practice Stations I: Imaging and Case Management Walk Throughs

Read it in full: **Chapter 13 in the textbook**. Practice it: **the practice exams** and **the flashcards**.

What to know

Imaging tasks reward seeing the finding and saying it in a usable form. A correct impression with no location, or a correct finding with no recommendation, is a partial answer. Every film answer has five parts: **finding** in descriptive terms, **location** (bone or level and side), **view** where it is best seen, **impression** in one line with one or two differentials, and **recommendation** (imaging or labs,

referral and urgency, and the effect on care). Drill to the official time, or a fixed window such as two minutes per film. When time is short, give the main finding, then the impression, then the recommendation, then the supporting detail.

Run the same routine on every film: read the label (age, sex, side, view, date), then **ABCS** (alignment and counts, bone, cartilage and joint spaces, soft tissues), and finish with the **corners**, where a rib lesion, an apical mass or aortic calcification often hides. Put every film into one of three buckets and say it: **proceed** (incidental or degenerative), **modify** (avoid thrust at a level, use low force, add imaging) or **stop and refer** (fracture, instability, tumor, infection, aneurysm, slipped epiphysis). Descriptive words are safe when you are unsure of the name; vague words are not.

High yield drill answers: an L5 pars lucency with a slip under 25 percent is a grade 1 isthmic spondylolisthesis (flexion and extension views, avoid extension loading and forceful P to A thrusts at L5). Widened prevertebral tissue at C2 with a lucency at the dens base is an odontoid fracture until proven otherwise (stop, immobilize, ED and CT). Bilateral symmetric SI erosions in a young man are sacroiliitis (ESR, CRP, HLA-B27, rheumatology). A missing pedicle is metastasis (urgent MRI and oncology). Aortic walls more than 3 cm apart are an aneurysm (ultrasound, vascular referral, emergency if pain, tenderness or hypotension). An ADI widening from 2 to 6 mm in flexion in RA is atlantoaxial instability. A subchondral crescent with preserved joint space is AVN (MRI). Klein's line missing the head on a frog leg lateral is SCFE (non weight bearing, same day referral).

Case stations share one sequence: the door card plan (top three differentials, the one red flag to rule out, the two or three discriminating tests), entry and identity, chief complaint and OPQRST, the red flag screen, background, a summary and transition, the exam with each result narrated, findings in plain language, the plan with consent, and the close. That ten second plan is what keeps a station focused.

Cervical radiculopathy is a root problem, so look for a dermatome, myotome and reflex that agree. C6 and C7 are most often involved. Cervical roots exit **above** the pedicle of the same number, so a C5 to C6 disc affects the C6 root. Use the cluster: Spurling (specific), ULTT A (sensitive), distraction relief and ipsilateral rotation under about 60 degrees; three or four positives

make radiculopathy likely, and a negative ULTT makes it much less likely. Always screen for **myelopathy** (hand clumsiness, gait imbalance, bilateral symptoms, hyperreflexia, Hoffmann, clonus, Babinski, Lhermitte), which needs MRI and surgical referral and contraindicates cervical manipulation.

After neck trauma, the **Canadian C spine rule** applies to alert (GCS 15), stable adults, not children, altered patients or those with known vertebral disease. Any high risk factor means image; with none, a low risk factor must be present before you ask for rotation; active rotation of 45 degrees each way means no imaging. Then grade whiplash with the **Quebec Task Force** scale: 0 no complaint; I pain, stiffness or tenderness only; II plus musculoskeletal signs; III plus neurologic signs; IV fracture or dislocation. Grades I and II do best with reassurance, early activity, exercise and short manual therapy; collars and rest slow recovery.

Headache stations use **SNOOP** to exclude secondary causes, then classify. Tension type is bilateral band like pressure without nausea. Migraine is unilateral, pulsating, 4 to 72 hours, worse with activity, with nausea and light and sound sensitivity. Cervicogenic headache is side locked, starts in the neck, and shows reduced rotation on the flexion rotation test. Cluster headache is severe orbital pain for 15 to 180 minutes with tearing and ptosis. Giant cell arteritis is a new headache over 50 with scalp tenderness and jaw claudication (same day referral). A thunderclap headache is subarachnoid hemorrhage (911). **Dissection** can present first as neck pain and headache; ask about new or unusual pain, minor trauma, the 5 D's and 3 N's and ataxia, and look for a partial Horner syndrome. Provocation tests are no substitute for history and a cranial nerve and cerebellar screen. In neck and head stations, take the blood pressure, screen cranial nerves when there is headache or dizziness, and name the stroke risk in consent.

Low back stations begin with triage into **mechanical**, **radicular or claudicant**, and **serious pathology**. Lumbar roots exit **below** the pedicle of the same number. A posterolateral L4 to L5 herniation compresses the **traversing L5** root; a far lateral herniation at the same level compresses the **exiting L4** root; a central herniation can compress several roots or the cauda equina. L4: knee extension and tibialis anterior, patellar reflex, medial leg. L5: great toe extension and hip abduction, no reliable reflex, lateral leg and first web space. S1: plantar flexion and eversion, Achilles reflex, lateral foot. The SLR reproduces leg pain below the knee between about 30 and

70 degrees; a crossed SLR is specific for a large herniation; centralization predicts a good prognosis. MRI waits for red flags, severe or progressive deficit, or failure of 4 to 6 weeks of care.

Separate **neurogenic** from **vascular** claudication: stenosis eases with sitting or bending, is better leaning on a cart, worse downhill, tolerates cycling and has normal pulses; arterial disease eases with standing still, is worse uphill, is provoked by cycling, and shows reduced pulses, shiny hairless skin and an ankle brachial index under 0.9. SI pain sits below L5 near the PSIS; three or more of five provocation tests, with no centralization, point to the SI joint. Always end low back stations with cauda equina safety netting in plain words.

Extremity stations add three habits: clear the joint above and below, compare sides, and check neurovascular status distally, with a decision rule before loading an injured joint. Lachman is the most sensitive ACL test and the pivot shift the most specific. A limping child with knee pain may have hip disease: SCFE, Perthes, transient synovitis or septic arthritis. A scaphoid fracture can hide on the first film.

Visceral pain is felt in the dermatomes of shared cord segments. Clues: pain unchanged by movement, linked to eating, breathing, urination, exertion or the cycle, systemic signs, abnormal vitals and an exam that fails to reproduce it; say so aloud. Name the urgency explicitly: **emergency** (call 911 and stay: cardiac chest pain, stroke signs, aortic catastrophe, cauda equina with retention, severe dyspnea), **same day** (GCA, infection, progressive deficit, suspected fracture, SCFE) or **routine**. Vital signs on the door card are a cue: a pulse over 100, respirations over 20, a temperature of 38 °C or more, or a BP of 180/110 or more should turn the station toward a medical cause and referral.

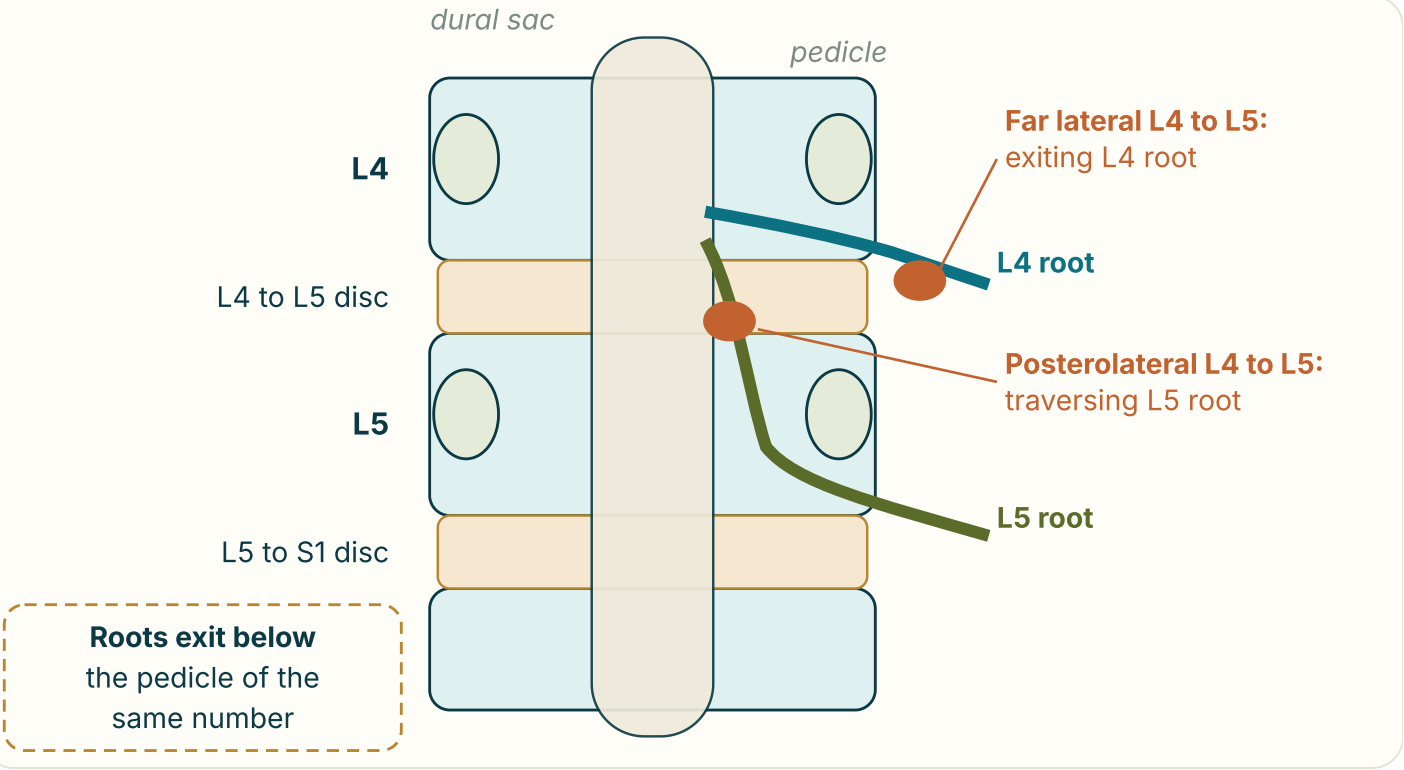

Disc level to root. At L4 to L5 the L4 root has already exited under the L4 pedicle, so a posterolateral herniation meets the traversing L5 root. A far lateral herniation at the same disc meets the exiting L4 root.

LOCK THESE IN

- Film answers: finding, location, view, impression, recommendation; say proceed, modify or stop and refer.
- ABCS, then the corners.
- Cervical roots exit above their pedicle; lumbar roots exit below.
- Posterolateral L4 to L5 hits L5; far lateral L4 to L5 hits L4.
- Canadian C spine: high risk images; low risk allows rotation; 45 degrees each way means no film.
- Quebec grades: I symptoms only, II musculoskeletal signs, III neurologic signs, IV fracture.
- Neurogenic claudication eases with flexion and has normal pulses; vascular eases standing still, ABI under 0.9.
- Abnormal door card vitals mean think medical cause and refer.

Root levels for case stations

Root	Motor	Reflex	Sensory
C5	Deltoid, elbow flexion	Biceps	Lateral arm
C6	Wrist extension, elbow flexion	Brachioradialis	Lateral forearm, thumb, index
C7	Elbow extension, wrist flexion	Triceps	Middle finger
C8	Grip	None reliable	Medial forearm, ring and little fingers
T1	Finger abduction	None reliable	Medial arm
L4	Knee extension, tibialis anterior	Patellar	Medial leg, medial malleolus
L5	Great toe extension, hip abduction	None reliable	Lateral leg, dorsum, first web space
S1	Plantar flexion, eversion	Achilles	Lateral foot, sole, little toe

Decision tools and discriminators

Tool	Content	Use
Film buckets	Proceed, modify, stop and refer	Say it with every film
Canadian C spine	High risk (65+, dangerous mechanism, paresthesias) images	Low risk factor then 45 degree rotation
NEXUS	No midline tenderness, deficit, altered alertness, intoxication, distracting injury	Alternative rule
Quebec WAD	0 to IV	I and II: activity, exercise, short manual care
Cervical cluster	Spurling, ULTT A, distraction, rotation under 60	3 or 4 of 4 likely
SLR	Leg pain below the knee about 30 to 70 degrees	Crossed SLR specific
Neurogenic claudication	Flexion relief, cart sign, cycling tolerated, pulses normal	Flexion based care
Vascular claudication	Standing relief, uphill worse, cycling provokes, ABI under 0.9	Vascular referral
SI cluster	3 or more of 5, no centralization	SI joint source
Door card vitals	Pulse over 100, RR over 20, T 38 °C or more, BP 180/110 or more	Medical cause

Worked cases

WORKED CASE 1 · A GYMNAST'S FILM IN FIVE PARTS

A 16 year old gymnast has six weeks of low back pain worse with back walkovers. Lateral lumbar film provided.

STEP 1 · ORIENT AND TRACE

Young female, lateral lumbar. The posterior body line steps forward at L5 to S1.

STEP 2 · FIND AND MEASURE

A lucent gap crosses the L5 pars. The posteroinferior corner of L5 sits in the first quarter of the S1 endplate.

STEP 3 · FINDING, LOCATION, VIEW

Bilateral L5 pars defects with anterior translation of L5 on S1, lateral view.

STEP 4 · IMPRESSION

Isthmic spondylolisthesis, Meyerding grade 1.

STEP 5 · RECOMMENDATION AND BUCKET

Modify: flexion and extension views for instability, relative rest from hyperextension, core work, no P to A thrust at L5, orthopedic referral if neurologic signs or progression.

WORKED CASE 2 · MATCHING A ROOT TO A DISC

A 39 year old warehouse worker has back pain down the back of the left leg to the outer foot. SLR left reproduces calf and foot pain at 40 degrees, he manages 6 single leg heel raises on the left versus 15 on the right, the left Achilles is 1+ and the lateral foot is numb. No bladder or saddle change.

STEP 1 · NAME THE ROOT

Weak plantar flexion, a reduced Achilles reflex and lateral foot numbness fit S1.

STEP 2 · NAME THE DISC

Lumbar roots exit below their pedicle, so the traversing S1 root is hit by a posterolateral L5 to S1 herniation.

STEP 3 · QUANTIFY THE DEFICIT

6 of 15 heel raises is 40 percent of the other side, a clear side to side deficit to record as a baseline.

STEP 4 · PLAN

No MRI now without red flags or progressive deficit; conservative care with consent, modified duty, re-examination in two weeks, and the cauda equina safety net in plain words.

WORKED CASE 3 · TWO KINDS OF LEG PAIN ON WALKING

A 71 year old smoker with diabetes has bilateral buttock and thigh aching after two blocks. He must sit and bend forward; standing still does not help; he walks farther leaning on a cart and cycles without trouble.

STEP 1 · READ THE POSTURE CLUES

Flexion relief, the cart sign and tolerated cycling favor neurogenic claudication.

STEP 2 · EXAMINE THE VESSELS ANYWAY

Pedal pulses palpable and symmetric, capillary refill normal. His risk factors keep arterial disease on the list.

STEP 3 · NOTE THE NEURO FINDINGS

Reduced Achilles reflexes and mild toe vibration loss raise diabetic neuropathy.

STEP 4 · PLAN

Lumbar films, an ABI to document vascular status, flexion based care, a flexed posture walking program, diabetes coordination, smoking cessation advice and a cauda equina screen.

TRAPS PEOPLE FALL INTO

- **Leaving out the recommendation.** It halves the credit for a film.
- **Stopping at the first finding.** Finish ABCS and look at the corners.
- **Using lumbar exit rules in the neck.** Cervical roots exit above their pedicle.
- **Blaming L4 for a posterolateral L4 to L5 disc.** It hits the traversing L5 root.
- **Applying the C spine rule to a child.** It is for alert, stable adults.
- **Prescribing a collar for whiplash grade II.** Early activity and exercise recover faster.
- **Assuming spinal claudication in a smoker with diabetes.** Check pulses and name the vascular differential.
- **Ignoring abnormal vitals on the door card.** They point to a medical cause.

Chapter 13 self-test · ten items

1. Which film answer is complete?

A. Lucency at the dens base, lateral view: odontoid fracture; immobilize, ED and CT

B. Lucency at the dens base, lateral view: odontoid fracture is most likely here

C. Some changes in the upper cervical spine on this view, possibly a fracture

D. Odontoid fracture; recommend continuing cervical care with extra caution today

---

A. Lucency at the dens base, lateral view: odontoid fracture; immobilize, ED and CT A full answer gives finding, location, view, impression and a recommendation with its effect on care.

2. A film shows mild degenerative disc narrowing with no other finding. Which bucket fits?

A. Modify the care
B. Stop and refer
C. Repeat the film later
D. Proceed with care

D. Proceed with care Incidental or degenerative findings that do not change care belong in the proceed bucket.

3. A C5 to C6 disc herniation most likely affects which root?

A. C5
B. C7
C. C6
D. C4

C. C6 Cervical roots exit above the pedicle of the same number, so the C6 root exits at C5 to C6.

4. A posterolateral herniation at L4 to L5 most often compresses which root?

A. The traversing L5 root
B. The exiting L4 root
C. The exiting L3 root
D. The traversing S1 root

A. The traversing L5 root The L4 root has already exited under the L4 pedicle. A far lateral herniation at that level would hit L4.

5. After a simple rear end collision, an ambulatory adult with delayed neck pain and no midline tenderness rotates 50 degrees each way. What does the Canadian C spine rule say?

A. Radiographs are needed
B. No imaging is needed
C. CT is needed at once
D. Flexion views first

B. No imaging is needed With no high risk factor, a low risk factor present and active rotation of 45 degrees each way, no imaging is indicated.

6. A whiplash patient has neck pain, reduced range of motion and point tenderness, with a normal neurologic exam. What is the Quebec grade?

A. Grade I
B. Grade III
C. Grade II
D. Grade IV

C. Grade II Grade II is a neck complaint with musculoskeletal signs. Grade III adds neurologic signs.

7. Which headache is side locked, starts in the neck and shows reduced rotation on the flexion rotation test?

A. Tension type headache
B. Cervicogenic headache
C. Migraine without aura
D. Cluster headache

B. Cervicogenic headache Cervicogenic headache is unilateral and side locked, provoked by neck movement or posture.

8. Which finding best supports vascular rather than neurogenic claudication?

A. Relief by sitting and the shopping cart sign
B. Symptoms that are worse when walking downhill
C. Cycling that is tolerated without symptoms
D. Relief by standing still and an ABI under 0.9

D. Relief by standing still and an ABI under 0.9 Vascular claudication eases with standing still and shows reduced pulses and a low ABI.

9. A 13 year old with a BMI in the 97th percentile has knee pain and a limp, a normal knee exam, and loss of hip internal rotation. What is next?

A. Knee MRI and a quadriceps strengthening program for several weeks
B. AP and frog leg pelvis films, crutches and same day orthopedic referral
C. Hip long axis distraction in the resting position to restore rotation
D. Reassurance that growing pains in teenagers settle down with time and rest

B. AP and frog leg pelvis films, crutches and same day orthopedic referral Knee pain with a limp in an overweight adolescent is SCFE until proven otherwise. Examine the hip and refer the same day.

10. A 58 year old has left upper back pain that began while shoveling snow, with a pulse of 104, respirations of 22 and sweating. What do you do?

A. Complete a full thoracic exam, then decide
B. Adjust the upper thoracic spine and recheck
C. Stop the workup, call 911 and stay with him
D. Refer him to his doctor within the week

C. Stop the workup, call 911 and stay with him Exertional onset, sweating, tachycardia and tachypnea point to acute coronary syndrome.

Practice Stations II: Technique Walk Throughs and Final Preparation

Read it in full: **Chapter 14 in the textbook**. Practice it: **the practice exams** and **the flashcards**.

What to know

Technique stations are scored on observable steps, not on whether a joint cavitates. Many ask you to set up and verbalize, or take the set up to tension without a thrust; follow the station instructions exactly and check the official candidate materials. One script earns the points: door card, greet and identify, screen, consent, **confirm** the listing by static and motion palpation, position, stance, contact with tissue pull, stabilize, **pre-load** with a comfort check, **line of drive** (delivered only if instructed), and **re-check** with aftercare. The verbal track proves the anatomy, keeps the patient informed and gives evidence for what is hard to see, such as the line of drive.

Listing systems differ. Translate any door card into three answers before touching the patient: **which side is posterior, which motion is restricted, which way must the segment move**. A vertebra whose body is rotated posteriorly on the right resists rotating left, and the contact goes on the posterior (right) side, driving it anterior.

In the neck, contact the **posterior side**, turn the head away from the contact to tension with slight lateral flexion toward it to localize, and drive P to A along the facet plane, slightly I to S, toward the opposite eye. For a C5 left rotation restriction with the right pillar posterior: right index contact on the right C5 pillar, left hand cradling the occiput, line toward the left eye. A lateral break drives L to M with the head bent over the contact. At the cervicothoracic junction, a thumb on the side of the deviated spinous pushes it back to midline. Screen for dizziness, visual change, new headache, trauma, RA or Down syndrome, anticoagulants, osteoporosis and neck surgery; watch the eyes and face at pre-load; and avoid sustained end range rotation with extension. Absolute contraindications in the neck include fracture, instability, suspected dissection, myelopathy, tumor or infection, and fusion at the level.

Thoracic facets sit about 60 degrees, so drives are mainly P to A with an I to S component following the slope, delivered at the end of **exhalation**. Prone bilateral contacts address extension

restrictions; prone unilateral and counter rotation contacts address rotation; the supine anterior thoracic move addresses flexion restrictions. In a woman over 60, ask about bone health first. With osteopenia or a prior fragility fracture, choose low force mobilization or drop or instrument methods, say why, and avoid the supine anterior thoracic move, which loads the rib cage and the anterior bodies. Rib angles are contacted lateral to the TP and driven P to A and lateral along the shaft on exhalation.

In **side posture**, put the posterior structure up: for L4 right posterior body rotation, the right side is up. A mammillary push on the up side or a spinous pull on the down side both rotate the vertebra left. Localize with top leg flexion while palpating the interspace, draw the bottom arm out to rotate the shoulder back, and roll the pelvis forward. For a **PI ilium** contact the **PSIS**, P to A and I to S; for an **AS ilium** contact the **ischial tuberosity** below the axis, P to A, rotating the ilium back. Swapping these contacts is a classic error. Screen first for cauda equina, progressive deficit, fracture or osteoporosis, aneurysm, tumor or infection, hip replacement, recent surgery and pregnancy. If leg pain increases or spreads during pre-load, stop, release and change approach; flexion distraction suits a disc patient unsuited to rotation.

Extremity set ups start with a **side to side joint play comparison**: the restricted glide is the listing. Apply the convex concave rule (shoulder abduction needs an inferior head glide, hip internal rotation a posterior head glide, knee extension an anterior tibial glide), use the resting position for distraction and glides, and keep the stabilizing hand close to the joint line so force crosses one joint. Screen for fracture (Ottawa rules), joint replacement, septic or inflammatory arthritis, instability (never thrust a lax joint in the direction of laxity), bone tumor, open growth plates and severe osteoporosis. A stiff diabetic shoulder with capsular loss suggests adhesive capsulitis and calls for graded oscillation, not a forceful thrust. With a replaced hip on the other side, treat only the native hip and avoid positions that flex and adduct the prosthesis.

A **mock circuit** reproduces time pressure, observation and task switching. Use four to six people rotating as candidate, standardized patient (answers only what is asked, reports cues), silent examiner with a checklist, and timekeeper. Write realistic door cards and scripts, include at least one station that should end in referral, and build in a surprise: dizziness at pre-load, abnormal vitals, a second finding in a film corner or a declined consent. Score done, partly done or not done,

flag **critical items** (contraindication screen, consent, pre-load comfort check, following the thrust instruction and stopping for symptoms) so that missing one fails the mock station, and add a 1 to 5 global rating. Feedback: one thing done well, critical items missed, one fix to test again.

Pace the station: in case management, finish the history by about **40 percent** of the time and the exam by about **80 percent**, leaving the last 20 percent for findings, plan and consent. In technique stations, finish screening and consent in the **first quarter**. Use the official times, or fixed practice values until you have them, and stop at the signal even mid sentence.

The final week is for consolidation. Run a full review pass at 7 days, a full mock circuit at 6, fix the list at 5, a short circuit with a surprise at 4, red flags and contraindications at 3, logistics settled at 2, and rest the day before with 30 to 60 minutes of light review. Keep a constant wake time and 7 to 9 hours of sleep; one poor night matters far less than a week of short sleep. Keep caffeine at your usual dose (half life about five hours), avoid alcohol and eat familiar food.

Manage nerves with slow breathing (box breathing 4, 4, 4, 4, or a double inhale and long exhale), **reappraisal** (label the racing heart as readiness), and a **door routine**: breathe out, read the card twice, name three differentials or the set up, picture your first sentence, knock. Reset between stations. If you blank, fall back on the sequence. If you realize you skipped consent, release, return to neutral, say so, give the full consent, then resume; many checklists credit the item when it is completed before the procedure. A red flag in a technique station, such as exertional breathlessness and pallor, ends the technique pathway: the safe decision outranks finishing the set up.

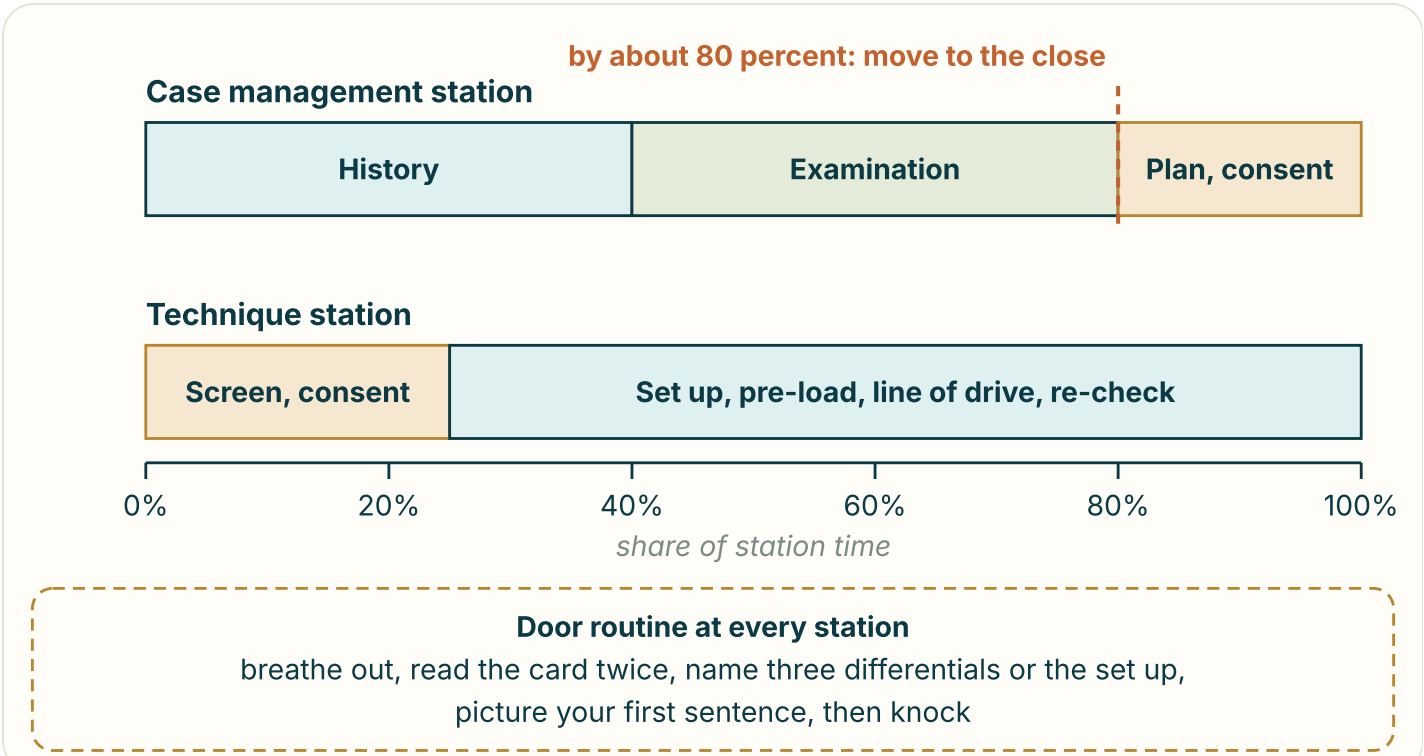

Pace the station before you enter. Finish the history by about 40 percent of the time and the exam by about 80 percent, leaving the last fifth for findings, plan and consent. In technique stations, finish screening and consent in the first quarter.

LOCK THESE IN

- Script: screen, consent, confirm, position, stance, contact, stabilize, pre-load, line of drive, re-check.
- Translate any listing: posterior side, restricted motion, direction to move.
- Neck: contact the posterior side, turn away, drive toward the opposite eye.
- Thoracic and rib drives are timed to the end of exhalation; modify for osteoporosis.
- Side posture: posterior structure up. PI uses the PSIS; AS uses the ischium.
- Extremities: compare joint play, apply the convex concave rule, stabilize near the joint line.
- Pacing: history by 40 percent, exam by 80 percent; technique screening and consent in the first quarter.
- Recover an omission openly; safety always outranks finishing the task.

Technique walk through set ups

Listing	Contact	Line of drive
C5 left rotation restricted, right pillar posterior	Right index contact on right C5 pillar	P to A, slightly I to S, toward the left eye
C2 to C7 right lateral flexion restricted	Right index contact on right pillar	L to M (right to left), slight I to S
C1 restricted in right rotation, left lateral mass posterior	Left index contact on left posterior arch	P to A and slightly L to M
C7 to T1 spinous deviated right	Right thumb on right side of spinous	R to L across the spinous
Thoracic extension restriction	Bilateral thenar or hypothenar on both TPs	P to A, slightly I to S, on exhalation
Thoracic rotation, right TP posterior	Pisiform on right TP; counter contact on left TP below	P to A with slight I to S arc, on exhalation
Thoracic flexion restriction	Fulcrum hand under the segment, supine	A to P through the elbows, on exhalation
L4 right posterior body rotation	Pisiform on right L4 mammillary, right side up	P to A with a body drop
Same listing, spinous pull	Finger pads on down (left) side of L4 spinous	Toward the ceiling
Right PI ilium	Right PSIS, right side up	P to A and I to S
Right AS ilium	Right ischial tuberosity, hip beyond 90 degrees	P to A, slightly I to S

Listing	Contact	Line of drive
Glenohumeral abduction restriction	Web on superior humeral head, arm about 55 degrees	S to I parallel to the glenoid
Posterior fibular head	Second MCP behind the fibular head	P to A, slightly lateral, flexing the knee
Plantar cuboid	Overlapped thumbs on plantar cuboid	Plantar to dorsal whip

Mock circuit and final week

Item	Content	Note
Roles	Candidate, SP, examiner, timekeeper	Rotate so everyone scores
Critical items (technique)	Contraindication screen, consent, pre-load comfort check, thrust instruction and stopping	Missing one fails the mock station
Global rating	1 to 5 for organization and professionalism	Captures the overall impression
Feedback	One done well, critical misses, one fix	Retest the fix
Pacing, case station	History by 40%, exam by 80%, last 20% plan	Stop at the signal
Pacing, technique	Screening and consent in the first quarter	Most time on set up and narration
7 and 6 days out	Review pass; full mock circuit	List every miss
5 and 4 days out	Fix the list; short circuit with a surprise	Confirm the fixes
3 and 2 days out	Red flags and contraindications; logistics	Lay everything out
Day before	30 to 60 minutes light review, rest	No late study
Sleep and caffeine	7 to 9 hours; usual caffeine, half life about 5 hours	No alcohol

Worked cases

WORKED CASE 1 · NARRATING A CERVICAL SET UP

A 36 year old has right neck pain. C5 is restricted in left rotation with tenderness over the right C5 pillar. Set up and verbalize; no thrust.

STEP 1 · TRANSLATE

Left rotation restricted and right pillar tender means the right side is posterior; the segment must move left.

STEP 2 · SCREEN AND CONSENT

Dizziness, double vision, new severe headache, injury, blood thinners, RA, neck surgery; then procedure, soreness, the rare stroke risk and mobilization as the alternative.

STEP 3 · SET UP ALOUD

"Index contact of my right hand on the right C5 pillar with a slight tissue pull; my left hand cradles the occiput; head rotated left to tension with slight right lateral flexion. Any dizziness or discomfort?"

STEP 4 · LINE AND FINISH

"P to A, slightly I to S along the facet plane, toward the patient's left eye." No thrust; release and recheck rotation.

WORKED CASE 2 · PACING A CASE STATION

A practice circuit uses 10 minute case stations. Plan where you should be at each point.

STEP 1 · HISTORY

40 percent of 10 minutes is 4 minutes, so finish the history by about 4:00.

STEP 2 · EXAMINATION

80 percent is 8 minutes, so finish the exam by about 8:00.

STEP 3 · CLOSE

The last 20 percent is 2 minutes for findings, plan and consent.

STEP 4 · TECHNIQUE COMPARISON

In a 10 minute technique station, the first quarter is 2.5 minutes, so screening and consent should be done by about 2:30.

WORKED CASE 3 · RECOVERING AN OMITTED CONSENT

Halfway through a C4 set up for a right rotation restriction with the left pillar tender, you realize you never obtained consent.

STEP 1 · STOP

Release the contact and return the head to neutral.

STEP 2 · SAY IT

"Before I go further, I'd like to explain what I'm planning and make sure you're comfortable with it."

STEP 3 · FULL CONSENT

Procedure and sound, common soreness, rare serious risks including stroke, alternatives such as mobilization, the right to refuse; ask permission.

STEP 4 · RESUME ALOUD

"Index contact of my left hand on the left C4 pillar; right hand cradles the occiput; head rotated right to tension with slight left lateral flexion; P to A toward the patient's right eye."

TRAPS PEOPLE FALL INTO

- **Saying only "posterior to anterior."** Add the second component and when you would thrust.
- **Contacting the anterior or restricted side.** Contact the posterior side and drive it forward.
- **Side posture with the wrong side up.** The posterior structure faces the ceiling.
- **Swapping PI and AS contacts.** PI uses the PSIS; AS uses the ischium.
- **A supine anterior thoracic move in osteopenia.** It loads the rib cage; choose low force methods.
- **Thrusting a lax joint in its lax direction.** Test stability first.
- **Talking through a symptom cue.** Stop hands first, then talk.
- **Finishing the task despite a red flag.** Safety outranks the set up.

Chapter 14 self-test · ten items

1. A door card gives "T7 body rotated posterior on the left." How should you translate it before touching the patient?

A. Left side posterior, left rotation restricted, the segment must move left
B. Left side posterior, right rotation restricted, the segment must move right
C. Right side posterior, right rotation restricted, the segment must move left
D. Right side posterior, left rotation restricted, the segment must move right

B. Left side posterior, right rotation restricted, the segment must move right A body rotated posterior on the left resists rotating right; contact the posterior left side and drive it forward.

2. In a supine cervical rotary set up for a right posterior pillar, which way is the head turned?

A. Toward the contact, to the right
B. Into full extension, no rotation
C. Away from the contact, to the left
D. To end range left with full extension

C. Away from the contact, to the left The head turns away from the contact to tension the segment, with slight lateral flexion toward it to localize.

3. When are thoracic and rib thrusts timed?

A. At the peak of inhalation
B. During a held breath in
C. At the end of exhalation
D. At any point in breathing

C. At the end of exhalation The rib cage is least resistant at the end of exhalation.

4. A 62 year old woman with osteopenia and a prior wrist fracture has a T6 extension restriction. What should you do?

A. Use a supine anterior thoracic move for better leverage
B. Use low force mobilization or drop methods and say why
C. Use a stronger prone body drop to overcome stiffness
D. Decline all care, since osteopenia forbids any treatment

B. Use low force mobilization or drop methods and say why Osteopenia changes the method. The supine anterior thoracic move is avoided because it loads the rib cage and anterior bodies.

5. For L4 right posterior body rotation in side posture, which side faces the ceiling?

A. The left side
B. Either side
C. Neither; prone
D. The right side

D. The right side The posterior structure goes up so the thrust can drive it forward.

6. Which contact corrects an AS ilium?

A. The posterior superior iliac spine
B. The sacral base, medial to the PSIS
C. The L5 mammillary process
D. The ischial tuberosity

D. The ischial tuberosity AS means the ilium rotated forward, so the contact below the axis on the ischium drives it back. PI uses the PSIS.

7. Which statement fits extremity technique stations?

A. Compare joint play side to side, and stabilize close to the joint line
B. Contact far from the joint so the force spreads across several joints
C. Skip the comparison when the patient points clearly to one joint
D. Thrust in the direction of laxity to tighten an unstable joint

A. Compare joint play side to side, and stabilize close to the joint line The restricted glide found by comparison is the listing, and close stabilization keeps the force across one joint.

8. In a mock circuit, which item should be flagged as critical for a technique station?

A. Naming the stance aloud before the contact
B. Confirming the listing by motion palpation first
C. Adjusting the table height for the patient
D. Stopping when symptoms appear during pre-load

D. Stopping when symptoms appear during pre-load Contraindication screening, consent, the pre-load comfort check and stopping for symptoms are safety critical.

9. In a 10 minute case station, by about when should the examination be finished?

A. About 4 minutes
B. About 6 minutes
C. About 8 minutes
D. About 9.5 minutes

C. About 8 minutes The target is history by about 40 percent and exam by about 80 percent, leaving the last 20 percent for findings, plan and consent.

10. Which nerve management technique labels a racing heart as readiness?

A. Reappraisal
B. Box breathing
C. Door routine
D. Tapering

A. Reappraisal Reappraisal reframes arousal as preparation, which helps performance under evaluative stress.

Cram sheet

Everything from chapters 13 and 14 in one place. Cover the right column and see if you can rebuild each row.

Imaging and case stations

Item	The rule	Note
Film answer	Finding, location, view, impression, recommendation	Recommendation says proceed, modify or stop
Routine	Label, ABCS, corners	Beats satisfaction of search
Case plan	Three differentials, one red flag, two or three tests	Ten seconds at the door
Cervical roots	Exit above their pedicle	C5 to C6 disc hits C6
Lumbar roots	Exit below their pedicle	Posterolateral L4 to L5 hits L5; far lateral hits L4
Cervical cluster	Spurling, ULTT A, distraction, rotation under 60	3 or 4 of 4 likely
Myelopathy	Clumsy hands, gait, Hoffmann, clonus, Babinski, Lhermitte	MRI, surgical referral, no manipulation
Canadian C spine	High risk images; low risk then 45 degree rotation	Alert, stable adults
Quebec WAD	I symptoms; II MSK signs; III neuro signs; IV fracture	I and II stay active
Claudication	Neurogenic: flexion relief, pulses normal; vascular: standing relief, ABI under 0.9	Check pulses
Visceral	Unchanged by movement, organ linked, abnormal vitals	Name the urgency
Door card vitals	Pulse over 100, RR over 20, T 38 °C or more, BP 180/110 or more	Medical cause

Technique and exam week

Item	The rule	Note
Script	Screen, consent, confirm, position, stance, contact, stabilize, pre-load, line, re-check	Narrate each
Translation	Posterior side, restricted motion, direction	Before touching
Neck	Posterior side, head turned away, toward opposite eye	Avoid end range with extension
Thoracic	P to A, slightly I to S, end of exhalation	Low force in osteopenia
Side posture	Posterior structure up	PI PSIS; AS ischium
Extremities	Compare joint play; convex concave; stabilize near joint	No thrust across a prosthesis
Pacing	History 40%, exam 80%; technique screen in first quarter	Stop at the signal
Mock critical items	Screen, consent, pre-load comfort, stopping for symptoms	One fix per candidate
Final week	Review, mock, fix, short circuit, red flags, logistics, rest	7 to 9 hours sleep
Nerves	Box breathing, reappraisal, door routine	Reset between stations

Dr. Garg Learning · CC BY-SA 4.0