Study Guide 6

This guide covers the second half of technique. Chapter 11 is the low back and pelvis: side posture and its lock, when to choose flexion distraction or a drop table instead, the ilium and sacral listings, and special cases such as pregnancy and the coccyx. Chapter 12 is the extremities: the convex concave rule that predicts every glide, and the screens that come before any contact. Read the "what to know" paragraphs, study the diagram, then say each worked set up aloud with the steps covered.

WHAT THIS GUIDE COVERS

- Chapter 11 · the lumbopelvic opening, side posture positioning and the lock, mammillary push, spinous pull and lumbar roll, safety inside the set up, prone and drop options, flexion distraction and the tolerance test, PI, AS, IN and EX ilium listings, sacral listings, the SI cluster, ilium and sacral set ups, coccyx, pregnancy, osteoporosis and other modifications.
- Chapter 12 · joint play and the convex concave rule, resting and close packed positions, glenohumeral, AC and SC set ups, elbow and radial head, the pulled elbow, wrist and carpals, hand, hip screening and distraction, knee glides and ligaments, the fibular head and nerve, patellar glides, Ottawa rules, ankle, cuboid, navicular and first MTP.

CHAPTER 11

Lumbar, Pelvic and Sacroiliac Set Ups

Read it in full: **Chapter 11 in the textbook**. Practice it: **the practice exams** and **the flashcards**.

What to know

Lumbopelvic technique stations score what an examiner can observe: introduction, identity, screening, consent, safe and modest positioning, the correct segment and contact, stabilization, a line of drive that matches the listing, and all of it said aloud. The thrust is usually not delivered on a standardized patient. Name six parts in order every time: listing, patient position, doctor stance,

contact point and segmental contact, stabilization, line of drive. Check the current candidate materials for what is scored.

Open every lumbopelvic station the same way: hand hygiene, introduction, name and date of birth; a red flag screen (saddle numbness, bladder or bowel change, a recent fall, cancer, fever, weight loss, a pulsing feeling in the belly); method questions (osteoporosis, blood thinners, surgery or fusion, joint replacement, pregnancy); consent; locate the level from landmarks (the iliac crests near L4); set up; check in at tension; and post check with aftercare.

Side posture positioning builds a lock. For the mammillary push and spinous pull, the **side of posterior body rotation goes up**. Listings are named by the spinous, so translate aloud: "spinous right means the body has rotated left, so the left side is posterior and goes up." Keep the bottom leg straight, flex the top hip while monitoring the target interspinous space until it just opens (more flexion moves tension higher), rotate the upper trunk back from above, take a split stance with your caudal thigh on the top knee, and hold the shoulder with your cephalad hand. The thrust is a short, shallow body drop; specificity comes from the lock, not amplitude.

The **mammillary push** puts a pisiform on the up side mammillary process and drives P to A along the facet plane. The **spinous pull** puts finger pads on the down side of the spinous and pulls it toward the ceiling, back to midline; the patient lies on the same side. A spinous push contacts the up side of the spinous, so the side reverses. The general **lumbar roll** is broad and nonspecific and should not be presented as a segmental correction. Do not thrust in suspected cauda equina, fracture, malignancy, infection, a pulsatile mass or progressive deficit. If sharp leg pain or numbness appears as you take the lock, stop, release slowly, return to neutral and reassess neurologic status aloud.

Choosing not to use side posture is a scored decision. An acute disc with radicular pain and an antalgic lean, osteoporosis, late pregnancy, spondylolisthesis, recent surgery or fusion, a hip replacement (especially posterior approach) and patient fear all push you toward **prone drop**, **flexion distraction**, instruments or mobilization. Prone bilateral thenar contacts treat an extension restriction but are avoided in spondylolisthesis and painful extension. A drop piece set to the patient's weight lets a fast, shallow thrust do the work with less force.

Flexion distraction uses a hinged table with the patient prone, hips over the hinge and ankles cuffed. The hypothenar contacts the **spinous of the vertebra above the involved disc** (for an L4 to L5 disc, the L4 spinous), and the caudal section is lowered into flexion and long axis distraction, opening the posterior disc space and the foramen. It always begins with a **tolerance test**: a gentle contact and a little flexion. If leg pain increases or **peripheralizes**, stop and reassess; if it stays the same or **centralizes**, proceed with slow, gentle distractions in short sets, never to pain. Lateral flexion and circumduction are reserved for facet syndromes and improving discs.

Ilium listings describe where the **PSIS** went, rotating about an axis near S2. A **PI** ilium has rotated posteriorly: PSIS low and prominent, ischium anterior, acetabulum carried superior, so the leg checks **short** on that side. An **AS** ilium has rotated anteriorly: PSIS high, ischium posterior, leg **long** on that side. **IN** means the PSIS moved lateral (wider from the sacral midline); **EX** means it moved medial. Common pairings are PI EX and AS IN. In motion terms, a PI behaves as a restriction of anterior rotation, an AS as a restriction of posterior rotation. These are functional leg checks; an anatomic short leg is measured, not adjusted.

Sacral listings describe which side of the base is posterior. Base posterior on one side is contacted on that side of the base, P to A. Bilateral base posterior (sacral extension) is contacted at the base to encourage nutation. Base anterior (sacral flexion) is contacted near the apex, P to A and slightly I to S, to encourage counternutation. Torsions are translated into which side of the base and which inferior lateral angle are posterior.

No single SI test is reliable. The **Gillet** test is positive when the PSIS fails to drop relative to S2 on hip flexion. In the **standing flexion test** the PSIS that rises higher marks the restricted side; the **seated** version implicates the sacrum. Three or more of five provocation tests (distraction, compression, thigh thrust, Gaenslen, sacral thrust) support the SI joint, especially once lumbar centralization is ruled out; the thigh thrust is often the most sensitive single test. Screen for **inflammatory** sacroiliitis: morning stiffness over 30 minutes eased by exercise, onset under 40 and alternating buttock pain.

Ilium corrections put the **involved side up** in side posture with a lighter trunk rotation. For **PI**, a pisiform on the PSIS (medial aspect for EX, lateral for IN), top hip moderately flexed, drive P to A and I to S, with the elbow visibly lowered. For **AS**, a pisiform or hypothenar on the **ischial**

tuberosity, top hip flexed to about 90 degrees, drive P to A with a slight I to S component; name the contact site in consent and contact over the drape. On a drop table the same contacts and lines apply.

Coccyx pain is worse sitting and rising, often after a fall or childbirth; the coccyx is most often flexed after a fall. Screen for fracture, pilonidal cyst, perianal abscess, rectal or pelvic disease and chordoma. On an exam use **external technique only**, prone with a pillow under the pelvis, a light contact over the drape, a chaperone offered and the site named in consent. Never perform or simulate an internal approach; say it would need scope verification, specific written consent and a chaperone.

In **pregnancy**, use supported side lying or a pregnancy table, lower force and less rotation, and avoid prolonged supine lying (supine hypotension from vena cava compression; tilt her to the left). Obstetric red flags mean no manipulation and immediate referral: bleeding, fluid leakage, preterm contractions, severe abdominal pain, reduced fetal movement, and **preeclampsia** signs (new hypertension, severe headache, visual change, upper abdominal pain, sudden swelling). Calf pain and swelling is a possible DVT. In **osteoporosis**, sudden pain after minimal stress is a compression fracture until proven otherwise; avoid rotational and heavy prone thrusts. Hip replacement means limited top hip flexion with a pillow between the knees; fusion means no thrust at the fused level; AS means no thrust to fused segments; aneurysm means no lumbar thrust.

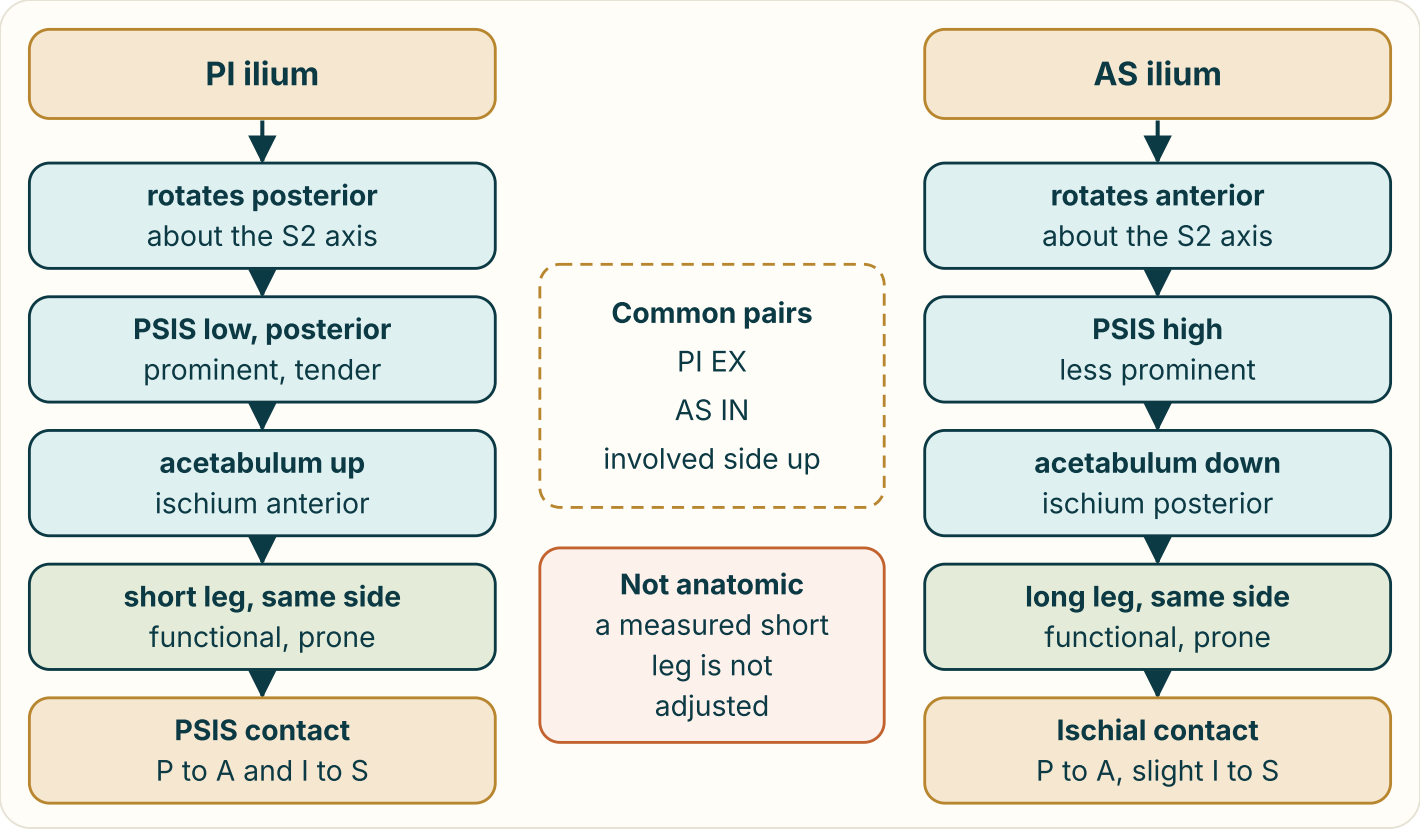

Follow the PSIS. A PI ilium drops the PSIS and checks short; an AS ilium raises it and checks long, both on the involved side. The correction drives the bone back through the contact that reaches it best.

LOCK THESE IN

- Six parts in order: listing, position, stance, contacts, stabilization, line of drive.
- Side posture: posterior body side up. Spinous right means left side up.
- Mammillary push P to A on the up side; spinous pull on the down side toward the ceiling.
- Flexion distraction contacts the spinous above the disc and starts with a tolerance test; peripheralization stops it.
- PI: PSIS low, short leg, PSIS contact P to A and I to S. AS: PSIS high, long leg, ischial contact.
- IN means PSIS lateral; EX means PSIS medial. Common pairs PI EX, AS IN.
- Three of five SI provocation tests support the SI joint.
- Coccyx: external only, chaperone offered. Pregnancy: side lying, low force, tilt left, preeclampsia means referral.

Lumbopelvic set ups

Listing or finding	Position	Contact	Line of drive
L4 spinous right, mammillary push	Right side down, left side up	Right pisiform on left L4 mammillary	P to A along the facet plane, body drop
L4 spinous right, spinous pull	Right side down	Finger pads on right side of L4 spinous	Toward the ceiling, right to left
L5 flexion fixation	Side posture, more hip flexion	Up side L5 mammillary or spinous	P to A and slightly I to S
L4 to L5 disc, tolerance test passed	Prone on flexion distraction table	Hypothenar on L4 spinous	Flexion and long axis distraction
L3 spinous left, prone drop	Prone, drop set to weight	Pisiform on left side of L3 spinous	L to R and P to A; drop releases
Right PI EX ilium	Side posture, right side up	Pisiform on medial right PSIS	P to A, I to S, slight M to L
Left AS IN ilium	Side posture, left side up, hip about 90 degrees	Pisiform on left ischial tuberosity	P to A, slight I to S, slight L to M
Sacral base posterior right	Prone or right side up	Right sacral base, medial to PSIS	P to A
Base anterior (sacral flexion)	Prone, abdominal pillow	Hypothenar on sacral apex	P to A, slightly I to S
Coccyx (exam)	Prone, pillow under pelvis	Light thumb over the drape	Gentle sustained correction

Listings, tests and modifiers

Item	Finding	Meaning or action
PI ilium	PSIS low, posterior; leg short same side	Restricted anterior rotation
AS ilium	PSIS high; leg long same side	Restricted posterior rotation
IN and EX	PSIS lateral (IN); PSIS medial (EX)	Usually paired PI EX, AS IN
Gillet	PSIS fails to drop on hip flexion	SI fixation
Standing flexion	Higher rising PSIS	Side of restriction
Seated flexion	Asymmetry	Implicates the sacrum
Provocation cluster	3 or more of 5	Supports SI pain
Hip replacement	Avoid flexion past about 90, adduction, internal rotation	Pillow between knees; prone methods
Late pregnancy supine	Vena cava compression	Tilt to the left side
Preeclampsia signs	Hypertension, headache, vision, epigastric pain, swelling	Emergency referral

Worked cases

WORKED CASE 1 · PUTTING THE PATIENT ON THE RIGHT SIDE

A 38 year old warehouse worker has 5 days of right low back pain without leg symptoms. L4 to L5 is restricted in left rotation, and the L4 spinous deviates right.

STEP 1 · SCREEN AND CONSENT

Saddle numbness, bladder or bowel change, weakness, fever, cancer, trauma; osteoporosis, blood thinners, surgery, pregnancy; then benefits, risks, alternatives and permission.

STEP 2 · TRANSLATE ALOUD

Spinous right, body rotated left, left side posterior, so the patient lies on the right side, left side up.

STEP 3 · BUILD THE LOCK

Right leg straight, left hip flexed until the L4 to L5 space opens, upper trunk rotated back by drawing the right shoulder.

STEP 4 · CONTACT AND DRIVE

Split stance with caudal thigh on the left knee, left hand on the left shoulder, right pisiform on the left L4 mammillary, P to A along the facet plane with a body drop. Pause at tension and ask about leg pain.

WORKED CASE 2 · A DISC THAT NEEDS A DIFFERENT TOOL

A 46 year old has 3 weeks of back pain down the back of the left leg to the heel, a left list, SLR positive at 40 degrees, a reduced left ankle reflex, normal strength and no bladder or bowel change.

STEP 1 · LOCALIZE

Posterior leg to the heel with a reduced ankle reflex fits S1, likely from an L5 to S1 disc.

STEP 2 · CHOOSE THE METHOD

Side posture rotation is a poor first choice with an acute disc and radiculopathy; use flexion distraction.

STEP 3 · CONTACT

The vertebra above the L5 to S1 disc is L5, so the hypothenar goes on the L5 spinous.

STEP 4 · TOLERANCE TEST

Small flexion, ask about leg pain. "If the leg pain spreads or worsens, I stop." Proceed in short gentle sets, recheck the reflex and SLR, and refer if weakness develops.

WORKED CASE 3 · NAMING AN ILIUM FROM THE FINDINGS

A 52 year old slipped on ice 3 days ago without falling. Prone, the left leg appears long, the left PSIS is high and the left ischial tuberosity palpates posterior. No osteoporosis.

STEP 1 · SCREEN FOR FRACTURE

A fall, hip impact, trouble bearing weight or groin pain with walking would mean imaging first.

STEP 2 · NAME THE LISTING

High PSIS with a long leg on the same side is a left AS ilium.

STEP 3 · SET UP

Side posture, left side up, top hip flexed to about 90 degrees, thigh on the knee, hand on the shoulder, pisiform on the left ischial tuberosity over the drape, with the contact site named in consent.

STEP 4 · VERBALIZE

"P to A with a slight I to S component, rotating the ilium posteriorly." Check in at tension and recheck leg length afterward.

TRAPS PEOPLE FALL INTO

- **Putting the spinous side up for a mammillary push.** The posterior body side goes up.
- **Contacting the disc level's lower vertebra in flexion distraction.** Contact the spinous above the disc.
- **Skipping the tolerance test.** Peripheralization must stop the procedure.
- **Mixing up PI and AS leg checks.** PI short, AS long, on the involved side.
- **Mixing up IN and EX.** IN moves the PSIS lateral; EX moves it medial.
- **Adjusting an anatomic short leg.** A true length difference is measured, not adjusted.
- **Simulating an internal coccyx technique.** External only on an exam.
- **Leaving a late pregnancy patient supine.** Tilt her to the left side.

Chapter 11 self-test · ten items

1. The L3 spinous is rotated left. For a mammillary push, which side goes up?

A. The right side, because the body has rotated right

B. The left side, because the spinous has rotated left

C. Either side, since the push works from both sides

D. The right side, because the spinous has rotated right

A. The right side, because the body has rotated right Spinous left means body rotated right, so the right side is posterior and goes up.

2. In side posture, how do you know the top hip is flexed to the target level?

A. The patient's knee touches the edge of the table

B. The patient reports a stretch in the posterior thigh

C. The target interspinous space just begins to open

D. The hip reaches exactly ninety degrees of flexion

C. The target interspinous space just begins to open Monitor the interspinous space; more flexion moves tension higher, less leaves it lower.

3. What makes a lumbar side posture adjustment specific?

A. A long, forceful rotation of the whole patient's trunk
B. The lock that brings tension to the target segment
C. A deep thrust through the lower ribs and pelvis
D. Repeated thrusts until a cavitation is heard

B. The lock that brings tension to the target segment The thrust is short and shallow. Specificity comes from the lock, not amplitude.

4. For an L4 to L5 disc treated with flexion distraction, where is the contact?

A. On the L5 spinous
B. On the sacral base
C. On the L3 spinous
D. On the L4 spinous

D. On the L4 spinous The contact holds the vertebra above the involved disc while the table flexes the lower segments.

5. During the flexion distraction tolerance test, the leg pain spreads farther down the leg. What do you do?

A. Stop and reassess
B. Increase the flexion
C. Add circumduction
D. Repeat it in a week

A. Stop and reassess Peripheralization is the stop rule. Centralization or no change allows treatment to proceed.

6. Prone, the right leg is short and the right PSIS is low and prominent. What is the listing?

A. Right AS ilium
B. Left PI ilium
C. Right IN ilium
D. Right PI ilium

D. Right PI ilium A PI ilium drops the PSIS and carries the acetabulum up, so the leg checks short on the same side.

7. What does an EX ilium describe?

A. The PSIS has moved medial, closer to the sacral midline
B. The PSIS has moved lateral, farther from the sacral midline
C. The PSIS has moved superior, making the leg check long
D. The PSIS has moved inferior, making the leg check short

A. The PSIS has moved medial, closer to the sacral midline External rotation moves the anterior ilium lateral and the PSIS medial. IN is the reverse.

8. Which contact corrects a left AS ilium in side posture?

A. The left PSIS, with the top hip only slightly flexed and the elbow lowered
B. The left ischial tuberosity, with the top hip flexed to about 90 degrees
C. The right ischial tuberosity, with the right side up and the hip extended
D. The left sacral base, with the patient prone and the drop piece set

B. The left ischial tuberosity, with the top hip flexed to about 90 degrees The ischial contact with more hip flexion rotates the ilium posteriorly. The PSIS contact is for PI.

9. On an exam, a patient has coccyx pain after a fall. Which approach is appropriate to demonstrate?

A. Internal technique with gloves, if the patient agrees
B. A side posture lumbar roll with a firm body drop
C. External technique over the drape with a chaperone offered
D. Simulated internal technique described step by step aloud

C. External technique over the drape with a chaperone offered Use external technique only. Internal technique would need scope verification, specific written consent and a chaperone.

10. A patient at 32 weeks reports a severe headache and seeing spots. Her blood pressure is 152/98. What is the correct action?

A. A low force side lying adjustment, then a referral
B. Supine soft tissue work to relieve the headache
C. A recheck of the blood pressure at the next visit
D. No manipulation and immediate obstetric referral

D. No manipulation and immediate obstetric referral New hypertension with headache and visual change suggests preeclampsia, an emergency referral, not a technique question.

CHAPTER 12

Extremity Set Ups

Read it in full: **Chapter 12 in the textbook**. Practice it: **the practice exams** and **the flashcards**.

What to know

Extremity adjustments restore **joint play**, the small passive accessory glides a joint needs for normal voluntary range. The patient cannot produce joint play; the doctor tests it with the joint relaxed. The missing glide is predicted by the **convex concave rule**. When a **convex** surface moves on a fixed concave one, roll and glide go in **opposite** directions (humeral head, femoral

head, proximal carpal row, talus). When a **concave** surface moves on a fixed convex one, they go the **same** way (tibial plateau, ulna, phalangeal bases, radial fovea). If the humerus will not abduct, the head must glide down; if the knee will not extend, the plateau must glide forward. Say the rule aloud so the examiner hears reasoning.

Know the resting (loose packed) positions, where joint play is tested and distraction is done: glenohumeral about 55 degrees abduction and 30 degrees horizontal adduction; humeroulnar about 70 degrees flexion and 10 degrees supination; radiocarpal neutral with slight ulnar deviation; hip about 30 degrees flexion, 30 degrees abduction and slight external rotation; knee about 25 degrees flexion; ankle about 10 degrees plantarflexion. Close packed positions are full abduction and external rotation at the shoulder, full extension with supination at the elbow, full extension, internal rotation and abduction at the hip, full extension with tibial external rotation at the knee, and full dorsiflexion at the ankle.

Screen the shoulder for dislocation and instability, fracture, a full thickness cuff tear, a painful freezing phase of adhesive capsulitis, and referral from the heart, lung apex, diaphragm, gallbladder and neck. Left shoulder pain with exertional chest pressure is cardiac until proven otherwise. Restricted **abduction** needs an **inferior glide**: supine, arm abducted to the start of the restriction, the web of the hand on the superior humeral head just lateral to the acromion, S to I along the glenoid. Restricted flexion or internal rotation needs a **posterior glide**; restricted extension or external rotation needs an **anterior glide**, which is avoided with anterior instability. General capsular restriction is treated with long axis distraction.

AC separations of grade I and II are conservative; grade III and above (step deformity, piano key sign, displacement on stress views) are imaged and referred, not adjusted. After healing, AC restriction is usually a superior or posterior distal clavicle. At the SC joint the common finding is an anterior medial clavicle. A **posterior SC displacement** after trauma, with hoarseness, dysphagia, dyspnea or venous congestion, is an emergency; never press posteriorly on a medial clavicle that is already posterior.

The elbow has three joints in one capsule. The radial head glides posteriorly with pronation and anteriorly with supination, so a **posterior radial head limits supination** and an **anterior radial head limits pronation**. Screen for supracondylar fracture in children (check the radial pulse and

the nerves), radial head fracture in adults (fat pad sign), dislocation, septic bursitis and ulnar nerve symptoms. The **pulled elbow** in a child of about 1 to 4 years follows a pull on the extended, pronated arm; reduction is hyperpronation or supination with flexion. A fall, swelling, bruising or point tenderness means radiographs first, and a child who does not use the arm soon after an attempt is referred for imaging.

At the wrist the convex carpals glide **dorsally for flexion** and **palmarly for extension**. Carpals are listed by displacement, most often dorsal; the capitate and lunate are most often addressed. A **dorsal capitate** is corrected with crossed thumbs, dorsal to palmar, with long axis traction (a whip). Snuffbox tenderness after a fall is a **scaphoid fracture** until proven otherwise: splint and reimage. A palmar lunate with median nerve symptoms is a dislocation needing emergency reduction. Exclude Colles and Smith fractures after a fall, and do not thrust an RA wrist with laxity. At the MCP and IP joints the concave base glides with the motion, and long axis distraction is the simplest technique. Flexor tenosynovitis (Kanavel signs) is a surgical emergency; a gamekeeper's thumb may need surgery.

Screen every hip for fracture (shortened, externally rotated leg after a fall; do not move it), femoral neck stress fracture, AVN, **SCFE** (an adolescent with a limp and obligatory external rotation on flexion; non weight bearing and urgent referral), Perthes disease (about 4 to 8 years), septic arthritis, a hip replacement and referred pain. The capsular pattern loses internal rotation most, then flexion and abduction. **Long axis distraction** in the resting position with the pelvis stabilized is the core technique; grasp above the malleoli, or the distal femur if the knee is unstable or painful, lean back to take up slack, then a quick shallow tug. The convex head glides posteriorly for flexion and internal rotation and anteriorly for extension and external rotation. A posterior approach replacement dislocates with flexion beyond 90 degrees, adduction and internal rotation, and a prosthetic hip is never thrust.

At the knee the concave tibia glides **anterior for extension** and **posterior for flexion**, with the screw home external rotation at terminal extension. Apply the **Ottawa knee rules** first. A tense effusion within about 2 hours is a hemarthrosis (ACL tear, fracture or patellar dislocation); a springy block to extension is a locked meniscus to refer; a hot, swollen knee with fever is septic until proven otherwise; calf pain and swelling raise DVT. Test the ligaments first, because the

glides are drawer tests in disguise: no anterior glide with a torn ACL, no posterior glide with a torn PCL.

A **posterior fibular head**, often after an inversion sprain, is corrected with a padded index MCP behind the head while the knee flexes over it, P to A. The **common fibular nerve** wraps the neck just below the head, so contact the head, never the neck, and check dorsiflexion, eversion and first web space sensation before and after. Patellar glides restore tracking: inferior for flexion and superior for extension; avoid lateral glides after a patellar dislocation.

At the ankle, the **Ottawa ankle and foot rules** decide imaging. Also screen for Achilles rupture (Thompson), a high ankle sprain, Lisfranc injury, stress fracture, Charcot foot in diabetes, gout, DVT and compartment syndrome; check pulses and sensation in every diabetic foot. The convex talus glides **posteriorly for dorsiflexion**; after an inversion sprain the talus is commonly anterior with limited dorsiflexion. The ankle tug (long axis distraction) is the foundation technique. **Cuboid syndrome** (a plantar cuboid) is corrected with the **cuboid whip**: prone, knee flexed about 70 to 90 degrees, overlapped thumbs on the plantar medial cuboid, plantar to dorsal at the end of a quick plantarflexion whip, after a fifth metatarsal base fracture and Lisfranc injury are excluded. A plantar navicular is driven plantar to dorsal after a navicular stress fracture is excluded. Hallux limitus is treated with distraction and a dorsal glide of the phalanx, never in an acute gout flare, and the forefoot is not squeezed over a Morton neuroma.

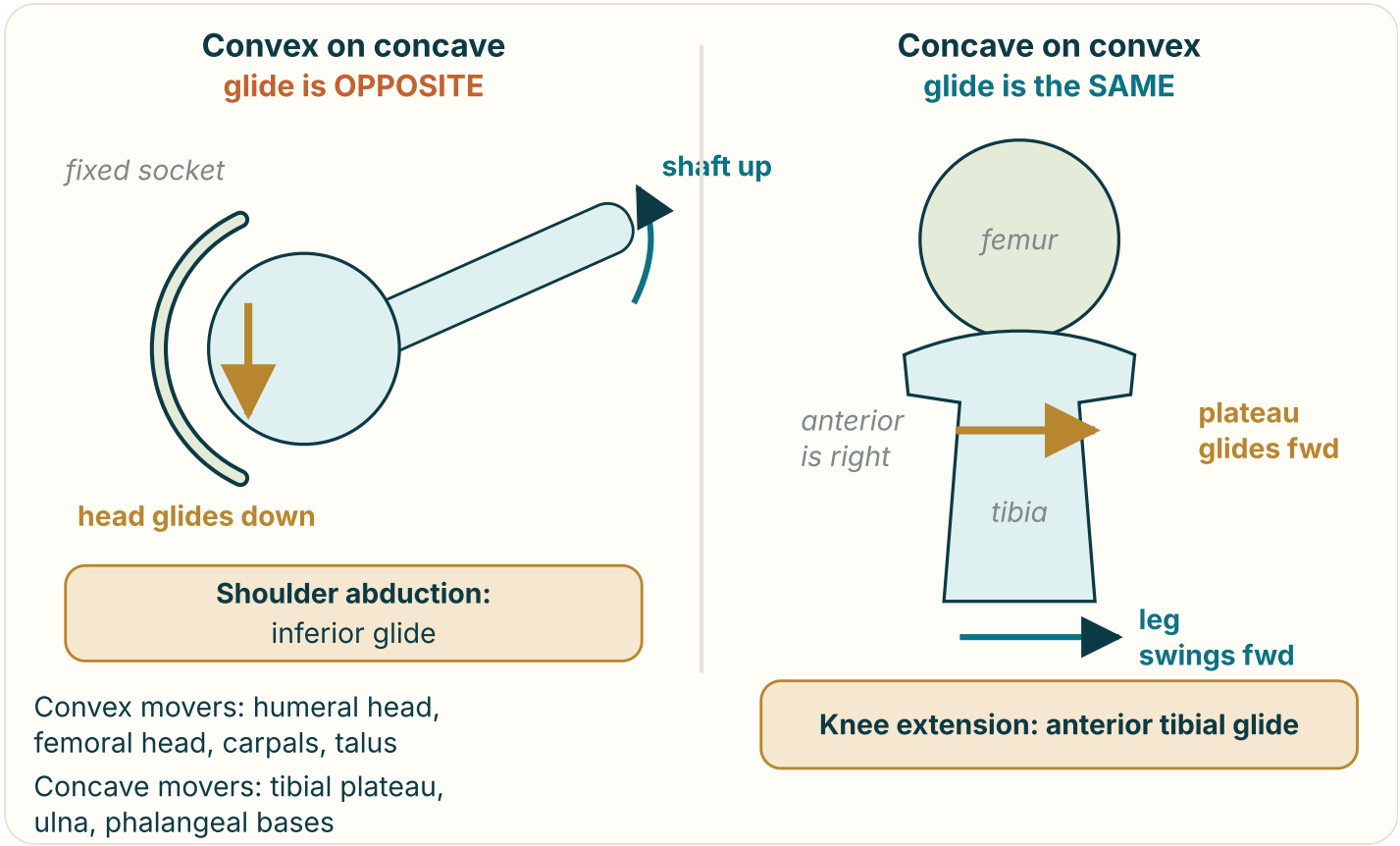

Which way does the joint glide? A convex surface glides opposite to the shaft; a concave surface glides the same way. Identify the moving partner and its shape, and the treatment glide follows.

LOCK THESE IN

- Convex moves: glide opposite. Concave moves: glide the same way.
- Shoulder abduction needs an inferior glide; flexion and internal rotation posterior; extension and external rotation anterior.
- Never press back on a posterior medial clavicle; posterior SC displacement is an emergency.
- Posterior radial head limits supination; anterior radial head limits pronation.
- Snuffbox tenderness: splint and reimage. Palmar lunate with median signs: emergency.
- Hip: distraction in the resting position; never thrust a prosthetic hip.
- Knee: test cruciates before tibial glides; contact the fibular head, not the neck.
- Talus glides posterior for dorsiflexion; cuboid whip plantar to dorsal after Ottawa and Lisfranc screens.

Glides and resting positions

Joint	Moving surface	Glide for the restriction	Resting position
Glenohumeral	Convex head	Abduction: inferior; flexion, IR: posterior; extension, ER: anterior	About 55 degrees abduction, 30 horizontal adduction
Humeroradial and radioulnar	Radial head	Supination limited: posterior head driven P to A	Elbow near extension for supination set up
Humeroulnar	Concave ulna	Long axis distraction	About 70 degrees flexion, 10 supination
Radiocarpal	Convex carpals	Flexion: dorsal glide; extension: palmar glide	Neutral, slight ulnar deviation
MCP and IP	Concave base	Flexion: palmar; extension: dorsal	Long axis distraction first
Hip	Convex head	Flexion, IR: posterior; extension, ER: anterior; abduction: inferior	About 30 flexion, 30 abduction, slight ER
Tibiofemoral	Concave tibia	Extension: anterior; flexion: posterior	About 25 degrees flexion
Talocrural	Convex talus	Dorsiflexion: posterior; plantarflexion: anterior	About 10 degrees plantarflexion
First MTP	Concave phalanx	Extension: dorsal glide	Distraction first

Screens before the contact

Region	Red flag or rule	Action
Shoulder	Exertional chest pressure with left shoulder pain	Cardiac until proven otherwise
AC joint	Step deformity, piano key sign, grade III or more	Image and refer
SC joint	Posterior displacement with hoarseness, dysphagia, dyspnea	Emergency
Child's elbow	Fall, swelling, point tenderness	Radiographs before any reduction
Wrist	Snuffbox tenderness after a fall	Splint and reimage
Hand	Kanavel signs	Surgical emergency
Hip	Shortened, externally rotated leg after a fall	Do not move it; emergency
Adolescent hip	SCFE signs	Non weight bearing, urgent referral
Knee	Ottawa knee rule; effusion within 2 hours; locked knee	Radiographs; refer
Fibular head	Foot drop, first web space numbness	Nerve injury; refer
Foot	Ottawa ankle and foot; warm red swollen diabetic foot	Radiographs; Charcot, refer

Worked cases

WORKED CASE 1 · TURNING A STIFF SHOULDER INTO A GLIDE

A 48 year old has 4 months of right shoulder stiffness with abduction limited to 110 degrees and a capsular end feel. Strength is normal, no trauma.

STEP 1 · SCREEN

Trauma, dislocation history, arm numbness, exertional chest symptoms, diabetes or thyroid disease, cancer and smoking; check apprehension.

STEP 2 · APPLY THE RULE

Abduction is restricted and the humeral head is convex, so it must glide inferiorly.

STEP 3 · SET UP

Supine, arm abducted to the start of restriction, web contact on the superior humeral head just lateral to the acromion, other hand holding the distal humerus.

STEP 4 · VERBALIZE

"Superior to inferior along the glenoid plane." Check in at tension, then reassess abduction.

WORKED CASE 2 · A DORSAL CAPITATE IN A CLIMBER

A 27 year old climber has dorsal central wrist pain and lost extension after a long session, with no fall. The dorsal capitate is prominent and tender.

STEP 1 · SCREEN FIRST

Snuffbox and scaphoid tubercle nontender; median nerve sensation intact; no swelling or inflammatory disease.

STEP 2 · NAME THE LISTING

Dorsal capitate.

STEP 3 · SET UP

Seated, forearm pronated, thumbs crossed over the dorsal capitate, fingers wrapping the palmar wrist.

STEP 4 · VERBALIZE

"Dorsal to palmar with long axis traction, taking the wrist from slight extension toward neutral." Plan radiographs if pain persists, since Kienböck disease stays on the list.

WORKED CASE 3 · LATERAL KNEE PAIN AFTER AN ANKLE SPRAIN

A 22 year old soccer player has lateral knee pain with running 3 weeks after an inversion sprain. The fibular head is tender and restricted in anterior glide. Ottawa rules and ligament tests are negative.

STEP 1 · CHECK THE NERVE FIRST

Dorsiflexion and eversion strength and first web space sensation are documented before contact.

STEP 2 · NAME THE LISTING

Posterior fibular head.

STEP 3 · SET UP

Supine, hip and knee flexed; padded index MCP behind the fibular head, not the neck; the other hand flexes the knee over the contact with slight external rotation.

STEP 4 · VERBALIZE AND RECHECK

"Posterior to anterior, the contact acting as a fulcrum." Recheck fibular motion, nerve function and the ankle that started the problem.

TRAPS PEOPLE FALL INTO

- **Gliding a convex joint the same way as the shaft.** Convex glides opposite.
- **Anterior shoulder glide with anterior instability.** Avoid it.
- **Pressing back on a posterior medial clavicle.** Exclude posterior SC dislocation first.
- **Reducing a pulled elbow after a fall.** Swelling or point tenderness means radiographs first.
- **Clearing a snuffbox on a normal film.** Splint and reimage.
- **Anterior tibial glide on a torn ACL.** That is an anterior drawer.
- **Contacting the fibular neck.** The common fibular nerve lies there.
- **Whipping the cuboid before the Ottawa and Lisfranc screens.** Screen first, aloud.

Chapter 12 self-test · ten items

1. The humerus will not abduct fully. Which glide does the convex rule predict?

A. A superior glide of the humeral head
B. An inferior glide of the humeral head
C. An anterior glide of the humeral head
D. A posterior glide of the humeral head

B. An inferior glide of the humeral head The convex head glides opposite to the shaft. The shaft rises in abduction, so the head must glide down.

2. The knee lacks full extension with intact cruciate ligaments. Which glide is indicated?

A. A posterior glide of the tibia
B. An inferior glide of the patella
C. A medial glide of the fibula
D. An anterior glide of the tibia

D. An anterior glide of the tibia The concave tibia glides the same way as the leg. Extension moves the tibia forward, so it needs an anterior glide.

3. After a fall on the shoulder, a patient has a medial clavicle displaced posteriorly with hoarseness. What is the correct action?

A. An anterior to posterior thrust on the clavicle
B. A sling and review in a week if no better
C. Emergency referral without posterior pressure
D. Superior to inferior glide of the clavicle

C. Emergency referral without posterior pressure A posterior SC displacement can compress the trachea, esophagus and great vessels. It is an emergency.

4. A posterior radial head tends to limit which motion?

A. Pronation
B. Elbow flexion
C. Wrist flexion
D. Supination

D. Supination The radial head glides anterior with supination, so a head fixed posterior limits supination.

5. A 3 year old stopped using an arm after being swung by the hands. There is no swelling or point tenderness. What fits best?

A. A radial head subluxation suitable for gentle reduction
B. A supracondylar fracture needing urgent radiographs
C. A septic elbow joint needing emergency referral
D. A posterior elbow dislocation needing a corrective thrust

A. A radial head subluxation suitable for gentle reduction A pull on the extended, pronated arm with little swelling fits a pulled elbow. A fall or swelling would mean radiographs first.

6. Which wrist glide restores flexion?

A. A dorsal glide of the proximal carpals
B. A palmar glide of the proximal carpals
C. A radial glide of the distal row
D. A long axis compression of the wrist

A. A dorsal glide of the proximal carpals The convex carpals glide opposite to the hand: dorsal glide for flexion, palmar glide for extension.

7. What is the resting position for hip long axis distraction?

A. Full extension with internal rotation and full abduction of the hip
B. About 90 degrees flexion with adduction and internal rotation of the hip
C. About 30 degrees flexion, 30 degrees abduction and slight external rotation
D. Neutral flexion with the knee locked straight and the pelvis left unbelted

C. About 30 degrees flexion, 30 degrees abduction and slight external rotation The resting position frees the capsule. Full extension, internal rotation and abduction is the close packed position.

8. A patient had a posterior approach hip replacement. Which hip position is most likely to dislocate it?

A. Extension with abduction and external rotation of the hip
B. Flexion beyond 90 degrees with adduction and internal rotation
C. Slight flexion with a pillow between the patient's knees
D. Prone lying with the knee flexed to ninety degrees on a pillow

B. Flexion beyond 90 degrees with adduction and internal rotation That position is also a posterior hip glide and an uncushioned side posture lock. Never thrust a prosthetic hip.

9. Where must the contact sit for a posterior fibular head set up?

A. On the fibular neck, below the head
B. On the fibular head, not the neck
C. On the lateral tibial plateau edge
D. On the distal fibula at the ankle

B. On the fibular head, not the neck The common fibular nerve wraps the neck just below the head. Pressure there risks foot drop.

10. Which statement about the cuboid whip is correct?

A. It drives plantar to dorsal on the plantar cuboid after Ottawa and Lisfranc screens
B. It drives dorsal to plantar on the dorsal cuboid during a dorsiflexion whip
C. It is the first choice for a warm, red and swollen foot in a person with diabetic neuropathy
D. It is used to reduce a fifth metatarsal base fracture after an inversion sprain

A. It drives plantar to dorsal on the plantar cuboid after Ottawa and Lisfranc screens The thumbs on the plantar medial cuboid deliver a plantar to dorsal thrust at the end of a quick plantarflexion whip, after fracture and Lisfranc are excluded.

Cram sheet

Everything from chapters 11 and 12 in one place. Cover the right column and see if you can rebuild each row.

Lumbopelvic rules

Item	The rule	Note
Six parts	Listing, position, stance, contacts, stabilization, line of drive	Said aloud in order
Side posture side	Posterior body side up	Spinous right: left side up
Lock	Bottom leg straight; top hip flexed until the target space opens; trunk rotated back	Thigh on the top knee
Mammillary push	Up side mammillary, P to A along the facet plane	Body drop
Spinous pull	Down side of spinous, toward the ceiling	Same side down
Leg pain at the lock	Stop, release, neutral, neuro recheck	Change approach
Other tools	Acute disc, osteoporosis, pregnancy, spondylolisthesis, fusion, hip replacement	Prone drop, flexion distraction, instruments
Flexion distraction	Spinous above the disc; tolerance test first	Peripheralization stops it
PI ilium	PSIS low, short leg; PSIS contact P to A, I to S	Involved side up
AS ilium	PSIS high, long leg; ischial contact, hip about 90	P to A, slight I to S
IN and EX	PSIS lateral; PSIS medial	PI EX, AS IN
SI cluster	3 or more of 5 provocation tests	Gillet, standing and seated flexion
Coccyx	External only, over the drape, chaperone	Internal: scope, written consent
Pregnancy	Side lying, low force, tilt left if supine	Preeclampsia: emergency referral

Extremity glides

Joint	Restriction	Glide
Shoulder	Abduction	Inferior
Shoulder	Flexion or internal rotation	Posterior
Shoulder	Extension or external rotation	Anterior (not with instability)
Radial head	Supination limited	Posterior head driven P to A
Wrist	Flexion; extension	Dorsal; palmar
Hip	Flexion and IR; extension and ER	Posterior; anterior
Knee	Extension; flexion	Anterior tibia; posterior tibia
Fibular head	Posterior	P to A on the head, not the neck
Ankle	Dorsiflexion	Posterior talus
Cuboid	Plantar	Plantar to dorsal whip
First MTP	Extension	Dorsal glide of the phalanx

Red flags before extremity work

Finding	Meaning
Exertional chest pressure with left shoulder pain	Cardiac
Posterior SC with hoarseness or dysphagia	Emergency
Snuffbox tenderness	Scaphoid fracture until proven otherwise
Palmar lunate with median signs	Dislocation, emergency
Shortened, externally rotated leg after a fall	Hip fracture
Adolescent limp, obligatory ER	SCFE
Effusion within 2 hours	Hemarthrosis
Springy block to extension	Locked meniscus
Foot drop after knee injury	Fibular nerve injury
Warm, red, swollen diabetic foot	Charcot neuroarthropathy

Dr. Garg Learning · CC BY-SA 4.0