Study Guide 5

This guide covers the first half of technique. Chapter 9 gives you the seven elements of every set up, the listing systems and the two rules that settle almost every side of contact question, plus preload, safety and the errors that cost the most points. Chapter 10 applies them to the occiput, atlas, lower neck, cervicothoracic junction, thoracic spine and ribs. Read the "what to know" paragraphs, study the diagram, then say each worked set up aloud in the fixed order with the steps covered.

WHAT THIS GUIDE COVERS

- Chapter 9 · the seven elements, reading the door card, a station script, Palmer Gonstead, atlas and National listings, contact side rules, facet planes, end feel, the phases of an HVLA thrust, cavitation, why stations stop at preload, contraindications, consent and the stop rule, the rule of threes and common errors.
- Chapter 10 · upper cervical anatomy and the vertebral artery, occiput and atlas set ups, ASRP, lower cervical rotary and lateral flexion set ups, locking, cervicothoracic level tests and the thumb move, prone and supine thoracic set ups, modifications, rib anatomy and motion, rib angle and first rib set ups, and rib red flags.

CHAPTER 9

Technique Station Principles and Scoring

Read it in full: **Chapter 9 in the textbook**. Practice it: **the practice exams** and **the flashcards**.

What to know

A technique station scores whether your hands and words match a correct plan. The door card usually gives age, complaint, region, a listing or motion finding, and the task, such as "set up and verbalize an adjustment for the listed segment." Examiners score observable behaviors: where the patient lies, where you stand, which part of your hand touches which part of the vertebra, what your other hand does, the intended direction, and whether you said it. A silent, elegant set up can lose to a slower, fully narrated one. Read the current candidate materials for the exact rules.

Every diversified style set up has **seven elements**, said in the same order: **listing**, **patient position**, **doctor stance**, **contact point** (the part of your hand: pisiform, thenar, index MCP, thumb), **segmental contact** (the part of the vertebra: spinous, transverse process, lamina, articular pillar, mammillary, rib angle), **stabilization** (the indifferent hand, table or patient position fixing what should not move) and **line of drive** in anatomical terms (P to A, L to M, I to S). The safety screen and consent come before them; preload and the spoken thrust come after. The most common scoring loss is not a wrong element but a missing one you performed and never said.

Use the door card time for three decisions: what the listing means in motion terms, which set up fits the region and the patient (age, osteoporosis or pregnancy may change it), and whether anything says do not adjust. If the card holds a red flag, the station may be testing whether you recognize it, and the correct performance is to explain why you will not adjust and what you will do instead.

A listing is shorthand for one fault written three ways. **Palmer Gonstead** describes the spinous: P for posterior body, then R or L for the side the spinous rotated toward, then S or I for whether that side is open or closed. **National** describes the body: flexion, extension, lateral flexion, rotation. **Motion palpation** names the restricted motion. The key fact: **the spinous and the body rotate in opposite directions**. PR means spinous right, body rotated left, right rotation restricted. If a card is ambiguous, state your reading aloud before you set up. Some cervical Gonstead analysis names the side of posterior body rotation instead.

The atlas has no true spinous, so its listing describes the ring: AS or AI for the tilt of the anterior tubercle, then laterality (R or L), then A or P for rotation on that same side. **ASRP** means anterior superior, laterality right, and the right side has rotated posterior; in National terms the atlas is translated right and rotated right.

Two rules settle almost every side question. **Transverse, lamina, pillar and mammillary contacts go on the side of posterior body rotation**, opposite the spinous, driven P to A. **Spinous contacts go on the side toward which the spinous rotated**, pushed back toward midline, L to M. For a cervical lateral flexion restriction, contact the side toward which you want lateral flexion, flex the head over the contact, and drive L to M. The facet plane sets the angle: lower cervical facets sit about 45 degrees, so the drive is P to A and slightly I to S ("toward the opposite eye");

thoracic facets sit about 60 degrees, close to frontal, so the drive is mainly P to A with a small I to S component following the kyphosis; lumbar facets sit near sagittal, so side posture adds rotation. C1 to C2 provides about half of cervical rotation.

Motion palpation moves the segment through each plane. A normal joint has a slightly springy end feel. A fixated joint has a hard, abrupt end feel with reduced play. A soft, boggy end feel suggests an acute or inflammatory process. An **empty end feel**, where the patient stops you before tissue resistance, suggests a serious lesion and is a reason to stop and evaluate.

An HVLA adjustment runs **positioning**, **tissue pull**, **preload** to joint tension, a fast short **impulse** (about a tenth of a second or a little more), and **resolution**. Thrusting through slack lets soft tissue absorb the force and pinches skin. Too little preload means a long, uncomfortable, unspecific move; too much makes the patient brace. Speed comes from the trunk and often a body drop, with elbows slightly flexed and locked and shoulders over the contact. **Cavitation** is gas forming as the joint gaps; the refractory period is roughly 15 to 20 minutes, the sound does not prove the target joint moved, and improvement does not depend on it. At the station, go to preload, hold, and describe the thrust; never deliver it, and never stop short of preload.

Every technique station is a safety station. **Absolute** contraindications to HVLA at the region include acute fracture or dislocation, ligamentous instability (RA, Down syndrome, os odontoideum), suspected cervical artery dissection, tumor or infection at the site, acute myelopathy and cauda equina syndrome. **Relative** ones include osteoporosis, anticoagulants, an acute inflammatory flare, recent surgery or fusion, disc herniation with progressive deficit, pregnancy and hypermobility. Positional vertebral artery tests have poor sensitivity; history and a neurologic screen are the key, and a negative test never makes manipulation safe.

Consent at the station names the procedure, the pop, common risks (soreness or stiffness for a day or two), the rare serious risk for the region (dissection for the neck, rib fracture with low bone density for thoracic and rib work), alternatives and the right to stop, then asks a direct question. Drape, explain before touching near the chest, gluteal region or pelvis, and offer a chaperone. Watch the face and breathing through preload. If the patient reports dizziness, visual change, nausea, numbness or sharp pain, stop, release slowly, return to neutral, keep a dizzy patient lying

down, and reassess vitals and a neurologic screen. Any neurologic sign means emergency referral. A safe "no" is a correct answer.

Common errors: wrong level or side, a soft contact or one on muscle, a line of drive that fights the facet plane, excessive cervical rotation, a floating stabilizing hand, poor table height, no preload, an actual thrust, a missing screen and silent performance. Count from two landmarks: C7 by the extension test and the inferior scapular angle at about T7. Use the **rule of threes**: T1 to T3 spinous tips sit at their own TPs, T4 to T6 halfway, T7 to T9 at the TPs of the vertebra below, T10 as T7 to T9, T11 halfway and T12 at its own. Use a two track script: plain words to the patient, precise terms to the examiner. If you catch an error, correct it aloud.

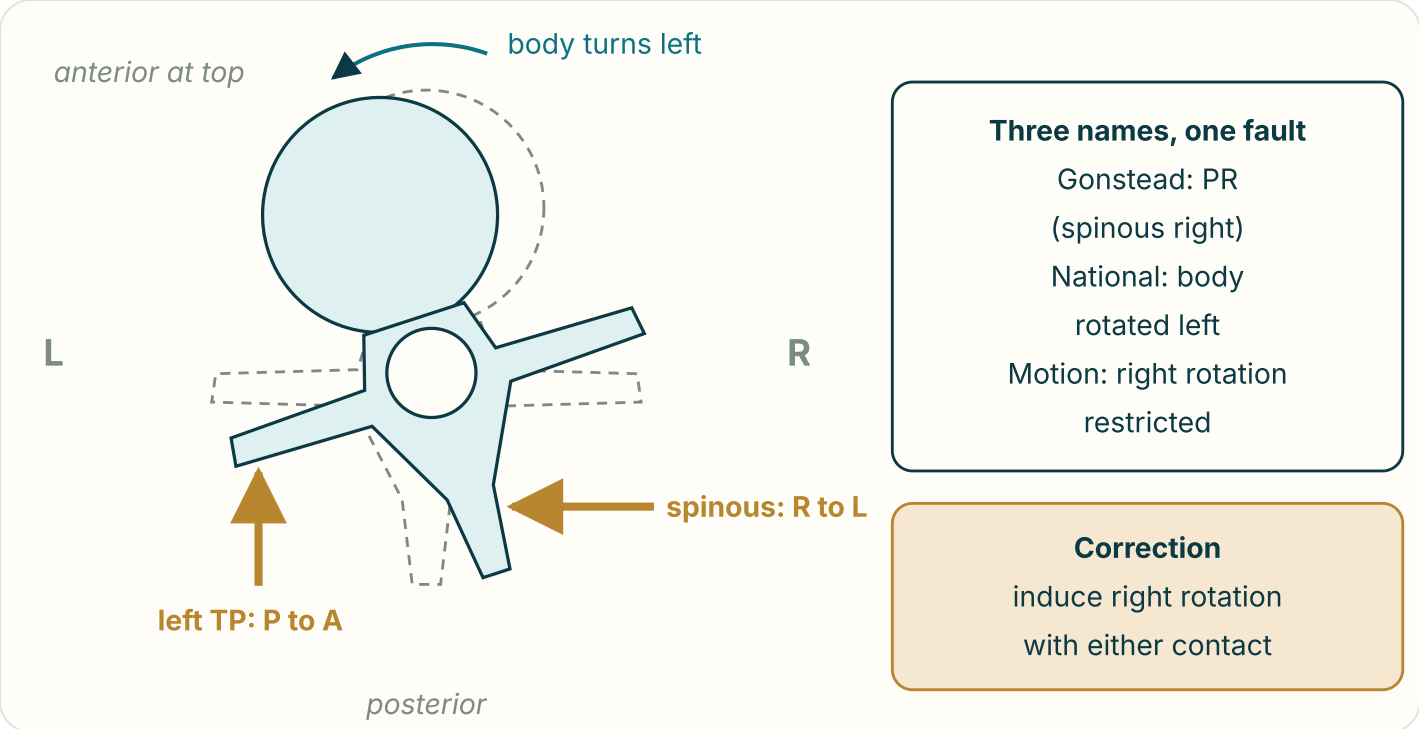

One fault, three names. When the spinous swings right (PR), the body turns left and the left transverse process becomes posterior. A P to A drive on the left TP, or an R to L push on the spinous, induces the restricted right rotation.

LOCK THESE IN

- Seven elements in order: listing, patient position, stance, contact point, segmental contact, stabilization, line of drive.
- Spinous and body rotate in opposite directions.
- TP, lamina, pillar and mammillary contacts go on the posterior body side; spinous contacts go on the spinous side.
- Cervical drive P to A and slightly I to S, toward the opposite eye; never end range rotation.
- Positioning, tissue pull, preload, impulse, resolution; at the station stop at preload and describe the thrust.
- Cavitation refractory period about 15 to 20 minutes; the pop is not the goal.
- Rule of threes: T7 to T9 spinous tips sit at the TPs of the vertebra below.
- A safe "no" for a red flag is a correct performance.

Listing translations

Gonstead	Spinous	National (body)	Restricted motion	Typical contact
PR	Right	Rotated left	Right rotation	Left TP P to A, or right side of spinous R to L
PL	Left	Rotated right	Left rotation	Right TP P to A, or left side of spinous L to R
PRS	Right, right side open	Left rotation, left lateral flexion	Right rotation and right lateral flexion	As PR, S component as taught
PRI	Right, right side closed	Left rotation, right lateral flexion	Right rotation and left lateral flexion	As PR, I component as taught
P	Posterior, no rotation	Flexion	Extension	Bilateral TPs, P to A
Anterior thoracic	Approximated	Extension	Flexion	Supine anterior thoracic below the segment
ASRP (atlas)	Ring tilted up, right lateral	Translated right, rotated right	Left rotation	Right posterior arch near the TP

Regions and rules

Region or rule	Value	Effect
Lower cervical facets	About 45 degrees	Drive P to A and slightly I to S
Thoracic facets	About 60 degrees, near frontal	Mainly P to A, small I to S, follow kyphosis
Lumbar facets	Near sagittal	Side posture with rotation
C1 to C2	About half of cervical rotation	Minimal force and head rotation
Rule of threes T1 to T3	Spinous at own TPs	TPs beside the spinous
Rule of threes T4 to T6	Halfway	TPs half a level above the tip
Rule of threes T7 to T10	At TPs of the vertebra below	TPs a full level above the tip
Rule of threes T11, T12	Halfway; own TPs	As T4 to T6; as T1 to T3
Impulse	About a tenth of a second or a little more	Fast, short, from the trunk
Cavitation refractory	About 15 to 20 minutes	Do not chase the pop
End feel	Springy normal; hard fixated; boggy acute; empty serious	Empty means stop and evaluate

Worked cases

WORKED CASE 1 · FROM A MOTION FINDING TO A CONTACT

T6 is restricted in right rotation in a 34 year old with mid back pain after moving house. No red flags. Task: prone set up.

STEP 1 · TRANSLATE

Right rotation restricted means the body is held in left rotation, so the spinous has swung right (Gonstead PR) and the left TP is posterior.

STEP 2 · SCREEN AND CONSENT

Trauma, osteoporosis, fever, weight loss, chest pain or shortness of breath, since mid back pain can be visceral. Explain soreness is common and rib injury rare.

STEP 3 · STATE THE SET UP

Prone, arms at the sides, table about mid thigh, fencer stance on the left. Contact point right pisiform; segmental contact left TP of T6; stabilization left hand over the contact.

STEP 4 · PRELOAD AND VERBALIZE

Tissue pull, preload to tension, then "P to A and slightly I to S, inducing right rotation." Release and say you would reassess.

WORKED CASE 2 · FINDING T8 WITH THE RULE OF THREES

Task: prone bilateral transverse set up for T8 with an extension restriction (Gonstead P). You find the inferior scapular angle at about the T7 spinous.

STEP 1 · COUNT

The inferior angle sits at about T7, so the next spinous down is T8.

STEP 2 · APPLY THE RULE

T7 to T9 spinous tips sit at the level of the TPs of the vertebra below. So the T8 TPs lie at about the level of the T7 spinous tip, one full level above the T8 tip.

STEP 3 · CONTACT

Crossed pisiforms on the right and left TPs of T8, tissue pull superiorly, preload at the end of exhalation.

STEP 4 · VERBALIZE

"A shallow body drop thrust, P to A and slightly I to S, to induce extension at T8." No actual thrust; release and reassess.

WORKED CASE 3 · THREE ERRORS IN ONE SET UP

C4 has a left lateral flexion restriction. A classmate contacts the right pillar, turns the head 70 degrees left and says the drive is "straight down toward the table."

STEP 1 · FIX THE SIDE

Lateral flexion contacts go on the side toward which you want lateral flexion: the left articular pillar, with the head laterally flexed left over it.

STEP 2 · FIX THE ROTATION

Use only slight rotation, never 70 degrees, which approaches end range and adds vascular and joint stress.

STEP 3 · FIX THE DRIVE

The line of drive is L to M, left to right through the pillar, not into the table.

STEP 4 · SAY IT

"Contact point left index MCP; segmental contact left pillar of C4; stabilization right hand cradling the occiput; line of drive L to M, inducing left lateral flexion," after the dissection screen and consent.

TRAPS PEOPLE FALL INTO

- **Contacting the TP on the spinous side.** For PR, the posterior TP is on the left.
- **Missing a level in the mid thoracic spine.** Use the rule of threes.
- **Driving straight down in the neck.** Follow the 45 degree facet plane, P to A and slightly I to S.
- **Rotating the neck to end range before preload.** Rotate only to take up slack at the level.
- **Letting the stabilizing hand float.** Name it and make it hold.
- **Verbalizing the thrust from slack.** Tissue pull and preload come first.
- **Delivering a real thrust.** Stop at preload and describe it.
- **Trusting a negative vertebral artery test.** It does not make manipulation safe.

Chapter 9 self-test · ten items

1. A door card lists T5 PL. Which statement is correct?

A. The body has rotated left, so right rotation is restricted
B. The body has rotated right, so left rotation is restricted
C. The spinous has rotated right, so the left TP is posterior
D. The segment is in flexion, so extension is restricted

B. The body has rotated right, so left rotation is restricted PL means spinous left. The body rotates the opposite way, to the right, so the right TP is posterior and left rotation is restricted.

2. For a T7 PR listing using a transverse contact, where does the pisiform go?

A. On the right transverse process of T7
B. On the left transverse process of T7
C. On the left side of the T7 spinous
D. On the right transverse process of T8

B. On the left transverse process of T7 Transverse contacts go on the side of posterior body rotation, opposite the spinous. Spinous right means body left, so the left TP is posterior.

3. For a spinous contact on a T4 PR listing, which way is the push?

A. Left to right on the left side of the spinous
B. Posterior to anterior on the right TP
C. Inferior to superior on the left TP
D. Right to left on the right side of the spinous

D. Right to left on the right side of the spinous Spinous contacts go on the side toward which the spinous has rotated and push it back toward the midline.

4. What does the atlas listing ASRP describe?

A. Anterior superior tilt, laterality right, right side rotated anterior
B. Anterior inferior tilt, laterality right, left side rotated posterior
C. Anterior superior tilt, laterality right, right side rotated posterior
D. Anterior superior tilt, laterality left, right side rotated posterior

C. Anterior superior tilt, laterality right, right side rotated posterior The letters give tilt, the side of laterality, then the rotation of that same side.

5. Which line of drive best fits a lower cervical rotary set up?

A. P to A and slightly I to S, toward the opposite eye
B. Straight down into the table, posterior to anterior
C. P to A and slightly S to I, away from the opposite eye
D. Pure lateral to medial with the head in full extension

A. P to A and slightly I to S, toward the opposite eye Lower cervical facets slope about 45 degrees, so the drive glides along the plane rather than compressing the joint.

6. What is the main purpose of preload before a verbalized thrust?

A. To produce the audible cavitation before the thrust
B. To remove tissue slack and bring the joint to tension
C. To stretch the paraspinal muscles for a few minutes first
D. To test the vertebral artery before any manipulation

B. To remove tissue slack and bring the joint to tension Thrusting from slack lets soft tissue absorb the force. Preload takes the joint to its elastic barrier.

7. A joint cavitated two minutes ago. What should you expect if you thrust again at once?

A. It will cavitate more loudly because the joint has loosened
B. It must cavitate again for the adjustment to be effective
C. It will cavitate only if more rotation is added to the set up
D. It usually cannot cavitate again for about 15 to 20 minutes

D. It usually cannot cavitate again for about 15 to 20 minutes After cavitation there is a refractory period. Chasing the pop with repeated thrusts is poor practice.

8. Where do the transverse processes of T8 lie relative to its spinous tip?

A. At the same level as the tip
B. About half a level above the tip
C. About one full level above the tip
D. About one full level below the tip

C. About one full level above the tip By the rule of threes, T7 to T9 spinous tips sit at the level of the TPs of the vertebra below.

9. During cervical preload the patient says she feels dizzy. What do you do first?

A. Release, return the head to neutral and keep her lying down
B. Hold the preload briefly to see whether the dizziness passes
C. Reduce rotation slightly and continue to the thrust phase
D. Sit her up quickly so that she can regain her balance

A. Release, return the head to neutral and keep her lying down Stop, release and keep a dizzy patient supine. Then check speech, pupils, eye movements, coordination and vitals.

10. On motion palpation the patient stops you before any tissue resistance is felt. What does this empty end feel suggest?

A. A normal joint with a slightly springy end feel at the barrier
B. A fixated joint that needs a stronger thrust
C. A possible serious lesion; stop and evaluate further
D. An acute strain that responds to more preload

C. A possible serious lesion; stop and evaluate further An empty end feel suggests a serious lesion and is a reason to stop and investigate.

Cervical and Thoracic Set Ups

Read it in full: **Chapter 10 in the textbook**. Practice it: **the practice exams** and **the flashcards**.

What to know

The upper cervical complex is built for motion, not load. The atlanto-occipital joints are cup shaped and move mainly in flexion and extension, the "yes" motion. The atlantoaxial joints allow large rotation, about half of all cervical rotation (roughly 40 degrees each way), checked by the alar ligaments, while the transverse ligament holds the dens against the anterior arch. The vertebral artery enters the transverse foramina usually at C6, passes through the atlas foramen and loops over the posterior arch. Rotation, especially with extension, stretches the opposite artery at that loop. So upper cervical set ups use **minimal rotation**, avoid end range, **never combine rotation with extension**, and use a precise, shallow impulse.

Screen for instability before any upper cervical work: rheumatoid arthritis, Down syndrome, inflammatory spondyloarthropathy, recent trauma, os odontoideum and congenital anomalies can weaken the transverse ligament or the dens and make HVLA contraindicated. Also screen for dissection: trauma, sudden unusual headache or neck pain, and the 5 D's and 3 N's.

The atlas listing **ASRP** means the anterior tubercle is tipped superior, the atlas has slipped right, and its right side is posterior. In diversified terms you contact the right side of the atlas, correct right laterality with an L to M component and correct the right posterior rotation with a P to A component. In the supine atlas set up, the lateral index MCP sits on the posterior arch on the posterior side, in the groove between the occiput and the C2 spinous; the other hand cradles the opposite occiput; the head turns away only about 30 degrees with slight lateral flexion toward the contact; and the drive is P to A, slightly L to M, toward the opposite eye. An occiput flexion restriction uses a bilateral occipital lift, I to S. Toggle recoil and instrument methods are alternatives when HVLA is relatively contraindicated or declined.

From C2 to C7 the segmental contact is the **articular pillar**, about 1.5 to 2 cm lateral to the spinous and posterior to the transverse processes, or the lamina in seated Gonstead work. The contact point is the lateral surface of the proximal phalanx at the index MCP. The transverse

processes carry the vertebral artery and are not HVLA contacts. The **rotary set up** contacts the pillar on the posterior body side (opposite the spinous), rotates the head away about 30 to 45 degrees, never to end range, adds slight lateral flexion toward the contact, and drives P to A and slightly I to S toward the opposite eye. The **lateral flexion set up** contacts the pillar on the side toward which flexion is restricted, bends the head over the contact as a fulcrum, adds a little rotation away, and drives L to M. It uses less rotation, which suits anxious patients.

In the lower cervical spine, lateral flexion and rotation couple to the same side. **Locking** combines lateral flexion toward the contact with rotation away, a non physiological pairing, so the levels above reach tension first and motion stays at the target level with less total rotation and force.

From C6 to T3 the mobile neck meets the stiff thorax, the shoulders pile up soft tissue, and the brachial plexus and subclavian vessels cross the first rib. Ask about arm symptoms and thoracic outlet signs first. Confirm levels with two tests: on passive extension, C6 moves forward and fades, C7 moves slightly, and T1 does not move; on rotation C7 moves more than T1. The **prone thumb move** for a rotated C7 to T2 puts the thumb on the side of the spinous toward which it rotated, with the other hand laterally flexing the head toward the contact to bring tension down, and the drive L to M with a slight P to A component. The swimmer's position raises one arm overhead to rotate the scapula away. Rotating the head to end range to "reach" T1 is unnecessary and unsafe.

The thoracic facets sit about 60 degrees, near the frontal plane, favoring rotation and lateral flexion. Spinous processes angle down, so use the rule of threes. A thoracic thrust loads the rib joints, the region is the commonest site of osteoporotic fracture, and mid back pain is a classic visceral presentation. **Prone bilateral transverse** contacts on one vertebra induce **extension**, P to A and slightly I to S with a body drop at end exhalation. **Crossed bilateral** contacts (posterior TP of the involved vertebra and the opposite TP of the vertebra below), a **unilateral transverse** contact on the posterior TP, or a **spinous push** on the side of spinous rotation induce **rotation**. For T6 PR, contact the left TP of T6 and the right TP of T7.

The **supine anterior thoracic** set up induces **flexion** for a segment fixed in extension, for patients who cannot lie prone, or when a body drop is too forceful. Arms are crossed over the chest, elbows stacked; the contact hand lies under the **lower vertebra** of the restricted segment as the

fulcrum; the doctor's chest drives A to P through the elbows, angled slightly S to I toward the fulcrum. Putting the fulcrum at the listed vertebra itself is a common error. Modify for osteoporosis or long term steroids (no body drops or supine thrusts through the ribs), breast tissue (a pillow or flat hand barrier), pregnancy (support cushions or side lying) and painful shoulders (a rolled towel).

Typical ribs (2 to 9) have a head articulating with two vertebral bodies and a tubercle articulating with the transverse process of the lower one. Ribs 1, 10, 11 and 12 articulate with one body, and 11 and 12 have no costotransverse joint. Upper ribs move in **pump handle** fashion, lower ribs in **bucket handle**, and 11 and 12 like calipers. An inhalation restriction (exhaled rib) is held down; an exhalation restriction (inhaled rib) is held up. The **rib angle** is the usual posterior contact, lateral to the TP by about two to three finger widths, driven P to A with a lateral and slightly inferior component along the rib at end exhalation. A pisiform on the TP adjusts the vertebra, not the rib. The elevated **first rib** is contacted on its superior surface behind the clavicle, with the head laterally flexed toward the contact to slacken the scalenes, and driven S to I and slightly L to M toward the opposite hip with a light impulse.

Rule out red flags before any rib thrust: exertional chest, arm or jaw pain (ischemia), sudden pleuritic pain with dyspnea or a swollen calf (embolism), sudden pleuritic pain in a tall thin young person (pneumothorax), point tenderness after trauma or with osteoporosis (fracture), dermatomal band pain before a rash (zoster), and constant night pain with a cancer history (metastasis).

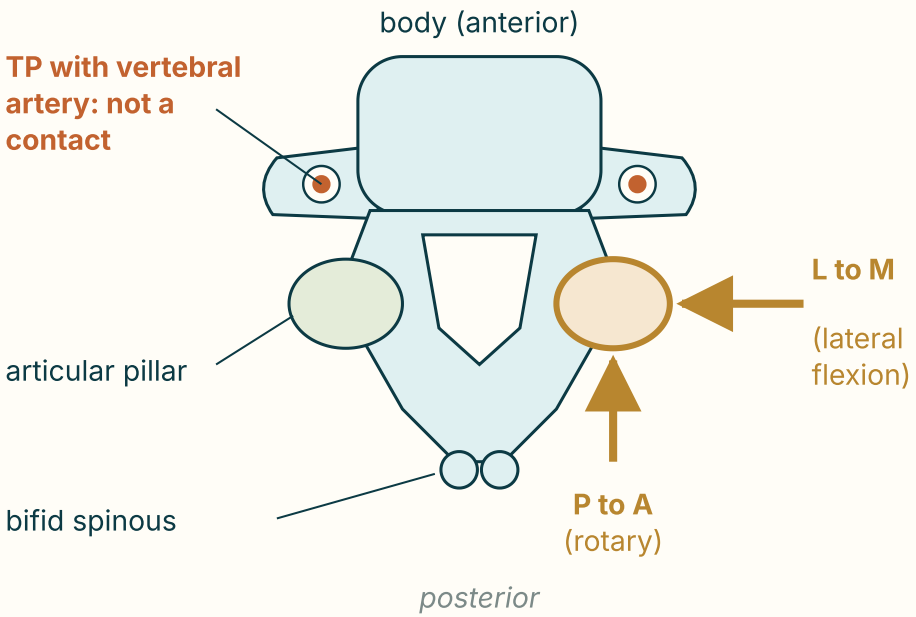

Pillar contacts in the lower neck. The articular pillar is the standard segmental contact. The rotary set up drives it P to A toward the opposite eye; the lateral flexion set up drives it L to M. Transverse processes carry the vertebral artery and are not HVLA contacts.

LOCK THESE IN

- Upper cervical: minimal rotation, no end range, never rotation with extension; screen for instability and dissection.
- ASRP: contact the right side of the atlas; L to M for laterality, P to A for rotation.
- Lower cervical contact is the articular pillar; TPs carry the artery and are not contacts.
- Rotary: posterior body side, toward the opposite eye. Lateral flexion: the side to flex, L to M.
- Lock above: laterally flex toward the contact, rotate away.
- Thumb move: spinous side, head laterally flexed toward the contact.
- Bilateral TP for extension; crossed bilateral, unilateral TP or spinous push for rotation; supine anterior thoracic for flexion with the fulcrum under the lower vertebra.
- Rib angle is lateral to the TP; first rib drive is S to I toward the opposite hip.

Set ups by region

Set up	Contact	Line of drive
Supine atlas (ASRP)	Right index MCP on right posterior arch of C1	P to A, slightly R to L, toward the left eye
Occiput flexion restriction	Both hands cupping the occiput	I to S traction with slight flexion
Lower cervical rotary (C5 left rotation restriction)	Right index MCP on right pillar	P to A, slightly I to S, toward the left eye
Lower cervical lateral flexion (C4 left LF restriction)	Left index MCP on left pillar	L to M (left to right)
Prone thumb move (T1 PR)	Thumb on right side of T1 spinous	R to L, slight P to A
Prone bilateral transverse (T8 extension restriction)	Crossed pisiforms on both T8 TPs	P to A, slightly I to S, end exhalation
Crossed bilateral (T6 PR)	Left TP of T6 and right TP of T7	P to A, slightly I to S
Unilateral transverse (T9 PL)	Pisiform on right TP of T9	P to A, slightly I to S
Supine anterior thoracic (T5 to T6 flexion restriction)	Hand under T6 TPs as fulcrum	A to P through the elbows, slightly S to I
Prone rib angle (right rib 6)	Pisiform on right rib 6 angle	P to A, lateral and slightly inferior, end exhalation
First rib, supine (right)	Right index MCP on superior surface of first rib	S to I, slightly L to M, toward the left hip

Anatomy that sets the rules

Item	Value	Why it matters
C1 to C2 rotation	About half of cervical rotation, about 40 degrees each way	Rotation happens at the atlas
Vertebral artery	Enters at C6, loops over C1 posterior arch	Rotation with extension stretches it
Pillar location	1.5 to 2 cm lateral to the spinous	Posterior to the TPs
Lower cervical coupling	Lateral flexion and rotation to the same side	Basis of locking
Level tests	Extension: C6 fades, C7 moves slightly, T1 still	Two tests before contact
Thoracic facets	About 60 degrees, near frontal	Rotation and lateral flexion
Rib joints	Head with two bodies; tubercle with lower TP	Ribs 1, 10, 11, 12 with one body
Rib motion	Pump handle upper; bucket handle lower; caliper 11 and 12	Breathing restrictions
Rib angle	2 to 3 finger widths lateral to the TP	Pisiform on the TP moves the vertebra

Worked cases

WORKED CASE 1 · SETTING UP ASRP

A 29 year old with suboccipital headaches has a prominent, tender right atlas TP and a posterior right side of C1. Listing ASRP. Screen negative.

STEP 1 · TRANSLATE

Anterior superior, laterality right, right side posterior. Both corrections point to the right side of the atlas.

STEP 2 · SCREEN AND CONSENT

5 D's and 3 N's, sudden headache, injury, inflammatory disease, Down syndrome, anticoagulants; the rare risk of arterial injury.

STEP 3 · SET UP

Supine, neck neutral, fencer stance at the head on the right. Right index MCP on the right posterior arch near the TP; left hand cradles the left occiput; head rotated left only about 30 degrees with slight right lateral flexion.

STEP 4 · VERBALIZE

"A shallow HVLA thrust, P to A and R to L, toward the left eye, correcting right laterality and right posterior rotation." Release, reassess.

WORKED CASE 2 · ROTARY OR LATERAL FLEXION?

A 46 year old teacher has right neck pain after sleeping awkwardly and is anxious about "neck cracking." C5 is restricted in right lateral flexion. Screen negative.

STEP 1 · ADDRESS THE ANXIETY

Explain the pop as gas release, the common and rare risks, and offer mobilization, instrument adjusting or soft tissue work.

STEP 2 · CHOOSE THE SET UP

A lateral flexion set up fits the listing and the anxiety because it uses little rotation.

STEP 3 · SET UP

Right index MCP on the right pillar of C5; left hand cradles the occiput; head laterally flexed right over the contact with slight left rotation to lock above.

STEP 4 · VERBALIZE OR ACCEPT A REFUSAL

"A shallow HVLA thrust, L to M from right to left, inducing right lateral flexion at C5." If she declines, document the refusal and use the alternative.

WORKED CASE 3 · WHERE THE FULCRUM GOES

A 52 year old has a flexion restriction between T5 and T6 (T5 held in extension on T6). Task: supine anterior thoracic set up. No osteoporosis.

STEP 1 · FIND THE SEGMENT

The restricted motion segment is T5 on T6. The upper vertebra (T5) is the one that moves.

STEP 2 · PLACE THE FULCRUM

Under the lower vertebra, T6, with the thenar and flexed fingers on the two TPs and the spinous in the gap.

STEP 3 · POSITION

Arms crossed, elbows stacked, upper trunk slightly flexed over the fulcrum, the other hand supporting the head.

STEP 4 · VERBALIZE

"A to P through the crossed arms, angled slightly S to I toward the fulcrum, inducing flexion of T5 on T6."

TRAPS PEOPLE FALL INTO

- **Rotating the neck to end range.** Take up slack only; about 30 degrees at the atlas.
- **Combining rotation with extension.** That stretches the vertebral artery loop.
- **Contacting a cervical TP.** It carries the artery; use the pillar.
- **Rotary contact on the spinous side.** The posterior body side is opposite the spinous.
- **Turning the head to end range to reach T1.** Laterally flex toward the contact instead.
- **Fulcrum under the listed vertebra.** It goes under the lower vertebra of the segment.
- **Pisiform on the TP for a rib.** Slide lateral to the rib angle.
- **Adjusting through pleuritic pain with dyspnea.** Rule out embolism and pneumothorax first.

Chapter 10 self-test · ten items

1. Why are upper cervical set ups done with minimal rotation and no extension?

A. Rotation with extension is needed to lock the occipital condyles first
B. The C1 to C2 joints cannot rotate at all without full extension
C. The alar ligaments must be stretched before any upper cervical thrust is given
D. Rotation with extension stretches the vertebral artery loop over the atlas

D. Rotation with extension stretches the vertebral artery loop over the atlas The artery loops over the posterior arch of C1. Rotation, especially with extension, stretches the opposite artery there.

2. For an ASRP atlas, which side is contacted?

A. The left side of the atlas
B. The right side of C2 spinous
C. The right side of the atlas
D. The left side of the occiput

C. The right side of the atlas Laterality is right and the right side is posterior, so both corrections point to the right side.

3. What is the standard segmental contact in the lower cervical spine?

A. The transverse process
B. The articular pillar
C. The anterior tubercle
D. The vertebral body

B. The articular pillar The pillar sits 1.5 to 2 cm lateral to the spinous. The TPs carry the vertebral artery and are not HVLA contacts.

4. For C5 PR in a rotary set up, which pillar is contacted?

A. The right pillar, driving C5 into left rotation
B. The left pillar, driving C5 into left rotation
C. The left pillar, driving C5 into right rotation
D. The right pillar, driving C5 into right rotation

C. The left pillar, driving C5 into right rotation Spinous right means body left, so the left pillar is posterior. Driving it P to A rotates C5 to the right.

5. How do you lock the segments above the contact in a lower cervical set up?

A. Laterally flex away from the contact while rotating away
B. Laterally flex toward the contact while rotating away
C. Rotate fully to end range toward the side of the contact
D. Extend the neck fully and then add slight rotation away

B. Laterally flex toward the contact while rotating away Coupling is same side, so opposite coupling brings the levels above to tension first.

6. Which test helps tell C7 from T1 before a thumb move?

A. On passive neck extension, T1 moves forward
B. On passive neck flexion, C6 becomes prominent
C. On passive neck extension, T1 does not move
D. On rotation, T1 moves more than C7 does

C. On passive neck extension, T1 does not move On extension C6 fades, C7 moves slightly and T1 does not move. On rotation C7 moves more than T1.

7. Which prone thoracic contact induces extension rather than rotation?

A. Bilateral transverse contacts on one vertebra
B. Crossed contacts on two adjacent thoracic vertebrae
C. A unilateral contact on the posterior TP
D. A spinous push on the side of rotation

A. Bilateral transverse contacts on one vertebra Bilateral TP contacts on the same vertebra drive it straight P to A into extension.

8. For a crossed bilateral set up on T6 PR, where do the contacts go?

A. Right TP of T6 and left TP of T7
B. Left TP of T6 and left TP of T7
C. Right TP of T5 and left TP of T6
D. Left TP of T6 and right TP of T7

D. Left TP of T6 and right TP of T7 One pisiform on the posterior TP of the involved vertebra and the other on the opposite TP of the vertebra below.

9. Where is the posterior contact for a rib set up?

A. The transverse process at the level of the rib
B. The spinous process of the vertebra above the rib
C. The costovertebral joint on the vertebral body
D. The rib angle, lateral to the transverse process

D. The rib angle, lateral to the transverse process A pisiform on the TP adjusts the vertebra. Slide about two to three finger widths lateral to reach the rib angle.

10. What is the line of drive for an elevated right first rib?

A. S to I and slightly L to M, toward the left hip
B. I to S and slightly M to L, toward the right ear
C. P to A and slightly I to S, toward the left eye
D. A to P through the crossed arms, toward the table

A. S to I and slightly L to M, toward the left hip The superior surface of the first rib is driven down and slightly medially toward the opposite hip.

Cram sheet

Everything from chapters 9 and 10 in one place. Cover the right column and see if you can rebuild each row.

Technique station rules

Item	The rule	Note
Seven elements	Listing, patient position, stance, contact point, segmental contact, stabilization, line of drive	Same order, said aloud
Wrap around	Screen and consent before; preload and spoken thrust after	Then release and reassess
Spinous and body	Rotate in opposite directions	PR: spinous right, body left
TP, lamina, pillar, mammillary	Posterior body side, P to A	Opposite the spinous
Spinous contact	Spinous side, toward midline	L to M
Lateral flexion contact	Side to flex toward	Head bent over the contact
ASRP	Tilt, laterality, rotation of that side	Contact right side of atlas
Thrust phases	Positioning, tissue pull, preload, impulse, resolution	Stop at preload at the station
Cavitation	Refractory about 15 to 20 minutes	Not proof of the target joint
End feel	Springy normal; hard fixated; boggy acute; empty serious	Empty: stop and evaluate
Two track script	Plain words to patient, precise terms to examiner	Correct errors aloud

Regional set ups

Region	Contact	Drive
Atlas rotation	Index MCP on posterior arch, posterior side	P to A, toward opposite eye; head about 30 degrees
Lower cervical rotary	Pillar on posterior body side	P to A, slightly I to S, toward opposite eye
Lower cervical lateral flexion	Pillar on side to flex	L to M
Junction thumb move	Thumb on spinous side	L to M, slight P to A; head flexed toward contact
Thoracic extension	Bilateral TPs, one vertebra	P to A, slightly I to S
Thoracic rotation	Posterior TP; crossed with opposite TP below; or spinous push	P to A or L to M
Thoracic flexion	Supine; fulcrum under the lower vertebra	A to P, slightly S to I
Rib angle	2 to 3 fingers lateral to TP	P to A, lateral and slightly inferior
First rib	Superior surface behind clavicle	S to I, toward opposite hip

Numbers and landmarks

Item	Value
Lower cervical facets	About 45 degrees
Thoracic facets	About 60 degrees, near frontal
C1 to C2 rotation	About half of cervical rotation
Rotary head turn	About 30 to 45 degrees, never end range
Inferior scapular angle	About T7
Rule of threes	T1 to T3 own; T4 to T6 half; T7 to T10 below; T11 half; T12 own
Impulse	About a tenth of a second or a little more

Dr. Garg Learning · CC BY-SA 4.0