Study Guide 2

This guide covers the high yield films. Chapter 3 is trauma: the unstable neck injuries, the three columns, slips and the limb fractures that hide. Chapter 4 is everything else a film can show: arthritis patterns, anomalies, scoliosis, tumors, infection, metabolic shapes and the soft tissue findings that are planted on spine films. Every case ends the same way, with a decision about imaging, referral and whether the region may be manipulated. Read the "what to know" paragraphs, study the diagram, then work each case with the steps covered.

WHAT THIS GUIDE COVERS

- Chapter 3 · cervical trauma and the four lines, C1 and C2 injuries, lower cervical patterns, stress films, the three column model, compression versus pathologic fractures, spondylolysis and Meyerding grading, hip, wrist, ankle and pediatric fractures, decision rules and absolute contraindications.
- Chapter 4 · arthritis patterns, DISH, RA of the neck, AS and the seronegatives, gout and CPPD, congenital anomalies, Cobb and Risser, aggressive versus nonaggressive lesions, metastasis and myeloma, infection, AVN and metabolic disease, aneurysm, Pancoast tumor and pneumothorax.

CHAPTER 3

High Yield Films I: Trauma

Read it in full: **Chapter 3 in the textbook**. Practice it: **the practice exams** and **the flashcards**.

What to know

A trauma film station is a safety station dressed as an imaging station. Examiners score the key finding, its level and side, the impression and a safe recommendation. Missing an unstable fracture, or recommending manipulation through one, can outweigh everything else. Use one spoken template every time: view, adequacy, key finding with level and side, secondary findings, a one line impression, and the recommendation last so it is never forgotten.

The neutral lateral cervical film is adequate only when the top of T1 shows, because lower cervical injuries hide behind the shoulders. A swimmer's view is the plain film fix, but real trauma risk needs CT. Trace the four lines. A step or sharp angle marks the injured level, and fanning of spinous processes, a widened facet or focal kyphosis point to ligament injury even with no fracture line. Prevertebral widening ("7 at 2, 22 at 6") supports a fracture but does not rule one out.

At C1 and C2, the **Jefferson fracture** is a burst of the atlas ring from axial load; on the open mouth view both lateral masses overhang C2, and a combined overhang over about 7 mm suggests transverse ligament rupture (rule of Spence). **Odontoid fractures** are type I (tip, rare), type II (base, the most common and the most likely not to unite) and type III (into the body, heals better); II and III are unstable. Separate a fracture from a Mach band. The **hangman fracture** breaks both pars of C2 in hyperextension with distraction, letting the C2 body slip forward on C3; the canal widens, so a normal neurologic exam does not mean stability. An ADI over 3 mm in adults (over 5 mm in children) means transverse ligament failure.

Below C2, think by mechanism. A simple wedge fracture loses anterior height with the posterior wall intact. A **flexion teardrop** from diving leaves a triangular anteroinferior fragment while the body is driven back into the canal; it is very unstable and often causes anterior cord syndrome. An **extension teardrop** is an avulsed corner, usually at C2, with intact posterior structures. The **clay shoveler fracture** avulses a spinous process, most often C7, and is stable. A **unilateral facet dislocation** shows about 25% slip and a bow tie of the facets; 50% or more means bilateral dislocation, which is unstable with a high rate of cord injury. A hyperflexion sprain may look nearly normal in neutral.

Flexion and extension films reveal ligament instability: more than about 3.5 mm of translation or more than about 11 degrees of angulation in the lower cervical spine, or an ADI that widens in flexion. Never take them with a known or suspected fracture, dislocation or neurologic deficit, or in an obtunded or intoxicated patient. Early films are often falsely normal, so they are commonly repeated at 7 to 14 days.

In the thoracolumbar spine, use the **Denis three column model**. The anterior column is the ALL and the front two thirds of the body. The middle column is the back third of the body and the PLL. The posterior column is the arch and its ligaments. One column is usually stable; two or more, or

any middle column injury, is potentially unstable. About half of these fractures occur at T11 to L2. A **burst fracture** from a fall onto the feet often comes with calcaneal fractures, and a **Chance fracture** from a lap belt often comes with bowel injury. The posterior body wall decides: straight means wedge; bowed or broken, with retropulsed bone or a widened interpediculate distance on the AP, means burst and CT.

Acute compression signs include a step or buckle in the anterior cortex, a dense zone of impaction under the endplate, endplate disruption and paraspinal swelling. Height loss of about 20 to 25% is mild, 25 to 40% moderate and over 40% severe. To separate osteoporotic from **pathologic fractures**, look at the pedicles, the posterior wall and the level. A destroyed pedicle, a convex posterior bulge, a solitary fracture above about T7, or night pain, weight loss or a cancer history favors malignancy and calls for MRI, labs and referral. An intravertebral vacuum cleft is nearly always benign. Never thrust at or near either type.

Spondylolysis is a pars defect, usually a fatigue fracture from repeated extension and rotation in young athletes. About 85 to 90% occur at L5, and about three quarters are bilateral. On the oblique view it is the collar on the neck of the Scotty dog. The **Meyerding** grade uses quarters of the S1 endplate: I up to 25%, II 26 to 50%, III 51 to 75%, IV 76 to 100%, V beyond the sacrum (inverted Napoleon hat). **Isthmic** slips are young, L5, pars broken and canal widened, with the step felt above the slipped level. **Degenerative** slips are in women over about 50, at L4 to L5, pars intact, canal narrowed with neurogenic claudication, and the step felt at the slipped level. A stable low grade slip is not an absolute contraindication: avoid a forceful PA thrust on the displaced segment. Grade III or more, progression, or neurologic signs are referred.

In the limbs, follow the rule of two: two views at right angles, the joints above and below, and comparison views in children. **Hip fractures** inside the capsule threaten the femoral head blood supply and carry a high risk of AVN, especially Garden III and IV; up to about 10% are invisible at first, so a patient who cannot bear weight needs same day MRI. **SCFE** is a Salter Harris I slip of the femoral head in an adolescent; Klein's line misses the epiphysis, and the patient goes non weight bearing with same day referral. The **scaphoid** waist is the usual fracture site; blood enters distally, so the proximal pole is at risk, and normal first films mean thumb spica and MRI or repeat films in 10 to 14 days.

Know the other names. Colles displaces the distal radius dorsally, Smith toward the palm. A Segond fracture means ACL tear. A lipohemarthrosis means an intra articular fracture. Weber C is unstable, and a Maisonneuve fracture needs the proximal fibula filmed. A Jones fracture sits about 1.5 to 2 cm beyond the fifth metatarsal tuberosity with a high nonunion rate, unlike the tuberosity avulsion. Salter Harris types run SALTR (I to V), and higher numbers mean more growth risk. Patterns that suggest abuse must be documented and reported.

The decision is what is scored. Acute fracture, instability, dislocation, pathologic bone, an acute osteoporotic fracture and a high grade or unstable slip are absolute contraindications to manipulating that region. Stop, protect, check neurologic status, explain, refer and document. An unstable injury or any deficit is an EMS call; do not let the patient walk out or drive. The **NEXUS** criteria clear an alert patient with no midline tenderness, no deficit, normal alertness, no intoxication and no distracting injury. The **Canadian C spine rule** images any high risk patient (65 or older, dangerous mechanism, or limb paresthesias); otherwise a low risk patient who can actively rotate 45 degrees each way needs no film.

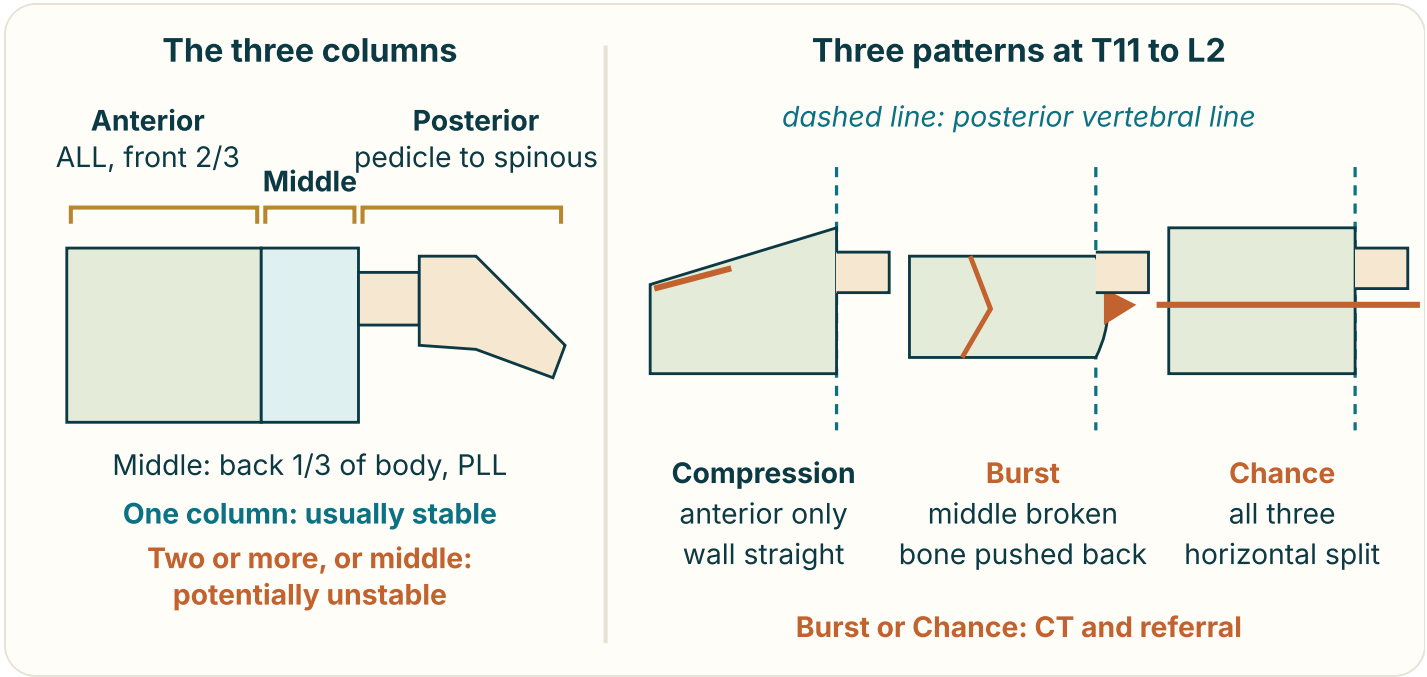

Count the columns. A compression fracture breaks the anterior column only. A burst fracture breaks the middle column and pushes bone back toward the canal. A Chance fracture splits all three columns horizontally.

LOCK THESE IN

- Lateral cervical film must reach the top of T1.
- Unstable: Jefferson with overhang over 7 mm, odontoid II and III, hangman, flexion teardrop, bilateral facet dislocation, ADI over 3 mm.
- Unilateral facet dislocation about 25% slip with a bow tie; bilateral 50% or more.
- No flexion and extension films with a fracture, dislocation, deficit or altered alertness.
- Thoracolumbar: count the columns; a broken posterior wall or wide pedicles means burst and CT.
- Meyerding quarters: I to 25%, II to 50%, III to 75%, IV to 100%, V past the sacrum.
- Normal films with persistent hip or scaphoid signs: protect and get MRI or repeat films.
- Every trauma answer ends with the decision: no manipulation, protect, refer at the right speed.

Injuries, findings and action

Injury	Key film finding	Stability and action
Jefferson (C1 burst)	Bilateral lateral mass overhang on open mouth	Over 7 mm combined: ligament rupture; immobilize, ED
Odontoid type II	Lucency across the dens base	Unstable, poor union; collar, EMS, CT
Hangman (C2)	Bilateral pars fracture, C2 forward on C3	Unstable even with normal neuro exam
Flexion teardrop	Anteroinferior triangle, body pushed back, kyphosis	Very unstable; anterior cord syndrome
Extension teardrop	Avulsed anteroinferior corner, usually C2	Stable in flexion, unstable in extension
Clay shoveler	Avulsed spinous, usually C7	Stable
Unilateral facet dislocation	About 25% slip, bow tie facets	Needs reduction; radiculopathy common
Bilateral facet dislocation	50% or more slip, perched or locked facets	Unstable; emergency
Wedge compression	Anterior height loss, posterior wall straight	Anterior column; stable unless severe
Burst	Posterior wall convex or broken, wide pedicles	Middle column; unstable; CT
Chance	Horizontal fracture through all three columns	Unstable; check for bowel injury
Intracapsular hip	Broken Shenton line, neck lucency	AVN risk; urgent referral
SCFE	Klein's line misses the epiphysis	Non weight bearing; same day referral
Scaphoid waist	Often invisible at first	Thumb spica; MRI or repeat in 10 to 14 days

Injury	Key film finding	Stability and action
Jones fracture	Transverse, 1.5 to 2 cm beyond tuberosity	Non weight bearing; orthopedic referral
Maisonneuve	Medial ankle injury plus proximal fibula fracture	Unstable syndesmosis

Grades and rules

Rule	Values	Use
Meyerding	I 0 to 25%, II 26 to 50%, III 51 to 75%, IV 76 to 100%, V beyond	Spondylolisthesis on the lateral
Compression height loss	Mild 20 to 25%, moderate 25 to 40%, severe over 40%	Semiquantitative grading
Cervical instability	Translation over 3.5 mm or angulation over 11 degrees	Flexion and extension films
Lumbar slip instability	Over about 4 mm or a change in grade	Flexion and extension films
Salter Harris	I through physis; II plus metaphysis; III plus epiphysis; IV all three; V crush	Higher number, more growth risk
Ottawa ankle	Posterior edge or tip of distal 6 cm of either malleolus, or cannot bear weight for four steps	When to film
Ottawa foot	Base of the fifth metatarsal or navicular, or cannot bear weight	When to film
Ankle mortise	Medial clear space over about 4 mm	Deltoid disruption, unstable
Calcaneus	Bohler angle under about 20 degrees (normal 20 to 40)	Fall from height; film the spine too

Worked cases

WORKED CASE 1 · A STEP AT C5 ON C6

A 41 year old man has neck pain and right arm tingling 2 days after a rear end collision. The lateral film shows C5 forward on C6 by about one quarter of the body width.

STEP 1 · CONFIRM ADEQUACY

The film reaches the top of T1.

STEP 2 · DESCRIBE

Anterolisthesis of C5 on C6 of about 25%. Facets superimpose above C5, but at C5 and below two facets sit side by side, a bow tie.

STEP 3 · IMPRESSION

Unilateral facet dislocation at C5 to C6, likely on the right given the arm symptoms. A slip of 50% or more would mean bilateral dislocation.

STEP 4 · RECOMMENDATION

No cervical manipulation. Rigid collar, keep him still, record a neurologic exam, and transport for CT and spine surgery evaluation.

WORKED CASE 2 · GRADING A SLIP WITH NUMBERS

On a lateral film the S1 endplate measures 44 mm front to back. The posteroinferior corner of L5 sits 13 mm forward of the posterior corner of S1. Grade the slip.

STEP 1 · FIND THE PERCENT

13 ÷ 44 = 0.295, so the slip is about 30%.

STEP 2 · APPLY MEYERDING

26 to 50% is grade II. Each quarter of 44 mm is 11 mm, so grade I would end at 11 mm and grade II at 22 mm.

STEP 3 · CHECK THE TYPE

A pars defect on the oblique makes it isthmic. An intact pars with big sclerotic facets at L4 to L5 would make it degenerative.

STEP 4 · RECOMMEND

Stable grade II without deficit: conservative care, no forceful PA thrust on the slipped segment, flexion and extension films if instability is suspected.

WORKED CASE 3 · AN OLD MAN, A MINOR FALL, A DENS

A 79 year old fell backward from standing and hit his forehead. Neck pain, no numbness. The lateral shows the dens tilted back with a lucency at its base and about 9 mm of prevertebral tissue at C2.

STEP 1 · APPLY THE DECISION RULE

Age 65 or older is high risk under the Canadian C spine rule, so imaging was required.

STEP 2 · SEPARATE FRACTURE FROM MIMIC

On the open mouth view the lucency crosses the base and runs beyond the dens only where the arch overlaps, so a Mach band is less likely. The soft tissue is widened over 7 mm.

STEP 3 · IMPRESSION

Type II odontoid fracture, unstable.

STEP 4 · ACT

No manipulation, keep him still and supine, rigid collar, neurologic check, and EMS to the emergency department. He must not drive or walk out.

TRAPS PEOPLE FALL INTO

- **Calling the film adequate without T1.** Lower cervical injuries hide behind the shoulders.
- **Mixing up the teardrops.** Flexion teardrop is very unstable; extension teardrop is an avulsed corner.
- **Trusting a normal neuro exam in a hangman fracture.** The canal widens, so the cord is often spared.
- **Ordering stress films on a fractured neck.** Flexion and extension views come only after fracture and deficit are excluded.
- **Calling a burst fracture a wedge.** Check the posterior wall and the interpediculate distance.
- **Placing the isthmic step at the slipped level.** In an isthmic L5 slip the step is felt between L4 and L5.
- **Clearing a wrist or hip on normal films.** Persistent signs earn immobilization and MRI or repeat films.
- **Confusing Jones with a tuberosity avulsion.** Jones is 1.5 to 2 cm distal and has a high nonunion rate.

Chapter 3 self-test · ten items

1. After a dive into shallow water, the open mouth film shows 5 mm of overhang on the left and 3 mm on the right at C1. What does this suggest?

A. A Jefferson fracture with likely transverse ligament rupture
B. A pseudo Jefferson offset that is normal for an adult
C. A type I odontoid fracture with an intact transverse ligament
D. Head rotation during the exposure with no injury present

A. A Jefferson fracture with likely transverse ligament rupture The combined overhang is 5 + 3 = 8 mm. By the rule of Spence, more than about 7 mm suggests transverse ligament rupture and an unstable Jefferson fracture. Pseudospread is a finding in young children.

2. Which odontoid fracture is the most common and the most likely to fail to unite?

A. Type I, through the tip
B. Type II, across the base
C. Type III, into the C2 body
D. A Mach band at the base

B. Type II, across the base Type II crosses the poorly perfused base. Type III enters the body and heals better, and a Mach band is not a fracture.

3. A lateral cervical film shows C4 slipped forward on C5 by about half the body width, with the facets perched. What is the injury?

A. Unilateral facet dislocation
B. Extension teardrop fracture
C. Clay shoveler fracture
D. Bilateral facet dislocation

D. Bilateral facet dislocation A slip of 50% or more means bilateral dislocation, which is unstable. Unilateral dislocation shows about 25% with a bow tie.

4. When are flexion and extension cervical films appropriate?

A. As the first film for any patient after a car collision
B. When a fracture has been seen, to judge how unstable the injury is
C. After fracture and deficit are excluded, often at 7 to 14 days
D. In an intoxicated patient who cannot report symptoms

C. After fracture and deficit are excluded, often at 7 to 14 days Stress films are contraindicated with a known or suspected fracture, dislocation, deficit or altered alertness. Early films can be falsely normal.

5. A lateral lumbar film after a fall from a ladder shows L1 height loss with a convex posterior wall. What should come next?

A. DXA, because this suggests osteoporosis
B. CT, because this suggests a burst fracture
C. Flexion and extension views of L1 today
D. Low force care and repeat films in a month

B. CT, because this suggests a burst fracture A bowed or broken posterior wall means middle column injury, a burst fracture, which is unstable and needs CT.

6. Which finding favors a pathologic rather than an osteoporotic compression fracture?

A. An intravertebral vacuum cleft
B. Several fractures of different ages
C. A destroyed pedicle on the AP view
D. Generalized thin cortices throughout

C. A destroyed pedicle on the AP view A missing pedicle, convex posterior bulge or solitary fracture above T7 favor malignancy. A vacuum cleft is nearly always benign.

7. An adolescent's L5 slip is 40% of the S1 endplate. What is the Meyerding grade?

A. Grade I
B. Grade III
C. Grade IV
D. Grade II

D. Grade II Grade II covers 26 to 50%. Grade I ends at 25%, and grade III covers 51 to 75%.

8. A 68 year old woman has an L4 slip with an intact pars and leg pain on walking relieved by sitting. Which statement fits?

A. This is isthmic, and the canal is widened at the level
B. This is dysplastic, and it needs urgent surgery
C. This is traumatic, from an acute fracture of the pars interarticularis
D. This is degenerative, and the canal is narrowed at the level

D. This is degenerative, and the canal is narrowed at the level Degenerative slips occur with an intact pars, usually at L4 to L5 in older women, and the whole vertebra moves forward, narrowing the canal and causing neurogenic claudication.

9. A snowboarder has snuffbox tenderness 4 days after a fall, and all three wrist views are normal. What is the plan?

A. Thumb spica, no wrist manipulation, MRI or repeat films in 10 to 14 days
B. Reassure the patient, since three normal views rule out a fracture
C. Wrist mobilization to restore motion before stiffness sets in
D. Comparison views of the opposite wrist taken today to settle the question

A. Thumb spica, no wrist manipulation, MRI or repeat films in 10 to 14 days A significant fraction of scaphoid fractures are invisible at first, and a missed waist fracture risks nonunion and proximal pole AVN.

10. A small vertical avulsion is seen off the lateral tibial plateau after a twisting injury. What does it strongly suggest?

A. An ACL tear
B. A meniscal cyst
C. A Jones fracture
D. A bipartite patella

A. An ACL tear The Segond fracture is strongly associated with ACL tear and calls for MRI and orthopedic referral.

CHAPTER 4

High Yield Films II: Arthritides, Tumors, Infection, Metabolic Disease and Soft Tissue

Read it in full: **Chapter 4 in the textbook**. Practice it: **the practice exams** and **the flashcards**.

What to know

Describe every arthritis with the same headings and you show a method rather than a guess: **alignment**, **bone density**, **cartilage space**, **distribution** and **soft tissue**, then ask whether there are erosions and whether there is new bone. Degenerative disease narrows the joint unevenly where load is greatest and builds osteophytes, sclerosis and cysts, with normal density. In the hand it takes the DIP, PIP and first CMC joints and spares the MCPs. In the spine it gives disc narrowing, endplate sclerosis, the vacuum phenomenon (which effectively excludes infection), horizontal osteophytes and facet arthrosis. Degenerative change is common and often painless, so link findings to symptoms.

DISH is a bone forming enthesopathy of older adults, more common in men and with diabetes and obesity. It lays flowing ossification along the front of at least four contiguous bodies with disc height preserved, no significant facet ankylosis and normal SI joints. It favors the right side of the

thoracic spine. In the neck it can cause dysphagia and travels with OPLL. A long fused segment breaks like a long bone with minor trauma and is unstable.

Rheumatoid arthritis is a synovial disease: soft tissue swelling, periarticular osteopenia, uniform joint space loss and marginal erosions with little new bone. It is bilateral and symmetric in the MCP, PIP, wrist and MTP joints, with an early ulnar styloid erosion. The cervical spine is the high stakes area. Pannus at C1 to C2 weakens the transverse ligament, giving atlantoaxial instability (ADI over 3 mm in an adult), cranial settling and stair step subluxations. Neutral and flexion films are standard before any neck treatment, and instability or myelopathic signs absolutely contraindicate cervical manipulation.

Ankylosing spondylitis begins in young adults, more often men, with inflammatory back pain. It starts in the SI joints, bilaterally and symmetrically, with erosions that pseudowiden the joint, then sclerosis and fusion. In the spine come Romanus lesions (shiny corners), squaring, then thin marginal syndesmophytes that build the bamboo spine, with the dagger and trolley track signs. Psoriatic arthritis is asymmetric, favors the DIP joints and makes the pencil in cup deformity and bulky asymmetric parasyndesmophytes. A fused spine of AS or DISH breaks like chalk after minor trauma, so new pain after any fall needs CT.

Gout shows punched out erosions with overhanging edges (Martel sign), joint space preserved until late, normal density and asymmetric tophi, classically at the first MTP. **CPPD** calcifies cartilage (knee menisci, wrist TFCC, symphysis) and makes OA in odd places: radiocarpal joint, second and third MCPs with hook osteophytes, isolated patellofemoral disease. A crowned dens can mimic meningitis.

Congenital anomalies come from failures of segmentation, formation or fusion. Do not call them fractures, know which change stability, and know which change technique. A **block vertebra** has a wasp waist and a rudimentary disc; the segments next to it are hypermobile, and the fused level is not manipulated. Hemivertebrae can cause rapidly progressive congenital scoliosis. Transitional segments require careful counting. Spina bifida occulta means no spinous contact over the cleft. Occipitalization of the atlas brings basilar impression and C1 to C2 instability, so no upper cervical manipulation without a stability assessment. A cervical rib comes off C7, whose transverse process slopes down.

Scoliosis is a curve of 10 degrees or more by the **Cobb method**, using lines along the superior endplate of the upper end vertebra and the inferior endplate of the lower. Measurement error is about 3 to 5 degrees, so a change of 5 degrees or more is progression. The **Risser** sign grades iliac apophysis ossification from ASIS to PSIS, 0 to 5; low grades mean growth remains. In a growing adolescent, observe under about 20 to 25 degrees with films every 4 to 6 months, refer for bracing at about 25 to 40 degrees with Risser 0 to 2, and refer for surgical consultation over about 40 to 50. A left thoracic curve, a painful curve, rapid progression, a young child or neurologic signs call for MRI.

For bone lesions, decide aggressive or not from margin, zone of transition, cortex, periosteal reaction and soft tissue mass, then narrow by age, location and matrix. Plain films show lysis only after about 30 to 50% of bone is lost. **Metastasis** is the most common malignant bone tumor; most are lytic, blastic points to prostate in men and breast in women, and the hallmark is the missing pedicle (winking owl). The ivory vertebra differential is blastic metastasis, Hodgkin lymphoma and Paget disease, and only Paget enlarges the bone. **Myeloma** shows punched out lesions or diffuse osteopenia, spares the pedicle early, is often cold on bone scan, and follows CRAB with an M protein. Benign lesions that need nothing include the vertebral hemangioma (corduroy), the bone island and the nonossifying fibroma. Osteoid osteoma causes night pain relieved by NSAIDs.

Infection destroys the disc and both endplates; tumor spares the disc. Pyogenic discitis, usually Staphylococcus aureus, first narrows the disc, then blurs and erodes both endplates. Films lag about 2 to 3 weeks, so MRI, ESR, CRP, CBC and blood cultures come first. Tuberculous spondylitis is slower, spreads under the ALL, preserves the disc longer and makes big paraspinal abscesses and a gibbus. AVN keeps the joint space until collapse and shows a crescent sign. Learn the shapes: H vertebra (sickle cell), picture frame and enlarged bone (Paget), rugger jersey (renal osteodystrophy), codfish (osteoporosis), Looser zones (osteomalacia) and radial side subperiosteal resorption of the middle phalanges (hyperparathyroidism).

Finish every film with a soft tissue sweep and say so. An **abdominal aortic aneurysm** is 3 cm or more (normal about 2 cm), usually in front of L2 to L4, measured outer wall to outer wall. A plain film can suggest but cannot exclude one; ultrasound confirms. Repair is commonly considered at

about 5.5 cm in men (about 5 cm in women) or with growth over about 0.5 to 1 cm a year. A painful aneurysm is urgent, and pain with hypotension, syncope or a pulsatile mass is a 911 emergency. Avoid forceful lumbar manipulation until it is evaluated. On cervical and upper thoracic films, look at the apices for a Pancoast tumor. A pleural line with no markings beyond it is a pneumothorax, and tension signs mean 911. Widened prevertebral tissue means hematoma, retropharyngeal abscess or calcific tendinitis of the longus colli.

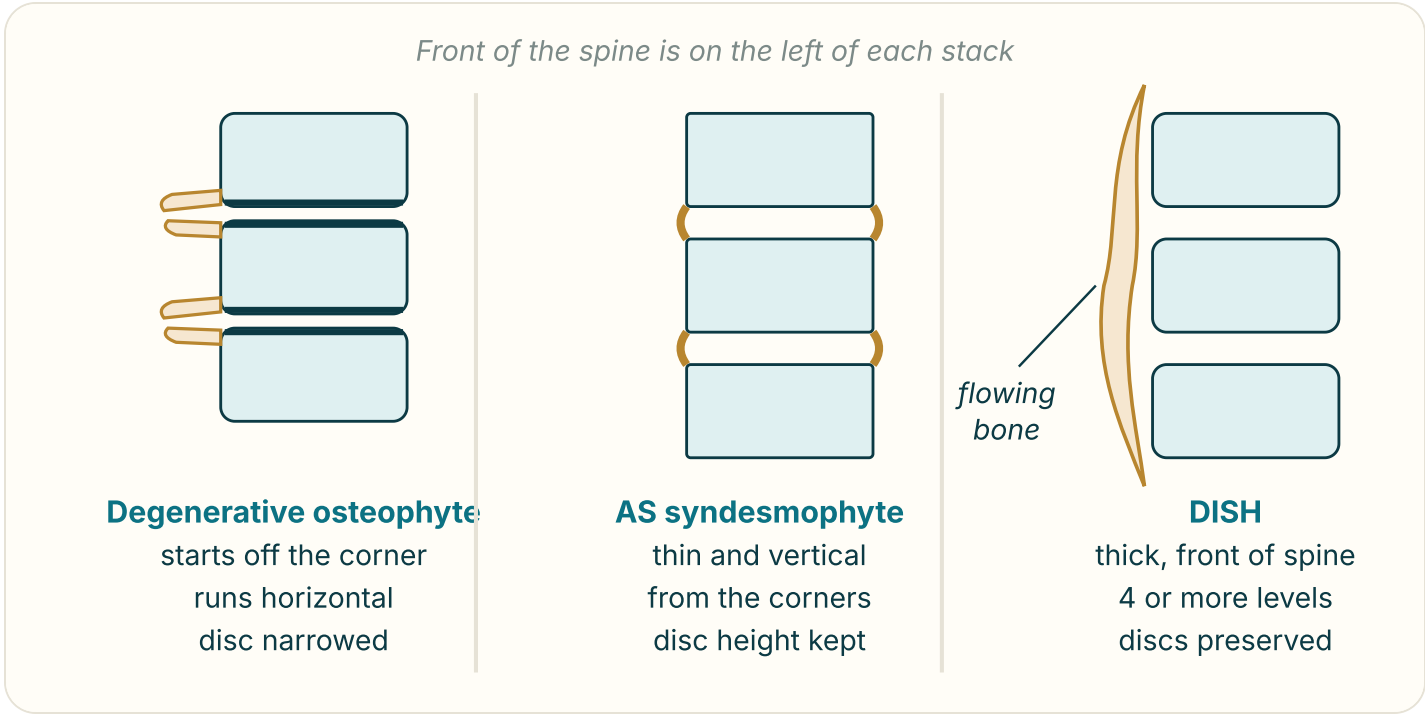

Osteophyte, syndesmophyte or DISH. Degenerative osteophytes start off the corner and run horizontally; syndesmophytes of ankylosing spondylitis are thin, vertical and marginal; DISH lays thick flowing bone along the front of four or more levels with the discs preserved.

LOCK THESE IN

- OA: uneven narrowing and osteophytes. RA: even narrowing, marginal erosions, osteopenia. Gout: punched out with overhanging edge, joint preserved.
- RA neck: ADI over 3 mm or myelopathic signs means no cervical manipulation and referral.
- AS or DISH fused spine plus a fall means CT.
- DISH: four or more levels, discs preserved, SI joints normal.
- Cobb angle of 10 degrees or more is scoliosis; 5 degrees change is progression.
- Missing pedicle: metastasis. Pedicle spared early, cold bone scan: myeloma.
- Infection destroys the disc and both endplates; tumor spares the disc.
- Aorta 3 cm or more is an aneurysm; plain films cannot exclude one.

Arthritis patterns

Feature	Degenerative	Rheumatoid	Seronegative	Gout	CPPD
Joint space	Nonuniform loss	Uniform, symmetric	Uniform, then ankylosis	Preserved until late	Nonuniform
Density	Normal	Periarticular osteopenia	Normal early	Normal	Normal
Erosions	None (central in erosive OA)	Marginal	Marginal with fluffy new bone	Punched out, overhanging edge	Uncommon
New bone	Osteophytes, sclerosis, cysts	None	Periostitis, syndesmophytes	Overhanging edge	Big osteophytes, chondrocalcinosis
Distribution	Weight bearing, DIP, PIP, first CMC	MCP, PIP, wrist, upper cervical	SI joints, spine; DIP in psoriatic	First MTP, asymmetric	Knee, wrist, second and third MCP

Scoliosis and lesion thresholds

Item	Value	Action or meaning
Scoliosis	Cobb 10 degrees or more	Usually with rotation
Progression	5 degrees or more between films	Same end vertebrae each time
Under 20 to 25 degrees, growing	Observe	Films every 4 to 6 months
25 to 40 degrees, Risser 0 to 2	Refer	Bracing evaluation
Over 40 to 50 degrees	Refer	Surgical consultation
Risser	0 none to 5 fused	Spreads ASIS to PSIS
Osteoid osteoma nidus	Under about 1.5 cm	Osteoblastoma is larger
Visible lysis	30 to 50% bone loss	Normal film does not exclude tumor
Osteoporosis	About 30% loss before visible; T score minus 2.5 or lower	DXA diagnoses
AAA	3 cm or more (normal about 2 cm)	Repair about 5.5 cm men, 5 cm women

Worked cases

WORKED CASE 1 · RHEUMATOID ARTHRITIS AND A REQUEST FOR A NECK ADJUSTMENT

A 58 year old with long standing RA on methotrexate has neck pain and tingling in both hands. Neutral ADI is about 3 mm and widens to about 7 mm in flexion, with dens erosion and step offs at C3 to C4 and C4 to C5.

STEP 1 · MEASURE AND NAME

An ADI that widens to 7 mm in flexion is atlantoaxial instability. Add subaxial subluxations.

STEP 2 · SCREEN FOR MYELOPATHY

Reflexes, Hoffmann sign, gait and hand dexterity. Bilateral hand symptoms raise concern.

STEP 3 · DECIDE

No cervical manipulation. Low force care elsewhere is reasonable.

STEP 4 · REFER AND EXPLAIN

Prompt referral to her rheumatologist and a spine surgeon with MRI; avoid end range flexion; tell her plainly why you will not adjust her neck.

WORKED CASE 2 · MEASURING PROGRESSION WITH THE COBB METHOD

A 12 year old girl has a right thoracic curve. Last visit the Cobb angle was 24 degrees. Today, using the same end vertebrae, it measures 31 degrees. She is Risser 0.

STEP 1 · FIND THE CHANGE

31 minus 24 = 7 degrees.

STEP 2 · COMPARE WITH ERROR

Measurement error is about 3 to 5 degrees, so 5 or more counts as progression. 7 degrees is real progression.

STEP 3 · PLACE THE CURVE

31 degrees sits in the 25 to 40 degree band, and Risser 0 means much growth remains.

STEP 4 · RECOMMEND

Refer to a pediatric orthopedist for bracing evaluation now, do a neurologic screen including abdominal reflexes, and use low dose PA technique for follow up films.

WORKED CASE 3 · A MISSING PEDICLE AND AN OLD CANCER

A 67 year old man has 2 months of constant low back pain worse at night, 5 kg unintended weight loss and prostate cancer treated 6 years ago. The AP shows no right L3 pedicle and a dense L3 body; discs are preserved.

STEP 1 · SEARCH THE PEDICLES FIRST

The right L3 pedicle is absent, the winking owl.

STEP 2 · READ THE DENSITY

A dense body that is not enlarged fits a blastic metastasis; Paget would enlarge the bone.

STEP 3 · IMPRESSION

Missing right L3 pedicle with sclerotic L3 body, highly suspicious for osteoblastic metastasis from prostate cancer.

STEP 4 · ACT

No lumbar manipulation. Same or next day referral with MRI, bone scan, PSA, CBC, calcium and alkaline phosphatase. Document a neurologic exam and give emergency advice for leg weakness, saddle numbness

or bladder or bowel change.

TRAPS PEOPLE FALL INTO

- **Calling a block vertebra a fracture.** Look for the wasp waist and rudimentary disc.
- **Reassuring a fused spine after a fall.** AS and DISH fractures are unstable; get CT.
- **Adjusting an RA neck without films.** Neutral and flexion views come first.
- **Calling a change under 5 degrees progression.** Measurement error is 3 to 5 degrees.
- **Calling a hemangioma a tumor to fear.** Corduroy striations with normal height are incidental.
- **Thinking a normal film excludes tumor.** Lysis shows only after 30 to 50% bone loss; MRI is sensitive.
- **Calling infection degenerative.** Destroyed disc and both endplates point to infection; vacuum gas points away.
- **Skipping the soft tissue sweep.** The aorta and the apices are the classic planted findings.

Chapter 4 self-test · ten items

1. Which film pattern best fits rheumatoid arthritis of the hands?

A. DIP and PIP narrowing with osteophytes and normal bone density
B. Symmetric MCP and PIP narrowing with marginal erosions and osteopenia
C. Punched out erosions with overhanging edges at the first MTP joint
D. DIP erosions with pencil in cup change and fluffy periostitis nearby

B. Symmetric MCP and PIP narrowing with marginal erosions and osteopenia RA is synovial: uniform narrowing, marginal erosions at the bare areas, periarticular osteopenia and little new bone, bilaterally and symmetrically.

2. A 66 year old man with diabetes has flowing anterior ossification over five thoracic levels, preserved discs and normal SI joints. What is the diagnosis?

A. Ankylosing spondylitis
B. Degenerative disc disease
C. DISH (Forestier disease)
D. Psoriatic arthritis

C. DISH (Forestier disease) DISH needs at least four contiguous levels with disc height preserved and normal SI joints. AS begins at the SI joints.

3. A patient with ankylosing spondylitis has new neck pain after a minor fall. What is the right next step?

A. Low force cervical care and review in two weeks
B. CT, because a fused spine fractures easily and unstably
C. Flexion and extension films to judge any abnormal motion
D. Reassurance, since the fused spine is very stable

B. CT, because a fused spine fractures easily and unstably A fused AS or DISH spine breaks like chalk after minor trauma, and the fracture is highly unstable.

4. Which finding best separates gout from rheumatoid arthritis on film?

A. Uniform joint space loss across the whole joint
B. Periarticular osteopenia with soft tissue swelling around the joint
C. Bilateral symmetric involvement of the wrists
D. Punched out erosions with overhanging edges, joint space kept

D. Punched out erosions with overhanging edges, joint space kept Gout spares the joint space until late and makes the Martel overhanging edge sign, with normal density.

5. Two fused cervical bodies show a concave anterior waist and a thin rudimentary disc. What is the technique implication?

A. Adjust the fused level gently to restore the motion it has lost over time
B. Avoid all cervical care, since the anomaly is unstable
C. Treat it as an acute fracture and refer to the ED
D. Leave the fused level alone; assess the hypermobile levels beside it

D. Leave the fused level alone; assess the hypermobile levels beside it A congenital block vertebra is fused and its neighbors are hypermobile. The wasp waist separates it from an acquired fusion.

6. A 13 year old has a 30 degree right thoracic curve and is Risser 1. What is the usual recommendation?

A. Referral for bracing evaluation
B. Observation with films in a year
C. Referral for spinal fusion surgery
D. No follow up, as growth has ended

A. Referral for bracing evaluation About 25 to 40 degrees in a skeletally immature patient (Risser 0 to 2) is the commonly taught bracing range.

7. A teenager has a painful scoliosis with night pain relieved by NSAIDs. What should you suspect?

A. Adolescent idiopathic scoliosis
B. A congenital block vertebra at the apex
C. Osteoid osteoma on the concave side
D. Leg length inequality

C. Osteoid osteoma on the concave side A painful curve is not routine idiopathic scoliosis. Osteoid osteoma sits on the concave side and is relieved by NSAIDs.

8. An older adult has diffuse osteopenia, punched out lytic skull lesions and a normal bone scan. What is most likely?

A. Blastic metastasis
B. Multiple myeloma
C. Paget disease
D. Osteoporosis alone

B. Multiple myeloma Myeloma is often cold on bone scan because there is little osteoblastic response. CRAB features and an M protein follow.

9. A lumbar film shows a narrowed L3 to L4 disc with indistinct, eroded endplates on both sides and no vacuum gas. What is the most likely process?

A. Pyogenic discitis
B. Metastatic disease
C. Degenerative disc disease
D. An osteoporotic fracture

A. Pyogenic discitis Infection crosses and destroys the disc and both endplates. Tumor usually spares the disc, and vacuum gas would point to degeneration.

10. A lateral lumbar film shows calcified aortic walls 5 cm apart in a 71 year old with steady, nonmechanical back ache. What is the plan?

A. No lumbar manipulation, same day ultrasound or CT and vascular referral
B. Routine ultrasound within a few months and continued lumbar care
C. Side posture manipulation once the blood pressure has been checked
D. Repeat the lateral lumbar film in a year to see whether the aorta has grown

A. No lumbar manipulation, same day ultrasound or CT and vascular referral A large aneurysm with nonmechanical pain may be symptomatic. Withhold manipulation, refer urgently, and give 911 advice for severe pain or faintness.

ONE PAGE

Cram sheet

Everything from chapters 3 and 4 in one place. Cover the right column and see if you can rebuild each row.

Trauma at a glance

Finding	Name	Decision
C1 overhang over 7 mm combined	Jefferson with ligament rupture	Unstable; collar, ED, CT
Lucency across dens base	Odontoid type II	Unstable; EMS
Bilateral C2 pars fracture	Hangman	Unstable even with normal neuro exam
25% slip, bow tie facets	Unilateral facet dislocation	Collar, CT, surgery evaluation
50% slip, perched facets	Bilateral facet dislocation	Emergency
Posterior wall bowed, wide pedicles	Burst fracture	CT, referral
Horizontal split through all columns	Chance fracture	Unstable; check abdomen
Collar on Scotty dog	Spondylolysis	Protect, image, follow
Klein's line misses epiphysis	SCFE	Non weight bearing, same day referral
Normal films, snuffbox pain	Occult scaphoid	Spica; MRI or repeat in 10 to 14 days
Transverse lucency 1.5 to 2 cm past tuberosity	Jones fracture	Non weight bearing, referral

Decision rules and grades

Rule	Content
NEXUS	Clear if no midline tenderness, deficit, altered alertness, intoxication or distracting injury
Canadian C spine	High risk (65+, dangerous mechanism, paresthesias) images; low risk who rotates 45 degrees each way does not
Stress films	Never with fracture, deficit or altered alertness; often at 7 to 14 days
Instability	Cervical over 3.5 mm or 11 degrees; lumbar slip over about 4 mm
Meyerding	I to 25%, II to 50%, III to 75%, IV to 100%, V beyond
Salter Harris	SALTR, I to V; higher means more growth risk
Ottawa ankle	Distal 6 cm posterior edge or tip of a malleolus, or cannot bear weight for four steps

Disease shapes and patterns

Finding	Think
Uneven narrowing, osteophytes	Degenerative
Even narrowing, marginal erosions, osteopenia	Rheumatoid
Overhanging edge, joint preserved	Gout
Chondrocalcinosis	CPPD
Bamboo spine, SI fusion	Ankylosing spondylitis
Flowing bone, 4+ levels, discs kept	DISH
Missing pedicle	Metastasis
Pedicle spared, cold scan, CRAB	Myeloma
Disc and both endplates destroyed	Infection
H vertebra	Sickle cell
Picture frame, big bone	Paget
Rugger jersey	Renal osteodystrophy
Aorta 3 cm or more	Aneurysm

Dr. Garg Learning · CC BY-SA 4.0