Study Guide 1

This guide covers the first two chapters. You will learn how a practical station is built and scored, and the routine that earns points in every room. Then you will build a film reading engine: one search pattern, the normal lines and spaces, and the variants that fool people. Work one chapter at a time. Read the "what to know" paragraphs, study the diagram and the tables, then try each worked case with the steps covered. Finish each chapter with its ten self-test items. Station counts and timings change, so confirm current details in the official candidate materials.

WHAT THIS GUIDE COVERS

- Chapter 1 · the OSCE format, door cards, standardized patients, checklists, critical actions and global ratings, verbalizing, exam day routine, study plans, consent, the stop rule and red flag referral.
- Chapter 2 · the label check, ABCS and review areas, satisfaction of search, cervical lines and spaces, normal variants, pelvic and elbow lines, chest and abdomen anatomy, and describing a lesion with a safe recommendation.

CHAPTER 1

How the Practical Exam Works and How to Prepare

Read it in full: **Chapter 1 in the textbook**. Practice it: **the practice exams** and **the flashcards**.

What to know

Part IV does not ask what you know. It asks what you do with a person in front of you and a clock on the wall. The design comes from the objective structured clinical examination (OSCE): many short, standardized encounters instead of one long one. Every candidate meets the same task, the same patient script and the same scoring sheet, which makes the result fairer and more reliable. Station counts, timings and written parts change over time, so always confirm the current details in the official candidate materials before you sit the exam.

There are three content areas. **Chiropractic technique** asks you to identify a listing, position the patient, take a stance, make the contact, stabilize, set the line of drive and describe the thrust. **Case management** asks for a focused history, a focused examination, a diagnosis, tests, a decision on care or referral, and documentation. **Imaging interpretation** asks you to search a film, describe what you find, give an impression and make a safe recommendation. The areas overlap. A case station may hand you a film, and a technique station may hide a reason not to adjust.

Each station starts with a **door card** outside the room. It gives the patient's name, age and sex, the setting, the complaint, sometimes vital signs, and the task. The door card tells you what is scored. If it says "focused history only," a perfect examination earns nothing. The cycle is always the same: a reading period, the encounter, often a post-encounter task such as a note or a film question, then rotation on the signal. When the signal ends the encounter, you stop, thank the patient and leave, even mid-sentence. Unfinished items are simply unscored.

A **standardized patient** (SP) gives the same history and the same physical responses to every candidate. SPs are often told to answer only what is asked. They will not volunteer that they take warfarin or lost 15 pounds unless you ask. Information you do not ask for does not exist. Scoring may be done by the SP, by an examiner in the room or watching remotely, or from a recording. Address the patient, not the examiner, unless the door card says otherwise. When a real thrust is not permitted, you set up fully, take tissue pull and preload, state the line of drive and say you would now deliver a high velocity, low amplitude thrust.

Most stations are scored with a **checklist** of observable actions marked done or not done. Checklists cannot award credit for what an examiner assumes you thought. Many exams add **global ratings** for communication, organization and professionalism, so a candidate who ticks every box but is brusque or rough can still score poorly. A **critical action** is an item whose omission is unsafe or a serious failure of care. Exams treat these differently, so behave as if each one can sink a station: safety screening before manipulation, red flag recognition, appropriate referral, informed consent, modesty, and stopping on pain.

Verbalizing turns thinking into something an observer can score. State each test, its result and what it means, including negatives. In technique stations name the listing, the contact point (part of your hand), the segmental contact (part of the vertebra), the stabilization, the line of drive and

the screening that came before it. Most lost points are habit failures: a skipped opening, a misread door card, silent testing, an incomplete red flag screen, leading questions, poor technique, running out of time, no plan, ignoring the patient and an inaccurate note.

Exam day rewards a fixed routine. Arrive early with only permitted items, dress cleanly with nothing dangling over the patient, and read every door card the same five ways: name, age and sex; complaint and duration; vital signs; task verbs; and your first three steps. Enter, perform hand hygiene in view, introduce yourself by name and role, confirm identity, state the agenda and check comfort. Expose only what you need, explain before touching, and treat the SP as a real patient. Never perform rectal, genital or breast examinations in a station; state that you would do it with consent and a chaperone, or refer. At the time warning, move to your close. It is better to skip two tests than to leave without a plan.

Study by doing. Write your own checklists, work in rotating trios (doctor, patient, examiner with checklist and timer), add timed mock stations, record yourself, and build volume on films with one fixed search pattern. Reading is the repair step, not the main activity. Practice on many different bodies so your set ups adapt to any patient size.

Every station sits on one communication spine: open, explain, consent, perform, check, close. **Informed consent** is a process covering the nature of the procedure, its material risks, the expected benefits and reasonable alternatives, including no treatment, and the right to stop. Separate consent to examine from consent to treat. Consent can be withdrawn at any moment, even mid set up. The **stop rule**: any new pain, dizziness, numbness or distress means stop, release, reassess, and resume with modification only if the symptom was minor and has settled. A red flag always outranks the planned task. Document in SOAP form and write only what you actually did.

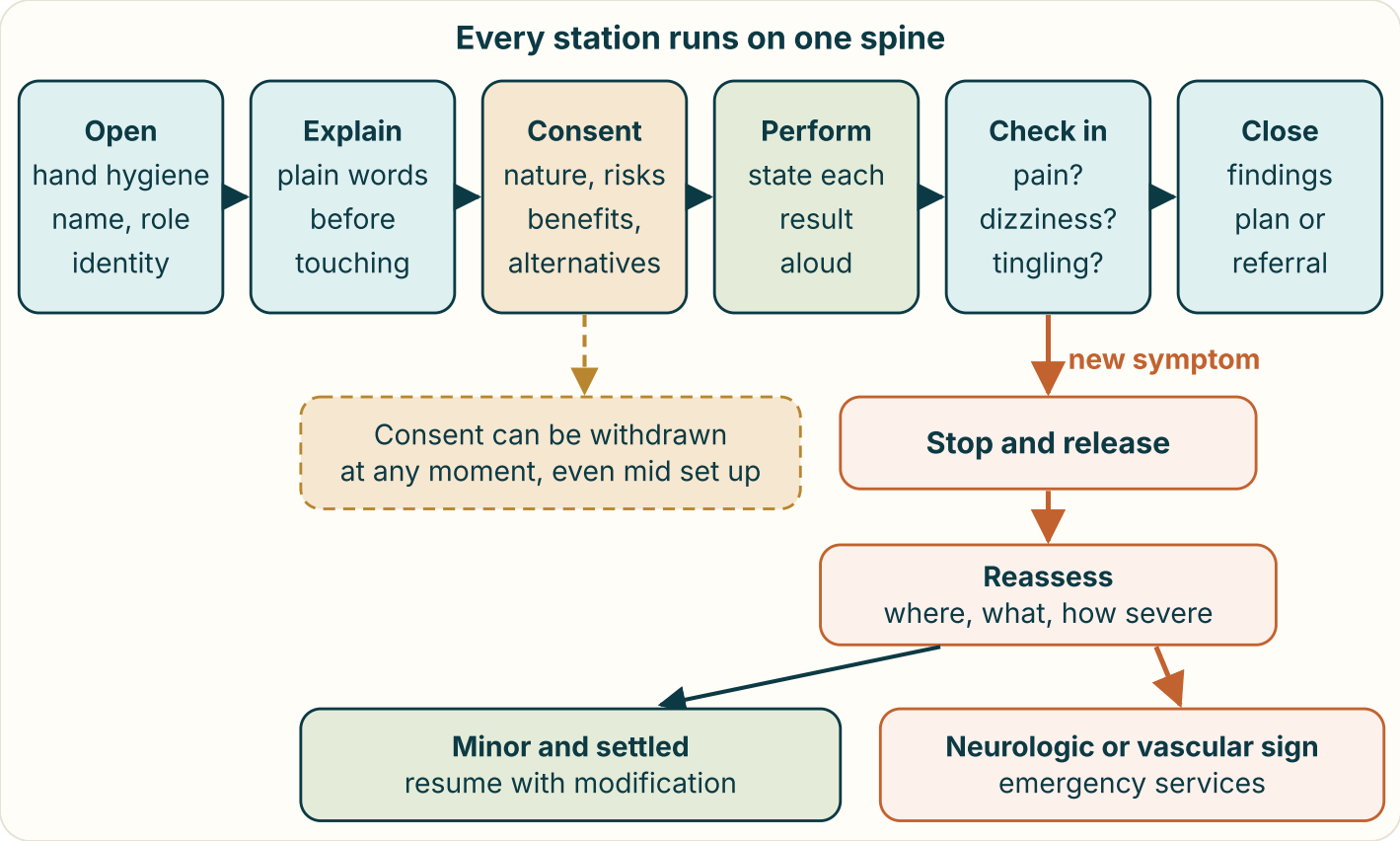

The communication spine and the stop rule. Every station, whatever its content, runs open, explain, consent, perform, check, close. Any new symptom during a test or set up triggers the same stop rule.

LOCK THESE IN

- Part IV is an OSCE style exam with technique, case management and imaging stations. Confirm current details in the official candidate materials.
- The door card defines what is scored. Read the verb and do every task it names, in order.
- SPs reveal only what you ask. A missed question is missing information.
- Checklists score observable actions. If you do not say it, it cannot be scored.
- Critical actions: screen before manipulation, recognize red flags, refer, obtain consent, protect modesty, stop on pain.
- State pertinent negatives as well as positives.
- At the time warning, move to findings, diagnosis, plan, consent and questions.
- Stop rule: stop, release, reassess. Neurologic or vascular warning signs mean emergency services.

Station skeletons and red flag responses

Item	What it covers
Technique station	Opening, listing, set up, close
History station	Opening, core, close
Examination station	Explain, consent, drape
Imaging station	Patient data, search, impression

Item	What it covers
Saddle anesthesia, retention, bilateral weakness	Cauda equina syndrome
Sudden neck pain or headache with dizziness, diplopia, dysarthria, dysphagia, ataxia	Cervical artery dissection
Over 50, prior cancer, weight loss, night pain	Malignancy
Fever, IV drug use, recent infection, immunosuppression	Spinal infection
Trauma, osteoporosis, long term steroids	Fracture
Pulsatile mass, tearing pain, older male smoker	Abdominal aortic aneurysm
Exertional chest pain, sweating, arm or jaw pain	Acute coronary syndrome
Anticoagulants or bleeding disorder	Bleeding risk

Item	What it covers
RA, Down syndrome, recent upper cervical trauma	Atlantoaxial instability

Worked cases

WORKED CASE 1 · READING A DOOR CARD WITH ABNORMAL VITAL SIGNS

Door card: Tom, 45, right shoulder pain. BP 182/112, pulse 96. Task: perform a focused examination and discuss your management plan.

STEP 1 · NOTICE WHAT WAS PLANTED

Vital signs on a door card are placed on purpose. A blood pressure of 182/112 changes the whole station.

STEP 2 · OPEN AS ALWAYS

Hygiene, introduction, identity, explanation and consent. Then recheck the pressure with the correct cuff size, arm supported at heart level, patient seated with feet flat and rested.

STEP 3 · ASK TARGET ORGAN QUESTIONS

Headache, chest pain, shortness of breath, visual change, confusion and weakness. Ask briefly about exertional, chest and abdominal symptoms, because right shoulder pain can be referred from the gallbladder or diaphragm.

STEP 4 · EXAMINE, THEN PLAN

Do the focused shoulder exam if he is stable. State that this reading needs medical evaluation: same day referral if confirmed and he has no symptoms, emergency referral if symptoms suggest hypertensive emergency. Defer spinal manipulation until the pressure is addressed.

WORKED CASE 2 · A HISTORY ONLY STATION

Door card: Robert, 58, low back pain for 3 weeks. Task: take a focused history. No physical examination in this station.

STEP 1 · READ THE VERB

History only. Palpation or range of motion earns nothing and spends time.

STEP 2 · OPEN AND START BROAD

Hygiene, introduce, confirm identity, ask permission. "Tell me about your back pain," then work through OPQRST.

STEP 3 · PRIORITIZE RED FLAGS FOR HIS AGE

Cancer history, unexplained weight loss, night or rest pain, fever, recent infection or IV drug use, trauma, steroid use, bowel or bladder change, saddle numbness, progressive leg weakness, anticoagulants, and tearing pain or abdominal pulsation for aneurysm.

STEP 4 · CLOSE

Summarize back to the patient, say the next step would be an examination, and ask for questions. The critical items are the cancer and weight loss questions, the cauda equina questions and the summary.

WORKED CASE 3 · THE STOP RULE DURING A SET UP

Door card: Linda, 41, neck pain. Task: demonstrate a set up for a right rotation restriction at C1 to C2, no thrust. During your screening she says the pain began yesterday after a quick head turn, with the worst headache of her life and double vision since.

STEP 1 · STOP

This is the real test of the station. Do not proceed with a cervical set up.

STEP 2 · ASK THE POSTERIOR CIRCULATION SCREEN

Dizziness, slurred speech, trouble swallowing, unsteadiness, numbness of the face or limbs. Check for nystagmus and gait if it does not delay care.

STEP 3 · EXPLAIN AND ACT

Tell her calmly that her symptoms could signal a problem with an artery in the neck, that adjusting is not safe, and that you are calling emergency services now. Stay with her.

STEP 4 · DOCUMENT

Record the symptoms, findings, time and actions taken.

TRAPS PEOPLE FALL INTO

- **Doing a task the card did not ask for.** A perfect exam in a history only station earns nothing.
- **Silent testing.** A test with no stated result gives the observer nothing to mark.
- **Leading questions.** "You don't have bladder problems, do you?" invites a reflexive no. Ask neutral questions.
- **Skipping the opening.** Hygiene, introduction, identity and consent are easy points lost in the first 20 seconds.
- **Ignoring the time warning.** Move to your close. A plan beats two more orthopedic tests.

- **Treating consent as a signature.** It is a process, and it can be withdrawn at any moment.
- **Repeating a painful test to confirm it.** Stop, note the angle and the pain, and do not repeat it.
- **Delivering a real thrust by default.** Thrust only if the station explicitly permits it; otherwise simulate and say so.

Chapter 1 self-test · ten items

1. A door card reads: "Perform a focused lumbar examination." What earns the most credit in this station?

A. A complete history with every red flag question asked in order
B. The examination tests, each explained and each result stated aloud
C. A full spinal adjustment set up delivered after the examination
D. A detailed patient note written while the patient is still present

B. The examination tests, each explained and each result stated aloud The verb on the door card defines the checklist. Here it is examination, and silent results cannot be scored.

2. During a history, an SP with back pain never mentions taking an anticoagulant. Why is this most likely?

A. The case writer expects the drug to come up during the exam
B. SPs are often instructed to reveal only what they are asked
C. The anticoagulant is irrelevant to a back pain station
D. The examiner will provide the drug list after the encounter

B. SPs are often instructed to reveal only what they are asked Information you do not ask for does not exist in an SP station. Medications belong in every red flag screen.

3. Which description best fits a global rating in a practical station?

A. A single checklist item marked done or not done by the standardized patient
B. An automatic station failure for skipping a safety screen
C. A holistic score for communication, organization and professionalism
D. A time penalty for running past the encounter signal

C. A holistic score for communication, organization and professionalism Global ratings capture what checklists miss, such as flow and respect. A rough or brusque candidate can score poorly despite a full checklist.

4. A candidate performs a Spurling test, sees the patient wince and moves on. What has the candidate failed to do?

A. Repeat the test on the same side to confirm the response
B. Ask the examiner whether the response counts as positive
C. State the result and what it suggests about the nerve root
D. Perform the test again with a stronger downward pressure on the head

C. State the result and what it suggests about the nerve root Verbalizing turns a hand movement into scorable technique, communication and interpretation. Repeating a painful test is not good practice.

5. The time warning sounds while you are halfway through your orthopedic tests. What should you do?

A. Move to findings, diagnosis, plan, consent and questions
B. Finish every remaining test, then speak as quickly as possible
C. Ask the examiner for one extra minute to complete the plan
D. Return after the signal to state the plan you did not reach

A. Move to findings, diagnosis, plan, consent and questions The warning is a hard trigger to close. A stated plan is worth more than the last two tests, and you do not return after the end signal.

6. Which element of the door card routine comes first in the five step reading pattern?

A. The task verbs
B. Your first three steps
C. Name, age and sex
D. The vital signs

C. Name, age and sex The routine runs name, age and sex; complaint and duration; vital signs; task verbs; then your first three steps.

7. In a technique station a real thrust is not permitted. What is the expected behavior?

A. Skip the set up and describe the adjustment in words from a standing position
B. Deliver a light thrust at half force so the examiner can see the direction
C. Take the contact only and leave the stance and preload unstated
D. Set up fully, preload, state the line of drive and say you would now thrust

D. Set up fully, preload, state the line of drive and say you would now thrust A simulated thrust still shows the complete set up and the verbalized line of drive, without delivering the impulse.

8. During a straight leg raise the patient says, "Ow, stop." What is the correct first action?

A. Hold the position briefly to note the exact angle first
B. Lower the leg at once and ask where the pain was felt
C. Repeat the test more slowly to confirm the finding
D. Continue to the dorsiflexion step to finish the test

B. Lower the leg at once and ask where the pain was felt The stop rule is stop, release and reassess. Note the angle and location, state it as a finding, and do not repeat the test.

9. A patient declines the proposed adjustment after your consent explanation. What should you do?

A. Accept the decision, document it and offer alternatives
B. Repeat the risk statement until the patient agrees to proceed
C. Perform a gentler adjustment without further discussion
D. End the station without discussing any other options

A. Accept the decision, document it and offer alternatives Consent must be voluntary. A refusal is respected, recorded and followed by reasonable alternatives.

10. Which SOAP entry shows a common documentation error?

A. Subjective: "denies bowel or bladder change"
B. Plan: "refer for same day medical evaluation"
C. Objective: "SLR positive left at 40 degrees"
D. Objective: "ortho tests negative"

D. Objective: "ortho tests negative" Tests must be named, with side and result. "Ortho tests negative" tells a reader nothing about what was done.

CHAPTER 2

Reading Films Under Time: Approach and Normal Anatomy

Read it in full: **Chapter 2 in the textbook**. Practice it: **the practice exams** and **the flashcards**.

What to know

An imaging station gives you a film, a short history and very little time. It scores what you find, how you describe it and what you recommend. The candidates who do well search every film the same way, know normal anatomy and its variants well enough that abnormal stands out, and can say a clear one line impression and a safe recommendation before the signal. A fixed search costs about 30 to 60 seconds per film once practiced.

Start with a five second **label check**: name and age (age changes the differential more than any other single fact), date, view, side marker, and whether the film is weight bearing. Check quality. A rotated lateral cervical film doubles the posterior margins and can mimic subluxation, and an underpenetrated film hides lytic lesions. If the films are inadequate, recommending more views is a legitimate answer. Then take a two second **global look** from a distance for overall density, alignment and asymmetry, which catches large findings that a close search can miss.

Then run **ABCS**. Alignment covers curves, contour lines and joint congruity. Bone covers size, shape, density, the cortex traced all the way around, the pedicles on AP spine views, endplates and posterior elements. Cartilage covers disc heights and joint spaces, uniform versus nonuniform narrowing, erosions and osteophytes. Soft tissue covers prevertebral tissue, paraspinal lines, psoas shadows, lung apices, aorta, kidneys, bowel gas and calcifications. The letters matter less than using one version every time. Finish with the **review areas** and the edges, because the board likes to hide a finding outside the stated region. A lumbar film also shows ribs, kidneys, aorta, iliac wings, SI joints and hips.

Satisfaction of search is stopping after the first abnormality. The obvious spondylolisthesis hides the renal stone, and degenerative change hides the lytic metastasis. Prevent it three ways: finish the pattern after a finding, ask what the finding is associated with, and look at the review areas last, on purpose. On an AP lumbar film, count the pedicles at every level. A missing pedicle in an older adult (the "winking owl" sign) is metastasis until proven otherwise; myeloma tends to spare the pedicle early.

On the neutral lateral cervical film, trace four smooth lines: the anterior vertebral line, the posterior vertebral line (George's line), the spinolaminar line and the posterior spinous line. A step in any line suggests subluxation, dislocation or fracture. The **atlantodental interval** (ADI) is 3 mm or less in adults and up to 5 mm in children; widening suggests transverse ligament insufficiency from trauma, rheumatoid arthritis, Down syndrome or inflammatory disease. Adult **prevertebral soft tissue** is about 7 mm or less at C2 and about 22 mm or less at C6 (about 14 mm at C6 in children); widening suggests hematoma, infection or mass. All seven cervical vertebrae and the top of T1 must be visible. A sagittal canal near 10 mm or less, or a Torg ratio under about 0.8, suggests a narrow canal.

On the open mouth view, the C1 lateral masses line up with C2. Overhang suggests a Jefferson fracture, and a combined overhang over about 7 mm suggests transverse ligament disruption (the rule of Spence). Mimics of a dens fracture include the Mach band, which extends beyond the bone and changes with a repeat view, and the subdental synchondrosis, which fuses at about 3 to 6 years. The ossiculum terminale is a normal variant. **Os odontoideum** is not: it may be unstable and needs flexion and extension evaluation before any upper cervical manipulation. A ponticulus posticus is common and benign, but many clinicians modify forceful rotatory upper cervical techniques, so mention it.

In children, **pseudosubluxation** of C2 on C3 up to about 3 to 4 mm is normal. Draw the posterior cervical (Swischuk) line from the C1 to the C3 spinous process; the anterior cortex of the C2 spinous should sit within about 2 mm. In the thoracic and lumbar spine, know the mimics: the limbus vertebra (corticated corner fragment), Schmorl nodes, the Cupid's bow, Hahn clefts, transitional segments, spina bifida occulta, facet tropism, cervical ribs and mild physiologic wedging of T11 to L1. With a transitional segment, say how you numbered.

On the AP pelvis, **Shenton's line** is a smooth arc from the superior pubic ramus onto the medial femoral neck; a break suggests femoral neck fracture, dislocation or dysplasia. **Klein's line** along the superior femoral neck should cut part of the epiphysis; if it misses, think slipped capital femoral epiphysis (SCFE). The acetabular floor should stay lateral to **Kohler's line**; if not, the finding is protrusio acetabuli. Growth plates are smooth, symmetric and predictable; fractures are sharp, uncorticated and unexpected. Comparison views are a legitimate recommendation. Elbow ossification follows CRITOE (about 1, 3, 5, 7, 9 and 11 years); the order matters more than the ages. The anterior humeral line should pass through the middle third of the capitellum, the radiocapitellar line should hit the capitellum on every view, and a posterior fat pad or raised anterior fat pad after trauma means occult fracture. Accessory ossicles are smooth, rounded and corticated; acute fragments are sharp with a matching donor defect.

Every spine film is also a chest or abdominal film. Judge the chest first: PA erect, clavicle heads equidistant from the spinous processes, about 9 to 10 posterior ribs of inspiration, and vertebrae faintly visible through the heart. The right heart border is the right atrium; the left border is the aortic knob, pulmonary trunk, left atrial appendage and left ventricle. The cardiothoracic ratio is

under 0.5 on a PA film; do not call cardiomegaly from an AP film. The left hilum sits higher than the right, the right hemidiaphragm about 1.5 to 2 cm higher than the left. The **silhouette sign** localizes disease: a lost right heart border means right middle lobe, a lost left heart border means lingula. Phleboliths, costal cartilage calcification and healed granulomas are normal; aortic walls 3 cm or more apart suggest aneurysm.

Describe before you diagnose: location, morphology, margins and **zone of transition**, matrix, periosteal reaction, cortex and soft tissue, plus age. A narrow zone means slow; a wide zone, moth eaten or permeative destruction means aggressive, and infection can look as aggressive as malignancy. Solid periosteal reaction is slow; lamellated, spiculated and Codman triangle reactions are aggressive. Then give a one line impression and a recommendation that answers three questions: more imaging or tests, referral and how urgent, and whether manipulation of the region is safe.

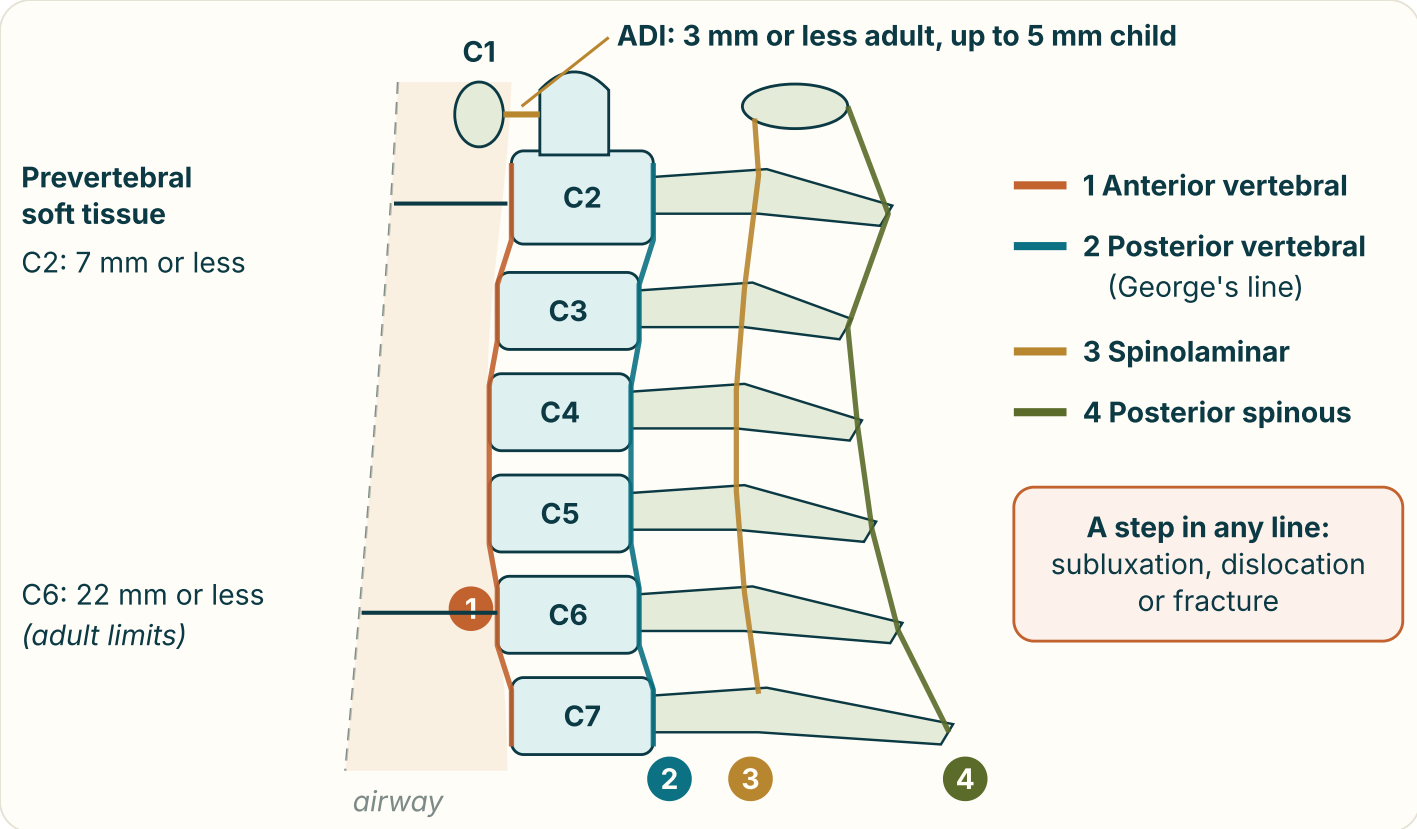

Lines and spaces on the lateral cervical film. Trace four smooth curves on every lateral cervical film and check the two spaces most often tested. A step in any line suggests subluxation, dislocation or fracture.

LOCK THESE IN

- Every film: label check, global look, ABCS, then review areas and edges.
- Finish the pattern after the first finding; that beats satisfaction of search.
- ADI 3 mm or less adults, up to 5 mm children; prevertebral tissue about 7 mm at C2 and 22 mm at C6.
- Os odontoideum is not a normal variant; it needs flexion and extension views before upper cervical work.
- Pseudosubluxation: C2 spinous within about 2 mm of the posterior cervical line.
- Shenton smooth, Klein cuts the epiphysis, acetabulum lateral to Kohler.
- Cardiothoracic ratio under 0.5 applies to a PA film only.
- Recommendation covers imaging, referral urgency and whether the region can be manipulated.

Normal values and lines

Measure	Commonly taught normal	Abnormal suggests
ADI (lateral cervical)	3 mm or less adult; up to 5 mm child	Transverse ligament insufficiency
Prevertebral soft tissue	About 7 mm at C2; about 22 mm at C6 (14 mm child)	Hematoma, infection, mass
Sagittal canal, lower cervical	More than about 12 to 13 mm	Stenosis near 10 mm or less; Torg ratio under 0.8
C1 lateral mass overhang	Aligned with C2	Jefferson fracture; over 7 mm total, ligament disruption
Posterior cervical line (child)	C2 spinous within about 2 mm	True injury such as a hangman fracture
Shenton's line	Smooth arc	Femoral neck fracture, dislocation, dysplasia
Klein's line	Intersects the lateral epiphysis	SCFE
Kohler's line	Acetabular floor lateral to it	Protrusio acetabuli
Femoral neck shaft angle	About 120 to 135 degrees	Coxa vara or coxa valga
Center edge angle	Over about 25 degrees	Acetabular dysplasia when low
Chest inspiration	9 to 10 posterior ribs	Poor inspiration widens heart, crowds bases
Cardiothoracic ratio (PA)	Under 0.5	Cardiomegaly (not on AP film alone)
Abdominal aorta	Walls under 3 cm apart	3 cm or more suggests aneurysm
Bowel diameter rule	3, 6, 9 cm (small bowel, colon, cecum)	Dilation

Aggressive or not

Feature	Nonaggressive (slow)	Aggressive (fast)
Zone of transition	Narrow, sclerotic rim	Wide, fades into normal bone
Destruction pattern	Geographic (IA, IB)	III defined geographic, moth eaten, permeative
Periosteal reaction	None or solid, smooth	Lamellated, spiculated, Codman triangle
Cortex	Intact or smoothly expanded	Destroyed
Soft tissue	No mass	Soft tissue mass

Worked cases

WORKED CASE 1 · THE FINDING HIDDEN IN FRONT OF THE SPINE

Lateral lumbar film, 68 year old male smoker with low back pain. Task: interpret and recommend.

STEP 1 · LABEL AND GLOBAL LOOK

68 year old man, lateral lumbar, adequate.

STEP 2 · ABCS

Multilevel disc narrowing and anterior osteophytes at L2 to L5. A satisfying finding, but do not stop.

STEP 3 · SOFT TISSUE PASS

A curvilinear rim of calcification bulges anterior to L2 to L4. Aortic walls about 3 cm or more apart suggest aneurysm, and the calcified wall may underestimate the true size.

STEP 4 · IMPRESSION

Multilevel degenerative disc disease; suspected abdominal aortic aneurysm.

STEP 5 · RECOMMENDATION

Abdominal ultrasound or CT and medical referral; emergency if severe or tearing pain, hypotension or a tender pulsatile mass. No lumbar manipulation or prone pressure until evaluated.

WORKED CASE 2 · A CHILD'S STEP AT C2 TO C3

Lateral cervical film of a 7 year old after a fall from monkey bars. He moves his neck freely and has no midline tenderness. C2 sits about 3 mm forward on C3.

STEP 1 · DO NOT CALL IT YET

Children have normal laxity and horizontal facets.

STEP 2 · DRAW THE LINE

The posterior cervical line runs from the C1 to the C3 spinous process. The anterior cortex of the C2 spinous falls within 1 mm of it, inside the 2 mm limit.

STEP 3 · CHECK THE REST

No fracture lines; the subdental synchondrosis is a normal lucency; the retropharyngeal space is normal.

STEP 4 · REPORT

Physiologic pseudosubluxation of C2 on C3; no evidence of acute injury. Correlate clinically, re-evaluate urgently if neurologic signs or midline tenderness develop, and avoid forceful cervical thrust in a recently injured child.

WORKED CASE 3 · KNEE PAIN, HIP FILM

AP pelvis of a 13 year old overweight boy with 4 weeks of left knee pain and a limp.

STEP 1 · WHY THE PELVIS

Knee pain in an adolescent can be referred from the hip.

STEP 2 · DRAW KLEIN'S LINE

On the left it misses the femoral epiphysis; on the right it cuts it. The left physis is widened and indistinct.

STEP 3 · IMPRESSION

Slipped capital femoral epiphysis, left.

STEP 4 · RECOMMENDATION

Same day orthopedic referral, non weight bearing with crutches, a frog leg lateral if available, and no hip or lumbopelvic manipulation. Explain why to the patient and parent.

TRAPS PEOPLE FALL INTO

- **Stopping at the first finding.** Degenerative change is a classic cover for an aneurysm or a lytic lesion.
- **Calling cardiomegaly on an AP film.** The 0.5 ratio is for a PA film; check inspiration first.
- **Calling os odontoideum a variant.** It may be unstable; the ossiculum terminale is the normal variant.
- **Overcalling a child's C2 slip.** Use the posterior cervical line before calling injury.
- **Calling a corticated ossicle a fracture.** Fractures are sharp and uncorticated with a donor defect.
- **Reading the fifth metatarsal apophysis as a fracture.** The apophysis runs parallel to the shaft; a fracture runs transverse.
- **Mislabeling a level.** With a transitional segment, say how you counted.

- **Diagnosing before describing.** A correct description and safe recommendation earn credit even if the label is off.

Chapter 2 self-test · ten items

1. Which statement best describes satisfaction of search?

A. Feeling confident once the label check has been completed
B. Searching only the region named on the door card task
C. Ending the search after one abnormality and missing a second
D. Finishing a film quickly enough to leave time for the report

C. Ending the search after one abnormality and missing a second Satisfaction of search is stopping once one finding is made. Finishing the pattern and checking review areas last prevents it.

2. On an adult lateral cervical film, which atlantodental interval is abnormal?

A. 5 mm
B. 2 mm
C. 3 mm
D. 1 mm

A. 5 mm The adult ADI is 3 mm or less. Up to 5 mm is accepted only in children.

3. An adult lateral cervical film shows prevertebral soft tissue of 12 mm at C2. What does this suggest?

A. A normal finding for the retrotracheal space
B. Poor inspiration on the lateral exposure
C. A rotated film doubling the posterior margins
D. Swelling from hematoma, infection or mass

D. Swelling from hematoma, infection or mass The commonly taught adult limit at C2 is about 7 mm, so 12 mm is widened. About 22 mm is the limit at C6.

4. A smooth ossicle sits above a short dens with a corticated gap. What is the safest step before upper cervical manipulation?

A. No further step, since it is a normal variant
B. Flexion and extension evaluation for instability
C. Repeat the open mouth view with the mouth wider
D. Comparison views of the opposite side of the neck

B. Flexion and extension evaluation for instability This describes os odontoideum, which may be unstable. The ossiculum terminale is the normal variant.

5. In a child, how do you separate pseudosubluxation of C2 on C3 from true injury?

A. Check that the C2 spinous lies within about 2 mm of the C1 to C3 line
B. Measure the ADI and confirm that it is under 3 mm
C. Confirm that the prevertebral tissue at C6 is under 22 mm
D. Look for overhang of the C1 lateral masses on the open mouth view of the neck

A. Check that the C2 spinous lies within about 2 mm of the C1 to C3 line The posterior cervical (Swischuk) line runs from the C1 to the C3 spinous process. More than about 2 mm of deviation suggests true injury.

6. On an adolescent's AP pelvis, Klein's line fails to intersect the femoral epiphysis on one side. What is the likely diagnosis?

A. Protrusio acetabuli
B. Developmental dysplasia of the hip joint
C. Slipped capital femoral epiphysis
D. Femoral neck stress fracture

C. Slipped capital femoral epiphysis Klein's line along the superior femoral neck should cut part of the epiphysis. When it misses, think SCFE.

7. On a PA chest film the right cardiac silhouette has disappeared. Which lobe holds the density?

A. The right lower lobe base
B. The lingula
C. The left upper lobe
D. The right middle lobe

D. The right middle lobe The silhouette sign: the right heart border is lost when the adjacent right middle lobe fills. A lost left heart border means lingula.

8. Round pelvic calcifications with lucent centers lie below the ischial spines of a 60 year old. What are they most likely to be?

A. Ureteral stones needing referral
B. Calcified mesenteric lymph nodes
C. Uterine fibroid calcification
D. Phleboliths, a normal finding

D. Phleboliths, a normal finding Phleboliths are round with a lucent center, low in the pelvis. Ureteral stones are often angular, follow the ureter and lack the lucent center.

9. Which feature points most strongly to an aggressive bone lesion?

A. A sclerotic rim around a lucency
B. A wide zone of transition
C. Solid, smooth periosteal new bone
D. A smoothly expanded intact cortex

B. A wide zone of transition The zone of transition is the best single indicator of activity. A wide zone means the lesion is outpacing the bone's response.

10. A film shows a lesion suspicious for metastasis. Which recommendation is complete?

A. Clinical correlation, with care to continue under usual precautions
B. Repeat plain films in six weeks before any change in the care plan
C. Advanced imaging and labs, prompt referral, no manipulation of the region
D. Emergency services now, cervical immobilization and staying with the patient

C. Advanced imaging and labs, prompt referral, no manipulation of the region A complete recommendation addresses imaging or tests, referral urgency and the safety of manipulation. Suspected malignancy calls for prompt referral and no manipulation of the region.

ONE PAGE

Cram sheet

Everything from chapters 1 and 2 in one place. Cover the right column and see if you can rebuild each row.

Station habits

Item	The rule	Note
Door card	Name, age, sex; complaint; vitals; task verbs; first three steps	The verb defines the checklist
Opening	Hygiene, name and role, identity, agenda, comfort	Easy points in the first 20 seconds
Scoring	Checklists, critical actions, global ratings	If it is not said, it is not scored
Verbalize	Test, side, result, meaning; listing, contacts, stabilization, line of drive	State pertinent negatives
Simulated thrust	Full set up, tissue pull, preload, stated line of drive	"I would now deliver a high velocity, low amplitude thrust"
Time warning	Move to findings, diagnosis, plan, consent, questions	Never return after the end signal
Consent	Nature, material risks, benefits, alternatives, right to stop	Separate consent to examine and to treat
Stop rule	Stop, release, reassess	Neuro or vascular signs: emergency services
Sensitive exams	Never in a station	State you would do it with consent and chaperone, or refer
SOAP	Negatives in S, named tests in O, reasoning in A, referral in P	Document only what you did

Red flags and responses

Finding	Suspect	Response
Saddle anesthesia, retention, bilateral weakness	Cauda equina	Emergency referral
Sudden neck pain or headache with dizziness, diplopia, dysarthria	Cervical artery dissection	No manipulation; emergency services
Over 50, cancer, weight loss, night pain	Malignancy	Urgent imaging and referral
Fever, IV drug use, immunosuppression	Infection	Urgent referral
Pulsatile mass, tearing pain	Aortic aneurysm	No lumbar adjusting; emergency if symptomatic
Exertional chest pain	Acute coronary syndrome	Stop; emergency services
RA, Down syndrome, upper cervical trauma	Atlantoaxial instability	Imaging clearance before upper cervical work

Film numbers

Item	Value	Note
ADI	3 mm or less adult; up to 5 mm child	Transverse ligament
Prevertebral tissue	About 7 mm at C2; 22 mm at C6	14 mm at C6 in children
C1 overhang	Over 7 mm total	Rule of Spence
Pseudosubluxation	C2 spinous within about 2 mm of C1 to C3 line	Up to 3 to 4 mm slip normal in children
Chest	9 to 10 posterior ribs; CT ratio under 0.5 on PA	Mediastinum under about 8 cm
Aorta	Walls 3 cm or more apart	Suspected aneurysm
CRITOE	About 1, 3, 5, 7, 9, 11 years	Order matters most
Neck shaft angle	About 120 to 135 degrees	Vara smaller, valga larger

Dr. Garg Learning · CC BY-SA 4.0