Final Review Study Guide

The final review covers all fourteen chapters. Each chapter here is shorter than in the study guides: four paragraphs of what to know, the diagram, the points to lock in, one table, one worked case, the traps and six new self-test items. If a chapter feels shaky, go back to its study guide for the full treatment. The long cram sheet at the end pulls every number in the course into one place. Two chapters a day fits the whole review into a week.

WHAT THIS GUIDE COVERS

- History and examination: chapters 1 to 4 (case history; general physical; spinal NMS exam; extremity, neurologic and vascular exam).
- Ordering and reading tests: chapters 5 and 6 (imaging decisions; laboratory and special studies).
- Clinical impression: chapters 7 and 8 (musculoskeletal and neurologic; systemic, visceral and special populations).
- Treatment and management: chapters 9 to 11 (technique decisions; supportive interventions; case management).
- Image interpretation: chapters 12 to 14 (arthritis; anomalies, scoliosis and trauma; tumors, metabolic disease and soft tissue).
- Every chapter carries a diagram, a table, a worked case, the traps and a six item self-test; the cram sheet holds all the numbers.

CHAPTER 1

The Case History

Read it in full: **Chapter 1 in the textbook**. Practice it: **the Study Guide 1 practice exam** and **the flashcards**.

What to know

The history alone points to the right diagnosis in about 70 to 80 percent of patients. It sorts spinal pain into serious pathology (about 1 to 2 percent), radicular syndrome (about 5 to 10 percent) and

nonspecific mechanical pain (about 90 percent). Record the chief complaint in the patient's words, then run OPQRST or OLDCARTS.

Flexion intolerance and cough aggravation suggest disc; extension intolerance suggests facets or stenosis. Neurogenic claudication eases with sitting or bending forward; vascular claudication eases by standing still. Mechanism predicts tissue: lift and twist for disc, axial load for burst fracture at T11 to L2, hyperextension for the pars, minimal trauma in an older or steroid treated patient for an osteoporotic fracture.

Prior cancer is the strongest history predictor of spinal malignancy (LR about 15). Urinary retention is the most sensitive cauda equina finding (about 90 percent). Screen the neck for dissection with the 5 Ds and 3 Ns. Visceral pain does not change with movement but does with eating, urination or menstruation.

Yellow flags (fear avoidance, catastrophizing, low mood, compensation) predict chronicity; screen with STarT Back. Use open questions first, a trained interpreter, pertinent negatives in the record and single line corrections with date, time and initials.

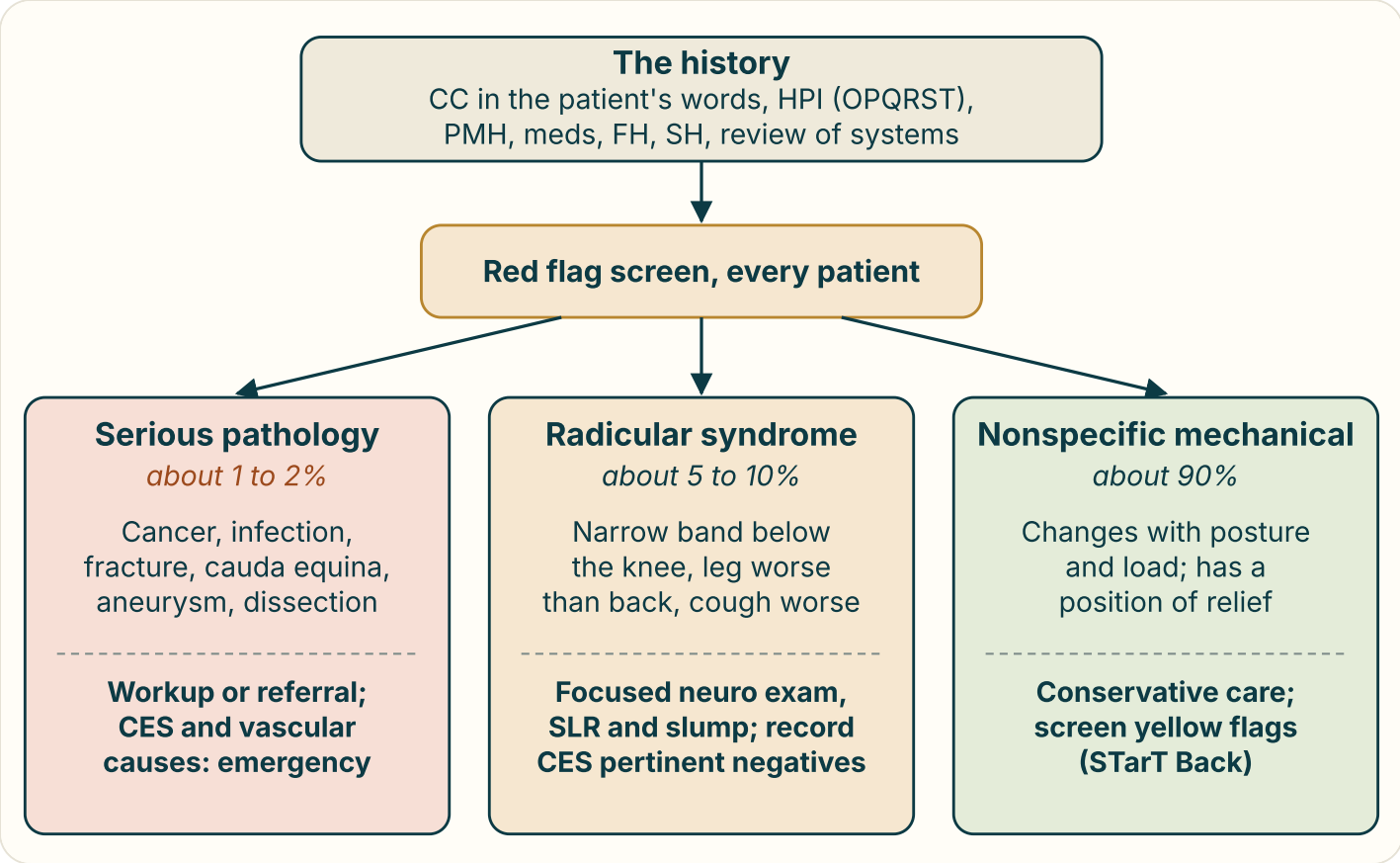

Three diagnostic bins. The history sorts most spinal pain patients before the exam begins. The red flag screen comes first, because the smallest bin holds the patients who must not be missed.

LOCK THESE IN

- Bins: serious 1 to 2%, radicular 5 to 10%, mechanical about 90%.
- Flexion intolerance means disc; extension intolerance means facet or stenosis.
- Neurogenic claudication: sit or bend to relieve. Vascular: stand still.
- Prior cancer LR+ about 15; urinary retention about 90% sensitive for CES.
- Dissection screen: 5 Ds and 3 Ns before any neck care.
- Red flags predict disease; yellow flags predict chronicity.

OPQRST answers and what they suggest

Element	Answer	What it suggests
Onset	Sudden with a specific load (lift and twist)	Mechanical injury: disc, facet, muscle strain
Onset	Insidious, steadily worsening, no event	Degenerative, inflammatory, neoplastic or infectious; ask red flag questions
Onset	Sudden, severe, "worst ever," no trauma	Vascular (dissection, aneurysm, hemorrhage) until proven otherwise
Provocation	Sitting, bending, cough, sneeze, strain	Discogenic or radicular
Provocation	Standing, extension, walking downhill	Facet joint or stenosis
Palliation	Nothing helps; or exercise helps, rest does not	Nonmechanical; exercise relief suggests spondyloarthritis
Quality	Burning, electric, shooting; or tearing	Neuropathic or radicular; tearing suggests dissection
Region	Narrow band below the knee to the foot	Radicular pain
Region	Diffuse buttock and thigh, stops above the knee	Somatic referred pain (facet, SI joint, disc)
Timing	Morning stiffness over 30 to 60 minutes	Inflammatory arthritis
Timing	Night pain unrelieved by position	Red flag: tumor or infection

Worked cases

WORKED CASE 1 · THE NEXT HISTORY QUESTION

A 39 year old carpenter lifted and twisted a sheet of plywood. Two days later he has burning pain down the back of the left thigh and calf to the little toe, worse sitting and with coughing. What should you ask next,

and why?

STEP 1 · READ THE PATTERN

Flexion plus rotation under load, leg pain below the knee in an S1 band and cough aggravation point to a posterolateral L5 to S1 disc herniation with S1 radicular pain.

STEP 2 · FIND THE QUESTION THAT CHANGES MANAGEMENT

With leg symptoms from a probable disc, the cauda equina screen is the question whose answer moves the case from conservative care to the emergency department.

STEP 3 · ASK IT IN PLAIN WORDS

"Any trouble starting or stopping your urine, any leaking, any numbness between your legs, any change in bowel control?"

STEP 4 · DOCUMENT BOTH WAYS

Record the negative answers as pertinent negatives, then focus the exam: SLR, slump, plantarflexion strength, Achilles reflex and lateral foot sensation.

TRAPS PEOPLE FALL INTO

- **Writing a diagnosis as the chief complaint.** Record the patient's words and duration. "Sciatica" or "subluxation" closes the mind too early.
- **Mixing up the two claudications.** Neurogenic needs sitting or bending forward; vascular eases by standing still and also hurts on a bike.
- **Treating each red flag as equal.** Most are weak alone. Prior cancer is strong (LR about 15); age over 50 alone is about 2.7.
- **Skipping the cauda equina screen.** Ask about urinary retention, leaking, saddle numbness and bowel change in every back pain patient with leg symptoms, and write down the negatives.
- **Calling yellow flags malingering.** Fear of movement and a pending claim predict slow recovery. They call for education and graded activity, not suspicion.

Chapter 1 self-test · six items

1. A 44 year old man has pain in a narrow band from the buttock to the lateral foot, worse with sneezing. What is the best term for this pain?

A. Nociplastic pain from central sensitization
B. Somatic referred pain from a facet joint
C. Visceral referred pain from the bladder
D. Radicular pain from an irritated nerve root

D. Radicular pain from an irritated nerve root Sharp pain in a narrow band below the knee, worse with Valsalva, is radicular pain from a sensitized root.

2. A 75 year old woman on long term prednisone felt sharp thoracic pain after a cough. What should happen before any manual therapy?

A. A trial of thrust manipulation at a low force
B. An MRI only if pain persists past six weeks
C. Thoracic radiographs to exclude a compression fracture
D. A home exercise program and a review visit in about a month

C. Thoracic radiographs to exclude a compression fracture Minimal trauma, age and steroid use make an osteoporotic compression fracture likely. Thrust is contraindicated until fracture is excluded.

3. A 27 year old woman has colicky right flank pain into the groin, cannot keep still, and has pink urine. What must also be asked?

A. Whether she sleeps on her right side
B. The date of her last menstrual period
C. How many hours a day she sits at work
D. Whether a sibling has scoliosis

B. The date of her last menstrual period This fits a ureteral stone, but ectopic pregnancy is the must not miss alternative in a woman of reproductive age.

4. A clinician decides "muscle strain" because the patient mentioned yard work, despite night pain and weight loss. Which error is this?

A. Anchoring on the first impression
B. Confirmation of a sensitive finding
C. Availability bias from a recent case
D. Appropriate use of pattern recognition

A. Anchoring on the first impression Anchoring holds onto the first impression despite contradicting red flags, often with premature closure.

5. Which question best separates neurogenic from vascular claudication?

A. Does the pain wake you at night most nights?
B. Did the pain begin after a lifting injury?
C. Is the pain worse in the morning on rising?
D. Does standing still relieve it, or must you sit?

D. Does standing still relieve it, or must you sit? Vascular claudication eases by standing still. Neurogenic claudication needs sitting or bending forward.

6. Which tool stratifies low back pain patients into low, medium or high risk of a poor outcome?

A. The PHQ-2 depression screen
B. The STarT Back Screening Tool
C. The Oswestry Disability Index
D. The Neck Disability Index

B. The STarT Back Screening Tool STarT Back has nine items and matches treatment intensity to risk. The Oswestry tracks function.

The General Physical Examination

Read it in full: **Chapter 2 in the textbook**. Practice it: **the Study Guide 1 practice exam** and **the flashcards**.

What to know

Measure blood pressure seated with the right cuff (a small cuff reads high) and palpate first to avoid an auscultatory gap. Stage 2 starts at 140 or 90; over 180 and/or 120 with target organ symptoms is an emergency. Orthostatic hypotension is a fall of 20 systolic or 10 diastolic within 3 minutes. Fever is 38.0 °C or more; qSOFA flags sepsis.

Weber goes to the bad ear in conductive loss and the good ear in sensorineural loss. Dull with increased fremitus is consolidation; dull with decreased fremitus is effusion. Aortic stenosis radiates to the carotids, mitral regurgitation to the axilla, and HCM gets louder with Valsalva. A JVP over 3 cm above the sternal angle is raised.

ABI is the higher ankle pressure over the higher arm pressure; 0.90 or less is PAD and over 1.40 is noncompressible. Examine the abdomen inspect, auscultate, percuss, palpate. An expansile mass above the umbilicus (3 cm or more) is AAA; tender with back pain is an emergency.

Torsion has an absent cremasteric reflex (L1 to L2) and needs surgery within about 6 hours. Saddle sensation tests S2 to S5, the anal wink S2 to S4. List every abnormal finding and assign treat, co-manage or refer.

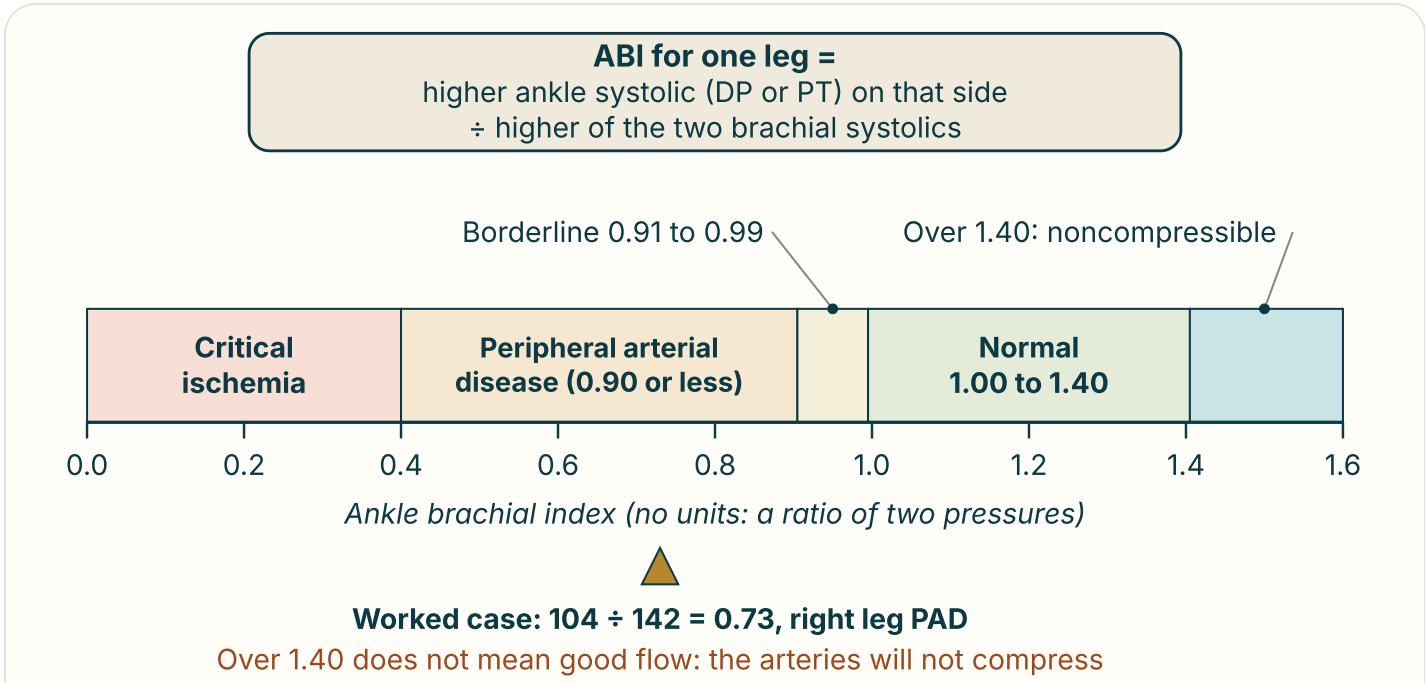

The ABI on a true scale. Divide the higher ankle pressure on each side by the higher arm pressure. An ABI of 0.90 or less defines peripheral arterial disease, and a value over 1.40 means stiff, calcified vessels, not better circulation.

LOCK THESE IN

- Small cuff reads high; over 180/120 with symptoms is an emergency.
- Orthostatic: 20 systolic or 10 diastolic within 3 minutes.
- Weber: bad ear in conductive, good ear in sensorineural loss.
- ABI 0.90 or less is PAD; over 1.40 is calcified.
- AAA is 3 cm or more; tender plus back pain means transfer now.
- Torsion: absent cremasteric reflex; epididymitis: Prehn sign.

Vital signs and thresholds

Measure	Value	Meaning or action
Blood pressure	Under 120 and under 80	Normal
Blood pressure	130 to 139 or 80 to 89; 140 or 90 and above	Stage 1; stage 2 (confirm and refer to primary care)
Blood pressure	Over 180 and/or over 120	No symptoms: same or next day contact; with target organ symptoms: emergency
Orthostatic drop	20 systolic or 10 diastolic within 3 min	Dizziness on rising, fall risk
Pulse	60 to 100; irregularly irregular	Atrial fibrillation: stroke risk, refer if new
Respirations	12 to 20; over 24 is a marker of serious illness	qSOFA uses 22 or more
Temperature	38.0 °C (100.4 °F) or higher	Fever; with back pain think spinal infection
SpO_2	95 to 100%; under 92% at rest abnormal	Under 90% is an emergency
BMI	18.5 to 24.9 normal; 30 and above obese	kg ÷ m^2
JVP	3 cm or less above the sternal angle	Higher means raised right atrial pressure
ABI	0.90 or less PAD; over 1.40 noncompressible	Higher ankle ÷ higher brachial

Worked cases

WORKED CASE 1 · CALCULATING AND READING AN ABI

A 67 year old smoker has right calf cramping after 150 meters. Brachial pressures are 142 right and 136 left. Right ankle pressures are 104 at the dorsalis pedis and 96 at the posterior tibial.

STEP 1 · PICK THE NUMERATOR

Use the higher ankle pressure on the right: 104.

STEP 2 · PICK THE DENOMINATOR

Use the higher of the two arm pressures: 142.

STEP 3 · DIVIDE

104 ÷ 142 = **0.73**.

STEP 4 · INTERPRET AND ACT

0.73 is 0.90 or less, so this is peripheral arterial disease. Refer for vascular evaluation and risk factor care, and ask about chest pain and TIA, since PAD marks systemic atherosclerosis.

TRAPS PEOPLE FALL INTO

- **Trusting a reading from a small cuff.** An undersized cuff reads falsely high. Re-measure with the right cuff before classifying.
- **Reading an ABI over 1.40 as excellent.** It means calcified, noncompressible vessels. Use a toe brachial index or duplex.
- **Using the lower arm pressure in the ABI.** The denominator is the higher of the two brachial pressures.
- **Palpating before auscultating the abdomen.** The order is inspect, auscultate, percuss, palpate, so palpation does not change bowel sounds.
- **Calling a psoas sign with fever a hip flexor strain.** Think psoas abscess, often from vertebral osteomyelitis or Crohn disease.

Chapter 2 self-test · six items

1. A patient with suspected pyelonephritis has a respiratory rate of 24, systolic pressure of 96 and is newly confused. What does this indicate?

A. Positive qSOFA, emergency care needed
B. Orthostatic hypotension from dehydration
C. Expected findings with any urine infection
D. Anxiety causing rapid shallow breathing

A. Positive qSOFA, emergency care needed Two or more of respiratory rate 22 or more, altered mentation and systolic 100 or less flag a high risk of a poor outcome.

2. A 58 year old smoker has right shoulder pain into the ring and little fingers, weight loss, ptosis and a small right pupil. What is the most likely cause?

A. Rotator cuff tendinopathy
B. A Pancoast tumor at the lung apex
C. Thoracic outlet syndrome
D. A C6 radiculopathy from a disc

B. A Pancoast tumor at the lung apex C8 to T1 symptoms plus Horner syndrome and weight loss in a smoker fit a superior sulcus tumor. Image the chest and refer.

3. Which finding over the lower chest best fits a large pleural effusion?

A. Hyperresonant, decreased sounds, trachea midline
B. Resonant, fine late inspiratory crackles
C. Dull, increased fremitus, bronchial breath sounds
D. Stony dull, decreased fremitus, trachea pushed away

D. Stony dull, decreased fremitus, trachea pushed away Fluid is stony dull and damps fremitus. A large effusion pushes the trachea away.

4. An ABI of 1.52 in a man with long standing diabetes means what?

A. Critical limb ischemia needing surgery
B. Borderline peripheral arterial disease
C. Calcified vessels; the result is unreliable
D. Excellent arterial flow in that leg

C. Calcified vessels; the result is unreliable Over 1.40 means noncompressible arteries. Use a toe brachial index or duplex ultrasound.

5. Which abdominal sign is periumbilical bruising from hemorrhage?

A. Cullen sign
B. Rovsing sign
C. Grey Turner sign
D. Murphy sign

A. Cullen sign Cullen sign is periumbilical bruising; Grey Turner sign is flank bruising.

6. Which findings fit acute epididymitis rather than torsion?

A. Sudden pain at rest with a horizontal lie
B. Pain unchanged by elevation, nausea
C. Cremasteric reflex present, pain eased by elevation
D. Absent cremasteric reflex, high riding testis

C. Cremasteric reflex present, pain eased by elevation Epididymitis keeps the cremasteric reflex and eases with elevation (Prehn sign).

CHAPTER 3

The Neuromusculoskeletal Examination of the Spine

Read it in full: **Chapter 3 in the textbook**. Practice it: **the Study Guide 2 practice exam** and **the flashcards**.

What to know

A rib hump on the Adams test means a structural curve; a scoliometer reading of about 7 degrees means a radiograph. Trendelenburg is named for the stance leg (weak gluteus medius, L5). Steppage means weak dorsiflexors; hip abduction and inversion are weak in L5 radiculopathy but spared in fibular palsy.

Screen the neck for fracture risk, instability, myelopathy and artery dysfunction before provoking it. Spurling is specific, ULTT A sensitive, and all four Wainner items give an LR+ of about 30.

Hoffmann, inverted supinator, Lhermitte and spastic gait mean myelopathy: MRI and no thrust. Positional artery tests never clear a patient.

Thoracic outlet tests count only if they reproduce symptoms. Thoracic pain that does not behave mechanically needs a red flag search; the thoracic spine holds about 70 percent of spinal metastases. SLR is positive at 30 to 70 degrees with pain below the knee; negative SLR rules out, crossed SLR rules in. Three of five Laslett tests suggest the SI joint.

Waddell signs (three or more categories) mark distress, not faking. Pain provocation is the most reliable palpation finding. An empty end feel is a red flag. PARTS needs two of four findings, one of them asymmetry or range of motion.

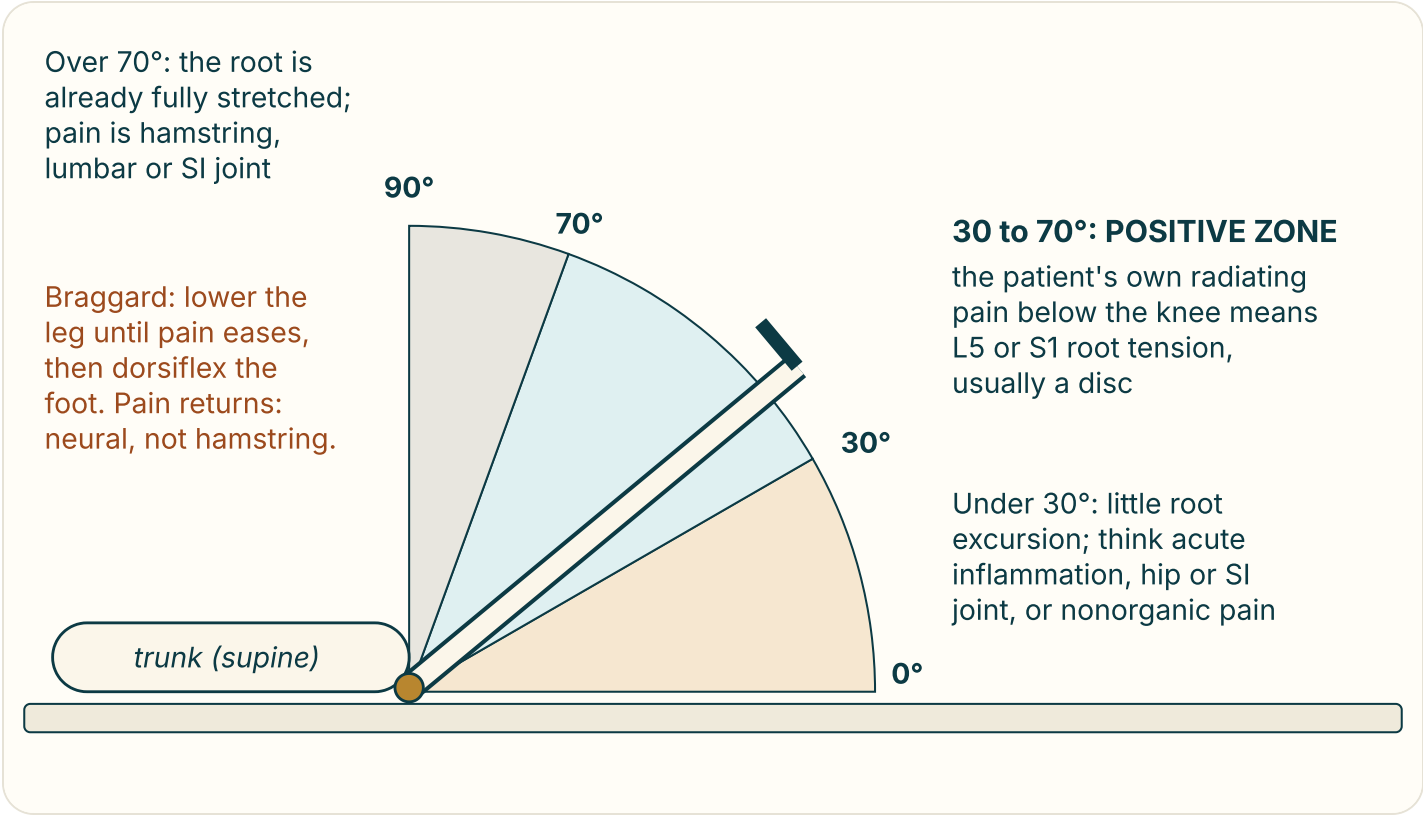

The straight leg raise by angle. Only the patient's own radiating pain below the knee between about 30 and 70 degrees counts as positive. Back pain or hamstring tightness alone does not.

LOCK THESE IN

- Scoliometer about 7 degrees or more: standing radiograph.
- Trendelenburg weakness is on the stance side.
- ULTT A rules out; Spurling and distraction rule in.
- Myelopathy: refer for MRI, no cervical thrust.
- Negative SLR rules out disc; crossed SLR rules in.
- Waddell signs mean distress; empty end feel means red flag.

Tests by value

Test	Positive finding	Value and use
Spurling	Dermatomal arm pain with lateral flexion and compression	Specificity about 0.85 to 0.95: rules in
ULTT A (median bias)	Reproduced symptoms, side to side difference	Sensitivity about 0.97: rules out when negative
Cervical distraction	Relief of arm pain	Specificity about 0.90
Wainner cluster	3 of 4 or 4 of 4 positive	LR+ about 6 or about 30
Myelopathy cluster	3 of 5 positive	LR+ about 30
Sharp Purser	Sliding reduction of the atlas	Specificity about 0.96
SLR	Radiating pain below knee at 30 to 70°	Sensitivity about 0.9, specificity about 0.25
Crossed SLR	Pain in the affected leg when the well leg is raised	Specificity about 0.9
Slump	Symptoms ease when the neck extends	About 0.84 sensitive, 0.83 specific
Laslett cluster	3 of 5, or 2 of the first 4	Sensitivity near 0.9, specificity near 0.8
Modified Schober	Increase under 5 cm on flexion	Restricted flexion; ankylosing spondylitis
Chest expansion	Under about 2.5 cm	Costovertebral AS involvement

Worked cases

WORKED CASE 1 · FOOT DROP: ROOT OR NERVE?

A 47 year old tile setter has low back pain and has started tripping over his left foot. His left foot slaps the floor, and he has knelt and sat cross legged at work for a week.

STEP 1 · NAME THE GAIT

Steppage with foot slap means weak ankle dorsiflexors.

STEP 2 · LIST THE TWO CLASSIC CAUSES

L5 radiculopathy or common fibular nerve palsy at the fibular head.

STEP 3 · RUN THE DECIDING TEST

Test hip abduction (gluteus medius) and foot inversion (tibialis posterior). Both are L5 functions, weak in radiculopathy and spared in fibular palsy.

STEP 4 · ADD THE SUPPORTING FINDINGS

Fibular palsy spares the back, limits numbness to the dorsum of the foot and lateral leg, and gives a Tinel sign at the fibular head.

STEP 5 · PLAN

A progressive motor deficit of either cause needs prompt referral and electrodiagnostic testing.

TRAPS PEOPLE FALL INTO

- **Naming the Trendelenburg side by the drop.** The weak muscle is on the stance side, opposite the side that drops.
- **Counting back pain on SLR as positive.** Only radiating pain below the knee at 30 to 70 degrees counts.
- **Calling a pulse change on Adson positive.** Thoracic outlet tests count only when they reproduce the patient's symptoms.
- **Clearing a neck with a negative DeKleyn.** Positional tests cannot exclude dissection. History and the neuro exam do.
- **Reading Waddell signs as faking.** Three or more categories mean distress and poorer prognosis, not malingering.

Chapter 3 self-test · six items

1. A patient with foot drop has weak hip abduction and foot inversion on the same side. Where is the lesion?

A. The common fibular nerve
B. The tibial nerve at the knee
C. The L5 nerve root
D. The deep fibular nerve only

C. The L5 nerve root Gluteus medius and tibialis posterior are L5 muscles outside the fibular nerve, so their weakness puts the lesion at the root.

2. Which cervical finding is an upper motor neuron sign?

A. Reduced biceps reflex
B. Inverted supinator sign
C. C6 dermatomal numbness
D. Weak wrist extension

B. Inverted supinator sign Finger flexion with a reduced brachioradialis response implies a C5 to C6 cord lesion. The others are root signs.

3. A 33 year old has chest expansion of 2 cm and morning stiffness for over an hour. What does the expansion finding suggest?

A. Normal expansion for a young adult
B. A first rib fixation held in inhalation on both sides
C. A thoracic disc herniation at T8
D. Costovertebral involvement by spondyloarthritis

D. Costovertebral involvement by spondyloarthritis Expansion under about 2.5 cm in a young adult with inflammatory back pain suggests ankylosing spondylitis.

4. Supine SLR reproduces leg pain at 25 degrees, but full seated knee extension is painless. What does this mismatch represent?

A. A positive Waddell distraction sign
B. Acute hamstring strain
C. A large axillary disc herniation
D. A positive Bechterew test

A. A positive Waddell distraction sign An inconsistent supine and seated SLR is the distraction (flip test) category of Waddell signs.

5. Which sacroiliac provocation test is the most sensitive single test in the Laslett cluster?

A. Gaenslen
B. Distraction
C. Sacral thrust
D. Thigh thrust

D. Thigh thrust Thigh thrust is the most sensitive; distraction is the most specific.

6. For documentation of a subluxation by examination, which combination meets the requirement?

A. Tenderness plus range of motion abnormality
B. Tenderness plus a positive special test
C. Tenderness plus tissue tone change
D. Tissue tone plus a special test

A. Tenderness plus range of motion abnormality At least two of the four PART findings are needed, and one must be asymmetry or range of motion abnormality.

Extremity, Neurologic and Peripheral Vascular Examination

Read it in full: **Chapter 4 in the textbook**. Practice it: **the Study Guide 2 practice exam** and **the flashcards**.

What to know

Clear the neck and viscera before blaming the shoulder. The capsular pattern loses external rotation most. Drop arm and the ER lag sign rule in a cuff tear; Hawkins with a painful arc and weak ER is the impingement cluster. Phalen and compression test carpal tunnel; snuffbox tenderness is a scaphoid fracture until proven otherwise.

Lachman is the best ACL test, the posterior drawer the best PCL test, valgus at 30 degrees the MCL test, and McMurray and Thessaly test the menisci. Ottawa rules are about 0.98 sensitive. Thompson detects Achilles rupture. Knee pain with a normal knee in an overweight adolescent is SCFE until proven otherwise.

Localize with dermatome, myotome and reflex. UMN signs (hyperreflexia, clonus, Babinski, Hoffmann) put the lesion in the brain or cord. A forehead sparing facial palsy is central. ABI 0.90 or less is PAD. Use Wells, not Homans; two or more points means same day ultrasound.

LR+ = sens ÷ (1 − spec); LR− = (1 − sens) ÷ spec. SnNout and SpPin. Above 10 or below 0.1 is a large shift.

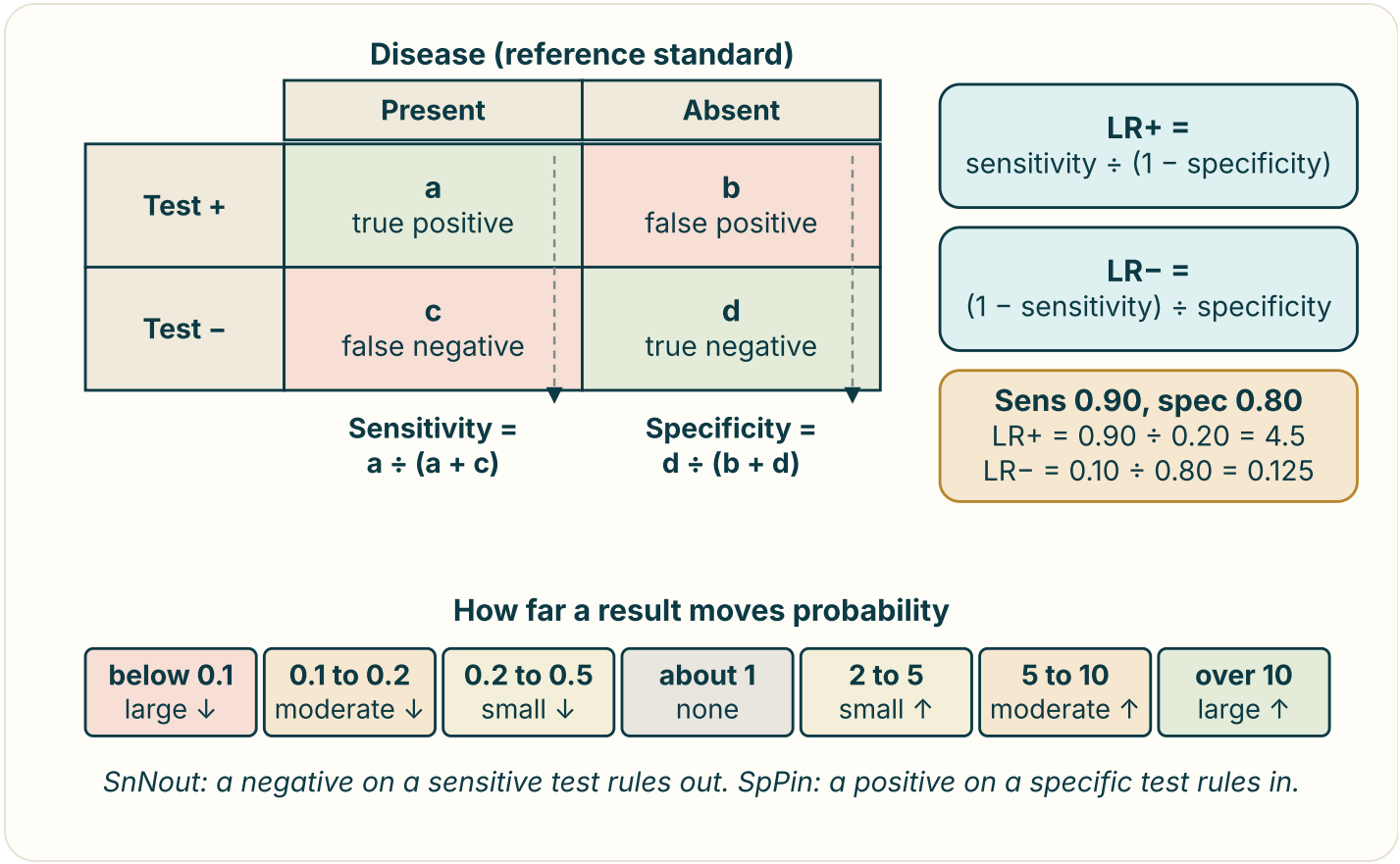

From the two by two table to likelihood ratios. Sensitivity reads down the disease column, specificity down the no disease column. Likelihood ratios combine both and do not change with prevalence, so they tell you how far one result moves your estimate.

LOCK THESE IN

- Drop arm and ER lag: cuff tear; Neer and Hawkins: sensitive only.
- Lachman for ACL; Ottawa rules decide films.
- Thenar skin spared in carpal tunnel.
- UMN versus LMN signs localize brain or cord versus root or nerve.
- Wells 2 or more: same day ultrasound.
- LR+ over 10 rules in; LR− under 0.1 rules out.

Root level screen

Root	Sensory area	Motor test	Reflex
C5	Lateral upper arm (deltoid)	Shoulder abduction, elbow flexion	Biceps
C6	Lateral forearm, thumb, index	Wrist extension, elbow flexion	Brachioradialis
C7	Middle finger	Elbow extension, wrist flexion, finger extension	Triceps
C8	Ring and little fingers, medial forearm	Finger flexion, thumb extension	None reliable
T1	Medial arm	Finger abduction	None
L4	Medial leg and medial malleolus	Ankle dorsiflexion, knee extension	Patellar
L5	Lateral leg, dorsum of foot, great toe	Great toe extension, hip abduction, inversion	Medial hamstring (inconsistent)
S1	Lateral foot, little toe, sole	Plantar flexion, eversion, hip extension	Achilles

Worked cases

WORKED CASE 1 · LIKELIHOOD RATIOS FROM SENSITIVITY AND SPECIFICITY

A test for a meniscal tear has a sensitivity of 0.70 and a specificity of 0.90. What are its likelihood ratios, and is it better for ruling in or ruling out?

STEP 1 · LR+

$0.70 \div (1 - 0.90) = 0.70 \div 0.10 =$ **7.0**.

STEP 2 · LR−

$(1 - 0.70) \div 0.90 = 0.30 \div 0.90 =$ **0.33**.

STEP 3 · READ THE SIZE

An LR+ of 7 is a moderate upward shift (about 35 to 40 points by the rule of thumb between 5 and 10). An LR− of 0.33 is only a small downward shift.

STEP 4 · CONCLUDE

It is a specific test: a positive result helps rule in (SpPin); a negative result does little to rule out.

TRAPS PEOPLE FALL INTO

- **Treating "shoulder pain" that neck movement reproduces.** Clear the neck and the viscera first.
- **Ordering an ankle film for ATFL tenderness.** Ottawa presses the posterior malleolar edge and tip, the fifth metatarsal base and the navicular.
- **Trusting a normal scaphoid film.** Snuffbox tenderness after a fall on the hand means thumb spica and repeat films in 10 to 14 days, or MRI.
- **Giving knee exercises to an adolescent with a normal knee.** Examine the hip: SCFE presents as knee pain.
- **Using Homans sign.** It is neither sensitive nor specific. Use the Wells criteria.

Chapter 4 self-test · six items

1. Which knee test is very specific for an ACL tear but hard to perform in an awake patient?

A. Pivot shift
B. Apley distraction
C. Patellar grind
D. Anterior drawer

A. Pivot shift The pivot shift is about 0.98 specific but guarding limits it. Lachman is the best overall clinical test.

2. Wrist drop after sleeping with the arm over a chair, triceps intact and numbness of the dorsal first web space. Where is the lesion?

A. Posterior cord of the plexus
B. Median nerve at the elbow
C. Radial nerve at the spiral groove
D. C7 nerve root at the C6 to C7 foramen

C. Radial nerve at the spiral groove Sparing of the triceps puts the lesion below its branches, at the spiral groove. C7 radiculopathy would weaken the triceps and its reflex.

3. Ascending symmetric leg weakness with lost reflexes after a viral illness most suggests what?

A. Myasthenia gravis
B. Guillain Barre syndrome
C. Bilateral L5 radiculopathy
D. Cervical myelopathy

B. Guillain Barre syndrome Ascending weakness with areflexia after infection is Guillain Barre; respiratory failure is the danger.

4. A test has sensitivity 0.95 and specificity 0.60. What is its negative likelihood ratio?

A. About 2.4
B. About 0.05
C. About 0.40
D. About 0.08

D. About 0.08 LR− = 0.05 ÷ 0.60 = 0.083, a large downward shift: a sensitive test rules out.

5. Which finding is an upper motor neuron sign?

A. Absent Achilles reflex
B. Wasting of the thenar eminence muscles
C. Sustained ankle clonus of five beats
D. Fasciculations in the calf

C. Sustained ankle clonus of five beats Clonus of more than three beats indicates an UMN lesion. The others are LMN signs.

6. After a tibial fracture, a patient has pain out of proportion and severe pain on passive toe stretch, with pulses present. What is suspected?

A. Deep vein thrombosis, routine ultrasound
B. Peripheral arterial disease, ABI next week
C. Expected fracture pain, recheck tomorrow
D. Compartment syndrome, an emergency

D. Compartment syndrome, an emergency Pain out of proportion and on passive stretch suggest compartment syndrome; loss of pulses is a late sign.

CHAPTER 5

Imaging Decisions, Protection, Positioning and Report Writing

Read it in full: **Chapter 5 in the textbook**. Practice it: **the Study Guide 3 practice exam** and **the flashcards**.

What to know

Image only when the answer could change care: red flags, a validated rule or 4 to 6 weeks of failed care. The Canadian C spine rule images anyone 65 or older, with a dangerous mechanism or with paresthesias; otherwise a low risk factor plus 45 degrees of rotation each way clears the neck. Ask about pregnancy before pelvic exposure; never withhold a needed study.

Dose falls most by skipping unnecessary films, then by collimation, filtration, proper kVp and mAs, long SID and correct positioning. Doubling distance quarters exposure; +15 percent kVp equals doubling mAs. Know the supplemental views: oblique (pars), swimmer's (C7 to T1), APOM (dens), Ferguson (SI), scaphoid, Y or axillary, tunnel, sunrise, mortise.

Trace the four cervical lines; ADI 3 mm adult and 5 mm child; soft tissue 7 mm at C2 and 22 mm at C6. Corticated means variant. Search with ABCS. Describe margin, zone of transition, matrix and periosteal reaction; age guides the differential. Reports end with an impression and recommendations.

MRI for soft tissue, marrow and early infection; CT for bone; bone scan is cold in myeloma; T1 dark marrow means replacement; the disc crosses infection but the tumor respects it. T score −2.5 or lower is osteoporosis.

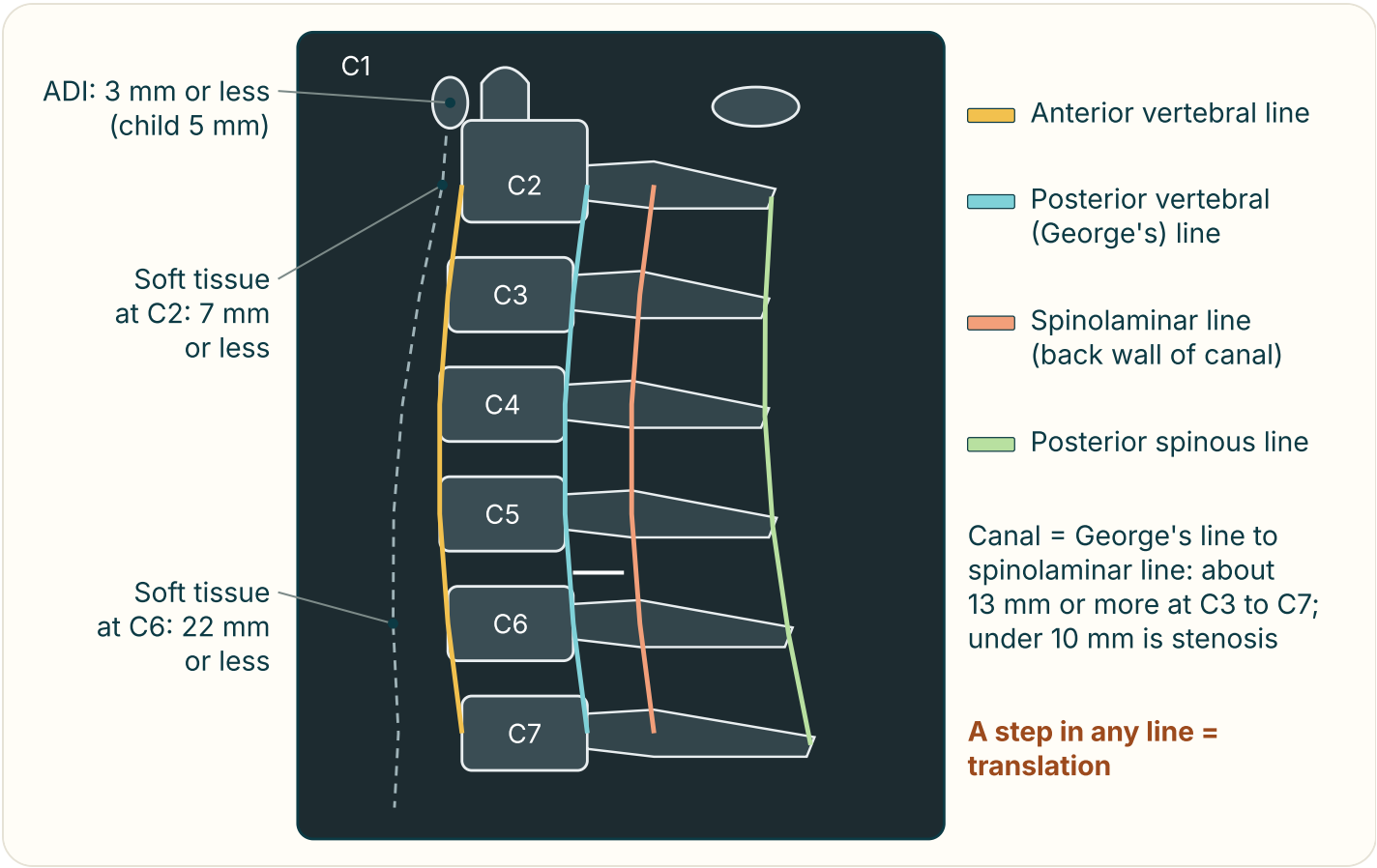

The lateral cervical film, drawn as lines. Trace four smooth curves and measure the ADI, the canal and the prevertebral soft tissue on every trauma film. Soft tissue swelling may be the only sign of an occult fracture.

LOCK THESE IN

- No films for acute nonspecific pain.
- Canadian C spine high risk: 65+, dangerous mechanism, paresthesias.
- Collimation is the best technical dose reducer.
- ADI 3 mm adult, 5 mm child.
- Bone scan cold in myeloma; cauda equina means emergency MRI.
- T score −2.5 or lower at the lowest site is osteoporosis.

The view that answers the question

Question	View	Note
Pars defect	Oblique lumbar	Collar on the Scottie dog neck
C7 and T1 hidden	Swimmer's lateral	Or CT if high risk
Dens, C1 lateral masses	APOM	Overhang over 7 mm: Jefferson fracture
Ligamentous instability	Flexion and extension laterals	Only after fracture is excluded
Radicular arm symptoms	Cervical obliques	Foramina, uncovertebral spurs
Sacroiliac joints, L5 to S1	Ferguson (25 to 30° cephalad)	Sacroiliitis, transitional segment
Occult scaphoid fracture	PA in ulnar deviation	Repeat in 10 to 14 days or MRI
Posterior shoulder dislocation	Axillary or scapular Y	AP can miss it
Osteochondritis dissecans	Tunnel (intercondylar)	Femoral condyle
Ankle joint space, syndesmosis	Mortise (15 to 20° internal rotation)	Stress views for instability

Worked cases

WORKED CASE 1 · THE CANADIAN C SPINE RULE STEP BY STEP

A 41 year old was rear ended at low speed, walked around the scene, and developed neck pain the next morning. There is no midline tenderness and no arm symptoms. She rotates 50 degrees left and right.

STEP 1 · HIGH RISK FACTORS?

Under 65, no dangerous mechanism, no paresthesias: none.

STEP 2 · LOW RISK FACTOR?

Simple rear end collision, ambulatory, delayed onset, no midline tenderness: yes, so range of motion may be tested safely.

STEP 3 · ACTIVE ROTATION

50 degrees each way exceeds 45.

STEP 4 · CONCLUDE

No imaging is needed. Change one fact (age 71, a fall down five stairs, arm paresthesias) and she must be imaged before any cervical manipulation.

TRAPS PEOPLE FALL INTO

- **Ordering films to "see what is out of place."** Acute nonspecific pain without red flags does not need imaging.
- **Testing rotation in a high risk patient.** Age 65 or older ends the Canadian rule: image first, move the neck later.
- **Trusting a normal film in a cancer patient with night pain.** Lytic lesions hide until 30 to 50 percent of bone is lost. Get MRI.
- **Choosing a bone scan for myeloma.** Myeloma is often cold. Use electrophoresis plus skeletal survey, low dose CT or MRI.
- **Calling a corticated corner fragment a fracture.** A limbus bone has corticated margins and a matching defect.

Chapter 5 self-test · six items

1. Which NEXUS finding means cervical imaging is needed?

A. Ability to walk at the scene
B. A simple low speed rear end collision
C. Delayed onset of neck pain next day
D. Posterior midline cervical tenderness

D. Posterior midline cervical tenderness NEXUS clears the neck only if there is no midline tenderness, no deficit, normal alertness, no intoxication and no distracting injury.

2. A 26 year old with suspected spondylolysis is unsure whether she could be pregnant. What comes first?

A. A pregnancy test before any pelvic exposure
B. A bone scan with SPECT of the pars
C. Oblique lumbar films with a lead apron
D. CT of the lumbar spine with thin cuts

A. A pregnancy test before any pelvic exposure Resolve the pregnancy question first. If imaging is needed during pregnancy, MRI without contrast avoids ionizing radiation.

3. A 6 year old has an apparent 3 mm anterior offset of C2 on C3 after a minor fall, with a normal exam. Which line helps decide if this is normal?

A. George's line
B. The Swischuk line
C. The Ferguson line
D. The spinous line

B. The Swischuk line If the C2 spinolaminar point lies within about 2 mm of the C1 to C3 line, it is pseudosubluxation.

4. Which periosteal reaction suggests a slow growing process?

A. Lamellated onion skin layers
B. A Codman triangle at the edge
C. Solid, thick, uninterrupted new bone
D. A sunburst spiculated pattern of new bone

C. Solid, thick, uninterrupted new bone Interrupted reactions mean aggression; solid reaction means slow growth.

5. On MRI, a destroyed disc that is bright on T2 with edema in both adjacent bodies most suggests what?

A. Acute osteoporotic compression fracture
B. Discitis and vertebral osteomyelitis
C. Metastasis to two adjacent bodies
D. A desiccated degenerated disc

B. Discitis and vertebral osteomyelitis The disc crosses the infection; tumor respects the disc.

6. A 44 year old man's DEXA shows a Z score of −2.3. What should follow?

A. Reassurance, since only T scores matter
B. Repeat DEXA in three months
C. An immediate bone scan
D. A search for a secondary cause of bone loss

D. A search for a secondary cause of bone loss A Z score of −2.0 or lower is below the expected range for age and prompts a search for causes such as steroids or hyperparathyroidism.

Clinical Laboratory and Special Studies in Cases

Read it in full: **Chapter 6 in the textbook**. Practice it: **the Study Guide 3 practice exam** and **the flashcards**.

What to know

Casts localize disease to the kidney: RBC casts glomerulonephritis, WBC casts pyelonephritis. Nitrite is specific for infection; blood without red cells means pigment. Classify anemia by MCV; ferritin is the best iron test; iron deficiency in a man or postmenopausal woman means colonoscopy; B12 deficiency adds dorsal column signs and raised MMA.

ESR over 100 suggests infection, myeloma, malignancy or giant cell arteritis. Anti CCP is specific for RA, a negative ANA nearly excludes lupus, and HLA B27 only supports a suspected spondyloarthritis. Myeloma: high calcium, anemia, kidney injury, high ESR, normal ALP. Paget disease: very high ALP, normal calcium.

Synovial WBC over about 50,000 with neutrophil predominance is septic until proven otherwise; urate needles are negative, CPPD rhomboids weakly positive, and crystals do not exclude infection. A positive FIT means colonoscopy.

ECG small box 0.04 s; PR 0.12 to 0.20 s; QRS under 0.12 s. Normal SNAP with numbness means a root lesion. PPV falls with prevalence; posttest odds = pretest odds × LR.

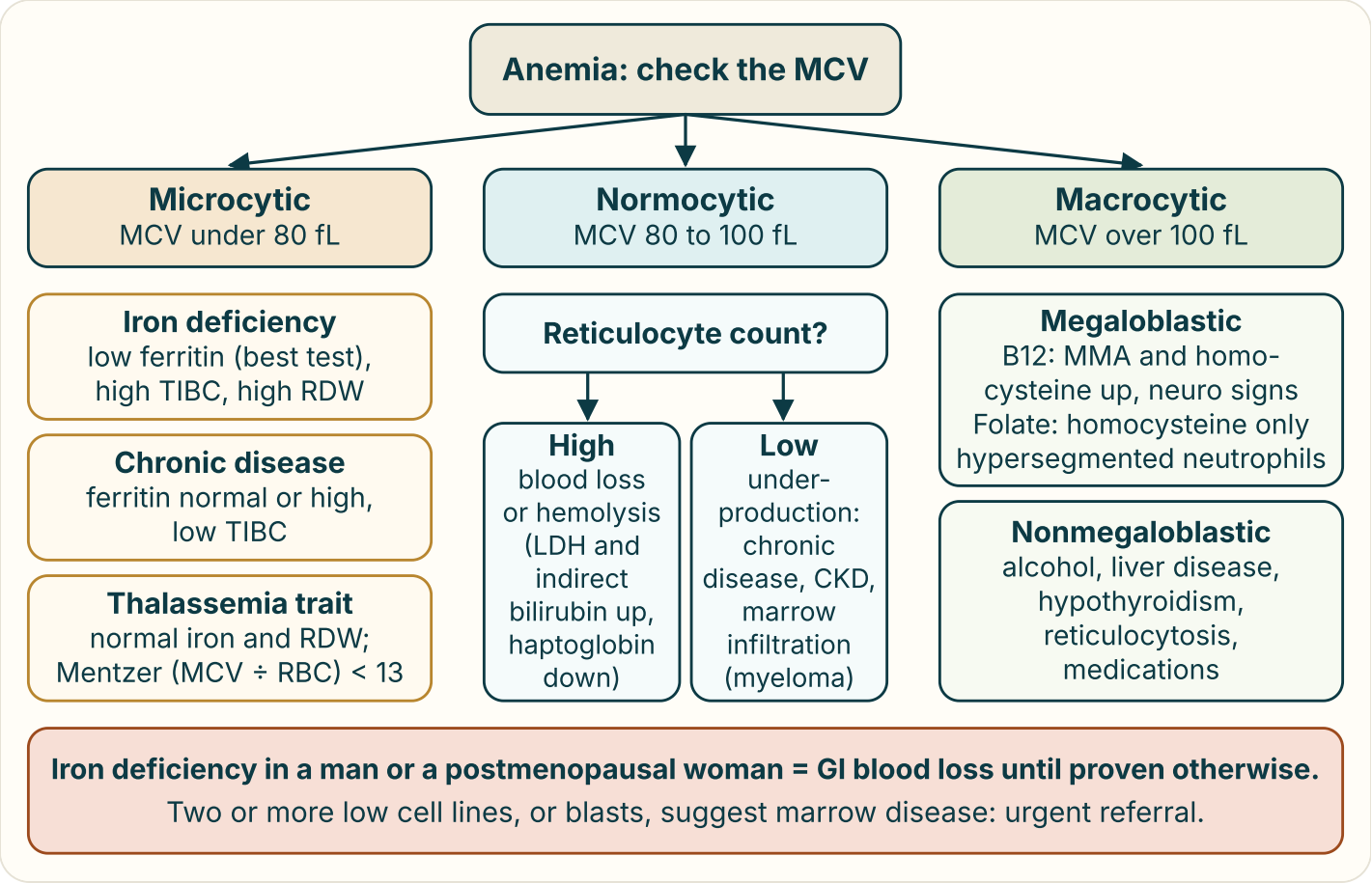

Anemia by MCV. The MCV sorts anemia into three short lists. In normocytic anemia, the reticulocyte count shows whether the marrow is responding (loss or destruction) or failing (underproduction).

LOCK THESE IN

- Casts mean kidney.
- Ferritin best for iron; men with iron deficiency need colonoscopy.
- Myeloma: CRAB plus normal ALP.
- Septic fluid usually over 50,000 WBC.
- Normal SNAP plus numbness: root lesion.
- Low prevalence lowers PPV.

Lab values and formulas

Test	Reference or rule	Key point
Hemoglobin	Men 13.5 to 17.5; women 12.0 to 15.5 g/dL	Hematocrit about 3 × Hb
MCV	80 to 100 fL	Classifies anemia
Platelets	150,000 to 450,000 per µL	Under 50,000: avoid forceful therapy
ESR upper limit	Men age ÷ 2; women (age + 10) ÷ 2	Over 100: short list
CRP	Under about 10 mg/L	Rises 6 to 8 h, peaks 48 h
Calcium	8.5 to 10.5 mg/dL	Corrected = Ca + 0.8 × (4.0 − albumin)
ALP	About 40 to 130 U/L	With GGT: liver; alone: bone
Urate	Saturates at about 6.8 mg/dL	May be normal in a flare
PSA	Over about 4 ng/mL prompts evaluation	Prostate specific, not cancer specific
Glucose	Fasting 126+ or HbA1c 6.5%+ is diabetes	Prediabetes 100 to 125 or 5.7 to 6.4%
BUN : creatinine	Over 20 suggests prerenal	eGFR under 30 changes drug choice
Mentzer index	MCV ÷ RBC under 13	Thalassemia trait
ECG	Small box 0.04 s; large 0.20 s	Rate = 300 ÷ large boxes
Nerve conduction	Arms 50 m/s or faster; legs 40 m/s or faster	Demyelination slows; axonal loss lowers amplitude

Worked cases

WORKED CASE 1 · WHY LOW PREVALENCE FOOLS A GOOD TEST

A test with sensitivity 0.90 and specificity 0.80 is applied to 1,000 patients, 10 percent of whom have the disease. What are the PPV and NPV?

STEP 1 · SPLIT THE GROUP

100 have the disease; 900 do not.

STEP 2 · FILL THE CELLS

True positives 0.90 × 100 = 90; false negatives 10. True negatives 0.80 × 900 = 720; false positives 180.

STEP 3 · PPV

90 ÷ (90 + 180) = 90 ÷ 270 = **33.3%**. Only a third of positives are right.

STEP 4 · NPV

720 ÷ (720 + 10) = 720 ÷ 730 = **98.6%**. A negative is very reassuring.

STEP 5 · THE LESSON

As prevalence falls, PPV falls and NPV rises, while sensitivity and specificity stay the same.

TRAPS PEOPLE FALL INTO

- **Reassuring with a negative dipstick protein in suspected myeloma.** The dipstick detects albumin, not light chains. Order electrophoresis.
- **Starting iron without finding the source.** Iron deficiency in a man or postmenopausal woman needs a GI workup.
- **Ruling out gout with a normal urate.** Urate can be normal in a flare. Crystals in fluid make the diagnosis.
- **Calling a hot joint gout because crystals are present.** Crystals do not exclude infection. Culture it.
- **Screening vague aches with an ANA.** Low specificity means false positives and a testing cascade.

Chapter 6 self-test · six items

1. A dipstick is strongly positive for blood, but microscopy shows few red cells after a marathon in the heat. Which test comes next?

A. Renal ultrasound for stones
B. Cystoscopy to look for bladder cancer
C. Urine culture for infection
D. Creatine kinase for rhabdomyolysis

D. Creatine kinase for rhabdomyolysis Dipstick blood without red cells suggests myoglobin or hemoglobin; check CK.

2. What is the approximate upper limit of normal ESR for a 70 year old woman by the rule of thumb?

A. 35 mm/h
B. 20 mm/h
C. 40 mm/h
D. 50 mm/h

C. 40 mm/h For women, (age + 10) ÷ 2 = 80 ÷ 2 = 40. For a 70 year old man it would be 35.

3. Measured calcium is 8.0 mg/dL and albumin is 2.5 g/dL. What is the corrected calcium?

A. 10.0 mg/dL
B. 9.2 mg/dL
C. 6.8 mg/dL
D. 8.4 mg/dL

B. 9.2 mg/dL 8.0 + 0.8 × (4.0 − 2.5) = 8.0 + 1.2 = 9.2, which is normal.

4. Which stool test best separates inflammatory bowel disease from irritable bowel syndrome?

A. Fecal calprotectin
B. Ova and parasites
C. Guaiac occult blood
D. Fecal fat stain

A. Fecal calprotectin Calprotectin is high in IBD and normal in IBS.

5. On a regular ECG there are 4 large boxes between R waves. What is the heart rate?

A. 100 per minute
B. 60 per minute
C. 75 per minute
D. 50 per minute

C. 75 per minute Rate = 300 ÷ 4 = 75.

6. Foot drop with numbness has a reduced superficial fibular SNAP, a block across the fibular head, and normal tibialis posterior and paraspinals. Where is the lesion?

A. Sciatic nerve in the buttock
B. L5 nerve root in the foramen
C. Lumbosacral plexus deep in the true pelvis
D. Common fibular nerve at the fibular head

D. Common fibular nerve at the fibular head A reduced SNAP puts the lesion distal to the DRG; sparing of tibialis posterior and paraspinals excludes L5 radiculopathy.

Clinical Impression I: Musculoskeletal and Neurologic Presentations

Read it in full: **Chapter 7 in the textbook**. Practice it: **the Study Guide 4 practice exam** and **the flashcards**.

What to know

Neck: mechanical (normal neuro), radiculopathy (one level LMN; C5 to C6 disc hits C6), myelopathy (UMN below the level; MRI and no thrust). Screen headaches with SNOOP before naming tension type, migraine, cluster or cervicogenic (side locked, positive flexion rotation test). Unusual neck pain with Horner or brainstem signs is dissection.

Thoracic pain is judged by behavior: exertional, pleuritic, tearing or meal related means visceral, and tenderness never excludes ischemia. Compression fracture and the zoster prodrome are the mechanical looking traps.

Lumbar: posterolateral discs hit the traversing root, far lateral the exiting root. Cauda equina means same day MRI. Neurogenic claudication eases with sitting; vascular eases standing still. Inflammatory back pain starts under 40 and improves with exercise.

Extremities: age plus mechanism plus one sign; Ottawa rules and snuffbox tenderness decide imaging. Vertigo by timing; in continuous vertigo a normal head impulse, changing nystagmus or skew means stroke.

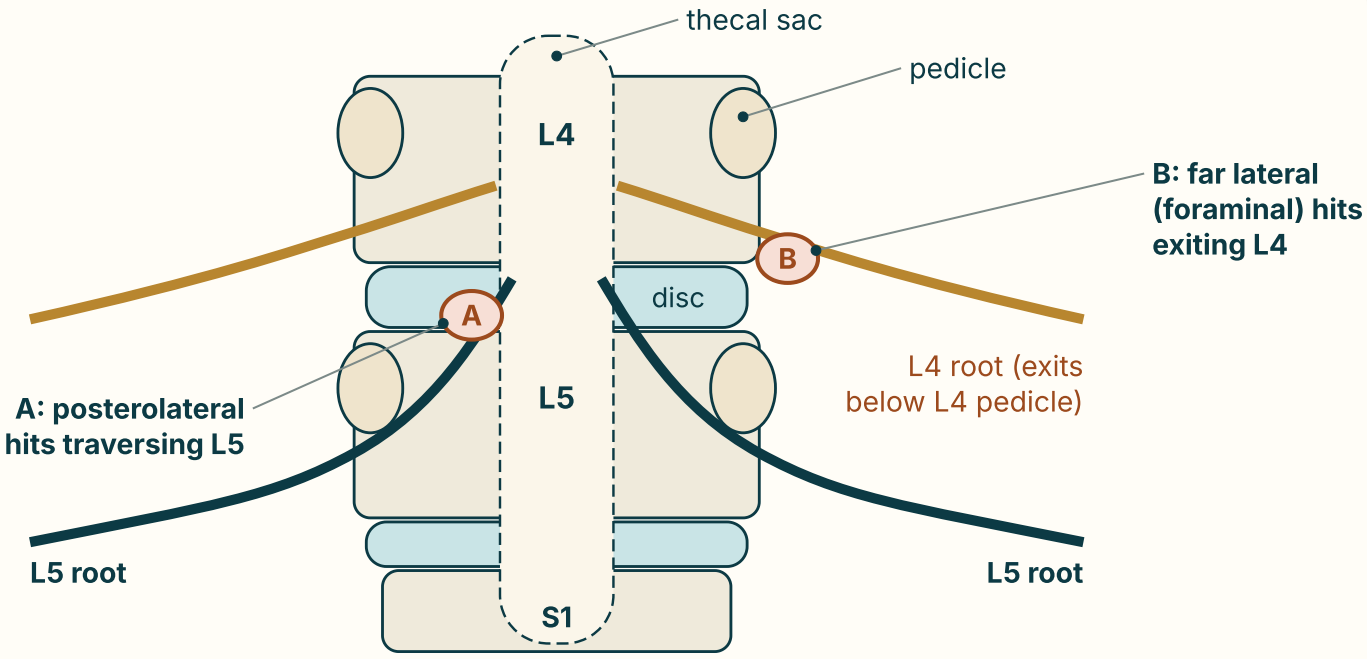

L4 to L5 disc: posterolateral hits the lower number (traversing L5); far lateral hits the upper number (exiting L4).
Neck: roots exit above their vertebra, so a C5 to C6 disc hits C6.

Traversing versus exiting root. The same L4 to L5 disc can produce an L5 or an L4 radiculopathy depending on where it herniates. Match the dermatome, myotome and reflex to the root before you name the level.

LOCK THESE IN

- C5 to C6 disc hits C6.
- SNOOP first; then name the headache.
- Tenderness does not exclude ischemia.
- Posterolateral: traversing root; far lateral: exiting root.
- Retention plus saddle numbness: emergency MRI.
- HINTS: normal head impulse is the dangerous result.

Low back presentations

Presentation	Most likely	Must not miss
Lift, flexion worse, normal neuro	Nonspecific mechanical LBP	Fracture in older or steroid treated patient
Leg worse than back, SLR 30 to 70°	Disc herniation with radiculopathy	Cauda equina syndrome
Over 60, legs ache walking, sit to relieve	Central stenosis	Vascular claudication
Teen athlete, extension pain	Spondylolysis or isthmic slip	Osteoid osteoma
Buttock below L5, provocation cluster	Sacroiliac joint pain	Sacroiliitis of spondyloarthritis
Under 40, morning stiffness, better with exercise	Axial spondyloarthritis	Infection or tumor if systemic
Older smoker, constant deep pain, pulsatile mass	Abdominal aortic aneurysm	Rupture

Worked cases

WORKED CASE 1 · NAMING THE ROOT FROM A FAR LATERAL DISC

A 52 year old has anterior thigh and medial leg pain, a weak quadriceps and a reduced patellar reflex. MRI shows an L4 to L5 herniation. Where on the disc is it most likely?

STEP 1 · NAME THE ROOT

Medial leg sensation, quadriceps and tibialis anterior weakness and a reduced patellar reflex mean L4.

STEP 2 · APPLY THE RULE

An L4 to L5 disc hits L5 if posterolateral (traversing) and L4 if far lateral (exiting).

STEP 3 · CONCLUDE

An L4 root lesion from an L4 to L5 disc means a **far lateral (foraminal)** herniation.

STEP 4 · CHECK THE TRAP

A posterolateral L4 to L5 disc would give dorsum of foot numbness and EHL weakness instead.

TRAPS PEOPLE FALL INTO

- **Calling myelopathy carpal tunnel.** Clumsy hands with brisk reflexes, Hoffmann and gait ataxia mean the cord.
- **Trusting a negative positional artery test.** It cannot detect dissection. History and neuro screen decide.
- **Anchoring on "I was shoveling snow."** Exertional interscapular tightness in a diabetic is cardiac until proven otherwise.
- **Treating the zoster prodrome as a rib.** Unilateral dermatomal burning with allodynia: re-examine daily and refer when vesicles appear.
- **Assuming posterolateral every time.** A far lateral L4 to L5 disc hits L4, not L5.

Chapter 7 self-test · six items

1. Clumsy hands, reduced biceps reflex, brisk triceps and patellar reflexes and a positive Hoffmann suggest cord compression near which level?

A. About T4 to T5
B. About C5 to C6
C. About C2 to C3
D. About C7 to T1

B. About C5 to C6 A reduced reflex at the level of compression with brisk reflexes below localizes the lesion; the biceps is C5.

2. Which headache is strictly unilateral orbital pain for 15 to 180 minutes with tearing in a restless patient?

A. Cervicogenic headache
B. Migraine without aura
C. Tension type headache
D. Cluster headache

D. Cluster headache Cluster headache is trigeminal autonomic: tearing, rhinorrhea, ptosis, restlessness. Refer for medical treatment.

3. A 15 year old gymnast has low back pain on extension and one leg standing extension, with tight hamstrings. What is most likely?

A. Spondylolysis of the pars at L5
B. Central stenosis at L4 to L5
C. Degenerative spondylolisthesis at L4
D. Sacroiliac joint sprain

A. Spondylolysis of the pars at L5 Repetitive hyperextension stresses the pars; isthmic slips are usually L5 on S1.

4. Which AAA finding calls for referral for repair rather than surveillance?

A. Diameter of 4.5 cm, stable
B. Diameter of 3.2 cm
C. Diameter of 5.5 cm or more
D. Calcified wall at 3.0 cm

C. Diameter of 5.5 cm or more Repair is considered at 5.5 cm or more or growth over 1 cm a year; any tender aneurysm is an emergency.

5. Foot drop with weak eversion, normal inversion and hip abduction, a normal ankle reflex and a Tinel at the fibular head after rapid weight loss. What is the diagnosis?

A. Common fibular nerve palsy
B. L5 radiculopathy from a disc
C. Sciatic neuropathy in the buttock
D. Tarsal tunnel syndrome

A. Common fibular nerve palsy Spared inversion and hip abduction exclude L5; leg crossing and weight loss compress the nerve at the fibular head.

6. Brief vertigo when rolling over in bed, with torsional upbeating nystagmus after a short latency that fatigues. What treatment fits?

A. Audiology and ENT referral
B. Emergency stroke referral
C. Cervical manipulation
D. Epley canalith repositioning

D. Epley canalith repositioning This is posterior canal BPPV, confirmed by Dix Hallpike and treated with the Epley maneuver.

CHAPTER 8

Clinical Impression II: Systemic, Visceral and Special Population Presentations

Read it in full: **Chapter 8 in the textbook**. Practice it: **the Study Guide 4 practice exam** and **the flashcards**.

What to know

Decide inflammatory or mechanical first. RA is symmetric small joint disease sparing the DIP joints (anti CCP; check C1 to C2 stability). Spondyloarthropathies share HLA B27, sacroiliitis, enthesitis and uveitis. Gout is a hot first MTP with negative needles; a hot joint is septic until aspirated. PMR is girdle stiffness after 50 with a high ESR; ask about giant cell arteritis.

Constant night pain with weight loss and a cancer history suggests metastasis (PB KTL; prostate blastic; winking owl). Myeloma is CRAB with an M spike. Tumor spares the disc; infection crosses it. Epidural abscess and cord compression are emergencies measured in hours.

Viscera refer to their segments; the diaphragm refers to the shoulder tip through C3 to C5. Children: growing pains leave a normal child by morning; Perthes is a boy 4 to 8 with a painless limp; SCFE is an overweight teen with knee pain and a Drehmann sign.

Older adults: a fall is a symptom. Pregnancy red flags: bleeding, preterm contractions, preeclampsia, DVT. State a primary diagnosis, secondary diagnoses and a must not miss alternative; failure to improve reopens the differential.

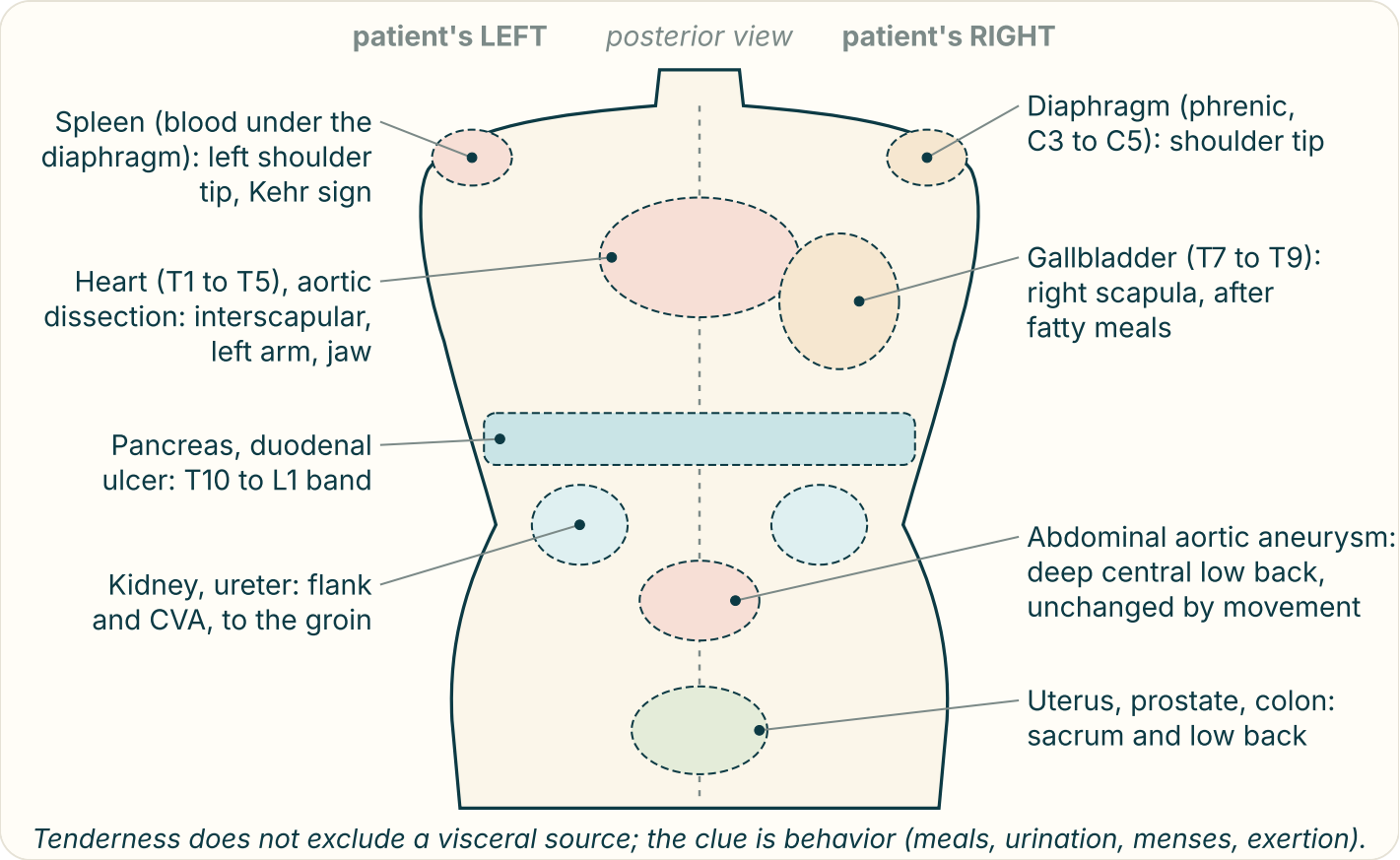

Visceral referral to the back. Viscera refer pain to the dermatomes of the segments that supply them, and the diaphragm refers to the shoulder tip through C3 to C5. Location suggests the organ; systemic signs set the urgency.

LOCK THESE IN

- RA spares the DIP; anti CCP is specific.
- PMR: ask about giant cell arteritis.
- Prostate metastases are blastic.
- Tumor spares the disc; infection crosses it.
- Shoulder tip pain with a normal shoulder: think diaphragm.
- SCFE presents as knee pain.

Systemic disease patterns

Condition	Case clues	Key test or finding
Rheumatoid arthritis	Symmetric MCP, PIP, wrist; spares DIP	Anti CCP (about 95% specific); ADI over 3 mm
Ankylosing spondylitis	Man under 40, chest expansion under 2.5 cm	Bilateral SI, marginal syndesmophytes, HLA B27 about 90%
Psoriatic arthritis	Nail pitting, sausage digit	DIP erosions, pencil in cup
Reactive arthritis	1 to 4 weeks after Chlamydia or diarrhea	Asymmetric lower limb, conjunctivitis, urethritis
Gout	Hot first MTP after alcohol or diuretic	Negatively birefringent needles
Polymyalgia rheumatica	Over 50, girdle stiffness, normal strength	High ESR, normal CK; 15 to 20% have GCA
Multiple myeloma	Over 60, CRAB	M spike; bone scan often negative
Osteomalacia	Diffuse bone pain, waddling gait	Low vitamin D, raised ALP, Looser zones
Paget disease	Over 55, bowed tibia, hearing loss	Very high ALP, normal calcium

Worked cases

WORKED CASE 1 · POLYMYALGIA WITH A WARNING SIGN

A 72 year old woman has six weeks of aching in both shoulders, neck and hips, needs 90 minutes to loosen up in the morning, and struggles out of a low chair. Strength is 5 of 5 once warm, ESR 68 mm/h, CRP raised, CK normal. She mentions a new right temporal headache.

STEP 1 · INFLAMMATORY OR MECHANICAL?

Prolonged morning stiffness and a high ESR: inflammatory.

STEP 2 · READ THE PATTERN

Bilateral girdle pain after 50 with normal strength and normal CK: polymyalgia rheumatica. Normal CK excludes myositis.

STEP 3 · FIND THE COMPLICATION

A new temporal headache raises giant cell arteritis (15 to 20 percent of PMR).

STEP 4 · SET URGENCY

Same day referral: vision is at risk.

TRAPS PEOPLE FALL INTO

- **Calling PMR fibromyalgia.** Girdle stiffness after 50 with a high ESR is PMR. Fibromyalgia has normal labs.
- **Forgetting the giant cell arteritis question.** Every PMR patient gets asked about headache, jaw pain and vision.
- **Thrusting the upper neck in active RA.** Exclude atlantoaxial instability first.
- **Reassuring with a normal film in suspected metastasis or infection.** Films lag; MRI is the next test when suspicion is high.
- **Waiting on a normal neuro exam in suspected epidural abscess.** Deficits can appear within hours. Same day MRI.

Chapter 8 self-test · six items

1. Which arthritis typically involves the DIP joints with nail pitting and dactylitis?

A. Psoriatic arthritis
B. Polymyalgia rheumatica
C. Rheumatoid arthritis
D. Pseudogout

A. Psoriatic arthritis Psoriatic arthritis hits DIP joints and whole digits; RA spares the DIP joints.

2. Which organism is the most common cause of adult vertebral osteomyelitis?

A. Pseudomonas aeruginosa
B. Mycobacterium tuberculosis
C. Staphylococcus aureus
D. Salmonella species

C. Staphylococcus aureus S. aureus is most common; Pseudomonas follows IV drug use, Salmonella sickle cell disease.

3. A teen has night pain in the femur relieved by aspirin, with a small lucent nidus and dense sclerosis on film. What is it?

A. Chondrosarcoma
B. Osteoid osteoma
C. Ewing sarcoma
D. Giant cell tumor

B. Osteoid osteoma Night pain relieved by NSAIDs with a small nidus is osteoid osteoma.

4. A 34 year old man paces with left flank pain into the groin, vomiting and hematuria, with no fever. What is the impression?

A. Lumbar facet sprain
B. Abdominal aortic aneurysm
C. Acute pyelonephritis
D. Ureteral stone (renal colic)

D. Ureteral stone (renal colic) Colicky flank to groin pain with restlessness and hematuria is renal colic; fever would raise an infected obstructed kidney.

5. A febrile 5 year old refuses to bear weight with a temperature of 39 °C, ESR 48 and WBC 14,000. What is the concern?

A. Septic arthritis of the hip
B. Transient synovitis of the hip
C. Growing pains of childhood
D. Legg Calve Perthes disease

A. Septic arthritis of the hip Fever, refusal to bear weight, ESR over 40 and WBC over 12,000 fit the Kocher criteria for septic arthritis: emergency.

6. An idiopathic scoliosis of 32 degrees in a premenarchal 12 year old usually calls for what?

A. Observation only
B. Bracing during growth
C. Surgical referral
D. No follow up needed

B. Bracing during growth Typical thresholds: observe under 25 degrees, brace 25 to 40 (or 45) in a growing child, surgery beyond about 45 to 50.

CHAPTER 9

Chiropractic Technique Decisions

Read it in full: **Chapter 9 in the textbook**. Practice it: **the Study Guide 5 practice exam** and **the flashcards**.

What to know

Decide whether the complaint is mechanical, then proceed, modify or refer. Absolute contraindications forbid thrust at the region (fracture, tumor, infection, instability, dissection, cauda equina, myelopathy); relative ones mean modify. Osteoporosis: no prone body weight thrust

or rib springing. RA and Down syndrome: ADI over 3 mm forbids upper cervical thrust. AS: never thrust fused segments. Pregnancy: avoid prolonged supine after about 20 weeks.

Flexion distraction suits disc and stenosis; instruments and drops lower force. Maitland I and II relieve pain, III and IV restore motion, V is a thrust past the elastic barrier.

Convex on concave glides opposite; concave on convex glides the same way. Cervical facets are about 45 degrees, thoracic 60, lumbar about 90 to the transverse plane; lower cervical coupling is same side. PI ilium gives an apparent short leg.

Dissection is screened by history; positional tests cannot clear a patient. On the table: stop, supine, emergency services, time of onset. Consent covers risks, benefits, alternatives and no treatment.

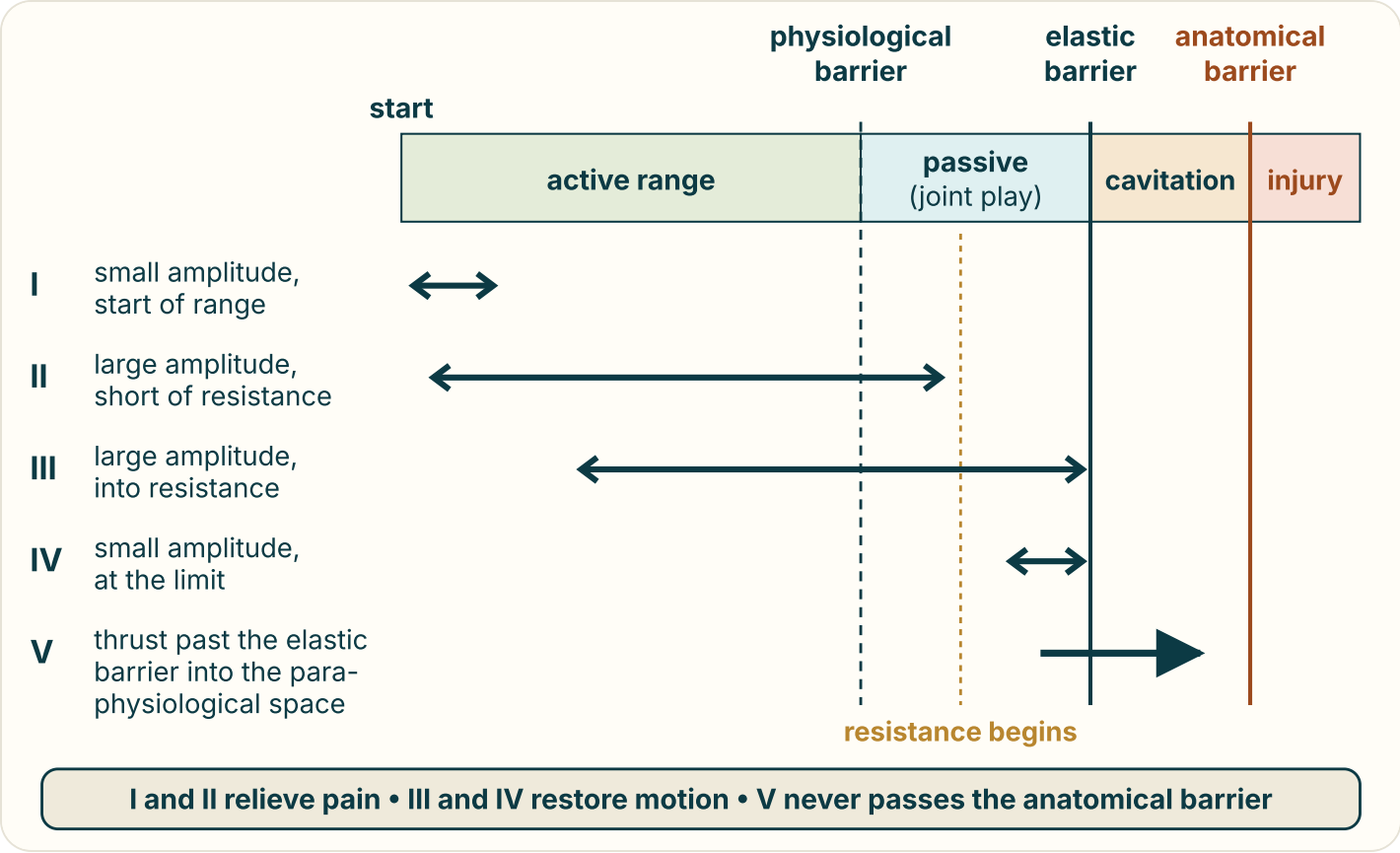

Maitland grades and barriers. Grades are defined by amplitude and by where in the range they act. A grade V thrust goes just past the elastic barrier, where cavitation occurs, and stops well short of the anatomical barrier.

LOCK THESE IN

- Relative contraindication: modify.
- ADI over 3 mm: no upper cervical thrust.
- Flexion distraction for disc and stenosis.
- Convex on concave glides opposite.
- PI ilium: apparent short leg.
- New neuro signs on the table: stop, supine, call.

Restricted motion and the glide that fixes it

Joint	Restricted motion	Glide
Glenohumeral (convex on concave)	Abduction	Inferior glide of the humeral head
Glenohumeral	Flexion, internal rotation	Posterior glide
Glenohumeral	Extension, external rotation	Anterior glide (not with anterior instability)
Radiocarpal (convex carpals)	Wrist flexion; extension	Dorsal glide; volar glide
Hip (convex head)	Flexion, internal rotation	Posterior glide; long axis distraction for OA
Tibiofemoral (concave tibia)	Knee extension; flexion	Anterior tibial glide; posterior tibial glide
Patellofemoral	Knee flexion	Inferior patellar glide
Talocrural (convex talus)	Dorsiflexion; plantar flexion	Posterior talar glide; anterior glide
Cuboid	Lateral midfoot pain after inversion	Cuboid whip or squeeze (plantar to dorsal)
First MTP (concave phalanx)	Extension (hallux limitus)	Dorsal glide of the proximal phalanx

Worked cases

WORKED CASE 1 · PROCEED, MODIFY OR REFER

Three patients with mechanical thoracic pain: (a) a 40 year old with no risk factors; (b) a 66 year old with osteopenia, T score −1.9, no fractures; (c) a 72 year old on prednisone for 8 years with new T8 pain after lifting soil and percussion tenderness.

STEP 1 · IS IT MECHANICAL?

All three describe pain changing with movement, but (c) adds a trivial load, steroids and percussion tenderness.

STEP 2 · PATIENT (A)

No contraindication: **proceed** with standard thoracic HVLA.

STEP 3 · PATIENT (B)

Osteopenia is relative: **modify** with instrument, light drop, mobilization, no prone body weight thrust or rib springing.

STEP 4 · PATIENT (C)

Compression fracture until proven otherwise: **no thrust at T8**, lateral thoracic films (MRI if negative and suspicion stays), supportive care; leg weakness would be an emergency.

TRAPS PEOPLE FALL INTO

- **Answering "do not treat" for a relative contraindication.** The best answer is usually a modification: low force, instrument, drop, flexion distraction or mobilization.
- **Clearing the neck with a negative positional test.** DeKleyn, Hautant, George and Maigne cannot clear a patient.
- **Prone thoracic thrust in osteoporosis.** Ribs and vertebrae fracture under prone PA body weight load.
- **Anterior glide for lost dorsiflexion.** The convex talus needs a posterior glide.
- **Thrusting a fused ankylosing spondylitis segment.** It is brittle and fractures with minimal force.

Chapter 9 self-test · six items

1. Which condition is an absolute contraindication to lumbar thrust at the involved region?

A. Stable grade I spondylolisthesis
B. Osteopenia without any fracture
C. Stable warfarin with a normal INR
D. Vertebral osteomyelitis at that level

D. Vertebral osteomyelitis at that level Infection compromises bone integrity. The others are relative and call for modification.

2. A patient on warfarin has spontaneous bruising and an INR above her target range. What is appropriate?

A. Standard HVLA with lighter pressure
B. No thrust; contact the prescriber
C. Deep instrument assisted soft tissue
D. Proceed if she signs a new consent

B. No thrust; contact the prescriber A supratherapeutic INR with bruising makes thrust inappropriate and needs prescriber contact.

3. Which technique pairing is classic for a frail, osteoporotic patient?

A. Instrument assisted adjusting
B. Prone body weight thoracic thrust
C. Rib springing and forced rotation
D. Long lever side posture roll

A. Instrument assisted adjusting Instruments deliver a very fast, low force impulse suited to fragile bone.

4. Which glide restores knee extension in open chain?

A. Inferior glide of the patella
B. Posterior glide of the tibia
C. Anterior glide of the tibia
D. Medial glide of the patella

C. Anterior glide of the tibia The concave tibia glides the same way it rolls, so extension needs an anterior tibial glide.

5. In structural scoliosis, which way do the vertebral bodies rotate?

A. Toward the convexity
B. Toward the concavity
C. Not at all in neutral
D. Posteriorly only

A. Toward the convexity Fryette type I: bodies rotate toward the convexity, making the rib hump on the convex side.

6. Local soreness after an adjustment typically lasts how long?

A. One to two weeks
B. Under one hour
C. 24 to 48 hours
D. About a month

C. 24 to 48 hours Mild soreness affects roughly a third to a half of patients and resolves in 24 to 48 hours.

CHAPTER 10

Supportive Interventions

Read it in full: **Chapter 10 in the textbook**. Practice it: **the Study Guide 5 practice exam** and **the flashcards**.

What to know

Ice for the acute stage, heat for subacute stiffness; no cold in Raynaud or cold urticaria. Ultrasound 1 MHz deep, 3 MHz shallow; continuous thermal, pulsed nonthermal; never over the pregnant uterus, eyes, tumor, pacemaker or DVT. High rate TENS for gate control, low rate for endorphins; no e-stim with a demand pacemaker. Lumbar traction: about 50 percent of body weight separates.

Teach the Mediterranean pattern. Supplements with evidence: vitamin D and calcium to fill gaps, omega 3 for RA, creatine with training, B12 for deficiency. Warfarin interacts with vitamin K, ginkgo, fish oil, garlic, vitamin E and St. John's wort. Calcium citrate for PPI users.

Rehab follows healing: protect, restore, rebuild. Centralization identifies the directional preference; peripheralization means stop. Novice strength: 60 to 70 percent 1RM for 8 to 12 reps. Keep loads close and move every 30 to 60 minutes; return to work early with modified duty.

Exercise 150 to 300 minutes moderate plus strength twice weekly after cardiovascular screening. Use the 5 As, stages of change and motivational interviewing.

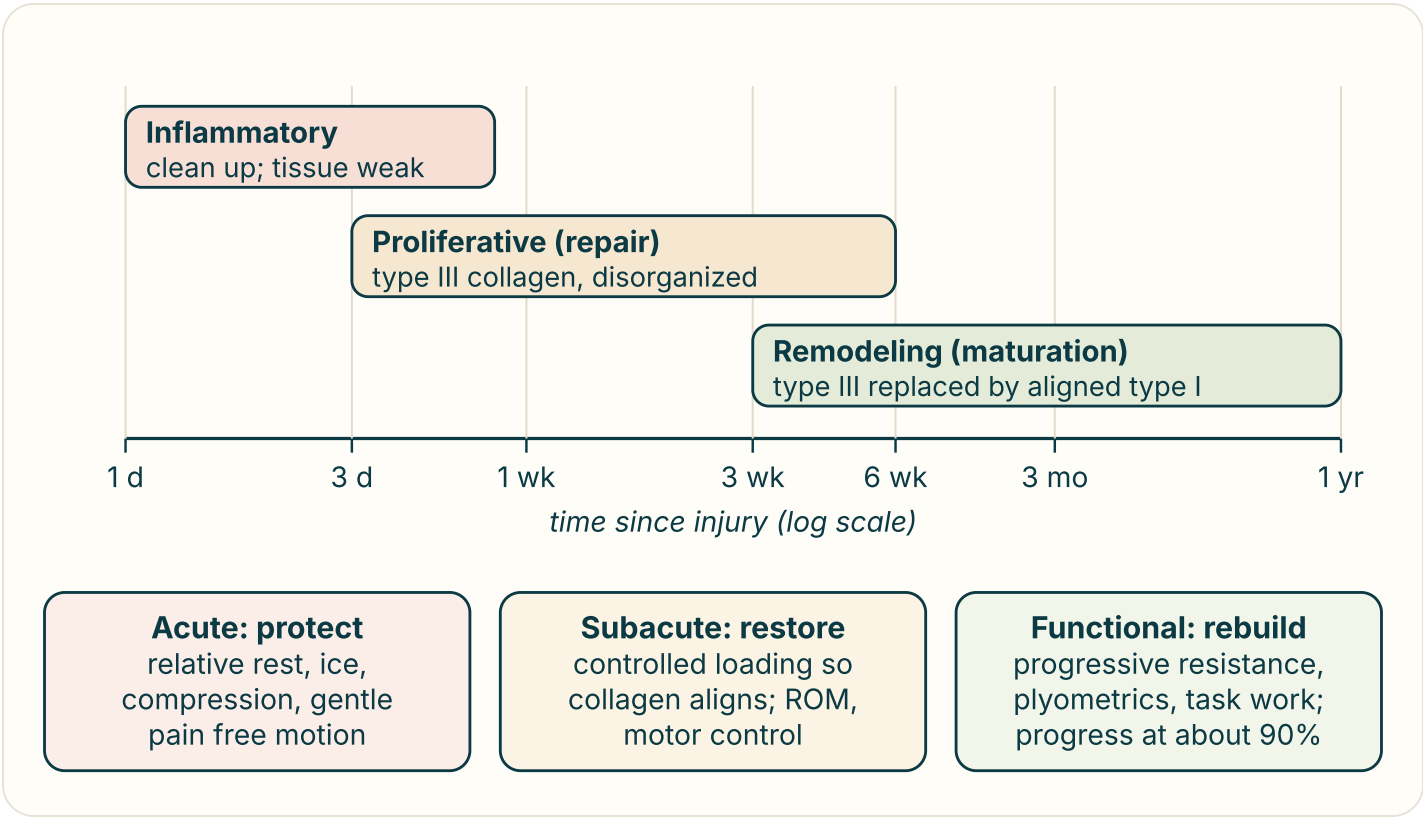

Healing sets the rehab plan. The phases overlap. Protect in the inflammatory phase, load with control in the repair phase so new collagen lines up, and build strength and skill through the long remodeling phase. Tendon and ligament take longer than muscle.

LOCK THESE IN

- Ice acute; heat subacute.
- 3 MHz shallow; 1 MHz deep.
- Demand pacemaker: no e-stim.
- Warfarin plus vitamin K: INR falls.
- Centralize: continue; peripheralize: stop.
- Match counseling to stage of change.

Modality settings and contraindications

Modality	Parameters	Never use with
Ice pack	15 to 20 min; acute stage	Raynaud, cold urticaria, cryoglobulinemia, PVD
Moist heat	70 to 75 °C pack, 6 to 8 layers, about 20 min	Acute inflammation, bleeding, DVT, malignancy, pregnant low back
Paraffin	About 52 to 54 °C, dip and wrap	Open wounds, impaired sensation
Ultrasound	1 MHz deep (2.5 to 5 cm); 3 MHz shallow (1 to 2 cm); 0.5 to 2.5 W/cm^2	Pregnant uterus, eyes, testes, tumor, pacemaker, DVT, cemented joints
High rate TENS	80 to 150 Hz, 50 to 100 µs, sensory	Demand pacemaker, carotid sinus, anterior neck
Low rate TENS	2 to 10 Hz, motor level	Same as above; pregnant uterus
IFC	Carriers near 4,000 Hz, beat 1 to 150 Hz	Same as electrical stimulation
NMES (Russian)	2,500 Hz, 50 bursts/s, 10 s on, 50 s off	Same as electrical stimulation
Iontophoresis	40 to 80 mA·min	Dexamethasone (−), lidocaine (+)
Cervical traction	10 to 15 lb start; 20 to 30 lb to separate	Instability, tumor, infection, vertebral artery disease
Lumbar traction	25% body weight friction; 50% to separate	Pregnancy, instability, severe osteoporosis
Laser	About 600 to 1,000 nm, J/cm^2	Eyes, malignancy, thyroid, pregnant uterus

Worked cases

WORKED CASE 1 · A KARVONEN TARGET RANGE

A 50 year old woman with a resting heart rate of 70 is cleared for exercise. What is her moderate intensity target range?

STEP 1 · MAXIMUM HR

220 − 50 = 170.

STEP 2 · HEART RATE RESERVE

170 − 70 = 100.

STEP 3 · APPLY 40 AND 59 PERCENT

70 + 0.40 × 100 = 110; 70 + 0.59 × 100 = 129.

STEP 4 · ANSWER AND CAUTION

Target **110 to 129 beats per minute**. If she takes a beta blocker, use RPE about 12 to 13 instead.

TRAPS PEOPLE FALL INTO

- **Heat on a fresh sprain.** Heat increases blood flow and edema. Protect, compress, elevate and use short bouts of ice.
- **Calling metal implants a contraindication to ultrasound.** They are not. They are a contraindication to diathermy.
- **Electrical stimulation with a demand pacemaker.** Use heat, manual therapy and exercise instead.
- **Calcium carbonate for a patient on a PPI.** Citrate is absorbed without acid.
- **Going gluten free before testing.** Serology and biopsy normalize on the diet; test first.

Chapter 10 self-test · six items

1. Which electrical current is used mainly to strengthen the quadriceps after knee surgery?

A. Iontophoresis with lidocaine
B. Russian stimulation or NMES
C. Low rate acupuncture TENS
D. High rate sensory TENS

B. Russian stimulation or NMES NMES at 2,500 Hz in 50 bursts per second with 10 on and 50 off reeducates and strengthens muscle.

2. Which is a contraindication to shortwave diathermy but not to ultrasound?

A. A pregnant uterus in the treatment field
B. A malignancy in the area
C. A metal plate in the treatment area
D. A deep vein thrombosis

C. A metal plate in the treatment area Metal implants contraindicate diathermy; ultrasound may be used at lower intensity.

3. A vegan patient on metformin has numb feet and a macrocytosis. Which supplement concern fits?

A. Excess calcium from fortified milk
B. Vitamin A toxicity from carrots
C. Vitamin D toxicity from sunlight
D. Vitamin B12 deficiency needing testing

D. Vitamin B12 deficiency needing testing Vegan diets and metformin cause B12 deficiency with neuropathy; refer for testing and replacement.

4. A worker off 9 weeks fears activity will damage his spine and is in dispute with his employer. What predicts his outcome best?

A. Yellow and black flags plus time off
B. His leg length difference
C. The size of his disc bulge on MRI
D. His lumbar range of motion today

A. Yellow and black flags plus time off Psychosocial and system factors predict chronicity better than imaging; use graded activity and modified duty.

5. What is the RPE range for moderate intensity on the 6 to 20 Borg scale?

A. About 18 to 20
B. About 12 to 13
C. About 15 to 17
D. About 6 to 8

B. About 12 to 13 Moderate is about 12 to 13; vigorous about 14 to 17.

6. A patient says he has walked every day for six weeks. Which stage of change is this?

A. Action
B. Maintenance
C. Contemplation
D. Preparation

A. Action He is doing the new behavior, but recently. Affirm the effort, problem solve setbacks and progress the plan.

CHAPTER 11

Case Management

Read it in full: **Chapter 11 in the textbook**. Practice it: **the Study Guide 6 practice exam** and **the flashcards**.

What to know

A plan names diagnosis, baseline, SMART goals, interventions, frequency, duration, re-exam date and discharge criteria. Phases run relief, corrective, self-management, then supportive (documented regression) or elective maintenance. A trial of care is about 2 weeks; two trials without response means change, test or refer.

Prognosis starts with natural history and worsens with severity, prior episodes, structural disease and yellow flags; STarT Back high risk needs psychologically informed care. MCIDs: NPRS

about 2, ODI about 10, NDI about 5 to 7. Re-examine every 2 to 4 weeks or about 12 visits.

Every referral has a destination and a speed: emergency, urgent (telephoned and confirmed), prompt or routine. Document informed refusal when a patient declines.

SOAP notes are timely, individualized, measurable and match the bill. PART needs two of four with A or R. PARQ consent is renewed when risk changes. 98940 to 98942 code 1 to 2, 3 to 4 and 5 spinal regions; 98943 is extraspinal.

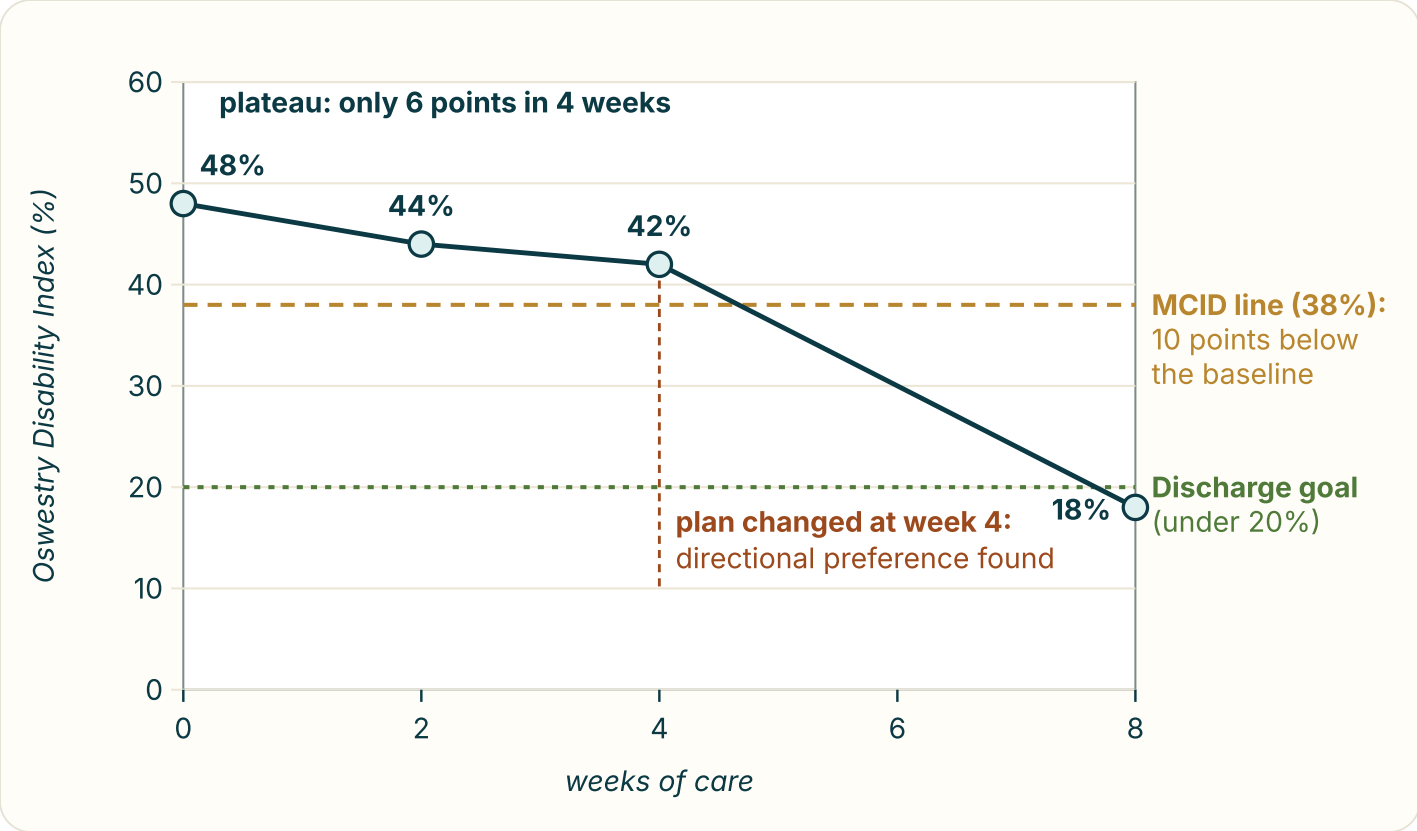

Judge change against the MCID. After two trials the Oswestry fell only 6 points, short of the 10 point MCID: a plateau. A new finding justified a new plan, and the score then passed both the MCID and the discharge goal.

LOCK THESE IN

- Two failed trials: change, test or refer.
- ODI MCID about 10 points.
- STarT Back high: add psychologically informed care.
- Referral = destination plus speed.
- PART: two of four, one A or R.
- Renew consent when risk changes.

Outcome measures and MCIDs

Measure	Scoring	Commonly taught MCID
NPRS	0 to 10	About 2 points or 30%
VAS	0 to 100 mm	About 15 to 20 mm
Oswestry (ODI)	0 to 100%	About 10 points or 30%
Roland Morris	0 to 24	About 3 to 5 points
Neck Disability Index	0 to 50 (or 0 to 100%)	About 5 to 7 points (10 to 14%)
PSFS	0 to 10 average	About 2 points
Headache Disability Index	0 to 100	About 16 points
FABQ work	0 to 42	Over 34 predicts poor return to work

Worked cases

WORKED CASE 1 · JUDGING A RE-EXAMINATION AGAINST THE MCID

A 46 year old has had twice weekly care for 4 weeks. NPRS went from 7 to 5 and ODI from 44% to 39%. Is this meaningful improvement?

STEP 1 · NPRS CHANGE

7 − 5 = 2 points, which is 2 ÷ 7 = 29%. That sits right at the MCID (about 2 points or 30%): borderline.

STEP 2 · ODI CHANGE

44 − 39 = 5 points, which is 5 ÷ 44 = 11%. Well short of about 10 points or 30%.

STEP 3 · WEIGH FUNCTION

The function score is the more persuasive measure, and it has not moved meaningfully: a plateau after two trials.

STEP 4 · ACT

Recheck the diagnosis, the treatment, adherence and yellow flags; then change the plan, test or refer. Do not simply continue or increase frequency.

TRAPS PEOPLE FALL INTO

- **Continuing or increasing care after a plateau.** No meaningful change after two trials means reassess, change, test or refer.
- **Calling a 5 point ODI gain improvement.** The MCID is about 10 points.
- **Right specialist, wrong speed.** Suspected cauda equina to a routine neurosurgery appointment is still wrong.
- **Relying on the intake consent form forever.** Renew consent when the diagnosis, technique, region or risk changes.
- **Cloned notes.** Each note needs visit specific numbers and an assessment of progress.

Chapter 11 self-test · six items

1. Which goal is written in SMART form?

A. ODI from 46% to under 20% in six weeks to return to full duty
B. Make the patient feel better about her back
C. Improve posture and general spinal health
D. Decrease the patient's pain as much as possible over the next months

A. ODI from 46% to under 20% in six weeks to return to full duty A SMART goal is specific, measurable, achievable, relevant and time bound, and tied to function.

2. Relief lasts only a few hours after each visit and then returns to baseline. What does this suggest?

A. The patient has reached full recovery
B. Imaging is required before any change
C. Visit frequency should be doubled
D. Passive care is not addressing the driver

D. Passive care is not addressing the driver Temporary relief without sustained change calls for active care or another approach and a diagnosis check.

3. How is an error in a paper note corrected?

A. Backdate a new note to replace it
B. Single line through it, correction, date, initials, reason
C. Tear out the page and redo the whole note from memory the same day
D. Correction fluid and a clean rewrite

B. Single line through it, correction, date, initials, reason Corrections stay visible and dated; never erase, obliterate or backdate.

4. Which seventh character on a sprain code marks active treatment?

A. D
B. X
C. A
D. S

C. A A is active treatment, D subsequent (healing phase), S sequela.

5. Which tool sorts low back pain patients into low, medium and high risk of persistent disability?

A. Neck Disability Index
B. STarT Back Screening Tool
C. Patient Specific Functional Scale
D. Headache Disability Index

B. STarT Back Screening Tool STarT Back has nine items and matches treatment intensity to risk.

6. A Medicare patient chooses elective maintenance care. What must happen beforehand?

A. She signs an Advance Beneficiary Notice
B. A new x-ray documents the subluxation
C. The claim is billed with the AT modifier
D. Nothing; Medicare covers maintenance

A. She signs an Advance Beneficiary Notice Maintenance is not medically necessary; an ABN is signed and the GA modifier is used.

CHAPTER 12

Image Interpretation I: Arthritic Disorders

Read it in full: **Chapter 12 in the textbook**. Practice it: **the Study Guide 6 practice exam** and **the flashcards**.

What to know

OA is productive: nonuniform narrowing, sclerosis, osteophytes, cysts, normal density, no erosions. Osteochondrosis (narrowing, vacuum, endplate sclerosis) differs from spondylosis deformans (claw osteophytes). DISH flows over four or more levels with tall discs and normal SI joints; it fractures after minor trauma.

RA is symmetric and proximal with osteopenia, uniform narrowing and marginal erosions, sparing the DIP joints. Adult ADI over 3 mm, often only in flexion, forbids upper cervical thrust. JIA adds growth disturbance and C2 to C3 ankylosis.

Sacroiliitis starts on the iliac side; bilateral symmetric suggests AS or enteropathic, asymmetric psoriatic or reactive, unilateral infection. AS: shiny corners, squaring, marginal syndesmophytes, bamboo spine. Psoriatic: DIP, pencil in cup, nonmarginal syndesmophytes.

Gout: punched out erosions with overhanging edges and preserved space. CPPD: chondrocalcinosis and OA in unusual joints. HADD: cloudlike tendon calcification.

Hemochromatosis: hook osteophytes. Read with ABCDS and end with labs, imaging and precautions.

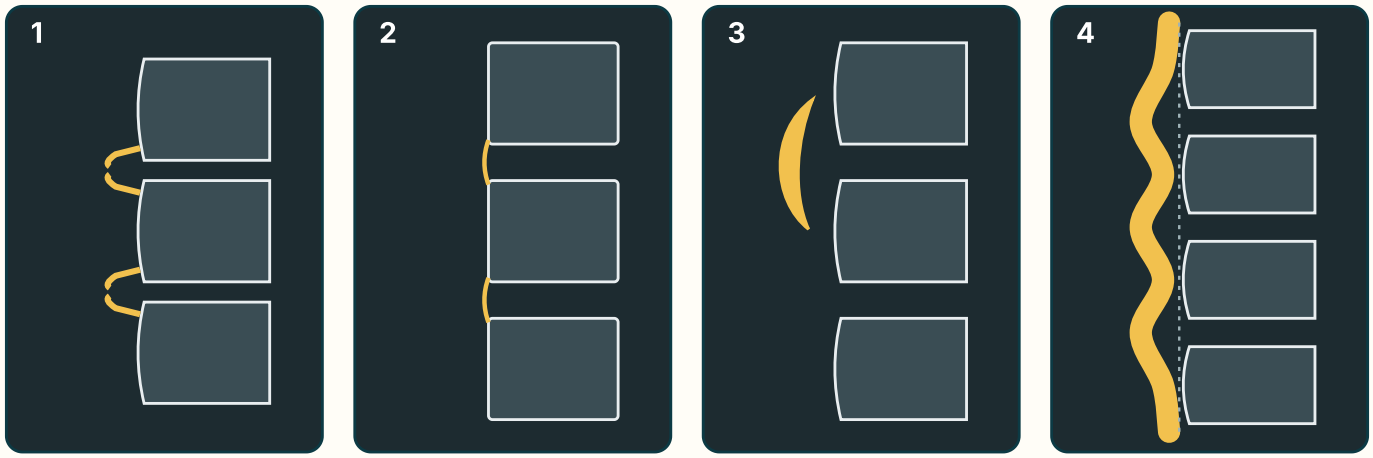

Schematic lateral views, anterior to the left. Start point, direction, thickness and disc height decide.

Four kinds of spinal new bone. Read where the new bone starts, which way it grows, how thick it is and what the disc does. Thin corner bridges are AS; bulky separate commas are psoriatic or reactive; thick flowing bone over tall discs is DISH.

LOCK THESE IN

- OA nonuniform; RA uniform.
- ADI over 3 mm: no upper cervical thrust.
- Marginal syndesmophyte: AS; nonmarginal: psoriatic or reactive.
- DISH: 4+ levels, tall discs, normal SI.
- Gout keeps the joint space.
- OA in an odd joint: CPPD.

Arthritis patterns on film

Disease	Distribution	Density	Joint space	Erosions and new bone
Osteoarthritis	Weight bearing, DIP, PIP, 1st CMC; asymmetric	Normal	Nonuniform loss	None (central in erosive OA); osteophytes
Rheumatoid	Bilateral MCP, PIP, wrist, MTP, C1 to C2	Periarticular osteopenia	Uniform loss	Marginal, no rim; no new bone
Ankylosing spondylitis	SI, spine, hips, shoulders; symmetric	Normal early, osteoporotic late	Loss then ankylosis	SI and corners; marginal syndesmophytes
Psoriatic	DIP, ray; SI asymmetric	Normal	Loss or widening	Pencil in cup; fluffy periostitis; nonmarginal
Reactive	Feet, ankles, knees, heels	Normal or early loss	Loss	Marginal; calcaneal periostitis
Gout	1st MTP, foot, knee, olecranon	Normal	Preserved until late	Punched out, sclerotic rim, overhanging edge
CPPD	Knee, wrist, 2nd and 3rd MCP, patellofemoral	Normal	OA like loss	Large cysts; chondrocalcinosis
Neuropathic	Midfoot, shoulder, knee by cause	Increased or resorbed	Destroyed	Debris, fragments, sclerosis

Worked cases

WORKED CASE 1 · READING NEW BONE ON A LATERAL FILM

A 68 year old obese man with diabetes has thoracic stiffness and trouble swallowing solids. The lateral thoracic film shows thick, undulating anterior ossification from T6 to T11, a thin lucent line between it and

the bodies, normal disc heights and unfused facets. The SI joints are normal.

STEP 1 · ALIGNMENT AND DENSITY

Alignment normal; bone density normal; the finding is productive new bone.

STEP 2 · DESCRIBE THE NEW BONE

Thick, flowing, anterior, six contiguous levels, separated from the bodies by a lucent line.

STEP 3 · CHECK THE DISCS AND SI JOINTS

Discs tall; facets and SI joints normal. That rules out AS (marginal syndesmophytes, sacroiliitis) and degenerative spondylosis (narrow discs).

STEP 4 · IMPRESSION

DISH.

STEP 5 · RECOMMENDATIONS

Evaluate the dysphagia (lateral cervical or ENT); note fracture risk: CT for any pain after trauma; no thrust through ossified segments; treat adjacent mobile levels gently.

TRAPS PEOPLE FALL INTO

- **Calling DISH ankylosing spondylitis.** DISH has thick flowing bone, tall discs and normal SI joints. AS has thin corner syndesmophytes and sacroiliitis.
- **Trusting a neutral ADI in RA.** Instability may appear only in flexion. Get flexion and extension views.
- **Reading a vacuum disc as infection.** Gas in the disc argues strongly against infection.
- **Calling DIP disease with fluffy new bone rheumatoid.** DIP, normal density and new bone mean psoriatic arthritis.
- **Ruling out gout because the joint space is normal.** Gout preserves the space and density until late.

Chapter 12 self-test · six items

1. Which finding essentially excludes infection in a narrowed disc?

A. A vacuum phenomenon in the disc
B. Paraspinal soft tissue swelling
C. Endplate erosion on both sides
D. Loss of the endplate white line

A. A vacuum phenomenon in the disc Gas within a degenerated disc argues strongly against infection, which destroys the endplates.

2. Ballooned epiphyses, a widened intercondylar notch and a squared patella in a child most suggest what?

A. Adult onset rheumatoid arthritis
B. Juvenile idiopathic arthritis
C. Osteochondritis dissecans
D. Slipped capital epiphysis

B. Juvenile idiopathic arthritis Chronic hyperemia in JIA causes these growth changes; hemophilic arthropathy is the main differential.

3. Three vertical lines of ossification on the AP lumbar view in AS are called what?

A. The winking owl sign
B. The pencil in cup sign
C. The Martel sign
D. The trolley track sign

D. The trolley track sign Ossified facet capsules and midline ligaments make three lines; a single central line is the dagger sign.

4. A patient with a bamboo spine fell from standing and has new neck pain, and plain films look unchanged. What next?

A. Reassure and adjust gently
B. A bone scan in six weeks
C. CT of the cervical spine
D. Repeat plain films in a month

C. CT of the cervical spine Carrot stick fractures through a fused spine are unstable and often missed on radiographs.

5. Cloudlike calcification just above the greater tuberosity in a painful shoulder is most likely what?

A. Hydroxyapatite calcific tendinitis
B. A gouty tophus
C. Myositis ossificans
D. Chondrocalcinosis from CPPD deposition

A. Hydroxyapatite calcific tendinitis HADD favors the supraspinatus tendon; it is amorphous without trabeculae.

6. Fragmentation, sclerosis, debris and dislocation at the Lisfranc joints of a diabetic suggest what?

A. Primary osteoarthritis
B. Rheumatoid arthritis of the foot
C. Neuropathic (Charcot) arthropathy
D. Chronic tophaceous gout

C. Neuropathic (Charcot) arthropathy The six Ds at the midfoot in diabetes is Charcot arthropathy; osteomyelitis is the main differential.

CHAPTER 13

Image Interpretation II: Congenital Anomalies, Variants, Scoliosis and Trauma

Read it in full: **Chapter 13 in the textbook**. Practice it: **the Study Guide 7 practice exam** and **the flashcards**.

What to know

Anomalies are failures of formation (hemivertebra, butterfly) or segmentation (block vertebra, occipitalization). Os odontoideum (smooth ossicle, large C1 arch) is unstable: no upper cervical thrust. A block vertebra has a wasp waist. Variants are corticated, bilateral and typically placed; fractures are sharp and tender.

DDH: the head belongs in the lower inner quadrant; acetabular index 30 degrees or less; Shenton unbroken. Scoliosis is 10 degrees by Cobb; observe 10 to 25, brace 25 to 40 in a growing child, surgical opinion over 40 to 50; atypical curves need MRI.

The middle column decides stability. Jefferson over 7 mm overhang, type II dens, flexion teardrop, bilateral facet dislocation, burst, Chance and fracture dislocation are unstable. Scotty dog collar is spondylolysis; Meyerding grades by quarters. Salter Harris SALTR.

Soft tissue: 7 mm at C2, 22 mm at C6; a posterior fat pad or FBI sign means fracture. Flexion and extension views (3.5 mm, 11 degrees) only after fracture is excluded.

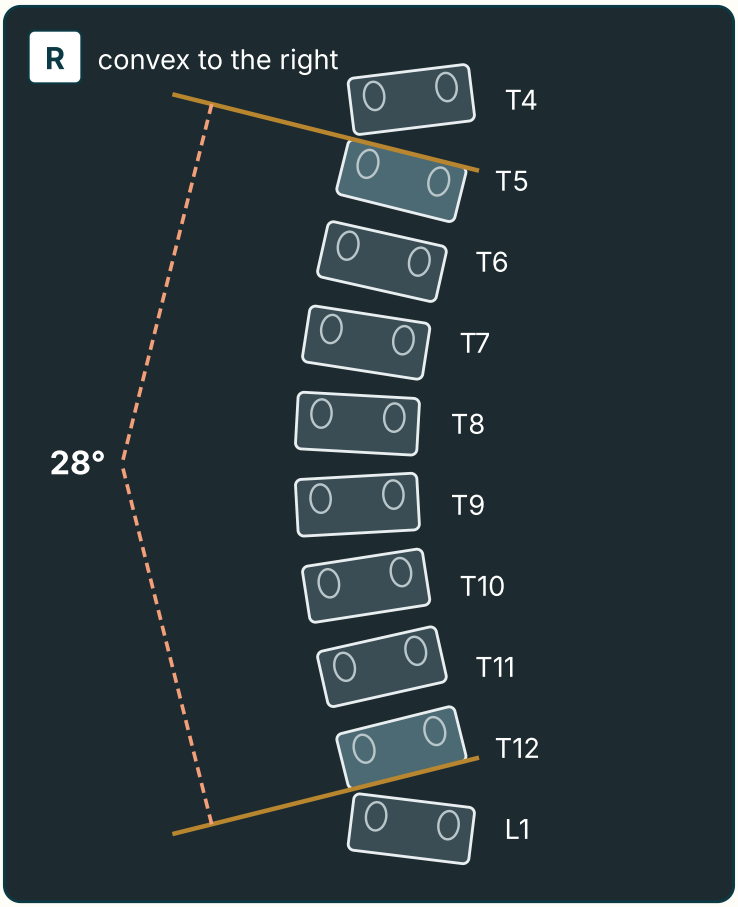

Cobb method

1 Find the end vertebrae:
the most tilted (T5, T12)
2 Line along the top plate
of T5 and bottom of T12
3 Draw perpendiculars;
measure where they meet
4 Error about 3 to 5°:
progression needs over 5°

Risser sign (iliac apophysis)

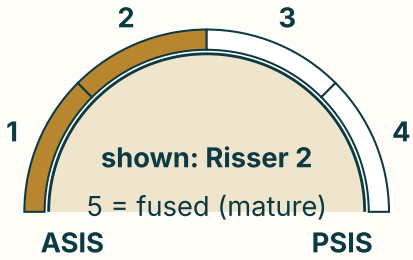

Growing child (Risser 0 to 2):
10 to 25° observe
25 to 40° refer for bracing
over 40 to 50° surgical opinion
atypical curve: MRI at any size

The Cobb angle and the Risser sign. Lines along the most tilted end plates, or their perpendiculars, give the Cobb angle; here each end vertebra tilts 14 degrees, for 28 degrees. Curve size plus Risser grade decides observation, bracing or surgical referral.

LOCK THESE IN

- Os odontoideum: no upper cervical thrust.
- Wasp waist: congenital block.
- Acetabular index over 30 degrees: dysplasia.
- Cobb 25 to 40 in a growing child: brace.
- Middle column injury: unstable.
- 7 at C2, 22 at C6.

Unstable or urgent patterns

Injury	Hallmark	Action
Jefferson burst	C1 overhang over about 7 mm (Spence)	Immobilize; ED for CT
Type II dens	Line at the base, noncorticated	Immobilize; ED
Hangman fracture	Bilateral C2 pars lines, C2 slips forward	Immobilize; ED
Flexion teardrop	Large anteroinferior fragment, body into canal	Immobilize; ED
Bilateral facet dislocation	Anterolisthesis 50% or more	Immobilize; ED
Burst fracture	Posterior wall involved, widened pedicles	CT; ED
Chance fracture	Horizontal split, posterior elements to body	ED (abdominal injury)
Femoral neck stress (tension side)	Superolateral neck line	Stop weight bearing; same day
SCFE	Klein line misses the epiphysis	Non weight bearing; urgent
Delayed cervical instability	Translation over 3.5 mm, fanning	Collar, MRI, prompt surgical referral

Worked cases

WORKED CASE 1 · MEASURING A COBB ANGLE

A 12 year old premenarchal girl has a right thoracic curve. On the standing PA film the superior end plate of T5 tilts 14 degrees one way and the inferior end plate of T12 tilts 14 degrees the other way. The iliac apophyses show no ossification.

STEP 1 · CONFIRM THE END VERTEBRAE

T5 and T12 are the most tilted at each end of the curve.

STEP 2 · ADD THE TILTS

Opposite directions add: 14 + 14 = **28 degrees**.

STEP 3 · GRADE MATURITY

No apophyseal ossification is Risser 0; she is premenarchal, near peak growth.

STEP 4 · DECIDE

Over 25 degrees in a growing child: refer to an orthopedic scoliosis specialist for bracing assessment now. Night pain, a left thoracic curve or abnormal abdominal reflexes would add MRI.

TRAPS PEOPLE FALL INTO

- **Calling os odontoideum a fresh fracture (or the reverse).** Smooth, corticated and a large C1 arch mean old; sharp and noncorticated mean fresh.
- **Trusting a neutral film for upper cervical stability.** Flexion and extension views are needed, after fracture is excluded.
- **Calling a butterfly vertebra a compression fracture.** Look at the AP: two triangles with reciprocal neighbors.
- **Relying on Ortolani and Barlow at 9 months.** They fade after about 3 months. Use abduction, Galeazzi and an AP pelvis.
- **Observing a 28 degree curve at Risser 0.** That is in the bracing range in a growing child: refer.

Chapter 13 self-test · six items

1. A smooth corticated fragment at the superolateral patella, present on both knees, is most likely what?

A. Bipartite patella
B. Osteochondral loose body
C. Patellar sleeve fracture
D. Transverse patellar fracture

A. Bipartite patella Superolateral, bilateral and corticated means a developmental variant.

2. On a lateral cervical film, a large anteroinferior body fragment with the posterior body pushed into the canal after a dive is what?

A. A clay shoveler fracture
B. A flexion teardrop fracture
C. An extension teardrop fracture
D. A limbus bone variant

B. A flexion teardrop fracture Flexion teardrop is highly unstable with anterior cord syndrome risk.

3. On the oblique lumbar view, a collar on the neck of the Scotty dog means what?

A. A pedicle fracture
B. A spina bifida occulta at L5
C. Facet arthrosis
D. Spondylolysis (pars defect)

D. Spondylolysis (pars defect) The neck of the Scotty dog is the pars interarticularis.

4. A posterior fat pad is visible on a lateral elbow film of a 7 year old after a fall. What is most likely?

A. Simple elbow sprain only
B. Nursemaid elbow, reduce it
C. An occult supracondylar fracture
D. A normal finding in children

C. An occult supracondylar fracture A visible posterior fat pad is never normal; in children it suggests a supracondylar fracture.

5. Which finding favors an osteoporotic over a pathologic compression fracture?

A. A destroyed pedicle on the AP view
B. Intact posterior wall and pedicles below T6
C. A level above T5 with a soft tissue mass
D. A convex posterior vertebral wall

B. Intact posterior wall and pedicles below T6 Pathologic fractures destroy pedicles, bulge the posterior wall and occur higher.

6. A lateral cervical film shows about 25 percent anterolisthesis of C5 on C6 with a bow tie appearance of the facets. What is it?

A. Degenerative spondylolisthesis
B. Normal pseudosubluxation
C. Unilateral facet dislocation
D. Bilateral facet dislocation

C. Unilateral facet dislocation About 25 percent slip with a bow tie sign is unilateral; 50 percent or more is bilateral.

CHAPTER 14

Image Interpretation III: Tumors, Miscellaneous Osteoarticular Disease and Soft Tissue

Read it in full: **Chapter 14 in the textbook**. Practice it: **the Study Guide 7 practice exam** and **the flashcards**.

What to know

Describe by age, number, location, margin, matrix, periosteal reaction and soft tissue. Over 40, a destructive lesion is metastasis or myeloma. Benign signatures: corduroy hemangioma, osteoid

osteoma nidus, osteochondroma continuity, enchondroma rings and arcs, fallen fragment, blown out ABC, ground glass, subarticular giant cell tumor.

Osteosarcoma: teens, knee, sunburst. Ewing: child, diaphysis, onion skin, fever. Chondrosarcoma: over 40, painful chondroid lesion. Myeloma: punched out holes, cold scan, M protein. Metastasis: winking owl, preserved disc; kidney and thyroid lytic expansile, prostate blastic.

Sickle cell gives H shaped vertebrae; AVN crescent sign means collapse. Infection crosses the disc; TB spreads under ligaments with a gibbus. Osteomalacia gives Looser zones; hyperparathyroidism radial phalangeal resorption; renal osteodystrophy rugger jersey; Paget picture frame and very high ALP.

Read the soft tissues: Pancoast at the apex, pneumothorax pleural line, effusion blunting, CTR over 0.5 on PA, AAA 3 cm or more in front of L1 to L4 (pain means emergency), opaque kidney stones, mostly lucent gallstones.

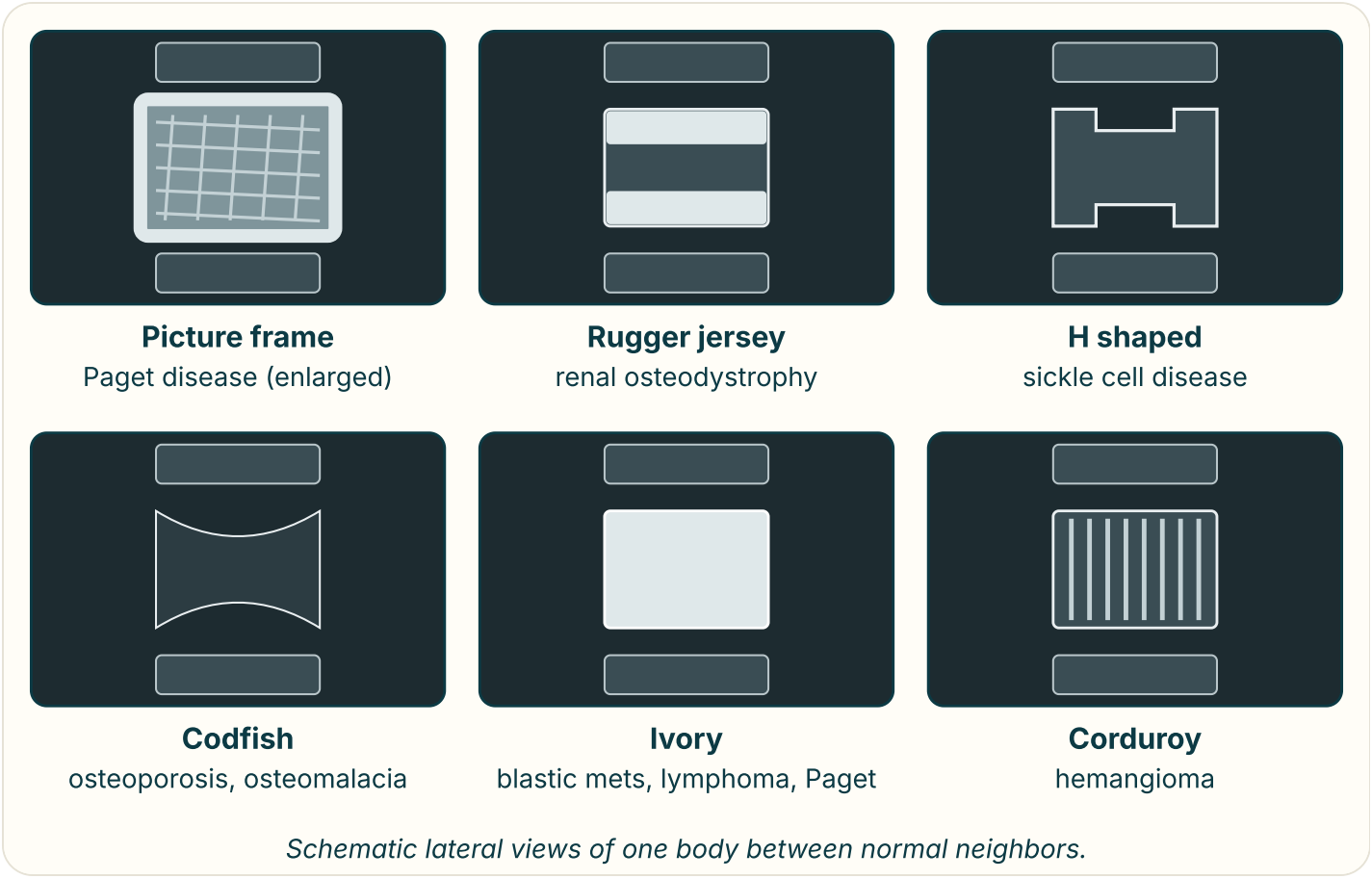

Six vertebral body patterns. Paget enlarges the body and thickens its frame; renal osteodystrophy stripes the end plates; sickle cell punches square central depressions; osteoporosis makes biconcave bodies; a dense normal sized body is ivory; coarse vertical striations are a hemangioma.

LOCK THESE IN

- Over 40: metastasis or myeloma first.
- Winking owl: metastasis.
- Myeloma: cold bone scan.
- Infection crosses the disc.
- Picture frame: Paget.
- AAA 3 cm or more; pain means emergency.

Bone lesions by age, site and sign

Lesion	Age and site	Hallmark
Hemangioma	Adults; thoracolumbar body	Corduroy; polka dot on CT
Osteoid osteoma	10 to 25; femur, tibia, posterior elements	Nidus under 1.5 cm; NSAID relieved night pain
Osteochondroma	Under 20; knee, humerus	Corticomedullary continuity; points away from joint
Enchondroma	Any; hand phalanges	Rings and arcs; scalloping under 2/3 cortex
Simple bone cyst	Under 20; proximal humerus	Central, metaphyseal; fallen fragment
ABC	Under 20; posterior elements	Eccentric, blown out; fluid levels
Giant cell tumor	20 to 40; distal femur, sacrum	Eccentric subarticular, no rim, closed physis
Osteosarcoma	10 to 25; knee metaphysis	Cloudlike osteoid, sunburst, Codman
Ewing sarcoma	5 to 20; diaphysis, pelvis	Permeative, onion skin, large soft tissue mass
Chondrosarcoma	Over 40; pelvis, proximal femur	Painful chondroid lesion over about 5 cm
Myeloma	Over 50; skull, spine, ribs, pelvis	Punched out, no rim; cold bone scan
Metastasis	Over 40; axial skeleton	Winking owl; disc preserved

Worked cases

WORKED CASE 1 · THE WINKING OWL

A 67 year old man with treated prostate cancer has six weeks of constant thoracolumbar pain, worse lying down at night, with no neurologic deficit. The AP lumbar film lacks the right pedicle of L2, and round dense foci sit in both iliac bones.

STEP 1 · AGE AND NUMBER

Over 40 with multiple lesions: metastasis or myeloma first.

STEP 2 · READ THE PEDICLE

A missing pedicle is the winking owl, classic for metastasis; myeloma spares the pedicle until late.

STEP 3 · READ THE DENSITY

Round blastic foci fit prostate metastasis; together the picture is mixed.

STEP 4 · RECOMMENDATIONS

No manipulation. MRI of the whole spine, PSA, CBC, calcium, ALP, prompt oncology referral within days.

STEP 5 · SAFETY NET

Leg weakness, saddle numbness or bladder or bowel change means emergency care the same day.

TRAPS PEOPLE FALL INTO

- **Ranking a primary tumor first in a 65 year old.** Over 40, metastasis and myeloma head every list.
- **Trusting a normal bone scan in suspected myeloma.** It is often cold. Use electrophoresis and a survey, low dose CT or MRI.
- **Calling a narrowed disc with eroded end plates degeneration.** Infection erodes both end plates; degeneration keeps them sharp.
- **Calling every dense vertebra a metastasis.** An enlarged body with a thick frame is Paget.
- **Missing a Pancoast tumor on a cervicothoracic film.** Compare the apices every time.

Chapter 14 self-test · six items

1. A central metaphyseal lytic lesion of the proximal humerus in a 12 year old with a cortical fragment lying in its dependent part is what?

A. A simple bone cyst with fallen fragment
B. An aneurysmal bone cyst with fluid levels
C. A giant cell tumor
D. An osteosarcoma

A. A simple bone cyst with fallen fragment The fallen fragment sign is pathognomonic of a simple bone cyst after fracture.

2. A uniformly flattened vertebral body in a child most suggests what?

A. Osteoporotic codfish vertebra
B. Eosinophilic granuloma (vertebra plana)
C. Scheuermann disease
D. A congenital hemivertebra with one pedicle

B. Eosinophilic granuloma (vertebra plana) Langerhans cell histiocytosis classically causes vertebra plana in children.

3. A subchondral lucent line in the femoral head of a patient on long term steroids is what?

A. A Looser zone (pseudofracture) of osteomalacia
B. A Brodie abscess tract
C. A normal physeal scar
D. The crescent sign of AVN with collapse

D. The crescent sign of AVN with collapse The crescent sign marks collapse of the necrotic segment (stage III).

4. Multiple levels with anterior body destruction, relative disc sparing, a gibbus and a calcified psoas abscess suggest what?

A. Metastatic prostate cancer
B. Ankylosing spondylitis
C. Tuberculous spondylitis
D. Pyogenic discitis

C. Tuberculous spondylitis Pott disease spreads under the anterior ligament and forms a cold abscess.

5. On a PA chest film, what cardiothoracic ratio indicates cardiomegaly?

A. Over 0.8
B. Over 0.5
C. Over 0.3
D. Under 0.5

B. Over 0.5 Heart width over half the internal chest width on a PA upright film; AP films magnify the heart.

6. About what share of gallstones are radiopaque on plain film?

A. About 80 to 90 percent
B. Nearly all of them
C. About 50 percent
D. About 10 to 20 percent

D. About 10 to 20 percent Most gallstones are lucent; ultrasound is the test. Most kidney stones are opaque.

Cram sheet

The whole Part III review on a few pages. Cover the right column and rebuild each row from memory.

History, examination and tests

Item	Value	Note
Diagnostic bins	Serious 1 to 2%; radicular 5 to 10%; mechanical about 90%	History alone diagnoses 70 to 80%
Likelihood ratios	Prior cancer LR+ about 15; LR over 10 or under 0.1 is decisive	LR+ = sens ÷ (1 − spec)
Cauda equina	Retention about 90% sensitive; saddle S2 to S5	Same day ED for MRI
Blood pressure	Stage 2: 140 or 90; severe over 180 and/or 120	Small cuff reads high
Orthostatic	20 systolic or 10 diastolic within 3 min	qSOFA: RR 22+, confusion, SBP 100 or less
ABI	0.90 or less PAD; over 1.40 calcified	Higher ankle ÷ higher brachial
AAA	3 cm; repair 5.5 cm; tender = emergency	Bifurcation at L4
Scoliometer	About 7° means radiograph	About Cobb 20°
Wainner cluster	4 of 4: LR+ about 30	ULTT A sensitivity about 0.97
SLR	Positive 30 to 70°; sens about 0.9	Crossed SLR spec about 0.9
Laslett	3 of 5 SI provocation tests	Thigh thrust most sensitive
Ottawa rules	Sensitivity about 0.98	Knee: age 55+; ankle: distal 6 cm
Wells (DVT)	2 or more: likely	Same day ultrasound
Canadian C spine	65+, dangerous mechanism, paresthesias: image	Else rotate 45° each way
Dose	Double distance: 1/4; +15% kVp = 2 × mAs	Collimation is the best technical step
Lateral cervical	ADI 3 mm (child 5); 7 mm at C2, 22 mm at C6	Canal 13 mm; under 10 stenosis
DEXA	T ≤ −2.5 osteoporosis; Z ≤ −2.0 secondary cause	Use the lowest site

Item	Value	Note
ESR	Men age/2; women (age + 10)/2	Over 100: infection, myeloma, GCA
Corrected calcium	Ca + 0.8 × (4.0 − albumin)	Normal 8.5 to 10.5
Synovial fluid	Septic usually over 50,000 WBC	Crystals do not exclude infection
ECG	Small box 0.04 s; PR 0.12 to 0.20 s; QRS under 0.12 s	Rate = 300 ÷ large boxes
EMG	Study at about 3 weeks or later	Root lesion: normal SNAP

Impression, treatment and management

Item	Value	Note
Dissection	About 2 to 3 per 100,000 a year	5 Ds and 3 Ns; positional tests cannot clear
Flexion rotation test	About 32° or less positive	Normal about 44°
Zoster	Prodrome 2 to 5 days; antivirals within 72 h	Unilateral dermatomal burning
Inflammatory back pain	Onset under 40; 4 of 5 ASAS	Sens about 77%, spec about 92%
PMR	Over 50; 15 to 20% have GCA	Normal strength and CK
Cord compression	5 to 10% of cancer patients	Same day whole spine MRI
Kocher (septic hip)	Fever over 38.5 °C, no weight bearing, ESR over 40, WBC over 12,000	
Facets	C 45°, T 60°, L 90° to the transverse plane	Lower cervical coupling same side
Maitland	I and II pain; III and IV motion; V thrust	Never past the anatomical barrier
Pregnancy	Avoid prolonged supine after about 20 weeks	Preeclampsia 140/90+
Ultrasound	1 MHz deep; 3 MHz shallow	Continuous thermal; pulsed nonthermal
TENS	High 80 to 150 Hz; low 2 to 10 Hz	No e-stim with demand pacemaker
Traction	Lumbar: 25% friction, 50% separation	Cervical 20 to 30 lb
Calcium and D	1,000 to 1,200 mg; 600 to 800 IU	Citrate with PPIs
Dosing	Novice 60 to 70% 1RM, 8 to 12 reps	Endurance under 50%, 15 to 25
Karvonen	Resting + % × (220 − age − resting)	40 to 59% moderate
Activity	150 to 300 min moderate; strength 2+ days	RPE 12 to 13

Item	Value	Note
Trial of care	About 2 weeks; two trials about 4 weeks	Then change, test or refer
MCID	NPRS 2; ODI 10; NDI 5 to 7; PSFS 2	FABQ work over 34 poor
Re-exam	Every 2 to 4 weeks or about 12 visits	And with anything new
CPT	98940 1 to 2; 98941 3 to 4; 98942 5; 98943 extraspinal	Modifier 25 separate E/M

Image interpretation

Item	Value	Note
DISH	4 or more contiguous levels, tall discs	Normal SI joints
RA ADI	Over 3 mm adult; high risk 9 to 10 mm	Often only in flexion
Sacroiliitis	AS: bilateral grade 2+ or unilateral 3 to 4	Unilateral: infection
Urate	Saturates about 6.8 mg/dL	Overhanging edge
Acetabular index	30° or less at birth	Head in lower inner quadrant
Cobb	10° or more; error 3 to 5°	Brace 25 to 40 in growing child
Jefferson	Over 7 mm overhang	Unstable
Meyerding	Quarters: I to 25%, II 50, III 75, IV 100, V beyond	
Salter Harris	SALTR; II about 75%	III and IV need anatomic reduction
Flexion/extension	3.5 mm or 11°	Only after fracture excluded
Osteoid osteoma	Nidus under 1.5 cm	NSAID relieved night pain
Lytic visibility	30 to 50% bone loss	MRI most sensitive for spine
Osteomyelitis	Visible at 10 to 14 days	Infection crosses the disc
Heel pad	Over 23 mm men, 21.5 mm women	Acromegaly
CTR	Over 0.5 on PA	AP magnifies
Stones	Kidney 80 to 90% opaque; gallstones 10 to 20%	Phleboliths have lucent centers

Rules that are not numbers

Topic	The rule
Next question	Pick the question or test whose answer would change management.
Red vs yellow flags	Red predict serious disease; yellow predict chronicity.
SnNout and SpPin	A negative sensitive test rules out; a positive specific test rules in.
Imaging	Image when a red flag, a rule or failed care says the answer could change management.
Tumor vs infection	Tumor spares the disc; infection crosses it.
Contraindications	Absolute: no thrust at that region; relative: modify.
Convex concave	Convex on concave glides opposite; concave on convex glides the same way.
Referral	Destination plus speed; urgent referrals are telephoned and confirmed.
Consent	PARQ; renew when the diagnosis, technique or risk changes.
Records	Pertinent negatives in; single line corrections; never alter after a claim.
Variants	Corticated, bilateral, textbook site means variant.
Fused spine	New pain after minor trauma in AS or DISH means CT.

Dr. Garg Learning · CC BY-SA 4.0
An independent study aid. Not affiliated with or endorsed by the National Board of Chiropractic Examiners.