Study Guide 7

This guide covers the last two image interpretation chapters. The items show a film and ask what it is, what else it could be, and how fast the patient must be seen. Read every film the same way, and finish every interpretation with the recommendation you would write. Work one chapter at a time, study the radiograph style diagram, copy the tables, cover the steps of each worked case, then do the self-tests and the cram sheet.

WHAT THIS GUIDE COVERS

- Chapter 13 · upper cervical anomalies, block vertebra and Klippel Feil, hemivertebra and butterfly vertebra, spina bifida, transitional segments and cervical rib, the corticated margin rule, DDH lines, scoliosis classification, Cobb and Risser, spinal and extremity fractures, Salter Harris, stress fractures, soft tissue trauma signs and flexion and extension views.
- Chapter 14 · describing a bone lesion, benign lesions, osteosarcoma, chondrosarcoma, Ewing sarcoma, myeloma, metastasis and the pedicle sign, sickle cell, AVN and the osteochondroses, osteomyelitis, discitis and tuberculosis, metabolic bone disease and vertebral body patterns, and chest and abdominal soft tissue findings.

CHAPTER 13

Image Interpretation II: Congenital Anomalies, Variants, Scoliosis and Trauma

Read it in full: **Chapter 13 in the textbook**. Practice it: **the Study Guide 7 practice exam** and **the flashcards**.

What to know

An anomaly matters when it makes a segment unstable, overloads its neighbors or predicts anomalies elsewhere. Anomalies are failures of **formation** (hemivertebra, butterfly vertebra, pedicle agenesis) or of **segmentation** (block vertebra, occipitalization, unsegmented bar). Occipitalization fuses C1 to the occiput, loads C1 to C2 and travels with basilar impression and Chiari malformation. **Os odontoideum** is a smooth, corticated ossicle above a short dens with a

large, rounded anterior arch of C1; it moves with C1, is unstable and contraindicates upper cervical thrust. A fresh type II dens fracture has a thin, irregular, noncorticated line and a normal arch. Ponticulus posticus (about 10 to 15 percent) is a variant worth noting. Basilar impression: dens tip more than about 7 mm above McGregor line.

A congenital **block vertebra** (C2 to C3, C5 to C6) has a wasp waist at the missing disc, a combined height of two bodies plus a disc, fused facets and an oval foramen; neighbors become hypermobile. Acquired fusion has no waist. Klippel Feil travels with Sprengel deformity and renal, cardiac and hearing anomalies (renal ultrasound). A hemivertebra is a wedge with one pedicle and a short sharp curve; a butterfly vertebra shows two triangles with reciprocally shaped neighbors on the AP. Spina bifida occulta (L5, S1) is usually insignificant; a hair tuft or dimple with neurologic signs suggests tethered cord. Transitional segments (about 10 to 15 percent) follow Castellvi I to IV (a unilateral, b bilateral); state how you counted. A cervical rib comes from C7 (downward pointing transverse process).

The **corticated margin rule**: a developmental ossicle is smooth, rounded and corticated on all sides, often bilateral and in a textbook site; a fracture fragment is sharp, noncorticated on the fracture side, fits a defect and is tender. The fifth metatarsal apophysis runs parallel to the shaft; a fracture runs transverse. Bipartite patella is superolateral and bilateral. A bipartite sesamoid is larger than its partner. A Mach band extends beyond the bone. A nutrient foramen crosses one cortex. When unsure, get a comparison view.

In **DDH** (female, breech, first born, left hip), Barlow and Ortolani fade after about 3 months; then limited abduction and Galeazzi lead. Ultrasound before about 4 to 6 months, then an AP pelvis: the head belongs in the lower inner quadrant of Hilgenreiner and Perkins lines, the acetabular index should be about 30 degrees or less (about 20 to 22 by age 2), and Shenton line should be unbroken. Refer promptly. **Scoliosis** is 10 degrees or more by Cobb. Bodies rotate toward the convexity. Adolescent idiopathic scoliosis is about 80 percent of structural curves, usually right thoracic. Atypical curves (left thoracic, short and sharp, rapid, under 10, painful, abnormal abdominal reflexes, cavus foot) need MRI. Cobb error is about 3 to 5 degrees. Risser 0 to 5; peak growth is before Risser 1. A 20 to 29 degree curve progresses in about two thirds at Risser 0 to 1. Observe 10 to 25, brace 25 to 40 (or 45) in a growing child, surgical opinion over about 40 to 50.

Decide neck films with NEXUS or the Canadian C spine rule. The **Denis three column** model: injury to two or more columns, especially the middle column, is unstable. **Jefferson** burst of C1: combined lateral mass overhang over about 7 mm (rule of Spence) means transverse ligament rupture. **Dens** fractures: type I tip, type II base (most common, nonunion), type III into the body (Harris ring broken). **Hangman**: bilateral C2 pars fractures from hyperextension. Clay shoveler (C7 spinous) and simple wedge fractures are stable; flexion teardrop is highly unstable; extension teardrop is stable in flexion; unilateral facet dislocation gives about 25 percent anterolisthesis and a bow tie sign; bilateral gives 50 percent or more. Burst (T12 to L2) needs CT; Chance fractures carry abdominal injury in up to half.

Osteoporotic versus pathologic fracture: intact posterior wall and pedicles below T6 favor osteoporosis; a destroyed pedicle, convex posterior wall, soft tissue mass or level above T5 favor malignancy. Spondylolysis (about 5 to 6 percent; L5 in about 85 to 90 percent) is a collar on the **Scotty dog**; early stress reactions need MRI, SPECT or CT. Wiltse types I to VI; **Meyerding** grades by quarters (V is spondyloptosis, inverted Napoleon hat). Extremity musts: posterior shoulder dislocation (lightbulb, rim sign over 6 mm), supracondylar fracture (posterior fat pad, anterior humeral line), Monteggia, scaphoid, perilunate (spilled teacup), Maisonneuve, Jones versus pseudo Jones, Lisfranc. **Salter Harris** SALTR: II is most common (about 75 percent, Thurston Holland fragment); III and IV need anatomic reduction. Posterior rib and metaphyseal corner fractures suggest abuse; chiropractors are mandated reporters.

Stress fractures hide on films for 2 to 3 weeks; MRI is the best early test; a tension side (superolateral) femoral neck stress fracture is a same day referral. Soft tissue signs reveal hidden fractures: prevertebral soft tissue over **7 mm at C2** or **22 mm at C6** in an adult (children 7 and 14); a visible posterior elbow fat pad (radial head in adults, supracondylar in children); a displaced scaphoid fat stripe or bowed pronator quadratus line; a fat fluid level (FBI sign) on a cross table lateral knee meaning an intra-articular fracture. Flexion and extension views show instability (translation over 3.5 mm or 20 percent, angulation over 11 degrees, fanning) but only after fracture is excluded, never forced, and often repeated at 7 to 14 days when spasm settles.

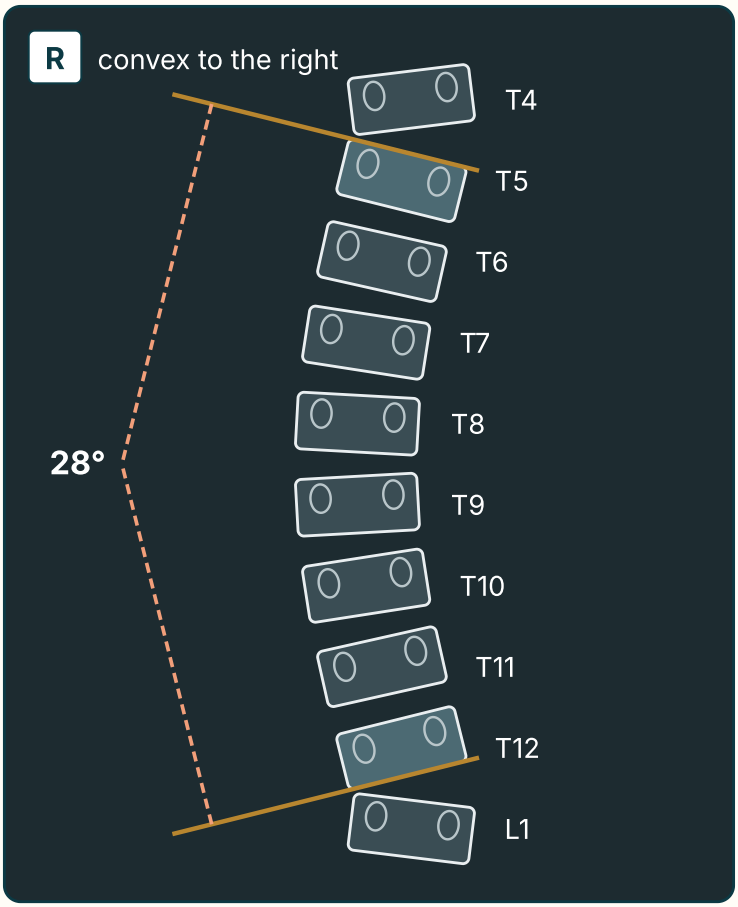

Cobb method

1 Find the end vertebrae:
the most tilted (T5, T12)
2 Line along the top plate
of T5 and bottom of T12
3 Draw perpendiculars;
measure where they meet
4 Error about 3 to 5°:
progression needs over 5°

Risser sign (iliac apophysis)

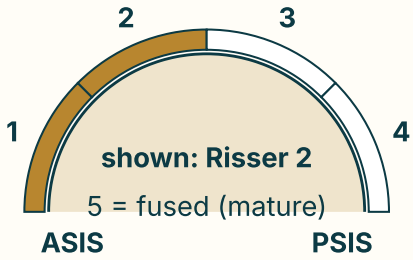

Growing child (Risser 0 to 2):
10 to 25° observe
25 to 40° refer for bracing
over 40 to 50° surgical opinion
atypical curve: MRI at any size

The Cobb angle and the Risser sign. Lines along the most tilted end plates, or their perpendiculars, give the Cobb angle; here each end vertebra tilts 14 degrees, for 28 degrees. Curve size plus Risser grade decides observation, bracing or surgical referral.

LOCK THESE IN

- Formation versus segmentation; corticated, bilateral, typical site means variant.
- Os odontoideum: smooth ossicle, large C1 arch, unstable, no upper cervical thrust.
- Block vertebra has a wasp waist; acquired fusion does not.
- DDH: head in the lower inner quadrant; acetabular index 30 degrees or less; Shenton unbroken.
- Cobb 10 degrees defines scoliosis; observe 10 to 25, brace 25 to 40 in growing children, surgery over 40 to 50.
- Middle column injury is unstable; Jefferson over 7 mm overhang is unstable.
- Salter Harris SALTR; type II most common; III and IV need anatomic reduction.
- Soft tissue: 7 at C2, 22 at C6; posterior fat pad and FBI sign mean fracture.

Unstable or urgent patterns

Injury	Hallmark	Action
Jefferson burst	C1 overhang over about 7 mm (Spence)	Immobilize; ED for CT
Type II dens	Line at the base, noncorticated	Immobilize; ED
Hangman fracture	Bilateral C2 pars lines, C2 slips forward	Immobilize; ED
Flexion teardrop	Large anteroinferior fragment, body into canal	Immobilize; ED
Bilateral facet dislocation	Anterolisthesis 50% or more	Immobilize; ED
Burst fracture	Posterior wall involved, widened pedicles	CT; ED
Chance fracture	Horizontal split, posterior elements to body	ED (abdominal injury)
Femoral neck stress (tension side)	Superolateral neck line	Stop weight bearing; same day
SCFE	Klein line misses the epiphysis	Non weight bearing; urgent
Delayed cervical instability	Translation over 3.5 mm, fanning	Collar, MRI, prompt surgical referral

Measurements and grades

Item	Value	Meaning
Prevertebral soft tissue	Adult 7 mm at C2, 22 mm at C6; child 7 and 14	Over: hemorrhage or edema
ADI	3 mm adult, 5 mm child	Over 10 mm: alar ligaments too
George line step	Over about 3 mm	Translation
Canal	Under about 12 mm; Torg under 0.8	Developmental stenosis
Flexion/extension	3.5 mm or 20% translation; 11° angulation	Lumbar about 4.5 mm (15%)
Acetabular index	30° or less at birth; 20 to 22° by 2	Over 30°: dysplasia
Scoliosis	Cobb 10° or more	Error 3 to 5°
Meyerding	I to 25%, II to 50, III to 75, IV to 100, V beyond	Quarters of the lower plate
Castellvi	I dysplastic TP (19 mm+), II joint, III fusion, IV mixed	a unilateral, b bilateral
Compression fracture	Height loss over about 50%	Suspect posterior ligament injury

Worked cases

WORKED CASE 1 · MEASURING A COBB ANGLE

A 12 year old premenarchal girl has a right thoracic curve. On the standing PA film the superior end plate of T5 tilts 14 degrees one way and the inferior end plate of T12 tilts 14 degrees the other way. The iliac apophyses show no ossification.

STEP 1 · CONFIRM THE END VERTEBRAE

T5 and T12 are the most tilted at each end of the curve.

STEP 2 · ADD THE TILTS

Opposite directions add: 14 + 14 = **28 degrees**.

STEP 3 · GRADE MATURITY

No apophyseal ossification is Risser 0; she is premenarchal, near peak growth.

STEP 4 · DECIDE

Over 25 degrees in a growing child: refer to an orthopedic scoliosis specialist for bracing assessment now. Night pain, a left thoracic curve or abnormal abdominal reflexes would add MRI.

WORKED CASE 2 · VARIANT OR FRACTURE

After a dance class, a 10 year old has a lucent line at the base of the fifth metatarsal running parallel to the shaft. She has mild diffuse soreness but no focal tenderness at the base.

STEP 1 · CHECK THE DIRECTION

Parallel to the shaft is the normal apophysis; a fracture line runs transverse.

STEP 2 · CHECK THE MARGINS

Smooth and corticated favors a variant.

STEP 3 · CHECK THE PATIENT

No focal bony tenderness at the site.

STEP 4 · CONCLUDE

Normal apophysis. If unsure, a comparison view of the other foot is the cheap, classic answer.

WORKED CASE 3 · DELAYED INSTABILITY AFTER WHIPLASH

A 42 year old was rear ended two weeks ago; the ED CT was normal. He has persistent neck pain and a normal neurologic exam. Flexion shows 4 mm anterior translation of C4 on C5 with widening of the C4 to C5 interspinous space.

STEP 1 · WHAT CT EXCLUDED

Fracture, but not ligament injury.

STEP 2 · MEASURE

4 mm exceeds 3.5 mm; interspinous fanning shows posterior ligament complex disruption.

STEP 3 · EXPLAIN THE DELAY

Spasm masked the instability early; that is why dynamic views are repeated at 7 to 14 days.

STEP 4 · ACT

No manipulation of the segment; collar; MRI; prompt spine surgery referral; report the measurement with a clear recommendation.

WORKED CASE 4 · A KNEE FILM AFTER A FALL

A 48 year old twisted her knee skiing. The cross table lateral shows a horizontal fat fluid level in the suprapatellar recess; no fracture line is visible.

STEP 1 · NAME THE SIGN

Fat over blood: lipohemarthrosis (FBI sign).

STEP 2 · EXPLAIN IT

The fat comes from marrow, so there is an intra-articular fracture.

STEP 3 · FIND THE LIKELY SITE

Most often the tibial plateau.

STEP 4 · ACT

CT and orthopedic referral; a vertical beam film would not have shown the level.

TRAPS PEOPLE FALL INTO

- **Calling os odontoideum a fresh fracture (or the reverse).** Smooth, corticated and a large C1 arch mean old; sharp and noncorticated mean fresh.
- **Trusting a neutral film for upper cervical stability.** Flexion and extension views are needed, after fracture is excluded.
- **Calling a butterfly vertebra a compression fracture.** Look at the AP: two triangles with reciprocal neighbors.
- **Relying on Ortolani and Barlow at 9 months.** They fade after about 3 months. Use abduction, Galeazzi and an AP pelvis.
- **Observing a 28 degree curve at Risser 0.** That is in the bracing range in a growing child: refer.
- **Ordering flexion and extension films right after trauma.** Exclude fracture first, never force motion, and repeat later if spasm masks motion.
- **Reassuring a runner with normal films.** Stress fractures hide for 2 to 3 weeks: MRI, and stop weight bearing for femoral neck pain.
- **Ignoring a posterior elbow fat pad.** It is never normal. Treat as an occult fracture.

Chapter 13 self-test · ten items

1. A lateral cervical film shows a smooth, corticated ossicle above a short dens and a large, rounded anterior arch of C1. What is it, and what comes before any upper cervical care?

A. Mach band artifact; repeat the APOM only
B. Ossiculum terminale; no further action needed
C. Type II dens fracture; immediate thrust to reduce
D. Os odontoideum; flexion and extension views first

D. Os odontoideum; flexion and extension views first Corticated margins and a hypertrophied C1 arch mean a longstanding lesion that is often unstable. Avoid upper cervical thrust and refer.

2. Two fused cervical bodies show a narrow waist at the absent disc and an oval foramen. What is it?

A. Surgical fusion
B. Congenital block vertebra
C. Ankylosing spondylitis
D. Fusion after discitis

B. Congenital block vertebra The wasp waist marks failure of segmentation; acquired fusions lack it.

3. On an AP lumbar film, the left L5 transverse process forms a joint with the sacral ala; the right is normal. Which Castellvi type?

A. Type IIIa
B. Type IV
C. Type IIa
D. Type IIb

C. Type IIa A unilateral pseudarthrosis is type II, a. It may cause Bertolotti syndrome.

4. A 9 month old breech born girl has limited left hip abduction and a positive Galeazzi; Ortolani and Barlow are negative. What fits?

A. AP pelvis and prompt pediatric orthopedic referral
B. Reassure, since Ortolani and Barlow are negative
C. Hip manipulation and recheck in a month
D. Hip ultrasound only, since the head is cartilage

A. AP pelvis and prompt pediatric orthopedic referral Ortolani and Barlow fade after about 3 months; at 9 months the head is ossified, so an AP pelvis is used.

5. A 13 year old premenarchal girl has a 32 degree right thoracic curve, Risser 1, normal neuro exam. Best next step?

A. Observe and recheck in a year
B. MRI of the whole neural axis
C. Refer for surgery now
D. Refer for bracing assessment

D. Refer for bracing assessment A 25 to 40 degree curve in a skeletally immature patient is in the bracing range.

6. After a dive, the open mouth view shows a combined C1 lateral mass overhang of 9 mm. What does this mean?

A. Congenital cleft of the C1 anterior arch
B. Stable isolated posterior arch fracture
C. Jefferson fracture with transverse ligament rupture
D. Normal pseudo Jefferson spread, as seen in many adults

C. Jefferson fracture with transverse ligament rupture Over about 7 mm (rule of Spence) implies transverse ligament rupture: unstable. Immobilize and send for CT.

7. A lap belted 25 year old has a horizontal fracture through the L1 spinous process, pedicles and body. What else must be evaluated urgently?

A. Bilateral calcaneal fractures
B. Intra-abdominal injury
C. Femoral neck stress fracture
D. Cervical facet dislocation

B. Intra-abdominal injury Chance fractures carry abdominal injury in up to half.

8. A Salter Harris fracture runs through the physis and exits the metaphysis. Which type is it?

A. Type II
B. Type III
C. Type I
D. Type IV

A. Type II Type II (A, above) is the most common, about 75 percent, with a Thurston Holland fragment.

9. After trauma, the retropharyngeal soft tissue at C2 measures 10 mm in an adult. What is next?

A. Flexion and extension views today
B. Cervical adjustment if neuro is normal
C. Immobilize and refer to the ED for CT
D. Repeat the lateral film in a month

C. Immobilize and refer to the ED for CT Over about 7 mm suggests hemorrhage from an occult fracture or ligament injury.

10. A 16 year old runner has groin pain with impact; films are normal, and you suspect a superolateral femoral neck stress fracture. What is correct?

A. Stop weight bearing and refer the same day
B. Hip mobilization and a running plan
C. Ice, NSAIDs and continue training
D. Reassure and recheck films in six weeks

A. Stop weight bearing and refer the same day Tension side femoral neck stress fractures can displace; MRI is the best early test.

CHAPTER 14

Image Interpretation III: Tumors, Miscellaneous Osteoarticular Disease and Soft Tissue

Read it in full: **Chapter 14 in the textbook**. Practice it: **the Study Guide 7 practice exam** and **the flashcards**.

What to know

Describe before you name. Age is the strongest filter: under 30, primary tumors and cysts; over 40, metastasis and myeloma first, whatever the lesion looks like. Multiple lytic lesions in an older adult are metastasis or myeloma until proven otherwise. Location matters: epiphysis (chondroblastoma, giant cell tumor, infection), metaphysis (most primaries), diaphysis (Ewing, fibrous dysplasia, myeloma, lymphoma); vertebral body versus posterior elements (osteoid osteoma, osteoblastoma, ABC). A geographic lesion with a sclerotic rim and narrow zone of transition grows slowly; **moth eaten** or **permeative** destruction is aggressive. Matrix: chondroid rings and arcs, cloudlike osteoid, ground glass fibrous. Periosteal reaction: solid is slow; onion skin, sunburst and Codman triangle are aggressive. FEGNOMASHIC is the young lytic lesion list.

Benign signatures: **hemangioma** (about 10 percent of adults; corduroy on film, polka dot on CT, bright on T1 and T2); **osteoid osteoma** (10 to 25; nidus under 1.5 cm in dense sclerosis; night pain relieved by NSAIDs; painful scoliosis concave toward the lesion; CT and ablation); bone island

(brush border, usually under 1 cm, cold on bone scan); **osteochondroma** (corticomedullary continuity, points away from the joint; worry if it grows or hurts after maturity or the cap exceeds about 1.5 to 2 cm); **enchondroma** (hand phalanges, rings and arcs, scalloping under two thirds of the cortex); simple bone cyst (fallen fragment); ABC (eccentric, blown out, fluid levels); nonossifying fibroma (leave alone); fibrous dysplasia (ground glass, rind sign, shepherd crook; McCune Albright); **giant cell tumor** (20 to 40, closed physis, eccentric, subarticular, no sclerotic rim; sacrum in the spine).

Malignant: **osteosarcoma** (10 to 25 and older adults with Paget or radiation; knee metaphysis; cloudlike osteoid, sunburst, Codman triangle; lungs are the main metastatic site). **Chondrosarcoma** (over 40; pelvis, proximal femur; painful chondroid lesion over about 5 cm, scalloping over two thirds of the cortex). **Ewing sarcoma** (5 to 20; diaphysis or flat bones; permeative, onion skin, large soft tissue mass, fever and high ESR that mimic osteomyelitis). Eosinophilic granuloma gives vertebra plana in a child. **Myeloma** (over about 50): punched out lesions without rims, raindrop skull, or diffuse osteopenia with compression fractures; pedicle preserved until late; bone scan often cold; M protein. Chordoma is the classic midline destructive sacral tumor.

Metastases are far more common than primary bone malignancies in adults and favor the axial red marrow through the Batson plexus. Primaries: breast, prostate, lung, kidney, thyroid. Lytic expansile ones come from kidney and thyroid; blastic from prostate. Plain film needs 30 to 50 percent loss; MRI is most sensitive in the spine. The **winking owl** (lost pedicle) is often the first sign; add a convex posterior wall, soft tissue mass and a preserved disc. The **ivory vertebra** is blastic metastasis, Hodgkin lymphoma or Paget disease (Paget enlarges the body). New weakness, a sensory level or sphincter change in a cancer patient is cord compression: same day MRI.

Sickle cell: **H shaped** (Lincoln log) vertebrae, infarcts, AVN, Salmonella osteomyelitis, hair on end skull (worse in thalassemia). **AVN** (ASEPTIC causes): stage I normal film with MRI double line, II mottled with round head, III **crescent sign** and flattening, IV osteoarthritis; MRI first in a high risk patient. Osteochondroses: Perthes (boys 4 to 8), Kienbock (lunate, negative ulnar variance), Freiberg (2nd metatarsal head), Kohler (navicular), Preiser (scaphoid), Osgood Schlatter, Scheuermann (three or more adjacent bodies wedged 5 degrees or more). Osteomyelitis

is invisible for about 10 to 14 days; sequestrum, involucrum and cloaca mark chronic infection; Brodie abscess is walled off. **Infection crosses the disc** (narrowing, eroded end plates on both sides); tumor spares it; degeneration keeps sharp sclerotic end plates and may show vacuum. Tuberculosis spreads under the ligaments, spares the disc early, makes a gibbus and a cold psoas abscess.

Metabolic disease: **osteoporosis** (normal labs; thin cortices; wedge and codfish vertebrae; DXA T ≤ −2.5); **osteomalacia** (low phosphate, high ALP, Looser zones at the medial femoral neck, pubic rami, scapula); **rickets** (wide, cupped, frayed metaphyses, rachitic rosary); **hyperparathyroidism** (radial middle phalanx subperiosteal resorption of the index and middle fingers, brown tumors, salt and pepper skull); **renal osteodystrophy** (rugger jersey spine, vascular calcification); **Paget** (over 55; enlarged bone, picture frame vertebra, blade of grass front, cotton wool skull, very high ALP with normal calcium; sarcoma under 1 percent); **acromegaly** (heel pad over about 23 mm in men, 21.5 mm in women; spade tufts; big sella).

Read every spinal film's soft tissues. A lung mass is over 3 cm; nodules over about 8 mm to 1 cm, spiculated, growing or in a smoker need CT; comparison films are the most useful step. **Pancoast** tumor: apical thickening over about 5 mm, rib destruction, C8 to T1 pain and Horner syndrome. **Pneumothorax**: a pleural line with no markings beyond (deep sulcus sign supine). **Effusion**: about 200 to 300 mL blunts the PA angle, 50 to 75 mL the lateral, 5 to 10 mL on decubitus. Cardiothoracic ratio over 0.5 on a PA film is cardiomegaly. **AAA** is 3 cm or more between calcified walls in front of L1 to L4; surveillance 3.0 to 5.4 cm, repair at 5.5 cm (about 5.0 in women) or fast growth, and pain or hypotension means emergency. About 80 to 90 percent of kidney stones are opaque; only 10 to 20 percent of gallstones are. Phleboliths have lucent centers. Free air under the diaphragm means perforation.

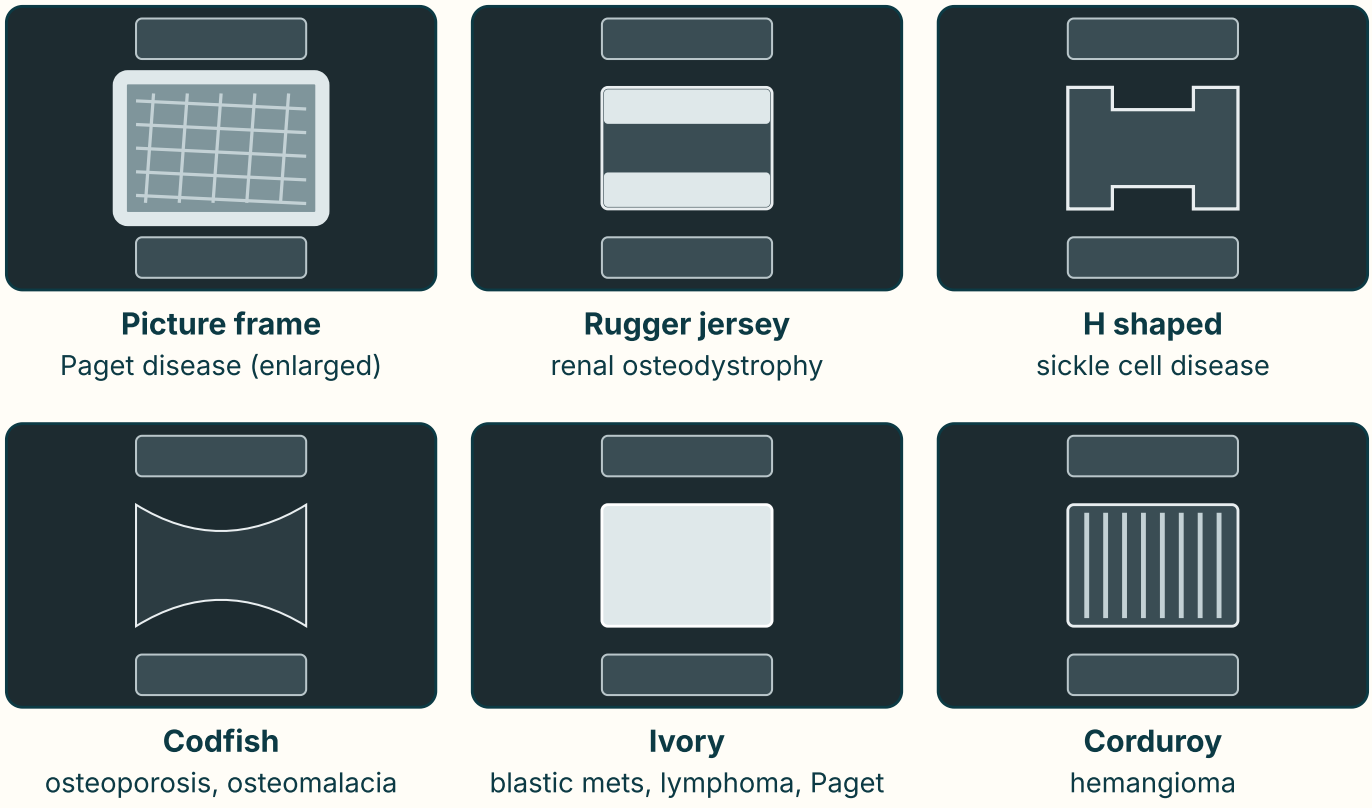

Schematic lateral views of one body between normal neighbors.

Six vertebral body patterns. Paget enlarges the body and thickens its frame; renal osteodystrophy stripes the end plates; sickle cell punches square central depressions; osteoporosis makes biconcave bodies; a dense normal sized body is ivory; coarse vertical striations are a hemangioma.

LOCK THESE IN

- Over 40, a destructive lesion is metastasis or myeloma until proven otherwise.
- Geographic with a sclerotic rim is slow; permeative, sunburst, onion skin and Codman triangle are aggressive.
- Winking owl means metastasis; preserved pedicle, punched out holes and a cold scan mean myeloma.
- Infection crosses the disc; tumor spares it; TB spreads under ligaments with a gibbus.
- Picture frame Paget, rugger jersey renal, H shaped sickle cell, codfish osteoporosis, corduroy hemangioma.
- Osteoid osteoma: small nidus, dense sclerosis, night pain relieved by NSAIDs.
- Giant cell tumor: 20 to 40, closed physis, eccentric, subarticular, no sclerotic rim.
- Calcified aortic walls 3 cm or more apart is an AAA; with pain it is an emergency.

Bone lesions by age, site and sign

Lesion	Age and site	Hallmark
Hemangioma	Adults; thoracolumbar body	Corduroy; polka dot on CT
Osteoid osteoma	10 to 25; femur, tibia, posterior elements	Nidus under 1.5 cm; NSAID relieved night pain
Osteochondroma	Under 20; knee, humerus	Corticomedullary continuity; points away from joint
Enchondroma	Any; hand phalanges	Rings and arcs; scalloping under 2/3 cortex
Simple bone cyst	Under 20; proximal humerus	Central, metaphyseal; fallen fragment
ABC	Under 20; posterior elements	Eccentric, blown out; fluid levels
Giant cell tumor	20 to 40; distal femur, sacrum	Eccentric subarticular, no rim, closed physis
Osteosarcoma	10 to 25; knee metaphysis	Cloudlike osteoid, sunburst, Codman
Ewing sarcoma	5 to 20; diaphysis, pelvis	Permeative, onion skin, large soft tissue mass
Chondrosarcoma	Over 40; pelvis, proximal femur	Painful chondroid lesion over about 5 cm
Myeloma	Over 50; skull, spine, ribs, pelvis	Punched out, no rim; cold bone scan
Metastasis	Over 40; axial skeleton	Winking owl; disc preserved

Metabolic disease and labs

Condition	Ca / PO_4 / ALP	Signature sign
Osteoporosis	Normal / normal / normal	Thin cortices, wedge and codfish
Osteomalacia, rickets	Low or normal / low / high	Looser zones; cupped frayed metaphyses
Primary hyperparathyroidism	High / low / normal or high	Radial middle phalanx resorption; brown tumors
Renal osteodystrophy	Low or normal / high / high	Rugger jersey; vascular calcification
Paget disease	Normal / normal / very high	Enlarged bone; picture frame; blade of grass
Myeloma	Often high / normal / usually normal	Punched out; cold scan
Acromegaly	Variable	Heel pad over 23 mm (men); spade tufts

Worked cases

WORKED CASE 1 · THE WINKING OWL

A 67 year old man with treated prostate cancer has six weeks of constant thoracolumbar pain, worse lying down at night, with no neurologic deficit. The AP lumbar film lacks the right pedicle of L2, and round dense foci sit in both iliac bones.

STEP 1 · AGE AND NUMBER

Over 40 with multiple lesions: metastasis or myeloma first.

STEP 2 · READ THE PEDICLE

A missing pedicle is the winking owl, classic for metastasis; myeloma spares the pedicle until late.

STEP 3 · READ THE DENSITY

Round blastic foci fit prostate metastasis; together the picture is mixed.

STEP 4 · RECOMMENDATIONS

No manipulation. MRI of the whole spine, PSA, CBC, calcium, ALP, prompt oncology referral within days.

STEP 5 · SAFETY NET

Leg weakness, saddle numbness or bladder or bowel change means emergency care the same day.

WORKED CASE 2 · DISC SPACE NARROWING: INFECTION OR DEGENERATION?

A 59 year old with diabetes has five weeks of worsening constant low back pain that wakes him, a recent urinary infection and a temperature of 37.9 °C. L3 to L4 is markedly narrowed with indistinct, eroded end plates on both sides.

STEP 1 · LOOK AT THE END PLATES

Eroded on both sides of the disc. Degeneration keeps them sharp and sclerotic, often with vacuum.

STEP 2 · LOOK AT THE DISC

Destroyed. Metastasis would usually spare it.

STEP 3 · ADD THE RISK

Diabetes, a recent infection, constant pain and low grade fever.

STEP 4 · ACT

Pyogenic spondylodiscitis: ESR, CRP, CBC, blood cultures, same day medical referral with MRI with contrast; emergency if neurologic signs or sepsis. No manipulation.

WORKED CASE 3 · PAGET OR PROSTATE?

A 72 year old says his hat no longer fits and has dull pelvic and low back ache. ALP is 640 U/L with normal calcium. L3 is enlarged with a thick dense cortical rim and coarse trabeculae; the right iliopectineal line is thickened.

STEP 1 · CHECK THE SIZE

The body is enlarged: Paget enlarges bone; metastasis does not.

STEP 2 · CHECK THE FRAME

A thick cortical rim is the picture frame vertebra.

STEP 3 · CHECK THE LABS

Very high ALP with normal calcium fits Paget.

STEP 4 · RECOMMEND

Paget disease; PSA is still reasonable; refer for medical management; ask about hearing and stenosis; low force technique; report any new focal pain or lytic change (sarcoma under 1 percent).

WORKED CASE 4 · AN AORTA ON A LUMBAR FILM

A 69 year old former smoker has mechanical low back pain. The lateral lumbar film shows calcified aortic walls in front of L3 that are 4.2 cm apart. He has no abdominal pain and normal vital signs.

STEP 1 · MEASURE

4.2 cm is 3 cm or more: probable AAA.

STEP 2 · PLACE IT IN THE TABLE

4.0 to 5.4 cm and asymptomatic: vascular referral and surveillance every 6 to 12 months.

STEP 3 · CONFIRM

Recommend ultrasound; plain film cannot exclude or size an aneurysm reliably.

STEP 4 · MODIFY AND WARN

No deep abdominal work or lumbar rotary thrust; new back, flank or abdominal pain means call emergency services.

TRAPS PEOPLE FALL INTO

- **Ranking a primary tumor first in a 65 year old.** Over 40, metastasis and myeloma head every list.
- **Trusting a normal bone scan in suspected myeloma.** It is often cold. Use electrophoresis and a survey, low dose CT or MRI.
- **Calling a narrowed disc with eroded end plates degeneration.** Infection erodes both end plates; degeneration keeps them sharp.
- **Calling every dense vertebra a metastasis.** An enlarged body with a thick frame is Paget.
- **Missing a Pancoast tumor on a cervicothoracic film.** Compare the apices every time.
- **Reading a skin fold as a pneumothorax.** A skin fold extends beyond the chest and has lung markings beyond it.
- **Calling a pelvic round density a ureteral stone.** Phleboliths are round with lucent centers and lie low and lateral.
- **Massaging a new hard lump in a bruised thigh.** Myositis ossificans: do not biopsy early or massage aggressively.

Chapter 14 self-test · ten items

1. A 19 year old has tibial night pain relieved by aspirin; the film shows a 7 mm lucency in dense cortical sclerosis. What best confirms it?

A. Plain films repeated in a year
B. A technetium bone scan alone
C. Serum protein electrophoresis
D. Thin section CT to show the nidus

D. Thin section CT to show the nidus This is osteoid osteoma; CT shows the nidus best and radiofrequency ablation is usual treatment.

2. A 28 year old has an eccentric lytic distal femoral lesion reaching the subchondral bone, with a narrow zone of transition, no sclerotic rim and closed physes. What is it?

A. Giant cell tumor
B. Simple bone cyst
C. Nonossifying fibroma
D. Chondroblastoma

A. Giant cell tumor Age 20 to 40, closed physis, eccentric and subarticular without a rim is giant cell tumor.

3. A metaphyseal bony projection points away from the knee, with cortex and medulla continuous with the femur. When does it need workup?

A. Only if the patient is under ten years old
B. Whenever it is seen on any radiograph
C. New pain or growth after skeletal maturity
D. Only if it points toward the joint

C. New pain or growth after skeletal maturity Osteochondroma growth or pain after maturity, or a cap over about 1.5 to 2 cm, raises concern for chondrosarcoma.

4. An 11 year old has thigh pain, fever and a high ESR with a permeative diaphyseal lesion, onion skin reaction and a large soft tissue mass. What leads the differential?

A. Paget disease and gout
B. Ewing sarcoma and osteomyelitis
C. Enchondroma and simple cyst
D. Osteosarcoma and bone island

B. Ewing sarcoma and osteomyelitis Both cause permeative destruction and onion skin; the large soft tissue mass favors Ewing.

5. A 67 year old has anemia, hypercalcemia, renal impairment, punched out skull lesions and a normal bone scan. What is the key lab?

A. Serum protein electrophoresis with immunofixation
B. HLA-B27 typing
C. Prostate specific antigen with a free PSA ratio only
D. Serum uric acid level

A. Serum protein electrophoresis with immunofixation Multiple myeloma shows an M protein; the bone scan is often cold.

6. A 24 year old with sickle cell disease has square central depressions of the vertebral end plates. What causes them?

A. Osteoporotic end plate fractures
B. Central end plate infarction
C. Renal osteodystrophy
D. Paget disease of bone

B. Central end plate infarction H shaped vertebrae form because the central end plate is supplied by end arteries.

7. A 45 year old with malabsorption has bilateral lucent bands perpendicular to the cortex at the medial femoral necks and pubic rami. Which labs fit?

A. High calcium and low PTH
B. Very high ALP with high phosphate
C. Normal calcium, phosphate and alkaline phosphatase
D. Low phosphate and high alkaline phosphatase

D. Low phosphate and high alkaline phosphatase Looser zones mean osteomalacia: low phosphate, low or normal calcium, high ALP, low vitamin D, raised PTH.

8. Which hand finding is pathognomonic for hyperparathyroidism?

A. Hook osteophytes at the 2nd and 3rd MCP heads
B. Pencil in cup deformity at the DIP joints
C. Radial subperiosteal resorption of middle phalanges
D. Spade shaped tufts of the distal phalanges

C. Radial subperiosteal resorption of middle phalanges Subperiosteal resorption on the radial side of the index and middle middle phalanges is the hallmark.

9. A 73 year old smoker has new deep back pain, BP 102/64, a tender pulsatile mass, and calcified aortic walls 6 cm apart on film. What is next?

A. Gentle lumbar mobilization today
B. Call emergency services now
C. Routine vascular surgery letter
D. Arrange an outpatient ultrasound

B. Call emergency services now A large AAA with pain, tenderness and relative hypotension suggests expansion or rupture.

10. Which feature favors Paget disease over blastic prostate metastasis in a dense vertebra?

A. Several discrete round blastic foci
B. A normal sized, uniformly dense ivory body
C. Enlarged body with a thick cortical frame
D. A raised PSA with normal ALP

C. Enlarged body with a thick cortical frame Paget enlarges bone with a picture frame and coarse trabeculae; metastasis does not enlarge it.

ONE PAGE

Cram sheet

Everything from chapters 13 and 14 in one place. Cover the right column and see if you can rebuild each row.

Numbers to know

Item	Value	Note
Ponticulus posticus	About 10 to 15% of people	Note it in the report
Basilar impression	Dens over about 7 mm above McGregor	With occipitalization, Paget, RA
Transitional segment	About 10 to 15%	Castellvi I to IV
Cervical rib	About 0.5 to 1%	From C7
Acetabular index	30° or less at birth; 20 to 22° by 2	Over 30°: DDH
Scoliosis	Cobb 10°+; error 3 to 5°	Observe 10 to 25; brace 25 to 40; surgery 40 to 50+
Progression	20 to 29° at Risser 0 to 1: about two thirds	Risser 2 to 4: about a quarter
Jefferson	Overhang over about 7 mm	Rule of Spence
Facet dislocation	Unilateral about 25%; bilateral 50%+	Bow tie sign
Spondylolysis	About 5 to 6%; L5 in 85 to 90%	Meyerding by quarters
Salter Harris II	About 75% of physeal fractures	Thurston Holland fragment
Prevertebral	7 mm C2; 22 mm C6 (child 14)	Flexion/extension 3.5 mm, 11°
Hemangioma	About 10% of adults	Corduroy
Osteoid osteoma nidus	Under 1.5 cm	Osteoblastoma over 1.5 to 2 cm
Osteochondroma cap	Over about 1.5 to 2 cm is concerning	Malignant change under 1% (solitary)
Lytic visibility	30 to 50% bone loss	Osteomyelitis visible at 10 to 14 days
Heel pad	Over about 23 mm men, 21.5 mm women	Acromegaly

Item	Value	Note
Effusion	200 to 300 mL PA; 50 to 75 mL lateral; 5 to 10 mL decubitus	CTR over 0.5 on PA
AAA	3 cm; repair 5.5 cm (about 5.0 women)	Kidney stones 80 to 90% opaque; gallstones 10 to 20%

Key terms and comparisons

Pair	How to tell them apart
Os odontoideum vs type II dens fracture	Smooth, corticated, big C1 arch versus thin, irregular, noncorticated, normal arch.
Block vertebra vs acquired fusion	Wasp waist and oval foramen versus no waist.
Variant vs fracture	Corticated, bilateral, textbook site versus sharp, focal, tender.
Osteoporotic vs pathologic fracture	Intact wall and pedicles below T6 versus lost pedicle, convex wall, above T5.
Metastasis vs myeloma	Lost pedicle, hot scan versus preserved pedicle, punched out, cold scan.
Infection vs tumor vs degeneration	Disc destroyed with eroded plates; disc spared; sharp sclerotic plates with vacuum.
Paget vs blastic metastasis	Enlarged body with frame versus normal size, discrete foci, PSA.
Kidney stone vs phlebolith	Along the ureter versus round, lucent center, low and lateral.

Dr. Garg Learning · CC BY-SA 4.0
An independent study aid. Not affiliated with or endorsed by the National Board of Chiropractic Examiners.