Study Guide 6

This guide pairs case management with the first image interpretation chapter. Management items stop at a decision point and ask for the next best step; interpretation items show a film and ask you to name a pattern and write the right recommendation. Both reward a fixed order of thinking. Work one chapter at a time, study the diagram, copy the tables, cover the steps of each worked case, then do the self-tests and the cram sheet.

WHAT THIS GUIDE COVERS

- Chapter 11 · plan contents, SMART goals, phases of care, trials of care, prognosis, STarT Back and the prediction rule, MCIDs, re-examination, plateaus and MMI, referral destination and speed, referral letters, co-management, SOAP, PART, PARQ consent, and coding.
- Chapter 12 · osteoarthritis by site, spinal degeneration, DISH, rheumatoid arthritis and the ADI, JIA, sacroiliitis grading, ankylosing spondylitis, psoriatic, reactive and enteropathic arthritis, gout, CPPD, HADD, hemochromatosis, neuropathic joints, ABCDS and the report.

CHAPTER 11

Case Management

Read it in full: **Chapter 11 in the textbook**. Practice it: **the Study Guide 6 practice exam** and **the flashcards**.

What to know

Case management is the second heaviest Part III area. It asks: what happens now? A **treatment plan** contains the working diagnosis (primary and secondary), baseline measures (pain, a validated functional questionnaire, objective findings, the patient's functional limits), short term (2 to 4 weeks) and long term goals, interventions with precautions, frequency and duration, the re-examination date and measures, discharge criteria and referral triggers, and home care. Goals are **SMART**: specific, measurable, achievable, relevant and time bound. Functional goals beat pain goals. The PSFS has the patient rate 3 to 5 chosen activities from 0 to 10.

Phases overlap: **relief** (2 to 3 visits a week for 1 to 2 weeks), **corrective and rehabilitative** (1 to 2 a week for 2 to 6 weeks), **self-management and discharge** (tapering to every 2 to 4 weeks), **supportive care** (for a patient at MMI with documented regression on withdrawal) and **wellness or maintenance** (elective, not medically necessary). A trial of care is about 2 weeks; after two trials (about 4 weeks) without meaningful response, the plan must change. Most acute low back episodes largely resolve within 6 to 8 weeks; passive care beyond about 12 weeks without functional gains is hard to justify. Prepaid long packages for acute conditions are viewed critically.

Prognosis starts with natural history: about 60 to 70 percent of acute low back pain improves substantially within 6 weeks, most within 12, and recurrence within a year is about half. About half of whiplash patients still have symptoms at a year. Worse prognosis comes with high baseline pain and disability, pain below the knee, deficit, multiple prior episodes, duration over 3 months, delay over about a week, structural or medical disease and yellow flags. **STarT Back** (nine items): low risk gets advice and minimal treatment; medium gets physical treatment; high gets physical treatment plus psychologically informed care. The lumbar manipulation **clinical prediction rule** has five items (symptoms under 16 days, none below the knee, FABQ work under 19, a hypomobile lumbar segment, a hip with over 35 degrees of internal rotation); four or more gave an LR+ of about 24 in the original study.

Judge change against the **MCID**: NPRS about 2 points or 30 percent; VAS about 15 to 20 mm; Oswestry about 10 percentage points or 30 percent; Roland Morris about 3 to 5; NDI about 5 to 7 points (of 50); PSFS about 2; Headache Disability Index about 16. An FABQ work score over 34 predicts poor return to work. Use one pain measure and one region specific functional measure at baseline and each re-exam. Reassess briefly every visit; re-examine formally every 2 to 4 weeks or about 12 visits or 30 days, and with any new complaint, worsening or new deficit.

A **plateau** forces five questions: is the diagnosis right, is the treatment right, is the patient doing the plan, are yellow flags blocking recovery, does the patient need something else? Relief that lasts only hours after each visit means passive care is not addressing the driver. **MMI** is when further significant recovery is not expected; it triggers impairment rating (AMA Guides). Maintenance care for a Medicare patient needs an Advance Beneficiary Notice. Discharge for

noncompliance needs reasonable notice, help finding care and emergency coverage, or it is abandonment.

Every referral has a destination and a speed. **Emergency**: cauda equina, dissection or stroke, symptomatic AAA, rapidly progressive myelopathy. **Urgent**: progressive foot drop or quadriceps weakness (spine surgeon with MRI), suspected infection, giant cell arteritis (same day), DVT (same day), metastasis with a deficit. **Prompt**: spondyloarthritis, RA, incidental aneurysm. **Routine**: psychology for fear avoidance, pain management after failed care. Urgent referrals are telephoned and confirmed. A referral letter asks a specific question and gives findings with numbers. A declined referral is documented as **informed refusal**. Chiropractors do not tell patients to stop prescribed drugs.

Records: "if it was not documented, it was not done," and the note must match the bill. **SOAP** notes are timely, individualized, measurable and consistent; late entries are labeled; corrections use a single line with date, initials and reason; never alter after a claim (spoliation); retain at least about 7 years for adults (longer for minors). Medicare subluxation by exam needs **PART** (two of four, one being asymmetry or range of motion), names the level, and covers only spinal manipulation. Consent uses **PARQ** (procedure, alternatives, risks, questions); the reasonable patient standard is stricter; renew consent when the diagnosis, technique, region or risk changes; a minor's parent or guardian consents.

Codes: ICD-10-CM gives the reason; CPT gives the service. **98940** is CMT of 1 to 2 spinal regions, **98941** 3 to 4, **98942** 5; **98943** is extraspinal. Modifier 25 marks a separately identifiable E/M (initial exam, formal re-exam, new complaint), not the routine pre-manipulation check. Modifier 59 (or XS) marks a distinct procedure in a separate region. Timed therapy codes (97110, 97112, 97140, 97530, 97035) are 15 minute units. Medicare: AT for active care, GA when an ABN is on file; M99.01 to M99.05 list the subluxation first. Sprain codes use a seventh character: A active treatment, D subsequent, S sequela. Solve management stems in order: red flags, direction of change against the MCID, does the diagnosis still fit, then the single most important action.

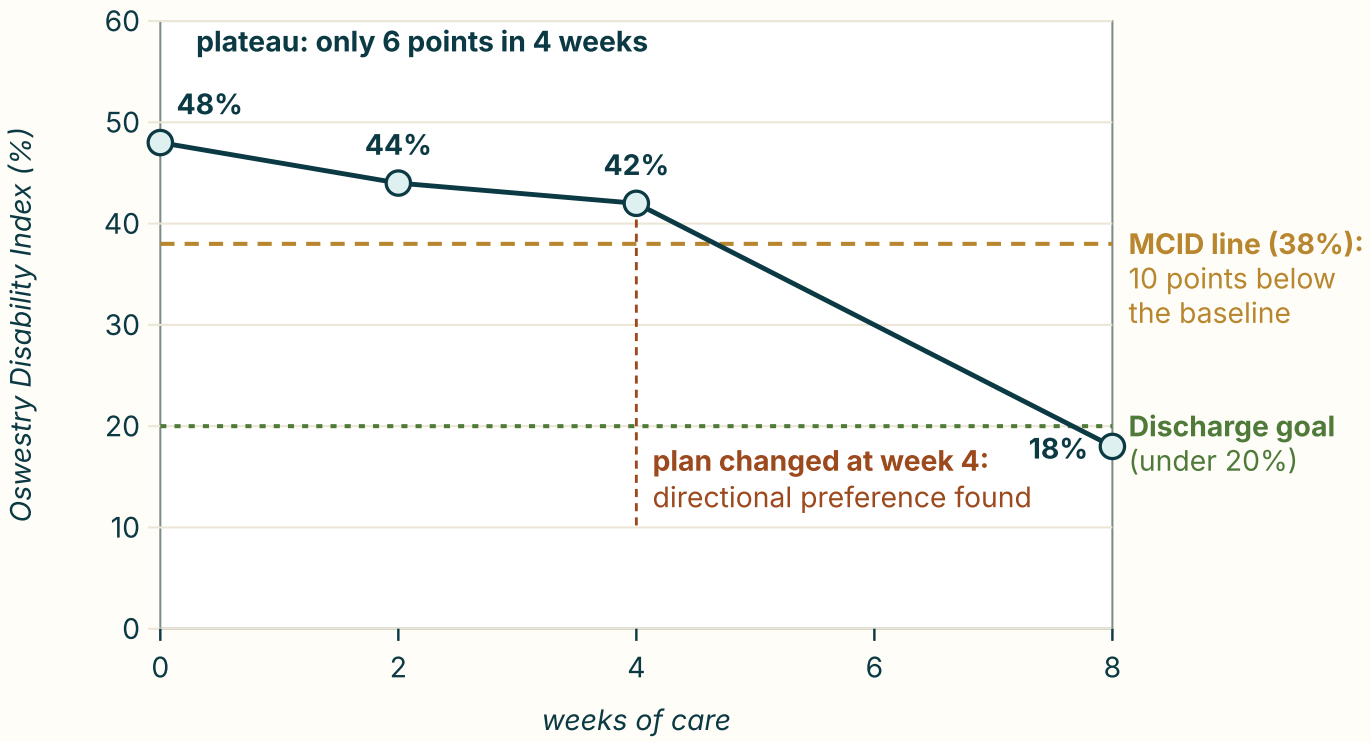

Judge change against the MCID. After two trials the Oswestry fell only 6 points, short of the 10 point MCID: a plateau. A new finding justified a new plan, and the score then passed both the MCID and the discharge goal.

LOCK THESE IN

- A plan names diagnosis, baseline, SMART goals, frequency, duration, re-exam date and discharge criteria.
- Trial of care about 2 weeks; no meaningful change after two trials means change, test or refer.
- MCID: NPRS about 2 points (30%); Oswestry about 10 points; NDI about 5 to 7.
- STarT Back high risk: physical care plus psychologically informed care.
- Re-examine every 2 to 4 weeks or about 12 visits, and with anything new.
- Referral = destination plus speed; urgent ones are telephoned and confirmed.
- PART: two of four, one being asymmetry or ROM; PARQ for consent; renew when risk changes.
- 98940 is 1 to 2 regions, 98941 is 3 to 4, 98942 is 5, 98943 extraspinal; modifier 25 for a separate E/M.

Outcome measures and MCIDs

Measure	Scoring	Commonly taught MCID
NPRS	0 to 10	About 2 points or 30%
VAS	0 to 100 mm	About 15 to 20 mm
Oswestry (ODI)	0 to 100%	About 10 points or 30%
Roland Morris	0 to 24	About 3 to 5 points
Neck Disability Index	0 to 50 (or 0 to 100%)	About 5 to 7 points (10 to 14%)
PSFS	0 to 10 average	About 2 points
Headache Disability Index	0 to 100	About 16 points
FABQ work	0 to 42	Over 34 predicts poor return to work

Referral speed and destination

Presentation	Destination	Urgency
Saddle anesthesia, retention, bilateral leg signs	Emergency department	Emergency
Neck pain with 5 Ds and 3 Ns	Emergency services	Emergency
Pulsatile mass with pain or hypotension	Emergency services	Emergency
Progressive foot drop	Spine surgeon with MRI	Urgent
Fever, IV drug use, back pain	ED or physician same day	Urgent to emergency
Over 50, temporal headache, jaw claudication	Physician same day	Urgent
Calf swelling after surgery	Physician or ED for duplex	Urgent, same day
Inflammatory back pain, uveitis	Rheumatologist	Prompt
Incidental 4.5 cm aortic calcification, no pain	Primary physician for ultrasound	Prompt
High fear avoidance, depression	Psychologist (CBT) with ongoing care	Routine

Worked cases

WORKED CASE 1 · JUDGING A RE-EXAMINATION AGAINST THE MCID

A 46 year old has had twice weekly care for 4 weeks. NPRS went from 7 to 5 and ODI from 44% to 39%. Is this meaningful improvement?

STEP 1 · NPRS CHANGE

7 − 5 = 2 points, which is 2 ÷ 7 = 29%. That sits right at the MCID (about 2 points or 30%): borderline.

STEP 2 · ODI CHANGE

44 − 39 = 5 points, which is 5 ÷ 44 = 11%. Well short of about 10 points or 30%.

STEP 3 · WEIGH FUNCTION

The function score is the more persuasive measure, and it has not moved meaningfully: a plateau after two trials.

STEP 4 · ACT

Recheck the diagnosis, the treatment, adherence and yellow flags; then change the plan, test or refer. Do not simply continue or increase frequency.

WORKED CASE 2 · THE CLINICAL PREDICTION RULE

A 37 year old has central low back pain for 9 days after moving furniture, no leg pain, FABQ work 12, hypomobile L4 and L5, and right hip internal rotation of 40 degrees. STarT Back is low risk.

STEP 1 · COUNT THE FIVE ITEMS

Under 16 days, yes. Nothing below the knee, yes. FABQ work under 19, yes. A hypomobile lumbar segment, yes. A hip over 35 degrees IR, yes. Five of five.

STEP 2 · READ THE RULE

Four or more predicts rapid response to lumbopelvic manipulation (LR+ about 24 in the original study).

STEP 3 · SET THE PLAN

Manipulation twice a week for two weeks, stay active, simple home exercises, re-exam at 2 to 4 weeks with NPRS and ODI.

STEP 4 · SET THE GOALS

NPRS 2 or less and ODI under 15% within four weeks. No imaging, no bed rest, no long prepaid package.

WORKED CASE 3 · A NEW DEFICIT MID CARE

In week 3 of care for an L5 radiculopathy, a 53 year old reports her foot has been "slapping" since yesterday. Dorsiflexion and great toe extension are 3 of 5 (previously 5 of 5). Saddle sensation, bladder and bowel are normal.

STEP 1 · RED FLAGS

A new, significant motor deficit is progressive radiculopathy. No cauda equina signs.

STEP 2 · DESTINATION AND SPEED

MRI and a spine surgeon, urgent: telephone the same day and confirm she is seen within days.

STEP 3 · STOP THE RIGHT THING

Stop lumbar manipulation.

STEP 4 · DOCUMENT AND SET THE SWITCH

Record the deficit, time and referral. Saddle anesthesia, retention or bilateral signs would make it an emergency department referral now.

TRAPS PEOPLE FALL INTO

- **Continuing or increasing care after a plateau.** No meaningful change after two trials means reassess, change, test or refer.
- **Calling a 5 point ODI gain improvement.** The MCID is about 10 points.
- **Right specialist, wrong speed.** Suspected cauda equina to a routine neurosurgery appointment is still wrong.
- **Relying on the intake consent form forever.** Renew consent when the diagnosis, technique, region or risk changes.
- **Cloned notes.** Each note needs visit specific numbers and an assessment of progress.
- **Modifier 25 on every visit.** Only for a significant, separately identifiable E/M such as an exam or new complaint.
- **Selling a long prepaid package for acute pain.** Frequency should follow the clinical picture.
- **Advising a patient to stop a prescribed drug.** Discuss effects, but medication changes go through the prescriber.

Chapter 11 self-test · ten items

1. After four weeks of twice weekly care, a patient's ODI went from 42% to 37% and she feels "a little better." What is the best next step?

A. Reassess the diagnosis, adherence and yellow flags, then change course
B. Continue the same plan for another four weeks of twice weekly care
C. Increase the visit frequency to three times per week
D. Add ultrasound and electrical stimulation each visit

A. Reassess the diagnosis, adherence and yellow flags, then change course A 5 point change is below the ODI MCID of about 10 points: a plateau.

2. Which set is the lumbar manipulation clinical prediction rule?

A. Under 16 days, pain below knee, FABQ under 19, normal mobility, hip ER over 35°
B. Under 6 weeks, leg pain below knee, FABQ over 34, hypermobility, hip IR under 35°
C. Under 16 days, no pain below knee, FABQ work under 19, hypomobility, hip IR over 35°
D. Over 3 months, no leg pain, FABQ under 19, hypomobility, hip flexion over 90°

C. Under 16 days, no pain below knee, FABQ work under 19, hypomobility, hip IR over 35° Four or more of the five criteria predict a rapid response to lumbopelvic manipulation.

3. A STarT Back screen puts a patient with three weeks of low back pain in the high risk group. How should the plan change?

A. Give advice only and discharge the patient at this visit
B. Advise bed rest until the pain score falls
C. Stop care and order an MRI of the lumbar spine
D. Add psychologically informed care to physical treatment

D. Add psychologically informed care to physical treatment High risk patients need physical treatment plus education, graded activity and attention to fear and catastrophizing.

4. Which finding at re-examination most clearly calls for urgent referral rather than a change of technique?

A. NPRS unchanged at 5 after two weeks
B. Dorsiflexion now 3 of 5, previously 5 of 5
C. Soreness for a day after the last visit
D. ODI down 6 points after four weeks

B. Dorsiflexion now 3 of 5, previously 5 of 5 A new, progressive motor deficit is progressive radiculopathy: stop manipulation of the region, MRI and urgent surgical referral.

5. A 69 year old smoker has steady back and flank pain unchanged by movement, BP 102/64, pulse 106 and a pulsatile mass above the umbilicus. What is the next step?

A. Call emergency medical services now
B. Order an outpatient abdominal ultrasound
C. Send a letter to vascular surgery
D. Gentle side posture and recheck tomorrow

A. Call emergency medical services now A pulsatile mass with hypotension and tachycardia is a leaking AAA until proven otherwise.

6. Which documentation satisfies Medicare PART for subluxation by examination?

A. Tenderness and a positive orthopedic test
B. Tenderness and tissue tone change at L4
C. Tenderness and range of motion abnormality at L4
D. Tissue tone change and paraspinal muscle spasm at L4

C. Tenderness and range of motion abnormality at L4 Two of the four PART findings are required, and one must be asymmetry or range of motion abnormality.

7. A patient's bone density scan shows osteopenia six weeks into thoracic care that began with a signed consent. What should you do?

A. Rely on the original signed consent form
B. Continue the same prone thoracic thrusts without any comment
C. Discharge the patient from all care today
D. Revisit consent, offer alternatives and modify technique

D. Revisit consent, offer alternatives and modify technique A new risk factor changes the material risk, so consent must be renewed and technique modified.

8. Which CPT code describes chiropractic manipulation of the cervical, thoracic and lumbar regions on one visit?

A. 98943
B. 98941
C. 98940
D. 98942

B. 98941 98941 covers 3 to 4 spinal regions. 98940 is 1 to 2, 98942 is 5, and 98943 is extraspinal.

9. A patient at MMI repeatedly loses ground when care stops, and this is documented. Which care is justified?

A. Immediate discharge with no follow up
B. Indefinite care at the original twice weekly frequency
C. Maintenance care billed as active care
D. Supportive care at the lowest effective frequency

D. Supportive care at the lowest effective frequency Supportive care needs documented regression on withdrawal; maintenance care is elective and not medically necessary.

10. A patient declines your recommended referral to a spine surgeon for progressive weakness. What is correct?

A. Explain the risks, offer alternatives and document informed refusal
B. Continue lumbar manipulation as before, as if nothing had changed
C. Discharge the patient at once without notice
D. Make the referral without telling the patient

A. Explain the risks, offer alternatives and document informed refusal Document an informed refusal, keep encouraging evaluation and do not carry on unchanged.

Image Interpretation I: Arthritic Disorders

Read it in full: **Chapter 12 in the textbook**. Practice it: **the Study Guide 6 practice exam** and **the flashcards**.

What to know

Arthritis is named from a pattern, not a single sign. **Osteoarthritis** is productive: cartilage fails where load is greatest, so the joint narrows **nonuniformly**, the bone beneath becomes sclerotic, fluid forced into the bone forms subchondral cysts (geodes), and the margins grow osteophytes. Density stays normal and there are no erosions. Knee: medial compartment first (varus). Hip: superolateral migration with medial cortical buttressing. Hand: DIP (Heberden), PIP (Bouchard) and first CMC, MCPs spared; erosive OA gives central erosions and a gull wing outline. Glenohumeral, radiocarpal, MCP or isolated patellofemoral disease suggests CPPD. Kellgren and Lawrence grades 0 to 4.

Spine vocabulary: **intervertebral osteochondrosis** is nucleus and endplate degeneration (narrowing, vacuum phenomenon, endplate sclerosis, Schmorl nodes; Modic 1 edema, 2 fatty, 3 sclerotic). A vacuum disc essentially excludes infection. **Spondylosis deformans** is outer annulus degeneration with claw osteophytes that start a few millimeters from the endplate. Traction spurs (2 to 3 mm from the margin) suggest instability. Facet and uncovertebral arthrosis narrow the foramina (obliques). Degenerative spondylolisthesis is L4 on L5 with an intact pars and narrows the canal. **DISH** (Resnick): flowing anterolateral ossification over at least four contiguous bodies, preserved discs, no facet ankylosis or SI erosion; thoracic, right sided, men over 50 with obesity and diabetes; complications are dysphagia, OPLL, fracture after minor trauma and heterotopic bone after hip replacement.

Rheumatoid arthritis is destructive: bilateral, symmetric, proximal (MCP, especially 2nd and 3rd; PIP; wrist with ulnar styloid erosion; MTP, the 5th often first), DIP sparing; fusiform soft tissue swelling first; periarticular osteopenia; **uniform** narrowing; marginal erosions at the bare areas with no sclerotic rim and no new bone; late ulnar deviation, swan neck and boutonniere. The hip migrates axially with protrusio. In the cervical spine, the ADI (posterior surface of the anterior arch to the dens) must be 3 mm or less in adults (5 mm in children), and instability may show only in flexion. ADI over about 9 to 10 mm or a posterior atlantodental interval of 14 mm or less means

high cord risk. Cranial settling is judged with McGregor's line (dens tip no more than about 4.5 mm above it).

JIA (onset before 16, at least six weeks) shows growth disturbance: ballooned epiphyses, accelerated maturation, limb length difference, a widened intercondylar notch and squared patella (hemophilia is the main differential), periostitis, brachydactyly, late erosions and ankylosis, and in the neck C2 to C3 apophyseal ankylosis with small vertebral bodies. Oligoarticular JIA carries a high risk of silent uveitis.

The **spondyloarthropathies** attack the enthesis, so they erode and then make bone. Sacroiliitis starts on the iliac side: blurring, erosions with pseudowidening, sclerosis, then ankylosis. New York grades 0 to 4; AS needs bilateral grade 2 or more, or unilateral grade 3 or 4. Bilateral symmetric: AS or enteropathic. Bilateral asymmetric: psoriatic or reactive. Unilateral: infection until proven otherwise. AS (over 90 percent of white patients HLA-B27): Romanus shiny corners, squaring, thin **marginal syndesmophytes**, bamboo spine, trolley track and dagger signs, Andersson lesion, and unstable carrot stick fractures after minor trauma. Psoriatic: DIP and ray pattern, normal density, pencil in cup, mouse ears, ivory phalanx, bulky **nonmarginal syndesmophytes** that skip levels. Reactive: the same moved to the feet and heels.

Gout (urate saturates at about 6.8 mg/dL): years of normal films, then asymmetric lower limb disease, tophi, punched out erosions with sclerotic rims and an **overhanging edge** (Martel sign), and preserved joint space and density until late. **CPPD**: chondrocalcinosis (menisci, TFCC, symphysis) and OA in unusual joints with large cysts, SLAC wrist and crowned dens; under 55, check calcium, PTH, magnesium and iron. **HADD**: cloudlike tendon calcification, supraspinatus most often; longus colli calcific tendinitis mimics a retropharyngeal abscess. **Hemochromatosis**: hook osteophytes on the radial 2nd and 3rd MCP heads; transferrin saturation over about 45 percent. **Neuropathic joint**: the six Ds; midfoot means diabetes, shoulder means syringomyelia, knee means tabes.

Read every arthritic film with **ABCDS**: alignment, bone density, cartilage space, distribution, soft tissues, then erosions and new bone. Distribution and density eliminate most choices. The report has findings (described, not diagnosed), an impression with a short differential and any safety finding stated plainly, and recommendations: laboratory correlation (RF, anti-CCP, ESR, CRP,

HLA-B27, urate, iron studies), further views or MRI, referral, and precautions such as flexion and extension views before cervical care in RA, or no thrust through fused segments.

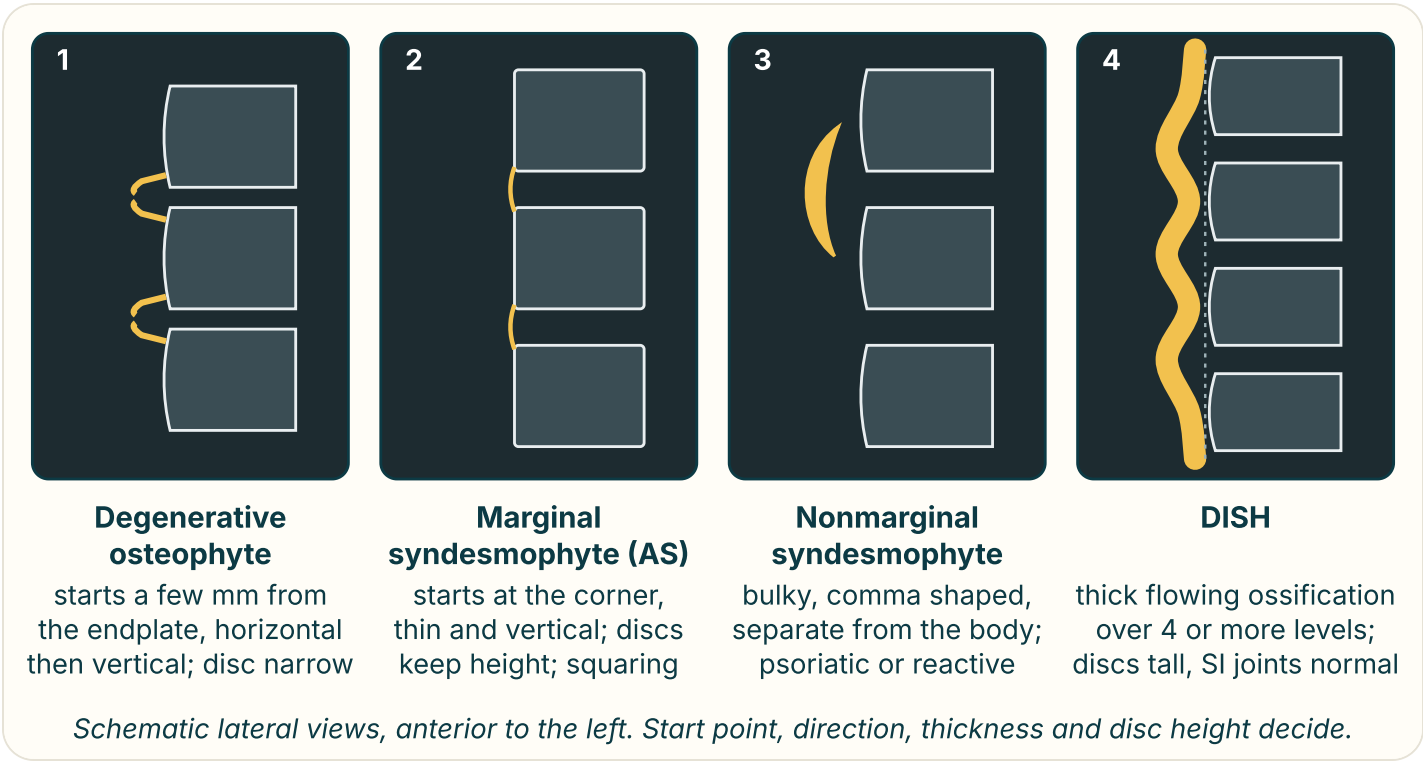

Four kinds of spinal new bone. Read where the new bone starts, which way it grows, how thick it is and what the disc does. Thin corner bridges are AS; bulky separate commas are psoriatic or reactive; thick flowing bone over tall discs is DISH.

LOCK THESE IN

- OA: nonuniform narrowing, sclerosis, osteophytes, cysts, normal density, no erosions.
- RA: symmetric, proximal, osteopenia, uniform narrowing, marginal erosions, DIP spared.
- Adult ADI over 3 mm (often only in flexion) forbids upper cervical manipulation.
- Osteophyte starts mm from the endplate; marginal syndesmophyte starts at the corner; DISH flows over 4+ levels with tall discs.
- Sacroiliitis: bilateral symmetric AS or enteropathic; asymmetric psoriatic or reactive; unilateral infection.
- Gout: punched out erosion, overhanging edge, preserved space and density.
- OA in an unusual joint means CPPD; hook osteophytes at 2nd and 3rd MCP mean hemochromatosis.
- A fused spine (AS, DISH) with new pain after minor trauma has a fracture until CT says otherwise.

Arthritis patterns on film

Disease	Distribution	Density	Joint space	Erosions and new bone
Osteoarthritis	Weight bearing, DIP, PIP, 1st CMC; asymmetric	Normal	Nonuniform loss	None (central in erosive OA); osteophytes
Rheumatoid	Bilateral MCP, PIP, wrist, MTP, C1 to C2	Periarticular osteopenia	Uniform loss	Marginal, no rim; no new bone
Ankylosing spondylitis	SI, spine, hips, shoulders; symmetric	Normal early, osteoporotic late	Loss then ankylosis	SI and corners; marginal syndesmophytes
Psoriatic	DIP, ray; SI asymmetric	Normal	Loss or widening	Pencil in cup; fluffy periostitis; nonmarginal
Reactive	Feet, ankles, knees, heels	Normal or early loss	Loss	Marginal; calcaneal periostitis
Gout	1st MTP, foot, knee, olecranon	Normal	Preserved until late	Punched out, sclerotic rim, overhanging edge
CPPD	Knee, wrist, 2nd and 3rd MCP, patellofemoral	Normal	OA like loss	Large cysts; chondrocalcinosis
Neuropathic	Midfoot, shoulder, knee by cause	Increased or resorbed	Destroyed	Debris, fragments, sclerosis

Measurements and grades

Item	Value	Meaning
ADI	3 mm adult; 5 mm child	Over: transverse ligament failure
ADI high risk	Over about 9 to 10 mm	Or posterior ADI 14 mm or less: surgical consult
McGregor line	Dens tip no more than about 4.5 mm above	Cranial settling
DISH	4 or more contiguous levels	Discs preserved
New York grade 2 / 3 / 4	Minimal / unequivocal / total ankylosis	AS: bilateral 2+ or unilateral 3 to 4
Kellgren and Lawrence	0 to 4	OA severity on film
Urate saturation	About 6.8 mg/dL	May be normal in a flare
Transferrin saturation	Over about 45%	Hemochromatosis screen
CPPD under 55	Check calcium, PTH, Mg, iron	Secondary causes

Worked cases

WORKED CASE 1 · READING NEW BONE ON A LATERAL FILM

A 68 year old obese man with diabetes has thoracic stiffness and trouble swallowing solids. The lateral thoracic film shows thick, undulating anterior ossification from T6 to T11, a thin lucent line between it and the bodies, normal disc heights and unfused facets. The SI joints are normal.

STEP 1 · ALIGNMENT AND DENSITY

Alignment normal; bone density normal; the finding is productive new bone.

STEP 2 · DESCRIBE THE NEW BONE

Thick, flowing, anterior, six contiguous levels, separated from the bodies by a lucent line.

STEP 3 · CHECK THE DISCS AND SI JOINTS

Discs tall; facets and SI joints normal. That rules out AS (marginal syndesmophytes, sacroiliitis) and degenerative spondylosis (narrow discs).

STEP 4 · IMPRESSION

DISH.

STEP 5 · RECOMMENDATIONS

Evaluate the dysphagia (lateral cervical or ENT); note fracture risk: CT for any pain after trauma; no thrust through ossified segments; treat adjacent mobile levels gently.

WORKED CASE 2 · RA AND THE FLEXION FILM

A 59 year old with 15 years of RA has occipital headache worse looking down and tingling in both hands. Neutral lateral ADI is 3 mm; flexion ADI is 8 mm. Hoffmann is positive on both sides.

STEP 1 · MEASURE IN BOTH VIEWS

Neutral 3 mm is at the limit; flexion 8 mm is well over 3 mm.

STEP 2 · INTERPRET

The flexion view unmasks atlantoaxial instability from transverse ligament failure.

STEP 3 · ADD THE NEUROLOGY

Bilateral hand paresthesia and Hoffmann signs suggest cord compromise.

STEP 4 · ACT

Cervical manipulation is absolutely contraindicated. Urgent spine surgery referral with MRI; emergency department if signs are progressing rapidly. The report states both measurements.

WORKED CASE 3 · A TOE THAT KEEPS FLARING

A 62 year old on a thiazide has had three hot great toes in six years. The film shows a lobulated soft tissue mass beside the first MTP and a well defined erosion of the medial metatarsal head with a sclerotic margin and a thin overhanging lip. Joint space and density are normal.

STEP 1 · DISTRIBUTION

Single first MTP, asymmetric, lower limb.

STEP 2 · DENSITY AND JOINT SPACE

Both preserved: against RA.

STEP 3 · EROSION CHARACTER

Punched out with a sclerotic rim and overhanging edge beside a tophus: gout.

STEP 4 · RECOMMENDATIONS

Serum urate, renal function, physician referral for urate lowering therapy and review of the diuretic. A hot toe with fever needs aspiration to exclude septic arthritis.

TRAPS PEOPLE FALL INTO

- **Calling DISH ankylosing spondylitis.** DISH has thick flowing bone, tall discs and normal SI joints. AS has thin corner syndesmophytes and sacroiliitis.
- **Trusting a neutral ADI in RA.** Instability may appear only in flexion. Get flexion and extension views.
- **Reading a vacuum disc as infection.** Gas in the disc argues strongly against infection.
- **Calling DIP disease with fluffy new bone rheumatoid.** DIP, normal density and new bone mean psoriatic arthritis.
- **Ruling out gout because the joint space is normal.** Gout preserves the space and density until late.
- **Calling OA of the radiocarpal or MCP joint primary OA.** Unusual joints point to CPPD or hemochromatosis.
- **Treating a unilateral inflamed SI joint as mechanical.** Unilateral sacroiliitis with fever is septic until proven otherwise.
- **Clearing a fused spine after a fall with plain films.** Radiographs miss many carrot stick fractures. Get CT.

Chapter 12 self-test · ten items

1. A lateral film shows bony spurs arising a few millimeters from the endplates, running horizontally then curving toward each other, with narrowed discs. What are they?

A. Degenerative claw osteophytes
B. Flowing DISH ossification
C. Nonmarginal syndesmophytes
D. Marginal syndesmophytes

A. Degenerative claw osteophytes Osteophytes start a few millimeters from the endplate and run horizontally first; syndesmophytes start at the corner and run vertically.

2. A hand film shows bilateral symmetric MCP and PIP narrowing, periarticular osteopenia, marginal erosions without new bone and normal DIP joints. What is most likely?

A. Psoriatic arthritis
B. Rheumatoid arthritis
C. Erosive osteoarthritis
D. Chronic tophaceous gout

B. Rheumatoid arthritis Symmetric proximal disease with osteopenia, uniform narrowing and marginal erosions without new bone is RA.

3. A patient with long standing RA has an ADI of 2 mm in neutral and 7 mm in flexion. What does this mean?

A. Normal, because the neutral value is only 2 mm wide
B. Normal laxity expected in all adults
C. Atlantoaxial instability; no upper cervical thrust
D. Degenerative change only, no concern

C. Atlantoaxial instability; no upper cervical thrust An adult ADI over 3 mm, here in flexion, means transverse ligament insufficiency.

4. Which hip pattern suggests inflammatory arthritis rather than OA?

A. Superolateral migration with osteophytes
B. Inferior head osteophyte with cysts
C. Medial cortical buttressing of the neck
D. Axial migration of the head with protrusio

D. Axial migration of the head with protrusio Concentric (axial) migration with protrusio fits RA; superolateral migration fits OA.

5. Under the modified New York criteria, which radiographic sacroiliitis supports ankylosing spondylitis?

A. Unilateral grade 1 changes
B. Unilateral grade 2 only
C. Bilateral grade 2 or higher
D. Bilateral grade 1 suspicious

C. Bilateral grade 2 or higher Bilateral grade 2 or more, or unilateral grade 3 or 4, counts.

6. A febrile IV drug user has a single inflamed sacroiliac joint with erosions. What must be considered first?

A. Septic sacroiliitis
B. Osteitis condensans ilii
C. Degenerative SI arthrosis
D. Ankylosing spondylitis

A. Septic sacroiliitis Unilateral sacroiliitis is infection until proven otherwise, especially with fever and IV drug use.

7. A 43 year old with psoriasis has DIP erosions with fluffy new bone, a pencil in cup deformity and normal density. What spinal finding is expected?

A. Thin marginal syndesmophytes at every level
B. Bulky nonmarginal syndesmophytes that skip levels
C. Flowing ossification over four levels
D. Claw osteophytes with narrowed discs

B. Bulky nonmarginal syndesmophytes that skip levels Psoriatic arthritis gives asymmetric, bulky, nonmarginal syndesmophytes.

8. A 66 year old has meniscal calcification, isolated patellofemoral narrowing with a large patellar cyst and TFCC calcification. What is the impression?

A. Primary osteoarthritis
B. Rheumatoid arthritis
C. Hydroxyapatite deposition
D. CPPD arthropathy

D. CPPD arthropathy Chondrocalcinosis plus OA in an unusual compartment with large cysts is CPPD.

9. A 48 year old man has hook osteophytes on the radial 2nd and 3rd metacarpal heads with wrist chondrocalcinosis. Which test should the report recommend?

A. HLA-B27 and CRP
B. Transferrin saturation and ferritin
C. Serum urate alone
D. Rheumatoid factor and anti-CCP antibody

B. Transferrin saturation and ferritin This pattern suggests hemochromatosis; early phlebotomy prevents organ damage.

10. A 46 year old has acute neck pain and painful swallowing; the film shows amorphous calcification anterior to C1 and C2 with prevertebral swelling. What is likely?

A. An acute dens fracture
B. Retropharyngeal abscess is certain
C. DISH with cervical dysphagia
D. Longus colli calcific tendinitis

D. Longus colli calcific tendinitis Hydroxyapatite in the longus colli is self limiting, but fever or toxicity calls for urgent evaluation to exclude an abscess.

ONE PAGE

Cram sheet

Everything from chapters 11 and 12 in one place. Cover the right column and see if you can rebuild each row.

Numbers to know

Item	Value	Note
Trial of care	About 2 weeks; two trials about 4 weeks	No response: change, test or refer
Relief phase	2 to 3 visits a week for 1 to 2 weeks	Corrective 1 to 2 a week for 2 to 6 weeks
Natural history	60 to 70% improve within 6 weeks	Recurrence within a year about half
Prediction rule	4 of 5 items; LR+ about 24 (original)	Under 16 days, FABQ work under 19, hip IR over 35°
MCID	NPRS 2 (30%); ODI 10 (30%); NDI 5 to 7; PSFS 2	VAS 15 to 20 mm; RMDQ 3 to 5; HDI 16
FABQ work	Over 34 predicts poor return to work	Range 0 to 42
Re-exam	Every 2 to 4 weeks or about 12 visits or 30 days	And with anything new
Record retention	At least about 7 years for adults	Longer for minors
CPT	98940 1 to 2; 98941 3 to 4; 98942 5 regions; 98943 extraspinal	Timed codes 15 min units
ADI	3 mm adult; 5 mm child; high risk over 9 to 10 mm	Posterior ADI 14 mm or less
McGregor	Dens tip up to about 4.5 mm above	Cranial settling
DISH	4 or more contiguous levels	Right sided thoracic
Sacroiliitis	AS: bilateral grade 2+ or unilateral 3 to 4	New York 0 to 4
Urate	Saturates about 6.8 mg/dL	Films normal for years
Hemochromatosis	Transferrin saturation over about 45%	Hook osteophytes 2nd and 3rd MCP

Key terms and comparisons

Pair	How to tell them apart
Supportive vs maintenance care	At MMI with documented regression versus elective wellness (ABN for Medicare).
Plateau vs MMI	Stopped improving (recheck everything) versus no further significant recovery expected after changes.
Urgent vs emergency referral	Telephoned, seen in a day or two versus ambulance or ED now.
PART vs PARQ	Subluxation findings (2 of 4, A or R) versus consent elements.
Modifier 25 vs 59	Separate E/M versus distinct procedure in another region.
OA vs RA	Nonuniform, sclerosis, osteophytes, normal density versus uniform, osteopenia, marginal erosions.
Osteophyte vs syndesmophyte vs DISH	Mm from endplate, horizontal; corner, thin, vertical; thick, flowing, 4+ levels.
Gout vs RA erosions	Punched out, sclerotic rim, overhanging edge versus marginal, no rim, osteopenic.

Dr. Garg Learning · CC BY-SA 4.0
An independent study aid. Not affiliated with or endorsed by the National Board of Chiropractic Examiners.