Study Guide 4

This guide covers the two clinical impression chapters, the heaviest content area on Part III. Every vignette here asks the same thing in different clothes: what is the most likely diagnosis, and what must not be missed? Learn the one or two discriminating clues for each condition, and practice naming the dangerous look alike before you name the common answer. Work one chapter at a time, study the diagram, copy the tables, cover the steps of each worked case, then do the self-tests and the cram sheet.

WHAT THIS GUIDE COVERS

- Chapter 7 · mechanical neck pain, radiculopathy and myelopathy, whiplash grades, primary and red flag headaches, cervical artery dissection, chest wall versus visceral thoracic pain, compression fracture and zoster, low back diagnoses and roots, cauda equina, stenosis, spondylolisthesis, SI and inflammatory back pain, extremity diagnoses, neurologic localization, MS, stroke, Parkinson disease and vertigo.
- Chapter 8 · RA, spondyloarthropathies, gout, PMR and fibromyalgia, metabolic and endocrine bone disease, metastasis, myeloma and primary tumors, spinal infection, visceral referral, pediatric hips and scoliosis, falls in older adults, pregnancy red flags, and primary and secondary diagnoses.

CHAPTER 7

Clinical Impression I: Musculoskeletal and Neurologic Presentations

Read it in full: **Chapter 7 in the textbook**. Practice it: **the Study Guide 4 practice exam** and **the flashcards**.

What to know

Diagnosis or clinical impression is the heaviest content area on Part III. Read a vignette for the one or two clues that separate a common mechanical problem from its dangerous look alike, then name the must not miss alternative. Neck cases sort into **mechanical pain** (normal neurologic exam), **radiculopathy** (one level of lower motor neuron findings) and **myelopathy** (upper motor

neuron signs below the level). Cervical roots exit above the vertebra of the same number, so a C5 to C6 disc hits C6; C6 and C7 are the most common. Hand on head relief is a radiculopathy clue. Myelopathy over 50 brings clumsy hands, gait ataxia, Hoffmann and Lhermitte; it means MRI, surgical opinion and no high velocity cervical thrust.

Whiplash is graded by the Quebec Task Force: 0 no complaint; I pain only; II pain plus musculoskeletal signs; III plus neurologic signs; IV fracture or dislocation (immobilize, emergency). Headache types: **tension type** is bilateral and pressing without nausea; **migraine** is unilateral, pulsating, 4 to 72 hours, with nausea and photophobia (aura develops over 5 or more minutes and lasts under 60); **cluster** is strictly unilateral orbital pain for 15 to 180 minutes with tearing and a restless patient; **cervicogenic** is side locked, starts in the neck, and has a positive flexion rotation test (about 32 degrees or less, or a 10 degree side difference; normal about 44).

Screen headaches with **SNOOP** first: systemic, neurologic, onset sudden, older (new after 50), pattern change. Thunderclap headache is subarachnoid hemorrhage; fever with stiff neck is meningitis; temporal headache with jaw claudication over 50 is giant cell arteritis. **Cervical artery dissection** (about 2 to 3 per 100,000 a year) begins with unusual neck pain and headache. Vertebral dissection adds the 5 Ds and 3 Ns and ataxia; internal carotid dissection adds a partial Horner syndrome (ptosis and miosis without anhidrosis) and pulsatile tinnitus. Positional tests do not detect it; withhold manipulation and send to the emergency department.

Thoracic pain is wall or viscus, judged by behavior, not location. About 1 in 7 patients with acute coronary syndrome has some chest wall tenderness, so tenderness never excludes ischemia. Exertional, pleuritic, tearing or meal related pain, or abnormal vitals, points to the heart, aorta, lungs or gut. Aortic dissection has an arm pressure difference over 20 mmHg. Costochondritis is multiple tender junctions without swelling; Tietze syndrome has swelling at one upper cartilage. The traps are the **compression fracture** (older patient, minor trauma, percussion tenderness, worse upright; fracture above T7 or posterior cortex involvement raises pathologic fracture) and the **zoster prodrome** (2 to 5 days of unilateral dermatomal burning with allodynia before vesicles; antivirals within 72 hours of rash).

About 90 percent of low back pain is nonspecific mechanical, 5 to 10 percent radicular, 1 to 2 percent serious. About 95 percent of herniations are at L4 to L5 or L5 to S1. A **posterolateral**

herniation hits the traversing (lower number) root; a **far lateral** one hits the exiting (upper number) root. L4: medial leg, tibialis anterior, patellar reflex. L5: dorsum of foot, EHL and gluteus medius, no reliable reflex. S1: lateral foot, calf, Achilles. Cauda equina (urinary retention about 90 percent, saddle anesthesia, bilateral deficits) means same day MRI; decompression within about 48 hours. Conus medullaris syndrome gives early symmetric sphincter loss with mixed signs and less pain.

Central stenosis (over 60, usually L4 to L5) gives neurogenic claudication relieved by sitting or flexion; cycling and uphill walking are tolerated. Isthmic spondylolisthesis is L5 on S1 after a pars fracture in a hyperextending adolescent; degenerative spondylolisthesis is L4 on L5 in women over 50 with an intact pars. The step off is above the slipped level in isthmic slips and at the slipped level in degenerative slips. Meyerding grades run I (under 25 percent) to V (spondyloptosis). Sacroiliac pain sits below L5 over the PSIS; three of five Laslett tests give an LR+ of about 4. **Inflammatory back pain** (ASAS): onset under 40, insidious, better with exercise, not with rest, night pain improving on rising; four of five gives about 77 percent sensitivity and 92 percent specificity.

Nonmechanical back pain with vascular risk is an AAA until proven otherwise: 3.0 to 5.4 cm is surveillance; 5.5 cm or more, or growth over 1 cm a year, is repair; tender or with hypotension is an emergency. A writhing patient has colic; a still patient has peritonitis. Extremity diagnosis is age plus mechanism plus one discriminating finding: painful arc and Hawkins for cuff tendinopathy; drop arm and ER lag for a tear over 60; capsular pattern in a diabetic for adhesive capsulitis; Finkelstein for de Quervain; snuffbox tenderness for scaphoid (up to a fifth are not visible on first films); FADIR for impingement; Lachman for ACL; Thompson for Achilles.

Neurologic cases: localize first. Polyneuropathy is symmetric and distal (diabetes; check 128 Hz vibration and the 10 g monofilament). Guillain Barre is ascending weakness with areflexia 1 to 3 weeks after an illness. Common fibular palsy spares inversion and hip abduction; meralgia paresthetica is anterolateral thigh burning with no weakness. MS: women 20 to 40, optic neuritis, Lhermitte, Uhthoff phenomenon. Stroke: BE FAST and time last known well; TIA risk is highest in the first 48 hours. Parkinson disease: bradykinesia plus rest tremor and rigidity. Vertigo by timing: seconds and positional is BPPV (Dix Hallpike, Epley); 20 minutes to 12 hours with

hearing change is Meniere; continuous needs **HINTS**, where a normal head impulse, direction changing nystagmus or skew means stroke.

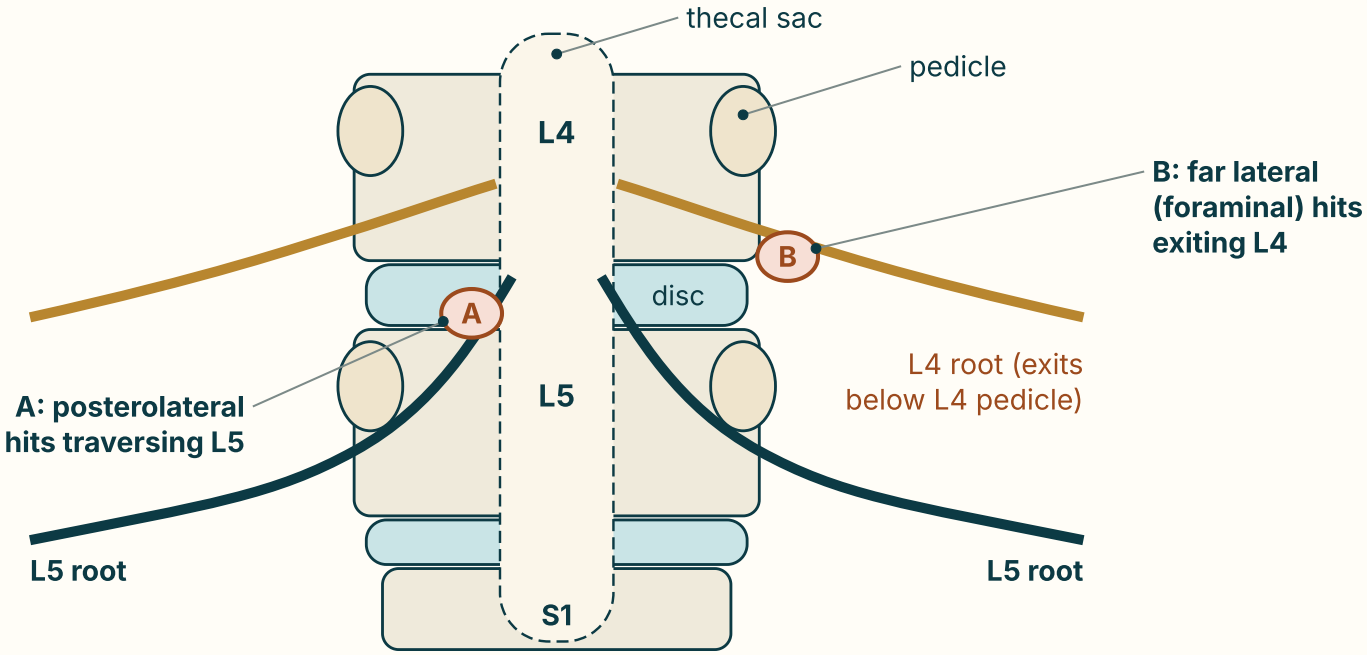

L4 to L5 disc: posterolateral hits the lower number (traversing L5); far lateral hits the upper number (exiting L4).
Neck: roots exit above their vertebra, so a C5 to C6 disc hits C6.

Traversing versus exiting root. The same L4 to L5 disc can produce an L5 or an L4 radiculopathy depending on where it herniates. Match the dermatome, myotome and reflex to the root before you name the level.

LOCK THESE IN

- Radiculopathy is one level of LMN signs; myelopathy is UMN signs below the level.
- SNOOP before naming a primary headache; cervicogenic is side locked with a positive flexion rotation test.
- Unusual neck pain plus Horner or 5 Ds and 3 Ns: dissection, no manipulation.
- Chest wall tenderness does not exclude ischemia; exertional pain is cardiac until proven otherwise.
- Posterolateral disc hits the traversing root; far lateral hits the exiting root.
- Cauda equina: retention and saddle anesthesia, same day MRI.
- Snuffbox tenderness is a scaphoid fracture even with a normal first film.
- Continuous vertigo with a normal head impulse is central until proven otherwise.

Low back presentations

Presentation	Most likely	Must not miss
Lift, flexion worse, normal neuro	Nonspecific mechanical LBP	Fracture in older or steroid treated patient
Leg worse than back, SLR 30 to 70°	Disc herniation with radiculopathy	Cauda equina syndrome
Over 60, legs ache walking, sit to relieve	Central stenosis	Vascular claudication
Teen athlete, extension pain	Spondylolysis or isthmic slip	Osteoid osteoma
Buttock below L5, provocation cluster	Sacroiliac joint pain	Sacroiliitis of spondyloarthritis
Under 40, morning stiffness, better with exercise	Axial spondyloarthritis	Infection or tumor if systemic
Older smoker, constant deep pain, pulsatile mass	Abdominal aortic aneurysm	Rupture

Headache and vertigo patterns

Pattern	Key clues	Diagnosis
Bilateral pressing, no nausea	Pericranial tenderness	Tension type headache
Unilateral pulsating 4 to 72 h	Nausea, photo and phonophobia	Migraine
Orbital 15 to 180 min, nightly	Tearing, ptosis, restless	Cluster headache
Side locked, from the neck	Flexion rotation about 32° or less	Cervicogenic headache
Thunderclap	Peak within a minute	Subarachnoid hemorrhage
Seconds, positional	Fatigable torsional upbeating nystagmus	BPPV
20 min to 12 h attacks	Low frequency hearing loss, tinnitus	Meniere disease
Days, after a virus, abnormal head impulse	Unidirectional nystagmus	Vestibular neuritis
Continuous, normal head impulse or skew	Direction changing nystagmus	Posterior circulation stroke

Worked cases

WORKED CASE 1 · NAMING THE ROOT FROM A FAR LATERAL DISC

A 52 year old has anterior thigh and medial leg pain, a weak quadriceps and a reduced patellar reflex. MRI shows an L4 to L5 herniation. Where on the disc is it most likely?

STEP 1 · NAME THE ROOT

Medial leg sensation, quadriceps and tibialis anterior weakness and a reduced patellar reflex mean L4.

STEP 2 · APPLY THE RULE

An L4 to L5 disc hits L5 if posterolateral (traversing) and L4 if far lateral (exiting).

STEP 3 · CONCLUDE

An L4 root lesion from an L4 to L5 disc means a **far lateral (foraminal)** herniation.

STEP 4 · CHECK THE TRAP

A posterolateral L4 to L5 disc would give dorsum of foot numbness and EHL weakness instead.

WORKED CASE 2 · NECK PAIN THAT IS A DISSECTION

A 37 year old woman has right upper neck and occipital pain since a sharp head turn three days ago, "nothing like" her tension headaches. Since yesterday she has felt off balance and had ten minutes of slurred speech. Finger to nose is dysmetric on the right.

STEP 1 · FIND THE UNUSUAL PAIN

New, severe, different neck pain after trivial rotation.

STEP 2 · ADD THE NEUROLOGY

Transient dysarthria, imbalance and an ipsilateral cerebellar sign: posterior circulation ischemia.

STEP 3 · IMPRESSION

Suspected vertebral artery dissection.

STEP 4 · ACT

Ambulance to the emergency department; no manipulation and no positional testing.

WORKED CASE 3 · VERTIGO WITH HINTS

A 68 year old with atrial fibrillation woke with severe spinning and vomiting and cannot walk unaided. Nystagmus beats left on left gaze and right on right gaze, the head impulse is normal, and there is a vertical skew.

STEP 1 · TIMING

Continuous vertigo: HINTS, not Dix Hallpike.

STEP 2 · HEAD IMPULSE

Normal: the vestibular nerve works, so the lesion is central. This is the dangerous result.

STEP 3 · NYSTAGMUS AND SKEW

Direction changing nystagmus and skew deviation are both INFARCT findings.

STEP 4 · ACT

Posterior circulation stroke until proven otherwise. Call emergency services and record the time last known well.

TRAPS PEOPLE FALL INTO

- **Calling myelopathy carpal tunnel.** Clumsy hands with brisk reflexes, Hoffmann and gait ataxia mean the cord.
- **Trusting a negative positional artery test.** It cannot detect dissection. History and neuro screen decide.
- **Anchoring on "I was shoveling snow."** Exertional interscapular tightness in a diabetic is cardiac until proven otherwise.
- **Treating the zoster prodrome as a rib.** Unilateral dermatomal burning with allodynia: re-examine daily and refer when vesicles appear.
- **Assuming posterolateral every time.** A far lateral L4 to L5 disc hits L4, not L5.
- **Blaming retention on pain medication.** New retention with sciatica is cauda equina until proven otherwise.
- **Doing Dix Hallpike in continuous vertigo.** Positional tests are for brief positional spells. Continuous vertigo needs HINTS.
- **Reading a normal head impulse as reassuring.** In acute continuous vertigo it suggests a central lesion.

Chapter 7 self-test · ten items

1. A 47 year old has neck pain and pain into the middle finger, weak elbow extension and a reduced triceps reflex. Which disc is most likely involved?

A. C6 to C7, affecting the C7 root
B. C7 to T1, affecting the C7 root
C. C6 to C7, affecting the C6 root
D. C5 to C6, affecting the C7 root

A. C6 to C7, affecting the C7 root Cervical roots exit above the vertebra of the same number, so the C6 to C7 disc affects C7.

2. After a rear end collision, a patient has neck pain, reduced range of motion and point tenderness, with a normal neurologic exam and no fracture. What is the Quebec grade?

A. Grade III
B. Grade I
C. Grade IV
D. Grade II

D. Grade II Neck complaint plus musculoskeletal signs is grade II. Neurologic signs make grade III.

3. A 35 year old woman has left neck and periorbital pain after a long dental visit, with a smaller left pupil and mild ptosis but normal sweating. What is the impression?

A. Cluster headache, first episode
B. Migraine with prolonged aura
C. Internal carotid artery dissection
D. Cervicogenic headache from C2

C. Internal carotid artery dissection Neck and face pain with a partial Horner syndrome (no anhidrosis) suggests carotid dissection. Withhold manipulation and refer to the emergency department.

4. A 34 year old has side locked right headache starting in the neck, worse with sustained posture, and flexion rotation to the right of 28 degrees. What is the most likely diagnosis?

A. Cluster headache
B. Cervicogenic headache
C. Tension type headache
D. Migraine without aura

B. Cervicogenic headache A side locked headache provoked by the neck with a positive flexion rotation test (about 32 degrees or less) is cervicogenic.

5. A 59 year old man with diabetes has interscapular tightness on climbing stairs that settles with rest, and T5 is mildly tender. What is the next step?

A. Thoracic radiographs to look for a fracture
B. Rib mobilization and a home stretching plan
C. Emergency evaluation today for coronary disease
D. Thoracic adjustment and recheck in two days

C. Emergency evaluation today for coronary disease Exertional pain relieved by rest in a diabetic is angina or ACS. Tenderness does not exclude ischemia.

6. A 73 year old woman has three days of right sided band like burning from mid back to upper abdomen; clothing on the skin hurts and there is no rash. What is most likely?

A. The prodrome of herpes zoster
B. An acute T8 compression fracture
C. Gallbladder disease referring pain
D. A costotransverse joint fixation

A. The prodrome of herpes zoster Unilateral dermatomal burning with allodynia before a rash in an older adult is the zoster prodrome.

7. A posterolateral L5 to S1 herniation most likely produces which finding?

A. Anterior thigh pain with a positive prone knee bend
B. Reduced Achilles reflex and weak plantar flexion
C. Weak great toe extension with a normal reflex
D. Reduced patellar reflex and weak quadriceps

B. Reduced Achilles reflex and weak plantar flexion A posterolateral L5 to S1 disc hits the traversing S1 root: calf weakness, lateral foot numbness and a reduced Achilles reflex.

8. A 67 year old has bilateral thigh and calf heaviness after two blocks that eases when he stands still; cycling cramps his calves and pulses are faint. What is the diagnosis?

A. Bilateral S1 radiculopathy
B. Cauda equina syndrome
C. Neurogenic claudication
D. Vascular claudication

D. Vascular claudication Relief by standing still, cycling intolerance and faint pulses point to peripheral artery disease. Confirm with an ABI under 0.9.

9. A 25 year old cyclist fell on an outstretched hand five days ago; the snuffbox is tender and the day of injury film was normal. What is the best plan?

A. Reassure and return in six weeks if sore
B. Thumb spica and repeat films in 10 to 14 days
C. Wrist strengthening exercises starting today
D. Wrist adjustment, since the film was normal

B. Thumb spica and repeat films in 10 to 14 days Snuffbox tenderness is a scaphoid fracture until proven otherwise; up to a fifth are invisible on initial films.

10. A 29 year old woman had painful vision loss in one eye last year and now has numb legs that worsen in a hot bath. What is the likely diagnosis?

A. Multiple sclerosis
B. Diabetic polyneuropathy
C. Guillain Barre syndrome
D. Lumbar spinal stenosis

A. Multiple sclerosis Episodes separated in time and space (optic neuritis, then sensory myelopathy) with the Uhthoff phenomenon suggest MS.

CHAPTER 8

Clinical Impression II: Systemic, Visceral and Special Population Presentations

Read it in full: **Chapter 8 in the textbook**. Practice it: **the Study Guide 4 practice exam** and **the flashcards**.

What to know

The patients harmed in practice are the ones whose cancer, infection, inflammatory disease or visceral disorder was treated as back pain for too long. First ask whether pain is **inflammatory** (stiffness after rest over 30 to 60 minutes, better with use, soft tissue swelling, raised ESR or CRP) or **mechanical** (worse with use, gelling for minutes, bony swelling). Then read the pattern. **Rheumatoid arthritis** is symmetric small joint polyarthritis (MCP, PIP, wrist, MTP) that spares the DIP joints, about three times more common in women, peaking at 30 to 50. Anti CCP is about 95 percent specific. Its chiropractic hazard is atlantoaxial instability: an adult ADI over 3 mm is abnormal, and rotational or high velocity upper cervical thrust is contraindicated in active RA until instability is excluded.

The **seronegative spondyloarthropathies** share HLA B27, sacroiliitis, enthesitis, asymmetric large joint oligoarthritis, anterior uveitis and a negative RF. Ankylosing spondylitis: man under 40, chest expansion under 2.5 cm, bilateral symmetric sacroiliitis, marginal syndesmophytes, HLA B27 in about 90 percent; a fused spine is fracture prone. Psoriatic: nail pitting, sausage digit, DIP erosions, pencil in cup. Reactive: 1 to 4 weeks after Chlamydia or enteric infection. Enteropathic: peripheral arthritis tracks bowel activity, axial disease does not. **Gout** is a hot first MTP after alcohol, a large meat meal or a diuretic; urate may be normal in the flare; needle shaped negatively birefringent crystals. Pseudogout hits the knee and wrist with chondrocalcinosis. A hot joint is septic until aspirated.

Polymyalgia rheumatica occurs after 50 (mean about 70): girdle aching and stiffness, normal strength and CK, high ESR (often over 40 to 50), dramatic response to low dose prednisone. About 15 to 20 percent also have giant cell arteritis, so always ask about headache, jaw claudication and vision. **Fibromyalgia** is widespread pain for 3 months or more with fatigue and

unrefreshing sleep and normal labs, diagnosed only after hypothyroidism, PMR, inflammatory arthritis, vitamin D deficiency and statin myopathy are considered. Hypothyroidism brings myalgia, carpal tunnel and slow relaxing reflexes; diabetes brings adhesive capsulitis, cheiroarthropathy, DISH and Charcot foot; osteomalacia brings Looser zones and raised ALP; Paget disease brings very high ALP with normal calcium. Long term glucocorticoids (5 mg prednisone daily for 3 months or more) are an osteoporosis risk.

Tumor and infection share a pattern: constant, progressive, nonmechanical night pain, weight loss or fever, percussion tenderness and a risk factor. Prior cancer is the strongest predictor. Bone metastases come from **PB KTL**: prostate (usually blastic), breast (lytic, blastic or mixed), kidney and thyroid (lytic, expansile), lung. They spread through the arteries and the valveless **Batson plexus**. The **winking owl** sign is a destroyed pedicle on the AP view. Metastatic cord compression occurs in about 5 to 10 percent of cancer patients: new weakness, a sensory level or sphincter change means same day whole spine MRI. Myeloma (after 60) is CRAB with an M spike, rouleaux and a falsely negative bone scan.

Primary bone tumors are tested by age, site and one clue: osteoid osteoma (10 to 30, night pain relieved by NSAIDs, painful scoliosis), osteosarcoma (10 to 25, knee metaphysis, sunburst), Ewing sarcoma (5 to 20, diaphysis, fever, onion skin), chondrosarcoma (over 40, rings and arcs), giant cell tumor (20 to 40, epiphysis after physeal closure, soap bubble), hemangioma (corduroy vertebra), chordoma (40 to 60, sacrum and clivus). Spinal infection is usually **S. aureus** by blood spread; Pseudomonas with IV drug use; Salmonella with sickle cell disease; tuberculosis (Pott disease) with gibbus and relative disc sparing. Fever is present in only about half; CRP is the most sensitive marker; films lag 2 to 4 weeks; MRI is the test. **Tumor spares the disc; infection crosses it.** Epidural abscess can paralyze within hours.

Viscera refer pain to the dermatomes of their segments through **viscerosomatic convergence**, and the diaphragm refers to the shoulder tip through the phrenic nerve (C3 to C5). Heart (T1 to T5): chest, left arm, interscapular. Gallbladder (T7 to T9): right scapula after fatty meals, Murphy sign. Pancreas: boring epigastric pain to the midback, relieved leaning forward. Kidney: flank to groin, writhing with a stone, fever and CVA tenderness with pyelonephritis. Spleen: left shoulder tip after trauma (Kehr sign). Ectopic pregnancy: missed period, bleeding, shoulder tip pain. Prostate:

sacral and perineal pain with urinary symptoms. A complaint the exam cannot reproduce needs a review of systems.

Children: growing pains (about 3 to 12) are bilateral, between joints, at night, gone by morning, with a normal exam. Red flags are unilateral or joint pain, limp, fever, night pain that wakes the child, and back pain under about 10. Match hip disorders to age: transient synovitis 3 to 10 (separate from septic arthritis with the Kocher criteria: fever over 38.5 °C, refusal to bear weight, ESR over 40, WBC over 12,000); **Perthes** in boys about 4 to 8 (painless limp, lost abduction and internal rotation); **SCFE** in overweight adolescents 10 to 16 (knee pain, Drehmann sign, Klein line misses the head, bilateral in 20 to 40 percent, non weight bearing). Scoliosis: Cobb 10 degrees or more; observe under 25, brace 25 to 40 (or 45) in a growing child, surgery beyond about 45 to 50. Painful scoliosis is never idiopathic.

Older adults: a fall is a symptom (syncope, orthostatic hypotension, polypharmacy, neuropathy, Parkinson disease); a Timed Up and Go over about 12 seconds suggests fall risk. An impacted femoral neck fracture may still let the patient walk. Pregnancy: low back and pelvic girdle pain affect about half; avoid prolonged supine after about 20 weeks. Red flags are bleeding or fluid leak, rhythmic pain before 37 weeks, preeclampsia (BP 140/90 or higher after 20 weeks with headache, visual change, RUQ pain, edema), DVT (risk four to five times higher) and cauda equina. Finally, state the impression: a **primary diagnosis** that explains the chief complaint, **secondary diagnoses** that change prognosis or technique, and a must not miss alternative. Failure to improve is new data.

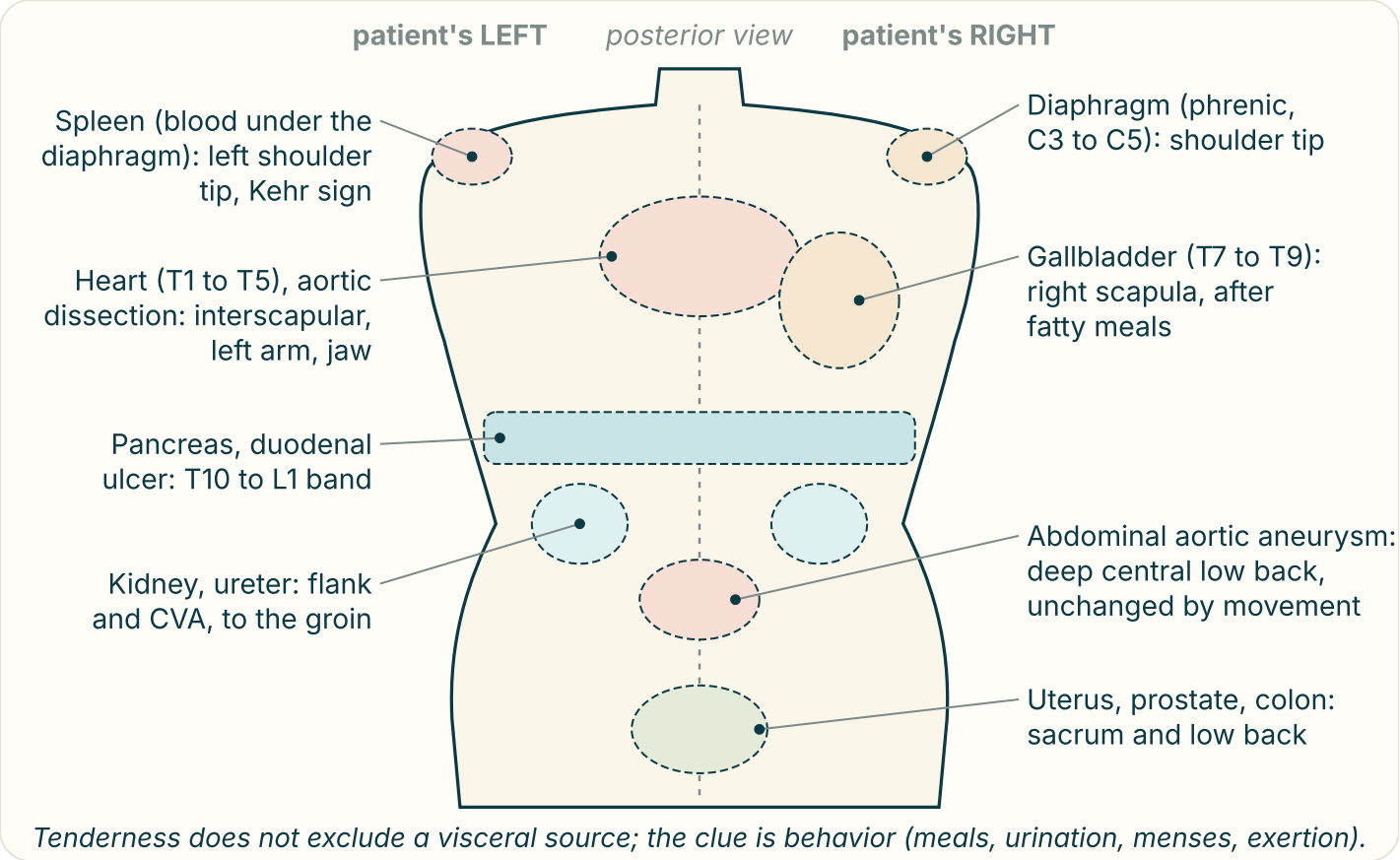

Visceral referral to the back. Viscera refer pain to the dermatomes of the segments that supply them, and the diaphragm refers to the shoulder tip through C3 to C5. Location suggests the organ; systemic signs set the urgency.

LOCK THESE IN

- Inflammatory pain: long morning stiffness, better with use, raised ESR or CRP.
- RA spares the DIP joints; anti CCP is specific; check C1 to C2 stability before upper cervical thrust.
- PMR after 50: girdle stiffness, normal strength and CK, high ESR; ask about giant cell arteritis.
- PB KTL to bone; prostate is blastic; winking owl is a lost pedicle.
- Tumor spares the disc; infection crosses it; epidural abscess can paralyze within hours.
- Diaphragm refers to the shoulder tip through C3 to C5; Kehr sign means splenic rupture.
- SCFE: overweight teen with knee pain and Drehmann sign; Perthes: boy 4 to 8 with painless limp.
- Pregnancy red flags: bleeding, preterm contractions, preeclampsia, DVT, cauda equina.

Systemic disease patterns

Condition	Case clues	Key test or finding
Rheumatoid arthritis	Symmetric MCP, PIP, wrist; spares DIP	Anti CCP (about 95% specific); ADI over 3 mm
Ankylosing spondylitis	Man under 40, chest expansion under 2.5 cm	Bilateral SI, marginal syndesmophytes, HLA B27 about 90%
Psoriatic arthritis	Nail pitting, sausage digit	DIP erosions, pencil in cup
Reactive arthritis	1 to 4 weeks after Chlamydia or diarrhea	Asymmetric lower limb, conjunctivitis, urethritis
Gout	Hot first MTP after alcohol or diuretic	Negatively birefringent needles
Polymyalgia rheumatica	Over 50, girdle stiffness, normal strength	High ESR, normal CK; 15 to 20% have GCA
Multiple myeloma	Over 60, CRAB	M spike; bone scan often negative
Osteomalacia	Diffuse bone pain, waddling gait	Low vitamin D, raised ALP, Looser zones
Paget disease	Over 55, bowed tibia, hearing loss	Very high ALP, normal calcium

Children's hips by age

Age	Condition	Clue and action
Infancy	Developmental dysplasia	Found on infant screening
3 to 10	Transient synovitis	After a virus, afebrile, bears weight; exclude septic hip
Any, febrile	Septic arthritis	Fever over 38.5 °C, no weight bearing, ESR over 40, WBC over 12,000: emergency
About 4 to 8 (boys)	Legg Calve Perthes	Painless limp, lost abduction and IR; radiographs, refer
10 to 16 (overweight)	SCFE	Knee pain, Drehmann sign; non weight bearing, urgent referral

Worked cases

WORKED CASE 1 · POLYMYALGIA WITH A WARNING SIGN

A 72 year old woman has six weeks of aching in both shoulders, neck and hips, needs 90 minutes to loosen up in the morning, and struggles out of a low chair. Strength is 5 of 5 once warm, ESR 68 mm/h, CRP raised, CK normal. She mentions a new right temporal headache.

STEP 1 · INFLAMMATORY OR MECHANICAL?

Prolonged morning stiffness and a high ESR: inflammatory.

STEP 2 · READ THE PATTERN

Bilateral girdle pain after 50 with normal strength and normal CK: polymyalgia rheumatica. Normal CK excludes myositis.

STEP 3 · FIND THE COMPLICATION

A new temporal headache raises giant cell arteritis (15 to 20 percent of PMR).

STEP 4 · SET URGENCY

Same day referral: vision is at risk.

WORKED CASE 2 · TUMOR OR INFECTION ON THE FILM

Two lumbar films. Film 1: one collapsed vertebral body with an absent left pedicle and normal disc heights above and below. Film 2: loss of the L3 to L4 disc space with erosion of both adjacent endplates.

STEP 1 · LOOK AT THE DISC

Film 1 spares the disc; film 2 destroys it.

STEP 2 · APPLY THE RULE

Tumor respects the disc; infection crosses it.

STEP 3 · NAME THEM

Film 1: metastasis (winking owl). Film 2: discitis and vertebral osteomyelitis.

STEP 4 · NEXT STEP

MRI with contrast for both, with labs (CBC, ESR, CRP; SPEP or PSA as fits; blood cultures for infection). Any neurologic sign makes it an emergency.

WORKED CASE 3 · PRIMARY AND SECONDARY DIAGNOSES

A 62 year old woman has five weeks of right posterior thigh and calf pain after gardening. SLR reproduces calf pain at 40 degrees, the right Achilles reflex is reduced and repeated heel raises are weak. She has type 2 diabetes (HbA1c 8.9 percent), a DXA T score of −2.7 and a high fear avoidance work score. Red flag screen is negative.

STEP 1 · SCREEN FOR DANGER

No saddle anesthesia, bladder change, fever or weight loss.

STEP 2 · PRIMARY DIAGNOSIS

Right S1 radiculopathy, most likely an L5 to S1 disc herniation.

STEP 3 · SECONDARY DIAGNOSES

Osteoporosis (avoid high force thrust, especially thoracic and ribs), poorly controlled diabetes (slower healing; compare ankle reflexes for neuropathy) and fear avoidance (predicts chronicity).

STEP 4 · PLAN THE WATCH POINTS

Monitor the deficit and Oswestry; MRI and surgical opinion if weakness progresses; emergency if cauda equina signs appear.

TRAPS PEOPLE FALL INTO

- **Calling PMR fibromyalgia.** Girdle stiffness after 50 with a high ESR is PMR. Fibromyalgia has normal labs.
- **Forgetting the giant cell arteritis question.** Every PMR patient gets asked about headache, jaw pain and vision.
- **Thrusting the upper neck in active RA.** Exclude atlantoaxial instability first.

- **Reassuring with a normal film in suspected metastasis or infection.** Films lag; MRI is the next test when suspicion is high.
- **Waiting on a normal neuro exam in suspected epidural abscess.** Deficits can appear within hours. Same day MRI.
- **Treating shoulder tip pain with a normal shoulder exam.** Think diaphragm: spleen, gallbladder, ectopic pregnancy.
- **Giving knee exercises to an overweight teen.** Examine the hip: SCFE presents as knee pain.
- **Continuing care that is not working.** Failure to improve is new data. Reopen the differential.

Chapter 8 self-test · ten items

1. A 46 year old woman has symmetric swelling of the MCP, PIP and wrist joints with two hours of morning stiffness. What must be excluded before upper cervical manipulation?

A. Vertebral artery hypoplasia
B. Basilar invagination of the skull
C. Os odontoideum ossicle
D. Atlantoaxial instability

D. Atlantoaxial instability This is rheumatoid arthritis. Synovitis erodes the transverse ligament and dens; an adult ADI over 3 mm is abnormal.

2. A 25 year old man has asymmetric knee and ankle swelling, red eyes and dysuria three weeks after a bout of diarrhea. What is the likely diagnosis?

A. Reactive arthritis
B. Psoriatic arthritis
C. Septic arthritis
D. Rheumatoid arthritis

A. Reactive arthritis Arthritis 1 to 4 weeks after enteric or Chlamydia infection with conjunctivitis and urethritis is reactive arthritis.

3. A 73 year old with shoulder and hip girdle stiffness, normal strength, normal CK and an ESR of 64 mm/h. Which question matters most next?

A. Any family history of psoriasis?
B. Any recent change in shoe wear?
C. New headache, jaw pain or vision change?
D. Any numbness in both feet at night in bed?

C. New headache, jaw pain or vision change? This is PMR; 15 to 20 percent have giant cell arteritis, which can cause blindness.

4. Which primary cancer most typically produces blastic (sclerotic) bone metastases?

A. Thyroid
B. Prostate
C. Lung
D. Kidney

B. Prostate Prostate metastases are usually blastic. Kidney and thyroid are lytic and expansile.

5. A lumbar AP film shows one pedicle missing at L2 with normal disc heights. What does this sign suggest?

A. Lytic metastasis (winking owl)
B. A congenital block vertebra
C. Spondylolysis of the pars
D. Discitis with endplate erosion

A. Lytic metastasis (winking owl) A destroyed pedicle on the AP view is the winking owl sign of metastasis. Infection destroys the disc.

6. A 48 year old with diabetes and a recent foot ulcer has constant night back pain, a temperature of 37.9 °C, focal L3 tenderness, CRP 96 mg/L, a normal neuro exam and normal films. What is next?

A. Lumbar manipulation and recheck in a week
B. Same day MRI with contrast and blood cultures
C. Repeat radiographs in four weeks
D. Bone density scan and vitamin D level

B. Same day MRI with contrast and blood cultures This is vertebral osteomyelitis or epidural abscess until proven otherwise. Films lag and deficits can appear within hours.

7. A 45 year old woman has right scapular pain after a large dinner, nausea, fever of 38.3 °C, full painless spinal motion and a positive Murphy sign. What is the impression?

A. Pancreatitis
B. Right rhomboid strain
C. Acute cholecystitis
D. Right T7 rib dysfunction

C. Acute cholecystitis Postprandial right scapular pain not reproduced by movement, with fever and a Murphy sign, is cholecystitis.

8. A 6 year old boy has a painless limp for two months and has lost hip abduction and internal rotation. What is the likely diagnosis?

A. Slipped capital femoral epiphysis
B. Transient synovitis of the hip
C. Osgood Schlatter disease
D. Legg Calve Perthes disease

D. Legg Calve Perthes disease Perthes is avascular necrosis of the femoral head in boys about 4 to 8. SCFE affects adolescents.

9. A 32 year old at 34 weeks with pelvic girdle pain now has a severe headache, flashing spots and facial puffiness; BP is 152/98 twice. What is next?

A. Recheck BP at next week's visit
B. Emergency obstetric evaluation now
C. Advise rest and fluids at home
D. Continue the planned pelvic treatment

B. Emergency obstetric evaluation now BP 140/90 or higher after 20 weeks with headache, visual change and edema is preeclampsia with severe features.

10. A 50 year old treated six weeks for "mechanical back pain" wakes at night, has lost 4 kg, ESR 74 mm/h, Hb 10.8 g/dL and calcium 11.3 mg/dL. Which error has occurred?

A. Availability bias
B. Confirmation of a sensitive test
C. Premature closure
D. Appropriate pattern recognition

C. Premature closure Accepting a diagnosis before it is verified and ignoring failure to improve is premature closure. The labs suggest myeloma.

ONE PAGE

Cram sheet

Everything from chapters 7 and 8 in one place. Cover the right column and see if you can rebuild each row.

Numbers to know

Item	Value	Note
Low back pain mix	Mechanical about 90%, radicular 5 to 10%, serious 1 to 2%	95% of herniations at L4 to L5 or L5 to S1
Flexion rotation test	Normal about 44°; positive about 32° or less	Or a 10° side difference
Migraine	4 to 72 h; aura over 5 min, under 60 min	Cluster 15 to 180 min
Dissection incidence	About 2 to 3 per 100,000 a year	Partial Horner in carotid dissection
ACS with chest wall tenderness	About 1 in 7	Tenderness does not exclude ischemia
Aortic dissection	Arm BP difference over 20 mmHg	Tearing pain, maximal at onset
Zoster	Prodrome 2 to 5 days; antivirals within 72 h of rash	PHN: pain 90 days or more
Cauda equina	Retention about 90%; decompress within about 48 h	Same day MRI
Meyerding	I under 25%; II 25 to 50; III 50 to 75; IV 75 to 100; V ptosis	
Inflammatory back pain	4 of 5 ASAS: sens about 77%, spec about 92%	Onset under 40
AAA	Surveillance 3.0 to 5.4 cm; repair 5.5 cm or growth over 1 cm/yr	Tender: emergency
Scaphoid	Up to a fifth missed on first films	Repeat in 10 to 14 days or MRI
PMR	Over 50 (mean about 70); 15 to 20% have GCA	ESR often over 40 to 50
Cord compression	5 to 10% of cancer patients	Same day whole spine MRI
Kocher (septic hip)	Fever over 38.5 °C, no weight bearing, ESR over 40, WBC over 12,000	

Item	Value	Note
Scoliosis	Observe under 25°; brace 25 to 40 (45); surgery over 45 to 50	Cobb 10° defines
Timed Up and Go	Over about 12 s	Fall risk
Preeclampsia	BP 140/90 or more after 20 weeks	With headache, visual change, RUQ pain

Key terms and comparisons

Pair	How to tell them apart
Radiculopathy vs myelopathy	One level LMN signs versus UMN signs below the level.
Traversing vs exiting root	Posterolateral disc hits the lower number; far lateral hits the upper.
Neurogenic vs vascular claudication	Sitting relieves versus standing still relieves; cycling tolerated versus painful.
BPPV vs vestibular neuritis vs stroke	Seconds and positional; days with abnormal head impulse; continuous with normal head impulse or skew.
Tumor vs infection	Tumor spares the disc (winking owl); infection crosses it.
Perthes vs SCFE	Boy 4 to 8, painless limp versus overweight teen, knee pain, Drehmann sign.
Growing pains vs pathology	Bilateral, between joints, gone by morning versus unilateral, joint, limp, fever.
Primary vs secondary diagnosis	Explains the chief complaint versus changes prognosis or technique.

Dr. Garg Learning · CC BY-SA 4.0
An independent study aid. Not affiliated with or endorsed by the National Board of Chiropractic Examiners.