Study Guide 3

This guide covers the two "ordering" chapters: imaging and the laboratory. The board asks the same three questions in both: does this patient need the study at all, which study answers the question, and what do you do with the result? Work one chapter at a time, study the diagram, copy the tables, then cover the steps of each worked case and talk them through. Every number in the worked cases has been checked; run them yourself. Finish with the self-tests and the cram sheet.

WHAT THIS GUIDE COVERS

- Chapter 5 · red flags for imaging, the Canadian C spine rule and NEXUS, Ottawa rules, pregnancy and children, ALARA, collimation and technique factors, standard and supplemental views, the lateral cervical lines and measurements, normal variants, ABCS, lesion description, the report, MRI, CT, bone scan, ultrasound and DEXA.
- Chapter 6 · dipstick and casts, the CBC and anemia by MCV, white cells, platelets and coagulation, ESR, CRP and autoantibodies, calcium, ALP and the bone patterns, PSA and glucose, stool tests, synovial fluid and crystals, ECG, EEG, nerve conduction and EMG, and predictive values and likelihood ratios.

CHAPTER 5

Imaging Decisions, Protection, Positioning and Report Writing

Read it in full: **Chapter 5 in the textbook**. Practice it: **the Study Guide 3 practice exam** and **the flashcards**.

What to know

Every film should answer a question that will change management. If you cannot write the question in one line, the film is not indicated. Plain films are good for fracture, alignment, advanced degeneration, many bone tumors and congenital anomalies. They are poor for disc herniation, root compression, early infection, ligament and soft tissue injury, and early metastasis, since roughly 30 to 50 percent of trabecular bone must be lost before a lytic lesion shows.

Do not image acute nonspecific spinal pain without red flags: degeneration is common in people without pain, and early imaging brings more procedures and no better recovery. Image for red flags (fracture risk, cancer, infection, cauda equina, progressive deficit, inflammatory back pain, AAA) or after about 4 to 6 weeks of failed care. Cauda equina goes to the emergency department for MRI now, never plain films first.

The **Canadian C spine rule** is sequential. Any high risk factor means image: age 65 or older, a dangerous mechanism (fall from 3 feet or 5 stairs, axial load, high speed or rollover collision, motorized recreational vehicle, bicycle collision) or limb paresthesias. If there is no low risk factor (simple rear end collision, sitting in the ED, ambulatory at any time, delayed onset, no midline tenderness), image. Otherwise test active rotation: 45 degrees each way means no imaging. **NEXUS** needs all five: no midline tenderness, no focal deficit, normal alertness, no intoxication, no distracting injury.

Ask about pregnancy and the last menstrual period before any abdominal or pelvic exposure. A lumbar series gives a fetal dose of about 1 to 4 mGy, well below the 50 to 100 mGy malformation threshold, so never withhold a needed study, but defer elective films and prefer ultrasound or MRI without gadolinium. Children are the most radiosensitive patients.

ALARA for the operator is time, distance and shielding; the inverse square law means doubling distance cuts exposure to one quarter. For the patient, the biggest saving is not taking unnecessary films, then **collimation** (the most effective technical step, which also cuts scatter and improves contrast), filtration (at least 2.5 mm aluminum equivalent above 70 kVp), right kVp and mAs, long SID and correct positioning on the first try. The 15 percent rule: raising kVp 15 percent has the same receptor effect as doubling mAs. Standard SID is 40 inches; 72 inches for lateral cervical, chest and full spine films. Use a grid above about 10 to 12 cm. Watch for digital dose creep.

Long bones and joints need two views at 90 degrees. Know the view for each question: pars defect, oblique lumbar (collar on the Scottie dog); C7 and T1, swimmer's lateral; dens and C1 masses, APOM; scaphoid, PA in ulnar deviation; posterior shoulder dislocation, axillary or scapular Y; sacroiliac joints, Ferguson (25 to 30 degree cephalad tilt); osteochondritis dissecans,

tunnel; patellofemoral joint, sunrise. Flexion and extension views come only after fracture is excluded.

On the lateral cervical film trace four lines (anterior vertebral, George's, spinolaminar, posterior spinous) and measure the ADI (3 mm or less adult, 5 mm child), prevertebral soft tissue (7 mm at C2, 22 mm at C6), the canal (about 13 mm or more; under 10 mm absolute stenosis; Torg ratio under 0.8 suggests stenosis), translation (under 3.5 mm) and angulation (under 11 degrees more than neighbors). Variants are smooth and **corticated**: pseudosubluxation of C2 on C3 (Swischuk line within about 2 mm), os odontoideum, limbus bone, Schmorl node, bone island, block vertebra with a wasp waist, spina bifida occulta.

Search with ABCS (alignment, bone, cartilage, soft tissue) plus hot spots to avoid satisfaction of search. Describe a lesion by location, margin (Lodwick IA geographic with sclerotic rim to III permeative), zone of transition, matrix (osteoid cloudlike, chondroid rings and arcs, fibrous ground glass) and periosteal reaction (solid is slow; lamellated, sunburst and Codman triangle are aggressive). Age leads: under 30 think primary tumor, over 40 metastasis and myeloma. A report has findings, an **impression** and specific recommendations; critical findings are phoned and documented.

MRI for soft tissue, marrow, nerve, cord and early infection; CT for bone detail and complex fracture; bone scan as a sensitive skeletal survey, but often cold in **multiple myeloma**; ultrasound for tendons, vessels and fluid; DEXA for density. On T1 fat is bright, and dark marrow means replacement; on T2 water is bright; STIR shows edema. "The disc crosses the infection, the tumor respects the disc." Plain films lag 1 to 3 weeks (osteomyelitis about 10 to 14 days). T score: minus 1.0 or higher normal, between minus 1.0 and minus 2.5 osteopenia, minus 2.5 or lower osteoporosis; use the lowest site. Z score of minus 2.0 or lower means search for a secondary cause.

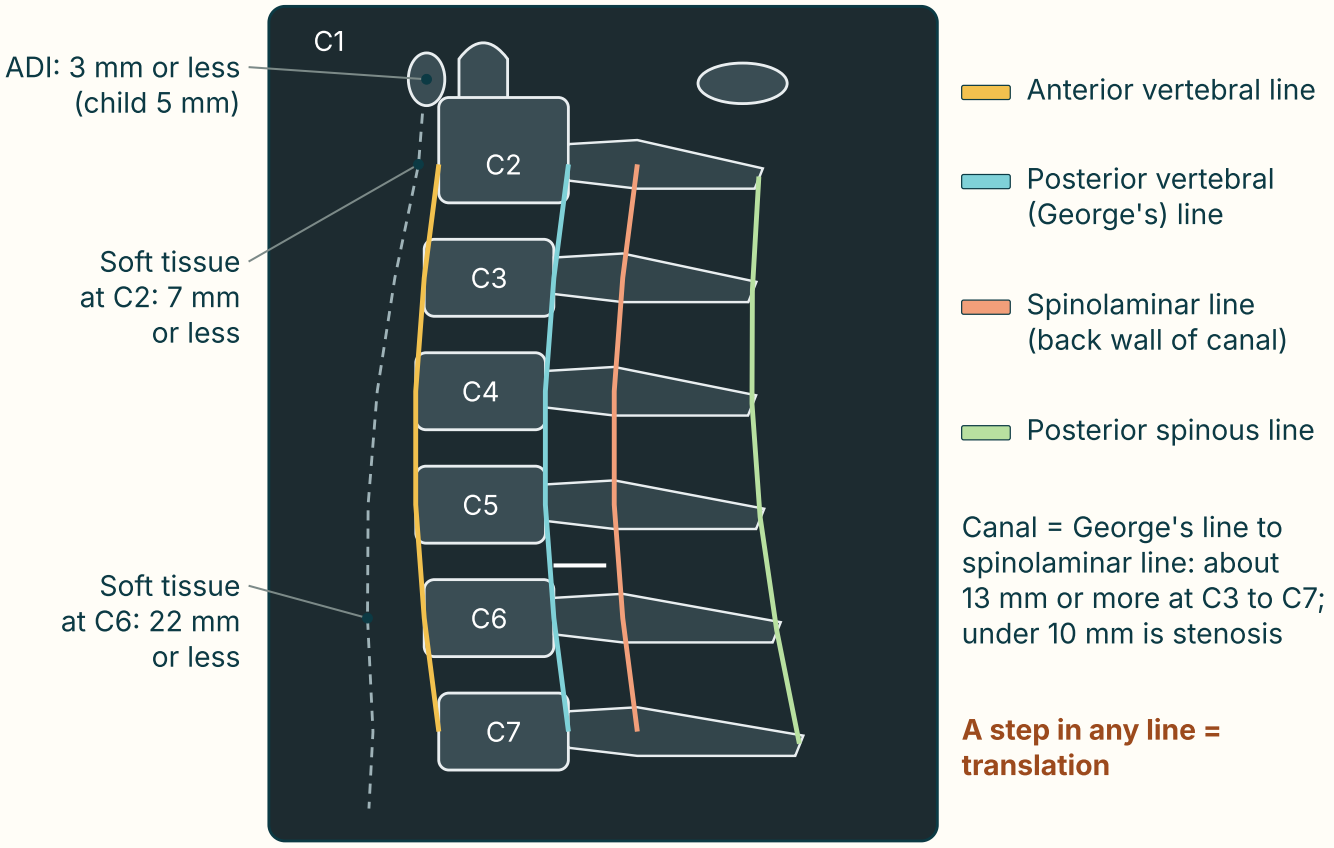

The lateral cervical film, drawn as lines. Trace four smooth curves and measure the ADI, the canal and the prevertebral soft tissue on every trauma film. Soft tissue swelling may be the only sign of an occult fracture.

LOCK THESE IN

- Image only when the answer could change care; no films for acute nonspecific pain.
- Canadian C spine: 65 or older, dangerous mechanism or paresthesias means image.
- Collimation is the most effective technical dose reducer and improves contrast.
- Inverse square: double the distance, one quarter the exposure. 15% kVp equals doubling mAs.
- ADI 3 mm adult, 5 mm child; soft tissue 7 mm at C2, 22 mm at C6.
- Corticated and smooth means variant; sharp, noncorticated and tender means injury.
- Bone scan is cold in myeloma; cauda equina needs emergency MRI.
- T score minus 2.5 or lower is osteoporosis; Z score for younger patients.

The view that answers the question

Question	View	Note
Pars defect	Oblique lumbar	Collar on the Scottie dog neck
C7 and T1 hidden	Swimmer's lateral	Or CT if high risk
Dens, C1 lateral masses	APOM	Overhang over 7 mm: Jefferson fracture
Ligamentous instability	Flexion and extension laterals	Only after fracture is excluded
Radicular arm symptoms	Cervical obliques	Foramina, uncovertebral spurs
Sacroiliac joints, L5 to S1	Ferguson (25 to 30° cephalad)	Sacroiliitis, transitional segment
Occult scaphoid fracture	PA in ulnar deviation	Repeat in 10 to 14 days or MRI
Posterior shoulder dislocation	Axillary or scapular Y	AP can miss it
Osteochondritis dissecans	Tunnel (intercondylar)	Femoral condyle
Ankle joint space, syndesmosis	Mortise (15 to 20° internal rotation)	Stress views for instability

Technique and measurements

Item	Value	Point
SID	40 in (100 cm); 72 in (180 cm) lateral cervical, chest, full spine	Longer SID, less magnification
15 percent rule	+15% kVp = 2 × mAs	Same receptor exposure
Grid	Parts over about 10 to 12 cm	Extremities without a grid
Filtration	At least 2.5 mm Al equivalent above 70 kVp	Removes low energy photons
Fetal dose, lumbar series	About 1 to 4 mGy	Malformation threshold 50 to 100 mGy
ADI	3 mm adult; 5 mm child	Transverse ligament
Canal C3 to C7	About 13 mm; under 10 mm absolute stenosis	Torg under 0.8 suggests stenosis
Instability	Translation 3.5 mm; angulation 11°	White and Panjabi
Compression fracture	Anterior height loss over about 20%	Thoracic lateral
Sacral base angle	About 41° (26 to 57)	Ferguson's angle
DEXA T score	−1.0 normal; to −2.5 osteopenia; ≤ −2.5 osteoporosis	Use the lowest site

Worked cases

WORKED CASE 1 · THE CANADIAN C SPINE RULE STEP BY STEP

A 41 year old was rear ended at low speed, walked around the scene, and developed neck pain the next morning. There is no midline tenderness and no arm symptoms. She rotates 50 degrees left and right.

STEP 1 · HIGH RISK FACTORS?

Under 65, no dangerous mechanism, no paresthesias: none.

STEP 2 · LOW RISK FACTOR?

Simple rear end collision, ambulatory, delayed onset, no midline tenderness: yes, so range of motion may be tested safely.

STEP 3 · ACTIVE ROTATION

50 degrees each way exceeds 45.

STEP 4 · CONCLUDE

No imaging is needed. Change one fact (age 71, a fall down five stairs, arm paresthesias) and she must be imaged before any cervical manipulation.

WORKED CASE 2 · DISTANCE AND DOSE

An operator stands 1 meter from a source of scatter during a fluoroscopic positioning check. How does exposure change at 2 meters and at 3 meters?

STEP 1 · RECALL THE LAW

Intensity is proportional to $1 \div \text{distance}^2$.

STEP 2 · AT 2 M

$(1 \div 2)^2 = 1/4$ of the exposure.

STEP 3 · AT 3 M

$(1 \div 3)^2 = 1/9$, about 11 percent.

STEP 4 · THE PRACTICAL RULE

Stand behind the barrier, never hold a patient, and remember that scatter from the patient is the main source of operator dose.

WORKED CASE 3 · WRITING AN IMPRESSION AND RECOMMENDATIONS

A 15 year old soccer player has six weeks of aching above the left knee, now waking him at night. The film shows a poorly defined mixed lesion of the distal femoral metaphysis with cloudlike density into the soft tissue, a sunburst reaction and a Codman triangle.

STEP 1 · DESCRIBE

Metaphyseal, ill defined (wide zone of transition), osteoid matrix, aggressive periosteal reaction, soft tissue extension.

STEP 2 · USE AGE

Under 30 with an aggressive lesion: primary bone tumor.

STEP 3 · IMPRESSION

"Aggressive bone forming lesion of the distal femoral metaphysis, most consistent with osteosarcoma; differential Ewing sarcoma, osteomyelitis."

STEP 4 · RECOMMENDATIONS

MRI of the entire femur and urgent orthopedic oncology referral within days, communicated directly to the family and documented. No local biopsy outside the sarcoma center.

WORKED CASE 4 · READING A DEXA REPORT

A 62 year old woman has a lumbar T score of −1.6 and a femoral neck T score of −2.7. Her lumbar film shows large anterior osteophytes.

STEP 1 · PICK THE SITE

Use the lowest T score: −2.7 at the femoral neck.

STEP 2 · CLASSIFY

−2.7 is at or below −2.5: osteoporosis.

STEP 3 · EXPLAIN THE MISMATCH

Spurs, aortic calcification and compression fractures falsely raise lumbar values.

STEP 4 · ACT

Refer for management and fracture risk (FRAX); avoid forceful thrust techniques and favor low force methods.

TRAPS PEOPLE FALL INTO

- **Ordering films to "see what is out of place."** Acute nonspecific pain without red flags does not need imaging.
- **Testing rotation in a high risk patient.** Age 65 or older ends the Canadian rule: image first, move the neck later.
- **Trusting a normal film in a cancer patient with night pain.** Lytic lesions hide until 30 to 50 percent of bone is lost. Get MRI.
- **Choosing a bone scan for myeloma.** Myeloma is often cold. Use electrophoresis plus skeletal survey, low dose CT or MRI.
- **Calling a corticated corner fragment a fracture.** A limbus bone has corticated margins and a matching defect.
- **Stopping at the first abnormality.** Satisfaction of search. Finish ABCS and the hot spots: dens, apices, aorta, hips, corners.
- **Writing findings with no recommendation.** Findings describe, the impression concludes, recommendations act.
- **Using the lumbar T score when the hip is lower.** Use the lowest site; degeneration falsely raises the spine.

Chapter 5 self-test · ten items

1. A 36 year old has had mechanical low back pain for 12 days with no leg symptoms, no trauma and a normal neurologic exam. He asks for x-rays. What is the best course?

A. Lumbar MRI without contrast
B. Treat and reassess without imaging
C. Flexion and extension lumbar films
D. AP and lateral lumbar films today

B. Treat and reassess without imaging Acute nonspecific low back pain without red flags does not warrant imaging. Reconsider after 4 to 6 weeks of failed care or a new red flag.

2. A 70 year old slipped on two steps, has midline C5 tenderness and normal arm sensation, and asks for an adjustment. Under the Canadian C spine rule, what is required?

A. Imaging before any range of motion testing
B. Treatment now and films if it does not improve
C. NEXUS screening before deciding on imaging
D. Active rotation testing to 45 degrees first

A. Imaging before any range of motion testing Age 65 or older is a high risk factor that mandates imaging. Do not test rotation or manipulate.

3. Which single technical measure most reduces patient dose and also improves contrast?

A. A larger focal spot
B. A higher grid ratio
C. A longer exposure time
D. Tight collimation

D. Tight collimation Collimation shrinks the irradiated volume, cutting both dose and scatter. A grid improves contrast but needs more exposure.

4. If an operator moves from 1 meter to 2 meters from a source, exposure changes to what fraction?

A. One half
B. One third
C. One quarter
D. One eighth

C. One quarter By the inverse square law, $(1 \div 2)^2 = 1/4$.

5. Raising kVp by 15 percent has about the same effect on receptor exposure as which change?

A. Halving the mAs
B. Removing the grid
C. Doubling the SID
D. Doubling the mAs

D. Doubling the mAs This is the 15 percent rule. Higher kVp also lowers skin dose for the same receptor exposure.

6. A trauma lateral cervical film does not show C7 and T1 because of the shoulders. What should be added?

A. Flexion and extension views
B. An APOM view
C. A swimmer's lateral view
D. A Ferguson view

C. A swimmer's lateral view The cervicothoracic junction must be seen on every trauma series. Flexion and extension come only after fracture is excluded.

7. An adult's atlantodental interval measures 5 mm on the lateral film. Which condition is a classic cause?

A. Degenerative disc disease at C5
B. Rheumatoid arthritis
C. Diffuse idiopathic skeletal hyperostosis
D. A congenital block vertebra

B. Rheumatoid arthritis Over 3 mm in an adult means transverse ligament insufficiency: trauma, RA, Down syndrome, ankylosing spondylitis.

8. A smooth, triangular, corticated fragment sits at the anterosuperior corner of L4 with no history of trauma. What is it most likely?

A. A limbus bone
B. A teardrop fracture
C. A Schmorl node
D. A bone island

A. A limbus bone Disc material herniating under the ring apophysis leaves a corticated corner fragment with a matching defect.

9. A 68 year old has back pain, anemia, an ESR of 96 mm/h and hypercalcemia. Which study is the poor choice?

A. Serum protein electrophoresis
B. Low dose whole body CT
C. Urine protein electrophoresis
D. A technetium bone scan

D. A technetium bone scan This suggests multiple myeloma, which is often cold on bone scan because it suppresses osteoblasts.

10. A 63 year old woman has a lumbar T score of −1.9 and a femoral neck T score of −2.6. What is the diagnosis?

A. Low Z score for age
B. Osteoporosis
C. Normal bone density
D. Osteopenia

B. Osteoporosis Use the lowest site. −2.6 at the femoral neck is at or below −2.5.

CHAPTER 6

Clinical Laboratory and Special Studies in Cases

Read it in full: **Chapter 6 in the textbook**. Practice it: **the Study Guide 3 practice exam** and **the flashcards**.

What to know

A lab value means nothing until it is attached to a patient. On the urinalysis, **casts** localize disease to the kidney: red cell casts mean glomerulonephritis, white cell casts pyelonephritis or interstitial nephritis, fatty casts nephrotic syndrome, muddy brown casts acute tubular necrosis, waxy and broad casts advanced CKD. Nitrite is specific but insensitive for infection; leukocyte esterase means pyuria. Dipstick blood with few red cells means hemoglobin or myoglobin (check CK for

rhabdomyolysis). The dipstick detects albumin, not light chains. Specific gravity fixed near 1.010 suggests CKD.

Crystals: calcium oxalate (envelope) in most stones, uric acid (rhomboid) with gout, struvite ("coffin lid") with urease infection and staghorn calculi, cystine (hexagonal) in cystinuria. Flank pain with hematuria and no casts suggests a stone; with fever and white cell casts, pyelonephritis; painless gross hematuria in an older smoker is bladder cancer until proven otherwise.

Read the CBC by pattern. Anemia is classified by **MCV** (80 to 100 fL). Microcytic: iron deficiency (ferritin is the single best test, under about 30 ng/mL), anemia of chronic disease, thalassemia trait (Mentzer index MCV ÷ RBC under 13, normal RDW). Iron deficiency in a man or postmenopausal woman means GI blood loss, often colon cancer, until proven otherwise. Macrocytic: B12 deficiency (methylmalonic acid and homocysteine raised, subacute combined degeneration, sometimes before anemia) or folate deficiency (homocysteine only). Normocytic: high reticulocytes mean loss or hemolysis; low mean underproduction, including marrow infiltration.

WBC 4,500 to 11,000; platelets 150,000 to 450,000. Bleeding risk rises below about 50,000 platelets, so forceful manual therapy is avoided. Neutrophilia with a left shift means bacterial infection; an ANC under 500 with fever is an emergency; blasts or two low cell lines need same day referral. PT and INR monitor warfarin (extrinsic); aPTT monitors heparin (intrinsic).

ESR rises slowly; its upper limit is about age ÷ 2 for men and (age + 10) ÷ 2 for women. Over 100 mm/h points to infection, myeloma or other malignancy, or giant cell arteritis. **CRP** rises in 6 to 8 hours, peaks at about 48, and tracks treatment better. A patient over 50 with new headache, jaw claudication or visual change and a high ESR has giant cell arteritis until proven otherwise: same day steroids. RF is sensitive but not specific; **anti CCP** is about 95 percent specific for RA. A negative ANA nearly excludes lupus. HLA B27 is in about 90 percent of white patients with AS but also 6 to 8 percent of everyone, so it only supports a suspected diagnosis.

Corrected calcium = measured + 0.8 × (4.0 − albumin). Outpatient hypercalcemia is usually hyperparathyroidism; in sick patients, malignancy. ALP with GGT means liver; ALP alone means bone (growth, healing fracture, Paget disease, blastic metastasis). **Myeloma** gives high calcium,

anemia, kidney injury and bone pain (CRAB) with a high ESR but a **normal ALP**. Osteoporosis has normal chemistries. Urate saturates at about 6.8 mg/dL but can be normal during a gout flare. Diabetes: fasting glucose 126 or more, HbA1c 6.5 percent or more.

A positive stool test means colonoscopy, never a repeat stool test. FIT detects human globin and is specific for lower GI bleeding; fecal calprotectin separates IBD from IBS. Reactive arthritis follows enteric (Salmonella, Shigella, Campylobacter, Yersinia) or Chlamydia infection by 1 to 4 weeks. Synovial fluid: normal under 200 WBC; noninflammatory 200 to 2,000; inflammatory 2,000 to about 50,000; **septic usually over 50,000** with over 75 to 90 percent neutrophils. Urate needles are strongly negatively birefringent; CPPD rhomboids weakly positive. Crystals do not exclude infection, and Gram stain is positive in only about half of septic joints.

ECG paper: small box 0.04 s, large box 0.20 s; rate = 300 ÷ large boxes between R waves. PR 0.12 to 0.20 s, QRS under 0.12 s, QTc under about 0.44 s (men) and 0.46 s (women). VF, VT, STEMI, complete heart block, Mobitz II and hyperkalemia are emergencies; Wenckebach is usually benign; new AF needs same day care. In electrodiagnosis, a root lesion is proximal to the dorsal root ganglion, so the **SNAP is normal** despite numbness; plexus and nerve lesions reduce it. Fibrillations take about 3 to 6 weeks in limb muscles, so study at about 3 weeks or later. PPV falls as prevalence falls; LR×pretest odds = posttest odds.

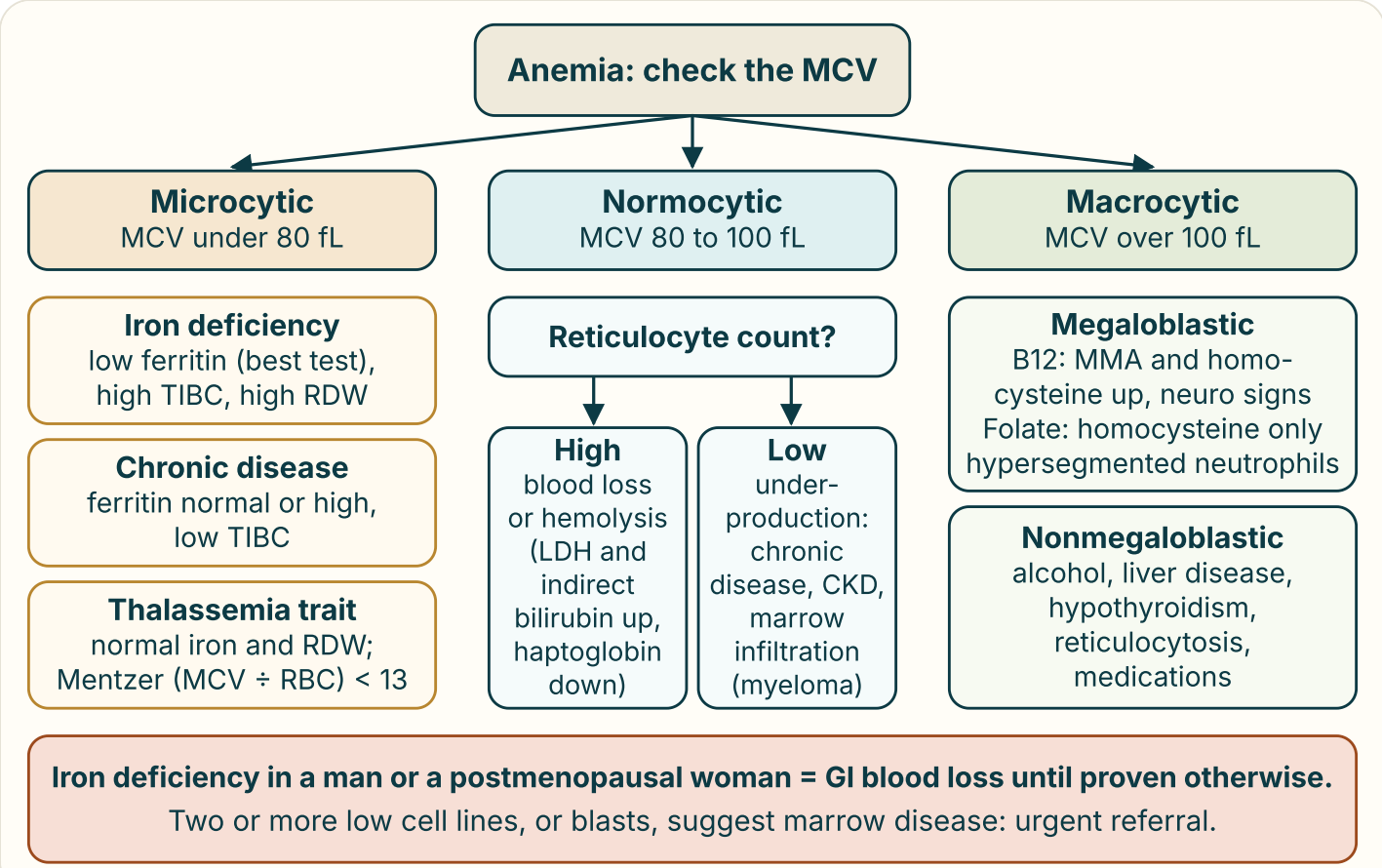

Anemia by MCV. The MCV sorts anemia into three short lists. In normocytic anemia, the reticulocyte count shows whether the marrow is responding (loss or destruction) or failing (underproduction).

LOCK THESE IN

- Casts mean kidney: RBC casts glomerulonephritis, WBC casts pyelonephritis.
- Ferritin is the best iron test; iron deficiency in a man means colonoscopy.
- B12 deficiency: macrocytosis, MMA and homocysteine up, dorsal column signs.
- ESR over 100: infection, myeloma, malignancy, giant cell arteritis.
- Myeloma: high calcium and ESR, anemia, kidney injury, normal ALP, cold bone scan.
- Synovial WBC over about 50,000 with neutrophils is septic until proven otherwise.
- Urate needles negative; CPPD rhomboids weakly positive; crystals do not exclude sepsis.
- Radiculopathy: normal SNAP, myotomal and paraspinal denervation after about 3 weeks.

Lab values and formulas

Test	Reference or rule	Key point
Hemoglobin	Men 13.5 to 17.5; women 12.0 to 15.5 g/dL	Hematocrit about 3 × Hb
MCV	80 to 100 fL	Classifies anemia
Platelets	150,000 to 450,000 per µL	Under 50,000: avoid forceful therapy
ESR upper limit	Men age ÷ 2; women (age + 10) ÷ 2	Over 100: short list
CRP	Under about 10 mg/L	Rises 6 to 8 h, peaks 48 h
Calcium	8.5 to 10.5 mg/dL	Corrected = Ca + 0.8 × (4.0 − albumin)
ALP	About 40 to 130 U/L	With GGT: liver; alone: bone
Urate	Saturates at about 6.8 mg/dL	May be normal in a flare
PSA	Over about 4 ng/mL prompts evaluation	Prostate specific, not cancer specific
Glucose	Fasting 126+ or HbA1c 6.5%+ is diabetes	Prediabetes 100 to 125 or 5.7 to 6.4%
BUN : creatinine	Over 20 suggests prerenal	eGFR under 30 changes drug choice
Mentzer index	MCV ÷ RBC under 13	Thalassemia trait
ECG	Small box 0.04 s; large 0.20 s	Rate = 300 ÷ large boxes
Nerve conduction	Arms 50 m/s or faster; legs 40 m/s or faster	Demyelination slows; axonal loss lowers amplitude

Synovial fluid classes

Class	WBC per µL	Neutrophils	Causes
Normal	Under 200	Under 25%	None
I, noninflammatory	200 to 2,000	Under 25%	Osteoarthritis, trauma, Charcot joint
II, inflammatory	2,000 to about 50,000	Over 50%	RA, gout, CPPD, reactive, psoriatic, SLE
III, septic	Usually over 50,000	Over 75 to 90%	S. aureus; gonococcus in young adults
IV, hemorrhagic	Variable	Variable	Trauma (fat droplets: fracture), hemophilia

Worked cases

WORKED CASE 1 · WHY LOW PREVALENCE FOOLS A GOOD TEST

A test with sensitivity 0.90 and specificity 0.80 is applied to 1,000 patients, 10 percent of whom have the disease. What are the PPV and NPV?

STEP 1 · SPLIT THE GROUP

100 have the disease; 900 do not.

STEP 2 · FILL THE CELLS

True positives 0.90 × 100 = 90; false negatives 10. True negatives 0.80 × 900 = 720; false positives 180.

STEP 3 · PPV

90 ÷ (90 + 180) = 90 ÷ 270 = **33.3%**. Only a third of positives are right.

STEP 4 · NPV

720 ÷ (720 + 10) = 720 ÷ 730 = **98.6%**. A negative is very reassuring.

STEP 5 · THE LESSON

As prevalence falls, PPV falls and NPV rises, while sensitivity and specificity stay the same.

WORKED CASE 2 · PRETEST ODDS TO POSTTEST PROBABILITY

A test for a disc herniation has sensitivity 0.85 and specificity 0.60. Your pretest estimate is 50 percent and the test is negative.

STEP 1 · LR−

(1 − 0.85) ÷ 0.60 = 0.15 ÷ 0.60 = 0.25.

STEP 2 · PRETEST ODDS

50% is odds of 0.50 ÷ 0.50 = 1.

STEP 3 · POSTTEST ODDS

1 × 0.25 = 0.25.

STEP 4 · BACK TO PROBABILITY

0.25 ÷ (1 + 0.25) = **20%**. Lower, but not excluded: MRI is still right if weakness progresses.

WORKED CASE 3 · THE CRAB PATTERN

A 70 year old man has two months of night thoracolumbar pain and a 5 kg weight loss. Hemoglobin 10.2 g/dL, normal MCV, ESR 96 mm/h, calcium 11.5 mg/dL with albumin 4.0, creatinine 1.9 mg/dL, normal ALP, urine dipstick protein negative.

STEP 1 · CORRECT THE CALCIUM

Albumin is 4.0, so the correction adds 0.8 × (4.0 − 4.0) = 0; calcium stays 11.5, high.

STEP 2 · LIST THE CRAB FEATURES

Calcium high, renal injury, anemia, bone pain: all four.

STEP 3 · EXPLAIN THE NORMAL RESULTS

ALP is normal because myeloma suppresses osteoblasts. The dipstick misses light chains.

STEP 4 · ACT

Serum protein electrophoresis with immunofixation and free light chains, prompt referral, skeletal survey or low dose CT or MRI (not a bone scan), and no manipulation until the skeleton is assessed.

WORKED CASE 4 · A HOT KNEE WITH CRYSTALS

A 67 year old man with diabetes has a hot, swollen knee and a temperature of 38.4 °C. Aspirate: turbid, 78,000 WBC per µL, 92 percent neutrophils, a few CPPD crystals, Gram stain negative.

STEP 1 · CLASSIFY THE FLUID

Over 50,000 with over 90 percent neutrophils: septic range.

STEP 2 · WEIGH THE CRYSTALS

CPPD crystals show crystal disease, but crystals and infection coexist.

STEP 3 · WEIGH THE GRAM STAIN

It is positive in only about half of septic joints, so negative does not reassure.

STEP 4 · ACT

Same day medical care for blood cultures, IV antibiotics and drainage. No manual therapy to the knee.

TRAPS PEOPLE FALL INTO

- **Reassuring with a negative dipstick protein in suspected myeloma.** The dipstick detects albumin, not light chains. Order electrophoresis.
- **Starting iron without finding the source.** Iron deficiency in a man or postmenopausal woman needs a GI workup.
- **Ruling out gout with a normal urate.** Urate can be normal in a flare. Crystals in fluid make the diagnosis.
- **Calling a hot joint gout because crystals are present.** Crystals do not exclude infection. Culture it.
- **Screening vague aches with an ANA.** Low specificity means false positives and a testing cascade.
- **Using HLA B27 as a screening test.** It is in 6 to 8 percent of the population. It only supports a suspected diagnosis.
- **Doing EMG on day 5.** Limb fibrillations take about 3 to 6 weeks; study at about 3 weeks or later.
- **Repeating a positive stool test.** A positive FIT means colonoscopy.

Chapter 6 self-test · ten items

1. A 25 year old woman has fever, right flank pain and dysuria. Urinalysis shows nitrite and leukocyte esterase with white cell casts. What is the diagnosis?

A. Acute cystitis
B. Glomerulonephritis
C. Acute pyelonephritis
D. A ureteral stone

C. Acute pyelonephritis White cell casts place the infection in the kidney. She needs same day medical care.

2. A 64 year old man with back pain has Hb 10.0 g/dL, MCV 71 fL, high RDW and ferritin 7 ng/mL. What is the most appropriate next step?

A. Start oral iron and continue spinal care
B. Refer for colonoscopy to find GI blood loss
C. Order HLA B27 and sacroiliac films
D. Recheck the CBC in six months

B. Refer for colonoscopy to find GI blood loss Iron deficiency in an older man is GI blood loss, often colon cancer, until proven otherwise.

3. A 72 year old woman has macrocytic anemia, lost vibration sense in both feet and a positive Romberg. Which result confirms the likely cause?

A. Low B12 with raised methylmalonic acid
B. Low ferritin with a high RDW
C. Low folate with raised methylmalonic acid
D. High reticulocytes with low haptoglobin

A. Low B12 with raised methylmalonic acid B12 deficiency raises both MMA and homocysteine and causes subacute combined degeneration. Folate deficiency raises only homocysteine.

4. A microcytic anemia has MCV 64 fL, normal ferritin, normal RDW and RBC 6.2 million per µL. What is most likely?

A. Iron deficiency anemia
B. Anemia of chronic disease
C. Sideroblastic anemia
D. Thalassemia trait

D. Thalassemia trait Mentzer index 64 ÷ 6.2 = 10.3, under 13, with normal iron and RDW points to thalassemia trait.

5. A 74 year old woman has a new temporal headache, jaw pain when chewing and an ESR of 90 mm/h. What should happen today?

A. Temporal artery biopsy before any treatment
B. A CRP in two weeks to confirm the trend
C. Same day referral for corticosteroids
D. Upper cervical manipulation and recheck

C. Same day referral for corticosteroids Suspected giant cell arteritis needs steroids now to prevent blindness; biopsy can follow.

6. Which test best confirms rheumatoid arthritis in a patient with symmetric small joint synovitis?

A. Antinuclear antibody
B. Rheumatoid factor
C. HLA B27 typing
D. Anti CCP antibody

D. Anti CCP antibody Anti CCP is about 95 percent specific and predicts erosive disease. RF is positive in many other conditions.

7. A 71 year old man has a bowed, enlarged tibia, ALP three times normal with normal GGT and normal calcium. What is the most likely diagnosis?

A. Osteoporosis
B. Paget disease of bone
C. Primary hyperparathyroidism
D. Multiple myeloma

B. Paget disease of bone Very high bone origin ALP with normal calcium and bony enlargement is classic Paget disease. Myeloma has a normal ALP.

8. Fluid from a swollen first MTP joint has 24,000 WBC per µL and needle shaped, strongly negatively birefringent crystals. What is the diagnosis?

A. Acute gout
B. Pseudogout (CPPD)
C. Osteoarthritis
D. Septic arthritis

A. Acute gout Monosodium urate needles in an inflammatory fluid are diagnostic of gout. CPPD crystals are rhomboid and weakly positive.

9. An ECG shows a PR that lengthens beat by beat until a P wave is not conducted, then repeats. What is the rhythm?

A. Atrial flutter with 2:1 block
B. Mobitz II, which needs urgent referral
C. Mobitz I (Wenckebach), usually benign
D. Complete heart block, emergency

C. Mobitz I (Wenckebach), usually benign Progressive PR lengthening with a dropped beat is Wenckebach, an AV nodal block. Mobitz II has a constant PR.

10. A screening test (sensitivity 95 percent, specificity 90 percent) is used where 1 percent have the disease. About what share of positives are true?

A. About 9 percent
B. About 50 percent
C. About 95 percent
D. About 90 percent

A. About 9 percent Per 1,000: 9.5 true positives and 99 false positives, so PPV = 9.5 ÷ 108.5, about 9 percent.

ONE PAGE

Cram sheet

Everything from chapters 5 and 6 in one place. Cover the right column and see if you can rebuild each row.

Numbers to know

Item	Value	Note
Lytic lesion visibility	30 to 50% of trabecular bone lost	Films lag MRI by 1 to 3 weeks
Imaging after failed care	About 4 to 6 weeks	Sooner for red flags
Canadian C spine	65+, dangerous mechanism, paresthesias	Rotate 45° each way if low risk
Fetal dose, lumbar series	About 1 to 4 mGy	Threshold 50 to 100 mGy
Inverse square	Double distance: 1/4 exposure	Triple: 1/9
15 percent rule	+15% kVp = 2 × mAs	SID 40 in; 72 in lateral cervical
Lateral cervical	ADI 3 mm (child 5); soft tissue 7 mm C2, 22 mm C6	Canal 13 mm; under 10 stenosis
Instability	Translation 3.5 mm; angulation 11°	Jefferson: overhang over 7 mm
DEXA	T ≤ −2.5 osteoporosis	Z ≤ −2.0: secondary cause
Osteomyelitis on film	About 10 to 14 days	MRI positive in a day or two
ESR limit	Men age/2; women (age + 10)/2	Over 100: short list
Corrected calcium	Ca + 0.8 × (4.0 − albumin)	Normal 8.5 to 10.5 mg/dL
Platelets	Under 50,000: avoid forceful therapy	Under 10,000 to 20,000: spontaneous bleeding
Synovial fluid	Normal under 200; septic usually over 50,000	Gram stain positive in about half
ECG	PR 0.12 to 0.20 s; QRS under 0.12 s	Small box 0.04 s; rate = 300 ÷ boxes
EMG timing	Paraspinals 1 to 2 wk; limbs 3 to 6 wk	Study at 3 weeks or later
Diabetes	Fasting 126+; HbA1c 6.5%+	Prediabetes 100 to 125; 5.7 to 6.4%

Formulas

Name	Formula	Meaning
PPV	TP ÷ (TP + FP)	Falls as prevalence falls
NPV	TN ÷ (TN + FN)	Rises as prevalence falls
Posttest odds	pretest odds × LR	Probability = odds ÷ (1 + odds)
Mentzer index	MCV ÷ RBC	Under 13: thalassemia trait
Heart rate (irregular)	QRS in 10 s × 6	Regular: 300 ÷ large boxes

Key terms and comparisons

Pair	How to tell them apart
Variant vs fracture	Smooth, corticated, often bilateral versus sharp, noncorticated, tender with swelling.
Infection vs tumor on MRI	The disc crosses infection; tumor respects the disc.
Bone scan vs myeloma	Bone scan is a sensitive survey but often cold in myeloma.
Liver vs bone ALP	ALP with GGT: liver. ALP alone: bone.
Gout vs CPPD	Needles, strongly negative versus rhomboids, weakly positive.
Mobitz I vs II	Lengthening PR then drop (benign) versus constant PR then sudden drop (dangerous).
Root vs nerve on NCS	Normal SNAP (proximal to DRG) versus reduced SNAP.

Dr. Garg Learning · CC BY-SA 4.0
An independent study aid. Not affiliated with or endorsed by the National Board of Chiropractic Examiners.