Study Guide 2

This guide covers the two neuromusculoskeletal examination chapters. The board rarely asks you to name a test; it gives you a patient and asks which test comes next and what the result means. So learn each test with its value: does a negative rule out, or does a positive rule in? Work one chapter at a time, study the diagram, copy the tables, then cover the steps of each worked case. Finish with the ten board style items per chapter and the cram sheet.

WHAT THIS GUIDE COVERS

- Chapter 3 · posture and scoliosis screening, gait deviations, cervical safety screens, the Wainner and myelopathy clusters, thoracic, rib and thoracic outlet tests, red flag thoracic pain, the SLR family and slump, the Laslett cluster and the hip screen, Waddell signs, end feel, palpation reliability and PARTS.
- Chapter 4 · shoulder, elbow, wrist and hand tests, hip, knee, ankle and foot tests, the Ottawa rules, root level screening, upper versus lower motor neuron lesions, cranial nerves, vascular procedures, the ABI, Wells criteria, sensitivity, specificity and likelihood ratios, and localization.

CHAPTER 3

The Neuromusculoskeletal Examination of the Spine

Read it in full: **Chapter 3 in the textbook**. Practice it: **the Study Guide 2 practice exam** and **the flashcards**.

What to know

On Part III the spinal exam arrives as a patient with a story, and the item asks which test comes next, what a positive result means, and whether this person can be treated safely. Observe posture and gait before the patient knows the exam has started. From the side, the ideal plumb line passes through the ear, the acromion, the greater trochanter and just in front of the knee and the lateral malleolus. Anterior head carriage, upper crossed syndrome (tight upper trapezius and pectorals, weak deep neck flexors) and lower crossed syndrome (tight hip flexors, weak abdominals and gluteus maximus) are the posture patterns to know.

The **Adams forward bend test** separates structural from functional scoliosis. In a structural curve the vertebral bodies rotate toward the convexity and push the ribs back into a rib hump on the convex side; a functional curve straightens with flexion. A scoliometer reading of about 7 degrees (roughly a 20 degree Cobb angle) warrants a standing PA radiograph. The usual pattern is a right thoracic curve in an adolescent girl. A left thoracic curve, a painful curve, rapid progression or neurologic signs call for MRI and referral.

Each gait deviation belongs to a phase and predicts a lesion. Stance is about 60 percent of the cycle and swing about 40 percent. A **Trendelenburg** drop is named for the stance leg: standing on the right, a left pelvic drop means a weak right gluteus medius (superior gluteal nerve, L5). **Steppage** with foot slap means weak dorsiflexors: L5 root or common fibular nerve. Hip abduction and foot inversion are weak in L5 radiculopathy but spared in fibular palsy. Spastic gait points to the cord; ataxic gait to the cerebellum or dorsal columns.

In the neck, safety comes before provocation: screen fracture risk, instability (rheumatoid arthritis, Down syndrome, os odontoideum), myelopathy and cervical artery dysfunction first. Spurling is specific (about 0.85 to 0.95) and helps rule radiculopathy in; the **upper limb tension test A** is sensitive (about 0.97) and, when negative, helps rule it out. The **Wainner cluster** is ULTT A positive, ipsilateral rotation under 60 degrees, positive distraction and positive Spurling: three of four gives an LR+ of about 6, all four about 30.

Myelopathy is an upper motor neuron problem: clumsy hands, broad based or spastic gait, nondermatomal numbness, Lhermitte sign, Hoffmann sign, the inverted supinator sign, hyperreflexia, clonus and Babinski. Three of five cluster items (gait deviation, Hoffmann, inverted supinator, Babinski, age over 45) give an LR+ of about 30. Myelopathy means MRI, surgical opinion and no cervical thrust. Positional vertebral artery tests have poor sensitivity and never clear a patient; the history and a neurologic exam do the screening.

Thoracic motion is small because of the rib cage. Chest expansion under about 2.5 cm in a young adult with inflammatory back pain suggests ankylosing spondylitis. Rib springing reproduces costovertebral or costotransverse pain; rib compression that hurts away from the point of pressure suggests fracture. Schepelmann: concave side pain suggests intercostal neuritis, convex side pain pleural or myofascial. Thoracic outlet tests (Adson, costoclavicular, Wright, Roos) count only

when they reproduce symptoms; a pulse change alone is common in healthy people. About 95 percent of thoracic outlet syndrome is neurogenic, usually the lower trunk (C8 to T1). The thoracic spine holds about 70 percent of spinal metastases.

The **straight leg raise** is positive only when it reproduces radiating pain below the knee between about 30 and 70 degrees. It is sensitive (about 0.9), so a negative SLR helps rule out disc herniation. The **crossed SLR** is specific (about 0.9) and helps rule it in. The slump is more balanced (about 0.84 and 0.83). The femoral nerve stretch tests L2 to L4. The modified Schober test should increase at least 5 cm. In the **Laslett cluster**, three of five sacroiliac provocation tests (or two of the first four) suggest the joint; thigh thrust is the most sensitive, distraction the most specific. FABERE groin pain implicates the hip; posterior pain implicates the SI joint.

Waddell signs come in five categories; three or more mark psychosocial distress and a poorer prognosis, never proof of malingering. Among palpation findings, pain provocation has the best interexaminer reliability (moderate kappa) and motion palpation the worst (near chance). An **empty end feel**, where pain stops motion before any resistance, is a red flag. PARTS (pain, asymmetry, range of motion, tone and texture, special tests) builds a segmental diagnosis; documentation needs at least two of the four PART findings, one of them asymmetry or range of motion abnormality.

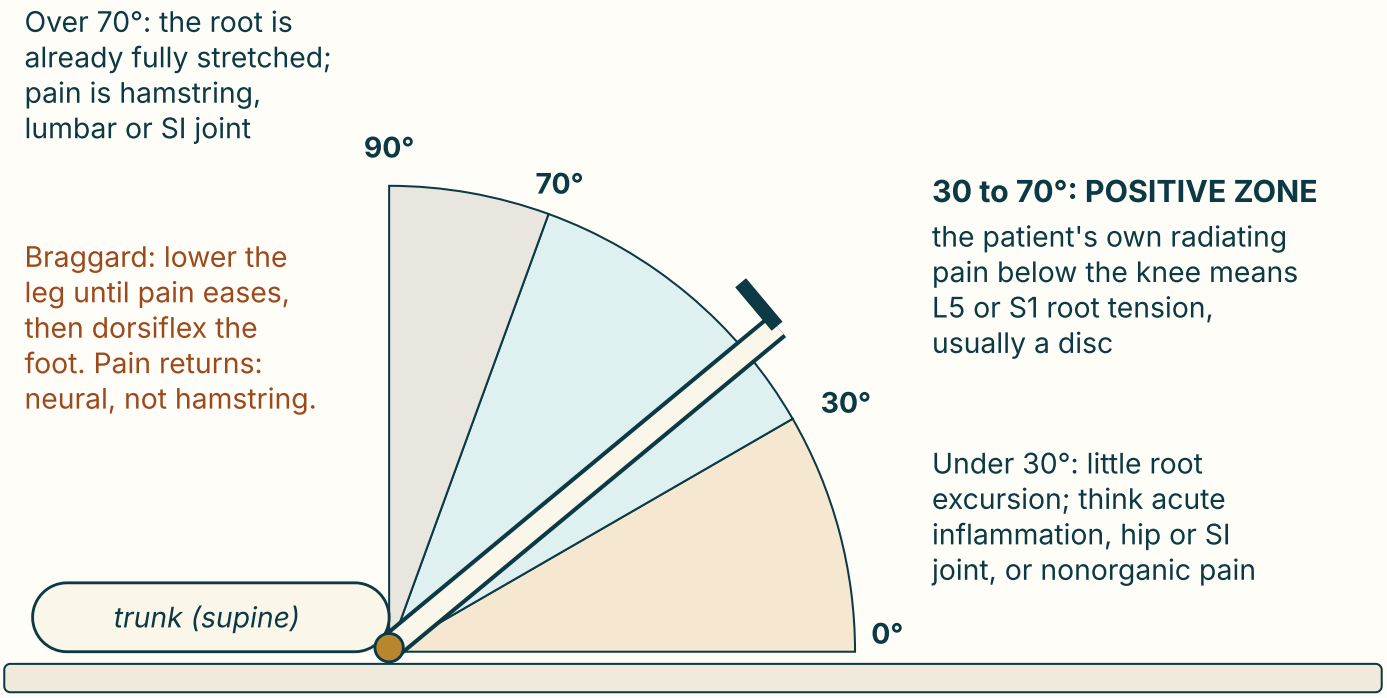

The straight leg raise by angle. Only the patient's own radiating pain below the knee between about 30 and 70 degrees counts as positive. Back pain or hamstring tightness alone does not.

LOCK THESE IN

- Rib hump on Adams means structural; a scoliometer reading of about 7 degrees means radiograph.
- Trendelenburg is named for the stance leg; steppage means weak dorsiflexors (L5 or fibular nerve).
- Spurling rules in, ULTT A rules out; all four Wainner items give an LR+ of about 30.
- Hoffmann, inverted supinator, Lhermitte and spastic gait mean myelopathy: MRI, no thrust.
- Positional artery tests never clear a patient; screen with the 5 Ds and 3 Ns.
- SLR positive only at 30 to 70 degrees with pain below the knee; negative SLR rules out, crossed SLR rules in.
- Laslett: three of five SI provocation tests; FABERE groin pain means hip.
- Pain provocation is the most reliable palpation finding; empty end feel is a red flag.

Tests by value

Test	Positive finding	Value and use
Spurling	Dermatomal arm pain with lateral flexion and compression	Specificity about 0.85 to 0.95: rules in
ULTT A (median bias)	Reproduced symptoms, side to side difference	Sensitivity about 0.97: rules out when negative
Cervical distraction	Relief of arm pain	Specificity about 0.90
Wainner cluster	3 of 4 or 4 of 4 positive	LR+ about 6 or about 30
Myelopathy cluster	3 of 5 positive	LR+ about 30
Sharp Purser	Sliding reduction of the atlas	Specificity about 0.96
SLR	Radiating pain below knee at 30 to 70°	Sensitivity about 0.9, specificity about 0.25
Crossed SLR	Pain in the affected leg when the well leg is raised	Specificity about 0.9
Slump	Symptoms ease when the neck extends	About 0.84 sensitive, 0.83 specific
Laslett cluster	3 of 5, or 2 of the first 4	Sensitivity near 0.9, specificity near 0.8
Modified Schober	Increase under 5 cm on flexion	Restricted flexion; ankylosing spondylitis
Chest expansion	Under about 2.5 cm	Costovertebral AS involvement

Gaits and what they predict

Gait	What you see	Lesion
Trendelenburg	Pelvis drops on the swing side	Weak stance side gluteus medius: L5, superior gluteal nerve
Steppage	High knee lift, foot slap	L5 root, common fibular nerve, neuropathy
Gluteus maximus	Trunk thrown back at contact	Inferior gluteal nerve or S1
Hemiplegic	Circumduction, arm flexed	Upper motor neuron lesion, stroke
Spastic scissoring	Stiff, narrow based, knees cross	Cervical myelopathy, cerebral palsy, MS
Sensory ataxic	Watches and stamps the feet; Romberg positive	Dorsal columns: B12, tabes, neuropathy
Parkinsonian	Stooped, shuffling, small steps	Parkinson disease

Worked cases

WORKED CASE 1 · FOOT DROP: ROOT OR NERVE?

A 47 year old tile setter has low back pain and has started tripping over his left foot. His left foot slaps the floor, and he has knelt and sat cross legged at work for a week.

STEP 1 · NAME THE GAIT

Steppage with foot slap means weak ankle dorsiflexors.

STEP 2 · LIST THE TWO CLASSIC CAUSES

L5 radiculopathy or common fibular nerve palsy at the fibular head.

STEP 3 · RUN THE DECIDING TEST

Test hip abduction (gluteus medius) and foot inversion (tibialis posterior). Both are L5 functions, weak in radiculopathy and spared in fibular palsy.

STEP 4 · ADD THE SUPPORTING FINDINGS

Fibular palsy spares the back, limits numbness to the dorsum of the foot and lateral leg, and gives a Tinel sign at the fibular head.

STEP 5 · PLAN

A progressive motor deficit of either cause needs prompt referral and electrodiagnostic testing.

WORKED CASE 2 · NECK AND ARM PAIN THROUGH THE CLUSTER

A 45 year old hygienist has right neck pain and burning into the lateral forearm and thumb. Right Spurling reproduces the thumb pain, distraction eases it, right rotation is 52 degrees and ULTT A reproduces the arm pain. The brachioradialis reflex is reduced and wrist extension is 4 of 5.

STEP 1 · COUNT THE CLUSTER

ULTT A, rotation under 60 degrees, distraction and Spurling are all positive: four of four, LR+ about 30.

STEP 2 · LOCALIZE

Thumb dermatome, wrist extensor weakness and a reduced brachioradialis reflex point to C6, usually a C5 to C6 disc.

STEP 3 · CHECK FOR CORD SIGNS

No Hoffmann, no gait change, no bilateral symptoms: radiculopathy, not myelopathy.

STEP 4 · PLAN

Conservative care with neurologic re-examination each visit; urgent MRI if weakness progresses or long tract signs appear.

WORKED CASE 3 · BUILDING A SEGMENTAL DIAGNOSIS WITH PARTS

A 30 year old has right neck pain and a suboccipital headache for ten days with no trauma or neurologic signs. Pressure on the right C2 to C3 pillar reproduces her headache, right rotation is 60 degrees, the suboccipitals are hypertonic and motion palpation suggests restricted C2 to C3 rotation.

STEP 1 · P

Tenderness reproduces familiar pain: the most reliable palpation finding.

STEP 2 · R

Regional rotation loss and segmental restriction at C2 to C3.

STEP 3 · T

Hypertonic suboccipital and upper trapezius tissue at the same level.

STEP 4 · CONCLUDE

Several findings converge at one level: right C2 to C3 segmental dysfunction with a cervicogenic headache pattern. Safety screens are clear, so treat and re-examine after care.

TRAPS PEOPLE FALL INTO

- **Naming the Trendelenburg side by the drop.** The weak muscle is on the stance side, opposite the side that drops.
- **Counting back pain on SLR as positive.** Only radiating pain below the knee at 30 to 70 degrees counts.
- **Calling a pulse change on Adson positive.** Thoracic outlet tests count only when they reproduce the patient's symptoms.
- **Clearing a neck with a negative DeKleyn.** Positional tests cannot exclude dissection. History and the neuro exam do.
- **Reading Waddell signs as faking.** Three or more categories mean distress and poorer prognosis, not malingering.
- **Trusting motion palpation alone.** Its interexaminer kappa is near chance. Anchor findings to tenderness and look for agreement.
- **Calling a groin pain FABERE an SI problem.** Groin pain with lost internal rotation means the hip.
- **Reassessing a curve "next year."** A 7 degree or larger scoliometer reading in a growing child needs a radiograph now.

Chapter 3 self-test · ten items

1. Standing on her left leg, a patient's right hemipelvis drops. Which structure is most likely weak?

A. Left gluteus maximus, inferior gluteal nerve
B. Left gluteus medius, superior gluteal nerve
C. Right gluteus medius, superior gluteal nerve
D. Right tensor fasciae latae, femoral nerve

B. Left gluteus medius, superior gluteal nerve The Trendelenburg sign identifies weakness on the stance side. The superior gluteal nerve (L5) supplies gluteus medius.

2. A 12 year old girl has a right thoracic prominence on forward bending, a scoliometer reading of 8 degrees and a normal neurologic exam. What is the next step?

A. Standing PA full spine radiograph
B. Postural exercises and no imaging
C. Recheck the curve in twelve months
D. MRI of the whole spine this week

A. Standing PA full spine radiograph A rotational prominence means a structural curve, and 8 degrees exceeds the 7 degree threshold. A radiograph gives the Cobb angle and Risser grade.

3. Which single test, when negative, best argues against cervical radiculopathy?

A. Cervical distraction test
B. Shoulder depression test
C. Upper limb tension test A
D. Spurling compression test

C. Upper limb tension test A ULTT A has a sensitivity near 0.97, so a negative result helps rule radiculopathy out. Spurling and distraction are specific tests.

4. A 62 year old has dropped keys for months, fastens buttons with difficulty, walks broad based and has bilateral Hoffmann signs. What is the best plan?

A. Repeat Spurling at each visit for progress
B. Cervical rotary thrust and recheck in a week
C. Carpal tunnel splints and nerve glides
D. Refer for cervical MRI and surgical opinion

D. Refer for cervical MRI and surgical opinion This is cervical spondylotic myelopathy. It is a reason to refer and a contraindication to high velocity cervical thrust.

5. A patient lateral flexes to the left and feels pain on the right side of the chest wall. What does Schepelmann suggest?

A. A fracture of the left eighth rib
B. Pleural irritation or intercostal myofascial strain
C. Costotransverse joint fixation on the left side of the chest
D. Intercostal neuritis on the right side

B. Pleural irritation or intercostal myofascial strain Pain on the convex (stretched) side suggests pleural or myofascial irritation. Pain on the concave side suggests intercostal neuritis.

6. Wright hyperabduction abolishes the radial pulse but reproduces no symptoms. How should it be recorded?

A. Positive for a cervical rib
B. Positive for costoclavicular compression
C. Positive for subpectoral compression
D. Negative for thoracic outlet syndrome

D. Negative for thoracic outlet syndrome Pulse obliteration occurs in many asymptomatic people. A thoracic outlet test counts only if it reproduces the patient's symptoms.

7. Raising a patient's right leg reproduces his left buttock and calf pain. What does this finding most suggest?

A. Hamstring tightness on the right side
B. Sacroiliac dysfunction on the left side
C. A disc herniation, often large or axillary
D. Nonorganic pain behavior on testing

C. A disc herniation, often large or axillary A positive crossed SLR is specific (about 0.9) for disc herniation and helps rule it in.

8. A 65 year old with buttock pain has groin pain on FABERE and 15 degrees of hip internal rotation. Where is the problem most likely?

A. The hip joint, likely osteoarthritis
B. The piriformis, likely myofascial
C. The L4 nerve root, likely stenosis
D. The sacroiliac joint, likely sprain

A. The hip joint, likely osteoarthritis Groin pain on FABERE and early loss of internal rotation point to the hip, not the SI joint.

9. Which palpatory finding has the best interexaminer reliability?

A. Motion palpation for fixation
B. Static spinous alignment
C. Pain provocation on pressure
D. Soft tissue texture change

C. Pain provocation on pressure Tenderness on pressure shows moderate agreement. Motion palpation for fixation is often near chance.

10. Passive shoulder abduction stops at 70 degrees because the patient asks you to stop, with no tissue resistance felt. He smokes and has lost weight. What does this end feel suggest?

A. An empty end feel, a red flag for serious disease
B. A springy block from a labral loose body
C. A soft tissue approximation from swelling
D. A capsular end feel from adhesive capsulitis

A. An empty end feel, a red flag for serious disease Pain stopping motion before any resistance is an empty end feel. With weight loss and smoking, image the chest and refer.

CHAPTER 4

Extremity, Neurologic and Peripheral Vascular Examination

Read it in full: **Chapter 4 in the textbook**. Practice it: **the Study Guide 2 practice exam** and **the flashcards**.

What to know

Most extremity and neurologic items are localization problems: which tissue, which nerve, which level, and whether the cause is in the limb, the spine or the blood supply. Clear the neck and viscera before blaming the shoulder, since C5 radiculopathy, the heart, the diaphragm (C3 to C5), the gallbladder and the spleen can all present as shoulder pain. Compare active and passive range. Loss of both, worst in external rotation, then abduction, then internal rotation, is the **capsular pattern** of adhesive capsulitis or arthritis. Lost active with preserved passive motion means a weak or torn cuff or a nerve lesion. A painful arc at 60 to 120 degrees suggests subacromial impingement; at 160 to 180 degrees, the AC joint.

Neer and Hawkins Kennedy are sensitive for impingement but not specific. Drop arm (specificity above 0.9) and the external rotation lag sign are specific for a full thickness cuff tear. Lift off, belly press and bear hug test subscapularis. The impingement cluster (Hawkins Kennedy, painful arc, weak external rotation) gives an LR+ of about 10. A traumatic cuff tear with marked weakness in an active patient needs early orthopedic referral. At the wrist, Phalen (about 0.68 sensitive, 0.73 specific) and carpal compression test carpal tunnel; thenar skin is spared because the palmar cutaneous branch leaves before the tunnel. Finkelstein tests de Quervain, Froment tests ulnar palsy, and snuffbox tenderness is a scaphoid fracture until proven otherwise, even with a normal film.

In the knee, the mechanism names the structure: a noncontact pivot with a pop and swelling within two hours is an ACL tear; a dashboard injury is a PCL tear; a blow to the lateral knee stresses the MCL; twisting a loaded, flexed knee tears a meniscus, which swells over 6 to 24 hours. **Lachman** is the best ACL test (about 0.85 sensitive, 0.94 specific); the pivot shift is very specific (about 0.98). The posterior drawer is the best PCL test. Valgus stress at 30 degrees isolates the MCL. McMurray and Thessaly test the menisci. Knee pain with a normal knee in an

overweight early adolescent with obligatory external rotation on hip flexion is **SCFE**: non weight bearing and radiographs.

The **Ottawa knee rule** calls for films with any one of: age 55 or older, isolated patellar tenderness, fibular head tenderness, inability to flex to 90 degrees, or inability to bear weight for four steps both immediately and in the office. The **Ottawa ankle rules** press the posterior edge and tip of the distal 6 cm of each malleolus, the base of the fifth metatarsal and the navicular, plus the four step test. They are about 0.98 sensitive, so a patient meeting none needs no film. ATFL tenderness is expected in a sprain. Thompson (about 0.96 sensitive, 0.93 specific) detects Achilles rupture; the squeeze test detects a syndesmotic sprain.

Localize roots with three tools: dermatome, myotome and reflex. C5 biceps, C6 brachioradialis, C7 triceps, L4 patellar, S1 Achilles. Strength is graded 0 to 5 and reflexes 0 to 4+. Upper motor neuron lesions give spasticity, hyperreflexia, clonus over three beats, Babinski and Hoffmann. Lower motor neuron lesions give flaccid weakness, wasting, fasciculation and reduced reflexes. Babinski is normal up to about 12 to 24 months. A facial palsy that spares the forehead is central; with aphasia or arm weakness it is a stroke. Romberg tests proprioception, not the cerebellum.

For the vessels, compare side to side. Pulses are graded 0 to 3+ (some scales add 4+); capillary refill should be under about 2 seconds. The Allen test checks the radial and ulnar arteries. The ABI is the higher ankle pressure over the higher brachial pressure; 0.90 or less is PAD (about 90 percent sensitive, 95 percent specific), and over 1.40 means calcified vessels. The 6 Ps (pain, pallor, pulselessness, paresthesia, paralysis, poikilothermia) mean acute limb ischemia. Pain out of proportion and pain on passive stretch after a crush or fracture suggest compartment syndrome.

Use the **Wells criteria**, not Homans sign, for DVT. One point each for active cancer; paralysis, paresis or recent leg cast; bed rest over 3 days or major surgery within 12 weeks; deep vein tenderness; whole leg swelling; calf more than 3 cm larger (10 cm below the tibial tuberosity); unilateral pitting edema; collateral superficial veins; prior DVT. Subtract two if another diagnosis is at least as likely. Two or more means DVT likely and same day ultrasound. A suspected DVT is never massaged or manipulated.

Sensitivity is the share of diseased people who test positive; specificity the share of healthy people who test negative. **SnNout**: a negative on a sensitive test rules out. **SpPin**: a positive on a specific test rules in. LR+ = sensitivity ÷ (1 − specificity); LR− = (1 − sensitivity) ÷ specificity. Above 10 or below 0.1 is a large shift; an LR of 2 adds about 15 percentage points, 5 about 30 and 10 about 45. Localize by asking which single lesion explains every finding: a root, a nerve, the plexus, the cord, the neuromuscular junction or the muscle.

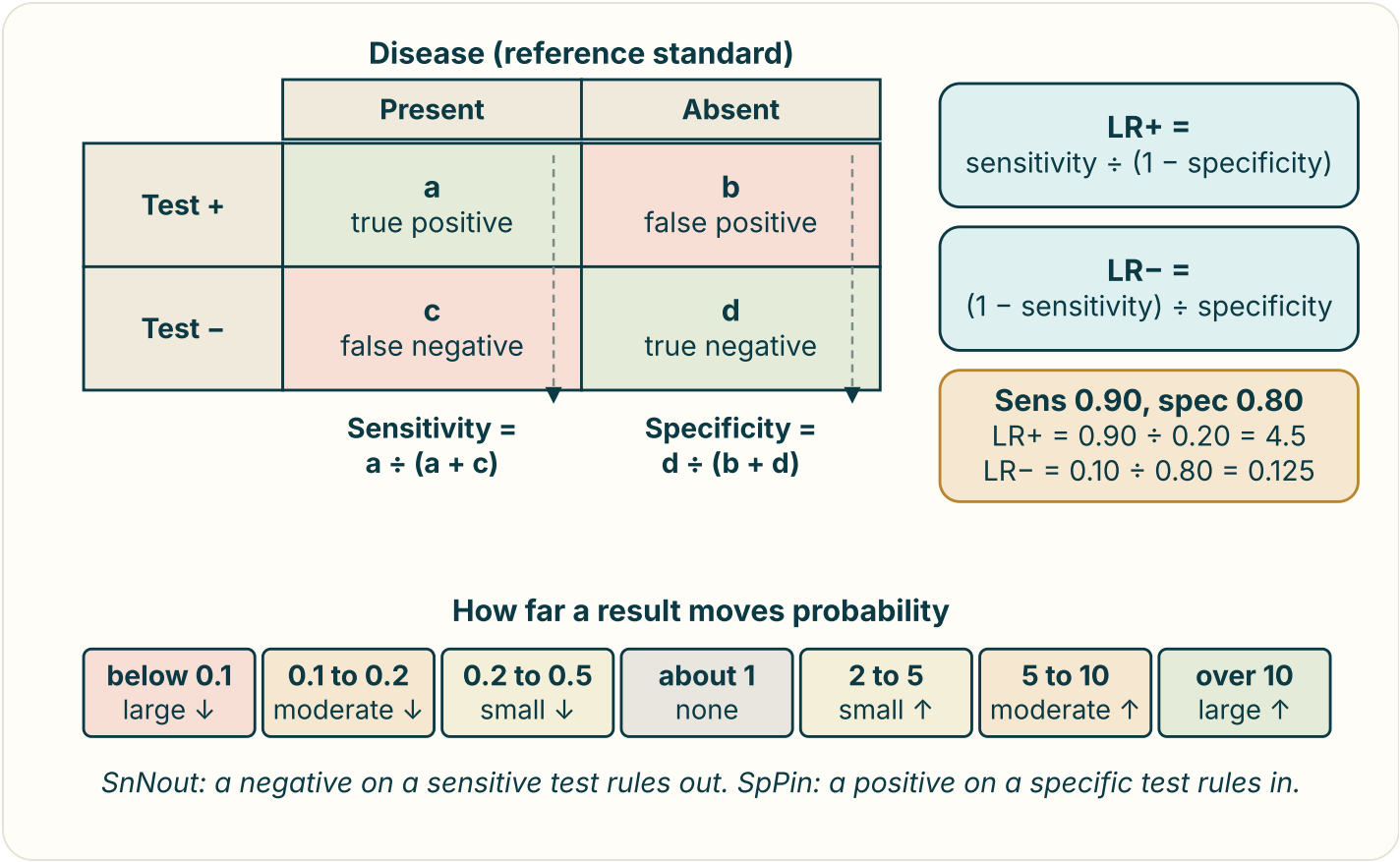

From the two by two table to likelihood ratios. Sensitivity reads down the disease column, specificity down the no disease column. Likelihood ratios combine both and do not change with prevalence, so they tell you how far one result moves your estimate.

LOCK THESE IN

- Capsular pattern at the shoulder: external rotation, then abduction, then internal rotation.
- Drop arm and ER lag sign rule in a cuff tear; Neer and Hawkins are sensitive only.
- Lachman is the best ACL test; posterior drawer the best PCL test; valgus at 30 degrees for MCL.
- Ottawa rules are about 0.98 sensitive: meet none, skip the film.
- C5 biceps, C6 brachioradialis, C7 triceps, L4 patellar, S1 Achilles.
- Forehead sparing facial palsy is central: with limb signs, call emergency services.
- Wells score of 2 or more means same day ultrasound; never Homans sign.
- LR+ = sens ÷ (1 − spec); LR− = (1 − sens) ÷ spec.

Root level screen

Root	Sensory area	Motor test	Reflex
C5	Lateral upper arm (deltoid)	Shoulder abduction, elbow flexion	Biceps
C6	Lateral forearm, thumb, index	Wrist extension, elbow flexion	Brachioradialis
C7	Middle finger	Elbow extension, wrist flexion, finger extension	Triceps
C8	Ring and little fingers, medial forearm	Finger flexion, thumb extension	None reliable
T1	Medial arm	Finger abduction	None
L4	Medial leg and medial malleolus	Ankle dorsiflexion, knee extension	Patellar
L5	Lateral leg, dorsum of foot, great toe	Great toe extension, hip abduction, inversion	Medial hamstring (inconsistent)
S1	Lateral foot, little toe, sole	Plantar flexion, eversion, hip extension	Achilles

Best tests for each structure

Structure	Best test	Value
Full thickness cuff tear	Drop arm; external rotation lag sign	Specific (drop arm above 0.9)
Subacromial impingement	Hawkins Kennedy + painful arc + weak ER	Cluster LR+ about 10
Carpal tunnel	Phalen; carpal compression	Phalen about 0.68 / 0.73
ACL	Lachman; pivot shift	Lachman 0.85 / 0.94; pivot shift spec about 0.98
Meniscus	McMurray; Thessaly	McMurray specific (about 0.77 to 0.9)
Achilles rupture	Thompson	About 0.96 / 0.93
Ankle or foot fracture	Ottawa rules	Sensitivity about 0.98
PAD	ABI 0.90 or less	About 90% sensitive, 95% specific

Worked cases

WORKED CASE 1 · LIKELIHOOD RATIOS FROM SENSITIVITY AND SPECIFICITY

A test for a meniscal tear has a sensitivity of 0.70 and a specificity of 0.90. What are its likelihood ratios, and is it better for ruling in or ruling out?

STEP 1 · LR+

$0.70 \div (1 - 0.90) = 0.70 \div 0.10 =$ **7.0**.

STEP 2 · LR−

$(1 - 0.70) \div 0.90 = 0.30 \div 0.90 =$ **0.33**.

STEP 3 · READ THE SIZE

An LR+ of 7 is a moderate upward shift (about 35 to 40 points by the rule of thumb between 5 and 10). An LR− of 0.33 is only a small downward shift.

STEP 4 · CONCLUDE

It is a specific test: a positive result helps rule in (SpPin); a negative result does little to rule out.

WORKED CASE 2 · A WELLS SCORE

A 53 year old woman is two weeks past knee arthroscopy with a swollen, painful left calf. The left calf is 3.5 cm larger, there is pitting edema on the left only and tenderness along the popliteal vein. No cancer, no prior clot, nothing else more likely.

STEP 1 · SCORE EACH ITEM

Major surgery within 12 weeks 1; deep vein tenderness 1; calf over 3 cm larger 1; unilateral pitting edema 1.

STEP 2 · CHECK THE SUBTRACTION

No alternative diagnosis is at least as likely, so no minus 2.

STEP 3 · TOTAL

1 + 1 + 1 + 1 = **4**: DVT likely.

STEP 4 · ACT

Same day compression ultrasound; emergency care if dyspnea, chest pain or tachycardia appear. No soft tissue work to the calf, and ignore Homans sign.

WORKED CASE 3 · PANCOAST, NOT CUBITAL TUNNEL

A 56 year old heavy smoker has three months of left hand weakness and numb ring and little fingers, with night pain in the shoulder and medial arm. The left pupil is small and the lid droops. Thenar and hypothenar muscles are wasted, medial forearm sensation is reduced and the elbow Tinel is negative.

STEP 1 · TEST THE ULNAR IDEA

The ulnar nerve does not supply the thenar muscles or the medial forearm skin. Both are involved, so the lesion is proximal to the ulnar nerve.

STEP 2 · LOCALIZE

C8 to T1 roots or the lower trunk of the plexus.

STEP 3 · ADD THE EYE

Ptosis and miosis on the same side: Horner syndrome.

STEP 4 · CONCLUDE AND ACT

A superior sulcus (Pancoast) tumor until proven otherwise. Chest radiograph and urgent medical referral.

TRAPS PEOPLE FALL INTO

- **Treating "shoulder pain" that neck movement reproduces.** Clear the neck and the viscera first.
- **Ordering an ankle film for ATFL tenderness.** Ottawa presses the posterior malleolar edge and tip, the fifth metatarsal base and the navicular.

- **Trusting a normal scaphoid film.** Snuffbox tenderness after a fall on the hand means thumb spica and repeat films in 10 to 14 days, or MRI.
- **Giving knee exercises to an adolescent with a normal knee.** Examine the hip: SCFE presents as knee pain.
- **Using Homans sign.** It is neither sensitive nor specific. Use the Wells criteria.
- **Mixing up central and peripheral facial palsy.** Forehead spared is central (stroke); whole half face is peripheral (Bell palsy).
- **Reading the Romberg as a cerebellar test.** Falling only with eyes closed means lost proprioception.
- **Assuming one positive test proves it.** The same result means different things at different pretest probabilities.

Chapter 4 self-test · ten items

1. A 66 year old fell on his outstretched arm. He cannot actively elevate past 80 degrees, passive elevation is full, and the arm drops from 90 degrees. Which additional sign best supports a full thickness tear?

A. Hawkins Kennedy impingement sign
B. External rotation lag sign
C. Speed test pain
D. Neer impingement sign

B. External rotation lag sign The ER lag sign is highly specific for a posterosuperior cuff tear. Neer and Hawkins are sensitive for impingement but do not confirm a tear.

2. A keyboard worker has nightly numbness of the thumb, index and middle fingers, a positive Phalen and intact sensation over the thenar eminence. Where is the lesion?

A. Median nerve at the pronator
B. Lower trunk of the plexus
C. Median nerve in the carpal tunnel
D. C6 nerve root in the C5 to C6 foramen

C. Median nerve in the carpal tunnel The palmar cutaneous branch leaves before the tunnel, so thenar skin is spared in carpal tunnel syndrome.

3. A 21 year old soccer player pivoted, felt a pop and swelled within an hour. Which test is the most accurate clinical test for the likely injury?

A. Anterior drawer at 90 degrees
B. McMurray from full flexion
C. Valgus stress at 30 degrees
D. Lachman at 20 to 30 degrees

D. Lachman at 20 to 30 degrees Lachman (about 0.85 sensitive, 0.94 specific) is the best ACL test. The anterior drawer is limited by guarding and effusion.

4. A 30 year old inverted his ankle, walked four steps into the office, and is tender only over the ATFL. Is a radiograph needed?

A. No; he meets no Ottawa criterion
B. Only if the anterior drawer is lax
C. Yes; any ATFL tenderness needs a film
D. Yes; swelling alone warrants a film

A. No; he meets no Ottawa criterion The Ottawa rules are about 0.98 sensitive. ATFL tenderness is expected in a sprain and is not a criterion.

5. A 12 year old overweight boy limps with distal thigh pain, a normal knee exam and obligatory external rotation on hip flexion. What is the next step?

A. Quadriceps strengthening for four weeks
B. Hip mobilization and a review in a week
C. Non weight bearing and pelvis radiographs
D. Knee MRI to look for a meniscal tear

C. Non weight bearing and pelvis radiographs This is slipped capital femoral epiphysis. Crutches and AP and frog leg lateral films (or urgent referral) protect against further slip and AVN.

6. A patient has foot drop with normal hip abduction and foot inversion and a Tinel sign at the fibular head. Where is the lesion?

A. Common fibular nerve at the fibular head
B. L5 nerve root in the lateral recess
C. Tibial nerve in the tarsal tunnel
D. Sciatic nerve in the deep buttock

A. Common fibular nerve at the fibular head Gluteus medius and tibialis posterior are L5 muscles outside the fibular nerve. When they are spared, the nerve is the culprit.

7. A 59 year old has new neck pain, word finding trouble, a right lower facial droop with a normal forehead and a weak right grip. What should you do?

A. Treat as Bell palsy and refer within the week
B. Call emergency services and note the time last well
C. Examine the cervical spine with Spurling first
D. Order cervical radiographs before deciding

B. Call emergency services and note the time last well A forehead sparing facial palsy with aphasia and arm weakness is an acute stroke. Treatment is time limited.

8. Right ankle pressure is 84 mmHg and the higher brachial pressure is 140 mmHg. What is the ABI?

A. 0.66, borderline result
B. 1.67, noncompressible vessels
C. 0.84, peripheral arterial disease
D. 0.60, peripheral arterial disease

D. 0.60, peripheral arterial disease 84 ÷ 140 = 0.60. That is 0.90 or less, so PAD. 1.67 is the ratio upside down.

9. A test has a sensitivity of 0.80 and a specificity of 0.95. What is its positive likelihood ratio?

A. 19
B. 4
C. 16
D. 0.84

C. 16 LR+ = 0.80 ÷ (1 − 0.95) = 0.80 ÷ 0.05 = 16, a large upward shift. Dividing by 0.20 instead gives 4.

10. Ten days after a long flight, a patient has calf swelling 3.5 cm larger than the other side and unilateral pitting edema; a calf strain is equally likely. What is the Wells score?

A. 2
B. 1
C. 4
D. 0

D. 0 Calf over 3 cm larger 1 plus pitting edema 1 = 2, then minus 2 because an alternative is at least as likely, giving 0. A flight is not itself a Wells item.

ONE PAGE

Cram sheet

Everything from chapters 3 and 4 in one place. Cover the right column and see if you can rebuild each row.

Numbers to know

Item	Value	Note
Scoliometer	About 7° (about Cobb 20°) means radiograph	5° is the screening threshold
Gait cycle	Stance about 60%, swing about 40%	Two double support periods of about 10%
Wainner cluster	3 of 4 LR+ about 6; 4 of 4 about 30	ULTT A sensitivity about 0.97
Myelopathy cluster	3 of 5 LR+ about 30	Age over 45 is an item
Chest expansion	Under about 2.5 cm abnormal	Measured at the 4th intercostal space
Spinal metastases	About 70% thoracic	Thoracic outlet: about 95% neurogenic
SLR	Positive 30 to 70°; sens about 0.9, spec about 0.25	Crossed SLR spec about 0.9
Slump	About 0.84 sensitive, 0.83 specific	Modified Schober: under 5 cm abnormal
Laslett cluster	3 of 5 (or 2 of first 4)	Sens near 0.9, spec near 0.8
Waddell	3 or more of 5 categories	Distress, not malingering
Lachman	About 0.85 sensitive, 0.94 specific	Pivot shift spec about 0.98
Ottawa rules	Sensitivity about 0.98	Knee: age 55+; ankle: distal 6 cm of malleoli
Thompson	About 0.96 sensitive, 0.93 specific	Achilles rupture
Clonus	More than 3 beats is abnormal	Babinski normal to 12 to 24 months
Capillary refill	Under about 2 s	Allen: flush within 5 to 7 s
ABI	0.90 or less PAD; over 1.40 calcified	About 90% sensitive, 95% specific
Wells (DVT)	2 or more: likely, same day ultrasound	Calf over 3 cm larger, 10 cm below tuberosity

Formulas

Name	Formula	Meaning
Sensitivity	a ÷ (a + c)	Share of diseased who test positive
Specificity	d ÷ (b + d)	Share of healthy who test negative
LR+	sensitivity ÷ (1 − specificity)	Over 10 is a large upward shift
LR−	(1 − sensitivity) ÷ specificity	Under 0.1 is a large downward shift
Rule of thumb	LR 2, 5, 10 add about 15, 30, 45 points	LR 0.5, 0.2, 0.1 subtract the same
ABI	higher ankle ÷ higher brachial	One value for each leg

Key terms and comparisons

Pair	How to tell them apart
Radiculopathy vs myelopathy	LMN: one dermatome, myotome, reduced reflex. UMN: clumsy hands, spastic gait, brisk reflexes, Hoffmann.
L5 root vs fibular nerve	Hip abduction and inversion weak in L5, spared in fibular palsy.
C8 root vs ulnar nerve	Thenar muscles and medial forearm involved in C8 to T1, spared in ulnar neuropathy.
FABERE groin vs posterior pain	Groin: hip joint. Posterior: SI joint.
Central vs peripheral facial palsy	Forehead spared: central (stroke). Whole half face: peripheral (Bell).
Romberg vs cerebellar	Romberg falls with eyes closed (proprioception). Cerebellar ataxia is unsteady with eyes open.
SnNout vs SpPin	Negative sensitive test rules out; positive specific test rules in.

Dr. Garg Learning · CC BY-SA 4.0
An independent study aid. Not affiliated with or endorsed by the National Board of Chiropractic Examiners.