Study Guide 1

This guide covers the first two chapters: taking a history that sorts the patient before you touch them, and the general physical examination that catches the problem the patient did not come in with. Work one chapter at a time. Read the "what to know" paragraphs, study the diagram, copy the tables by hand, then cover the steps of each worked case and talk yourself through it. Finish each chapter with its ten board style items. The cram sheet at the end puts every number in one place.

WHAT THIS GUIDE COVERS

- Chapter 1 · the three diagnostic bins, OPQRST, mechanism of injury, pretest probability and likelihood ratios, the review of systems, red flags by threat, the cauda equina and dissection screens, yellow flags, special populations and documentation.
- Chapter 2 · general survey, BMI and blood pressure technique and staging, orthostatic hypotension, vital sign thresholds, eyes, ears and nodes, lung and heart patterns, JVP, the ABI and claudication, abdominal signs, hernias, scrotal emergencies and the sacral exam.

CHAPTER 1

The Case History

Read it in full: **Chapter 1 in the textbook**. Practice it: **the Study Guide 1 practice exam** and **the flashcards**.

What to know

On Part III the history is where most cases are won. Primary care research has shown for decades that the history alone points to the right diagnosis in about 70 to 80 percent of patients. For a chiropractor the history has three jobs: sort the patient into a diagnostic bin, build a short list of hypotheses for the exam to test, and set a baseline that the record can stand on later.

The three bins are **serious pathology** (about 1 to 2 percent of spinal pain patients), **radicular syndrome** (about 5 to 10 percent) and **nonspecific mechanical pain** (about 90 percent). The

standard order of the history is identifying data, chief complaint, history of present illness, past history, medications and allergies, family history, social history and the review of systems. Record the chief complaint in the patient's own words with its duration, never as a diagnosis such as "sciatica."

OPQRST (onset, provocation and palliation, quality, region and radiation, severity, timing) and OLDCARTS cover the same ground. What the board tests is what each answer means. Sudden onset with a load suggests a mechanical injury. Insidious, steadily worsening onset calls for red flag questions. Sudden, severe, "worst ever" pain without trauma is vascular until proven otherwise. Burning or electric pain is neuropathic, and a tearing quality suggests arterial dissection. Pain in a narrow band below the knee is radicular; a diffuse buttock and thigh ache that stops above the knee is somatic referred pain.

Behavior under load points to the pain generator. **Flexion intolerance** (worse sitting, bending, lifting, in the morning) fits a disc. **Extension intolerance** (worse standing, walking, walking downhill) fits the facets or stenosis. Pain worse with cough or sneeze suggests a space occupying lesion, usually a disc. Leg symptoms on walking that ease with sitting or bending forward are neurogenic claudication; leg pain that eases by simply standing still is vascular claudication.

The mechanism of injury predicts the tissue. Flexion with rotation under load stresses the posterolateral annulus. Axial load causes compression or burst fractures, most often at T11 to L2, and a calcaneal fracture travels with a lumbar fracture in about 10 percent of cases. Repetitive hyperextension stresses the pars. Minimal trauma in an older or steroid treated patient is an osteoporotic compression fracture until proven otherwise. Duration sets the class: acute under 6 weeks, subacute 6 to 12 weeks, chronic over 12 weeks. Failure to improve after about four weeks of appropriate care is a common trigger for imaging or referral.

Background history sets **pretest probability**. A prior history of cancer is the strongest single history predictor of spinal malignancy (positive likelihood ratio about 15); age over 50 alone is about 2.7. The cancers that most often spread to bone are breast, prostate, lung, kidney and thyroid. Medications matter both ways: anticoagulants raise bleeding risk, long term corticosteroids bring osteoporosis and masked fever, fluoroquinolones bring tendon rupture, and

statins can cause myalgia. Injection drug use, fever and immunosuppression push toward infection.

The review of systems finds systemic and visceral disease behind a musculoskeletal complaint. Visceral pain does not behave mechanically: movement and palpation do not change it, while eating, urination, menstruation or exertion do. The single most sensitive finding for **cauda equina syndrome** is urinary retention (sensitivity about 90 percent). Before treating the neck, screen for cervical artery dissection: new, severe, unusual neck pain or headache and the 5 Ds and 3 Ns (dizziness, diplopia, dysarthria, dysphagia, drop attacks, ataxia, nausea, nystagmus, numbness).

Yellow flags predict chronic disability, not serious disease: fear avoidance, catastrophizing, low mood, passive coping, job dissatisfaction and compensation issues. Screen them with tools such as the STarT Back tool (nine items, low, medium or high risk). Good history technique starts with open questions, then focused and closed ones, clarifies vague words such as "dizzy," and avoids leading questions. Use a trained medical interpreter, never a child. A defensible record includes pertinent negatives, baseline outcome measures, and corrections made with a single line, the date, time and initials.

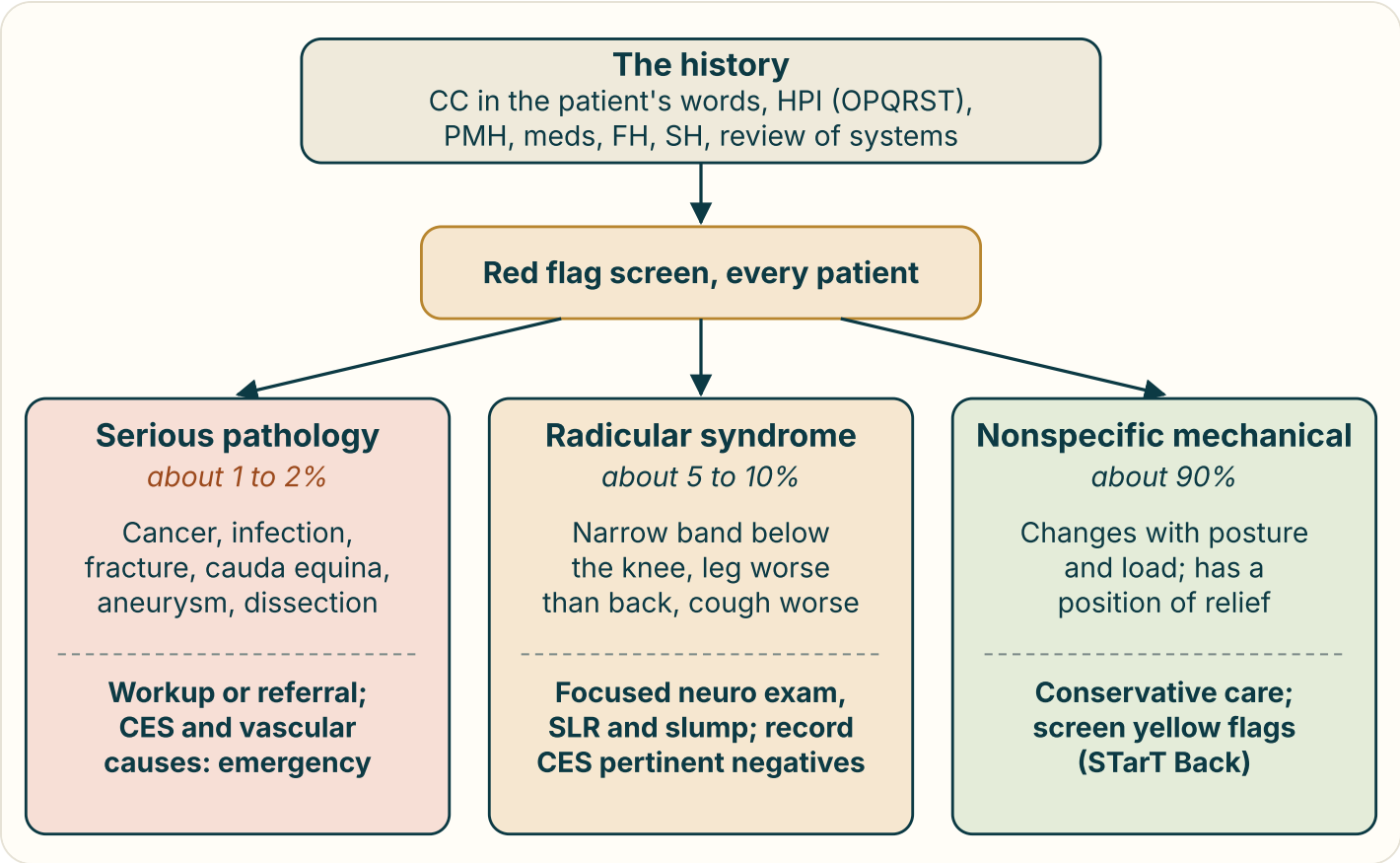

Three diagnostic bins. The history sorts most spinal pain patients before the exam begins. The red flag screen comes first, because the smallest bin holds the patients who must not be missed.

LOCK THESE IN

- Three bins: serious pathology about 1 to 2%, radicular about 5 to 10%, nonspecific mechanical about 90%.
- Flexion intolerance and cough aggravation suggest disc; extension intolerance suggests facet or stenosis.
- Neurogenic claudication eases with sitting or bending forward; vascular claudication eases by standing still.
- Prior cancer has a positive LR of about 15 for spinal malignancy; breast, prostate, lung, kidney and thyroid spread to bone.
- Urinary retention is the most sensitive cauda equina finding (about 90%); ask about bladder, bowel and saddle sensation in every patient with leg symptoms.
- Before neck care, screen for dissection: sudden unusual neck pain or headache plus the 5 Ds and 3 Ns.
- Red flags predict serious disease; yellow flags predict chronicity.
- Document pertinent negatives; correct the record with a single line, date, time and initials.

OPQRST answers and what they suggest

Element	Answer	What it suggests
Onset	Sudden with a specific load (lift and twist)	Mechanical injury: disc, facet, muscle strain
Onset	Insidious, steadily worsening, no event	Degenerative, inflammatory, neoplastic or infectious; ask red flag questions
Onset	Sudden, severe, "worst ever," no trauma	Vascular (dissection, aneurysm, hemorrhage) until proven otherwise
Provocation	Sitting, bending, cough, sneeze, strain	Discogenic or radicular
Provocation	Standing, extension, walking downhill	Facet joint or stenosis
Palliation	Nothing helps; or exercise helps, rest does not	Nonmechanical; exercise relief suggests spondyloarthritis
Quality	Burning, electric, shooting; or tearing	Neuropathic or radicular; tearing suggests dissection
Region	Narrow band below the knee to the foot	Radicular pain
Region	Diffuse buttock and thigh, stops above the knee	Somatic referred pain (facet, SI joint, disc)
Timing	Morning stiffness over 30 to 60 minutes	Inflammatory arthritis
Timing	Night pain unrelieved by position	Red flag: tumor or infection

Red flags by threat and urgency

Threat	History red flags	Urgency if suspected
Malignancy	Prior cancer, age over 50, weight loss, no improvement in 4 to 6 weeks, night pain	Urgent workup in days; same day if new neurologic deficit
Infection	Fever, injection drug use, immunosuppression, diabetes, recent UTI or spinal procedure	Same day medical evaluation; emergency if neurologic signs
Fracture	Significant trauma (minor in the elderly), osteoporosis, long term steroids, age over 70	Image before manual therapy
Cauda equina syndrome	Urinary retention, saddle numbness, fecal incontinence, bilateral or progressive leg weakness	Emergency: same day ED for MRI and decompression
Abdominal aortic aneurysm	Age over 60, male, smoker, hypertension; deep boring or tearing pain unrelated to movement	Emergency if symptomatic
Cervical artery dissection	Sudden severe unusual neck pain or headache; 5 Ds and 3 Ns; Horner syndrome	Emergency: stroke pathway
Giant cell arteritis	Over 50, new headache, scalp tenderness, jaw claudication, visual change	Same day: risk of blindness

Worked cases

WORKED CASE 1 · THE NEXT HISTORY QUESTION

A 39 year old carpenter lifted and twisted a sheet of plywood. Two days later he has burning pain down the back of the left thigh and calf to the little toe, worse sitting and with coughing. What should you ask next, and why?

STEP 1 · READ THE PATTERN

Flexion plus rotation under load, leg pain below the knee in an S1 band and cough aggravation point to a posterolateral L5 to S1 disc herniation with S1 radicular pain.

STEP 2 · FIND THE QUESTION THAT CHANGES MANAGEMENT

With leg symptoms from a probable disc, the cauda equina screen is the question whose answer moves the case from conservative care to the emergency department.

STEP 3 · ASK IT IN PLAIN WORDS

"Any trouble starting or stopping your urine, any leaking, any numbness between your legs, any change in bowel control?"

STEP 4 · DOCUMENT BOTH WAYS

Record the negative answers as pertinent negatives, then focus the exam: SLR, slump, plantarflexion strength, Achilles reflex and lateral foot sensation.

WORKED CASE 2 · NEUROGENIC VERSUS VASCULAR CLAUDICATION

A 68 year old man reports heaviness in both buttocks and thighs after walking two blocks. Leaning on a shopping cart helps within minutes; standing still does not. He can ride an exercise bike comfortably.

STEP 1 · FIND THE DISCRIMINATING CLUE

Relief by flexion (sitting, leaning forward) rather than by simply stopping is the key clue.

STEP 2 · CHECK THE BIKE

Cycling is a flexed posture, so stenosis patients tolerate it. Arterial disease would hurt on the bike too.

STEP 3 · NAME THE DIAGNOSIS

Neurogenic claudication from lumbar spinal stenosis.

STEP 4 · NAME THE MUST NOT MISS

Peripheral arterial disease. Palpate pedal pulses and consider an ankle brachial index.

WORKED CASE 3 · WHEN THE HISTORY OVERRIDES THE PATIENT'S STORY

A 64 year old man who smokes heavily says he "strained it gardening" six weeks ago. The pain is constant, deep and boring, unchanged by any position, worse at night, and he has lost 6 kg without trying.

STEP 1 · TEST THE ANCHOR

Gardening is the patient's explanation, but the pain does not behave mechanically: no position changes it.

STEP 2 · COUNT THE RED FLAGS

Age over 50, night pain, unexplained weight loss, no response to care, heavy smoking.

STEP 3 · BUILD THE DIFFERENTIAL

Metastatic disease (lung, prostate), multiple myeloma, abdominal aortic aneurysm, pancreatic cancer.

STEP 4 · ACT

Palpate for a pulsatile abdominal mass, screen neurologically, and obtain radiographs and labs (CBC, ESR or CRP, calcium, alkaline phosphatase, PSA, protein electrophoresis) or refer promptly. Defer manipulation. Accepting "gardening" would be anchoring.

TRAPS PEOPLE FALL INTO

- **Writing a diagnosis as the chief complaint.** Record the patient's words and duration. "Sciatica" or "subluxation" closes the mind too early.
- **Mixing up the two claudications.** Neurogenic needs sitting or bending forward; vascular eases by standing still and also hurts on a bike.
- **Treating each red flag as equal.** Most are weak alone. Prior cancer is strong (LR about 15); age over 50 alone is about 2.7.
- **Skipping the cauda equina screen.** Ask about urinary retention, leaking, saddle numbness and bowel change in every back pain patient with leg symptoms, and write down the negatives.
- **Calling yellow flags malingering.** Fear of movement and a pending claim predict slow recovery. They call for education and graded activity, not suspicion.
- **Testing a suspected dissection.** Sudden unusual neck pain with brainstem signs means no provocative tests and no neck treatment. Send to the emergency department.
- **Letting a family member interpret.** Use a trained medical interpreter, never a child, and document the interpreter's name or ID.
- **Rewriting a wrong entry.** A single line through the error, the correction, date, time and initials. Never erase or rewrite.

Chapter 1 self-test · ten items

1. A 36 year old man has right buttock pain that stops above the knee after a day of shoveling. It is a deep, diffuse ache with no numbness. What pain pattern does this history describe?

A. Somatic referred pain from a spinal structure
B. Visceral referred pain from the right kidney
C. Radicular pain from an irritated S1 root
D. Neurogenic claudication from central stenosis

A. Somatic referred pain from a spinal structure A deep, poorly localized ache that stops above the knee with no neurologic symptoms is somatic referred pain from a facet, disc or SI joint. Radicular pain runs in a narrow band, often below the knee.

2. A 55 year old woman has back pain that is worse standing and walking downhill and eased by sitting. Which tissue does this behavior under load point to most?

A. A posterolateral annular tear of the disc
B. Visceral referral from the pelvic organs
C. A muscle strain of the lumbar extensors
D. Facet joints or a narrowed spinal canal

D. Facet joints or a narrowed spinal canal Extension intolerance loads the posterior elements and narrows the canal and foramina, which fits facet pain or stenosis. Flexion intolerance would point to a disc.

3. Which single history finding carries the greatest weight for malignancy as the cause of low back pain?

A. Back pain that began without any injury
B. Pain that is not relieved by bed rest
C. A prior history of cancer at any time
D. Age over 50 years with pain for a month

C. A prior history of cancer at any time A prior cancer history has a positive likelihood ratio of about 15. Age over 50 alone is about 2.7, and "not relieved by bed rest" barely moves probability.

4. A 46 year old man with low back and left leg pain asks to start treatment today. Which history item is the most sensitive screen for cauda equina syndrome?

A. Numbness on the top of the left foot
B. Difficulty starting or emptying the bladder
C. Pain that wakes him once during the night
D. Pain that is worse when he coughs hard

B. Difficulty starting or emptying the bladder Urinary retention is the single most sensitive finding for cauda equina syndrome, at about 90 percent. Overflow incontinence follows retention.

5. A 31 year old woman has had low back pain for nine months with an hour of morning stiffness. Exercise helps and rest does not, and she had psoriasis diagnosed last year. Which diagnosis leads?

A. Lumbar spinal stenosis with neurogenic claudication
B. Lumbar disc herniation with an S1 radiculopathy
C. Axial spondyloarthritis with inflammatory back pain
D. Nonspecific mechanical low back pain with deconditioning

C. Axial spondyloarthritis with inflammatory back pain Onset before 40, long morning stiffness, relief with exercise but not rest and psoriasis fit inflammatory back pain. HLA-B27, CRP and SI joint imaging with rheumatology co-management follow.

6. A 52 year old woman reports a sudden, severe left neck pain and a headache "nothing like my usual" after a sharp head turn, now with slurred speech. What is the best action?

A. Perform a vertebral artery test before deciding on care
B. Arrange immediate emergency transfer for vascular imaging
C. Treat with low force mobilization and review in one week
D. Order cervical flexion and extension radiographs first

B. Arrange immediate emergency transfer for vascular imaging New, unusual neck pain and headache with a brainstem sign such as dysarthria is a suspected dissection. Do not run provocative tests or treat the neck; send to the emergency department.

7. A worker has been off for ten weeks, believes bending will "ruin his spine," and has an open compensation claim. How should these findings be classed?

A. Yellow flags that predict delayed recovery
B. Signs of conscious symptom exaggeration
C. Orange flags that need psychiatric referral
D. Red flags that call for urgent imaging

A. Yellow flags that predict delayed recovery Fear avoidance beliefs and compensation issues are yellow flags (with blue and black flag elements). They predict chronic disability and call for education and graded activity.

8. A clinician seeing a Spanish speaking patient needs to ask about bladder and sexual function. Who should interpret?

A. A front desk staff member who speaks Spanish
B. The patient's bilingual 14 year old daughter
C. The patient's spouse, who knows the history
D. A trained medical interpreter, in person or remote

D. A trained medical interpreter, in person or remote Family members, and especially children, may filter sensitive answers and lack medical vocabulary. A trained interpreter translates exactly; document the interpreter's name or ID.

9. You notice that yesterday's note recorded the wrong side of the leg pain. How should you correct it?

A. Single line through it, correct it, add date, time and initials
B. Erase the entry and rewrite the note so it reads cleanly
C. Leave it unchanged and mention the error to the patient
D. Print a new note and destroy the original page

A. Single line through it, correct it, add date, time and initials A defensible correction keeps the original legible under a single line, with the correction, date, time and initials. Altering or destroying records is among the most damaging things a clinician can do.

10. A 34 year old woman at 29 weeks of pregnancy has low back pain that now comes every 10 minutes with tightening of her abdomen. What is the most appropriate action?

A. Order lumbar radiographs with a lead apron
B. Treat the pelvis with drop table technique today
C. Refer her immediately to labor and delivery
D. Advise a support belt and review next week

C. Refer her immediately to labor and delivery Rhythmic back pain with uterine tightening is preterm labor until proven otherwise. Pregnancy related mechanical pain is diagnosed only after obstetric red flags are cleared.

CHAPTER 2

The General Physical Examination

Read it in full: **Chapter 2 in the textbook**. Practice it: **the Study Guide 1 practice exam** and **the flashcards**.

What to know

A chiropractor is a portal of entry provider. The back pain may be an aneurysm, the neck pain a thyroid mass, the headache a blood pressure of 210 over 125. Part III cases slip one abnormal sign into a musculoskeletal story and ask what it means. The general survey starts at the door: a patient lying perfectly still suggests peritonitis, a patient who cannot get comfortable suggests renal or biliary colic, and cachexia suggests cancer or chronic disease.

BMI is weight in kilograms divided by height in meters squared: under 18.5 underweight, 18.5 to 24.9 normal, 25 to 29.9 overweight, 30 or more obese. **Blood pressure** technique is tested: seated 5 minutes, back supported, feet flat, arm bare at heart level, a cuff bladder that encircles about 80 percent of the arm. A small cuff reads falsely high. Palpate first, inflate 20 to 30 mmHg above the point the radial pulse disappears to avoid an auscultatory gap, and deflate at 2 to 3 mmHg per second. Normal is under 120 and under 80; stage 1 is 130 to 139 or 80 to 89; stage 2 is 140 or

higher or 90 or higher. Over 180 and/or 120 is severe; with symptoms of target organ damage it is a hypertensive emergency.

Orthostatic hypotension is a fall of at least 20 mmHg systolic or 10 mmHg diastolic within 3 minutes of standing. An interarm difference above about 15 to 20 mmHg suggests subclavian stenosis or aortic dissection. Normal adult pulse is 60 to 100, respirations 12 to 20, oxygen saturation 95 to 100 percent, and fever is 38.0 °C (100.4 °F) or higher. With back pain, fever means think discitis, osteomyelitis, epidural abscess or pyelonephritis. A patient with suspected infection and two or more qSOFA criteria (respiratory rate 22 or more, altered mentation, systolic pressure 100 or less) needs emergency care.

In the head and neck, **Horner syndrome** (ptosis, miosis, anhidrosis) with neck pain suggests carotid dissection, and in a smoker with shoulder pain suggests a Pancoast tumor. On tuning fork tests, Weber lateralizes to the bad ear in conductive loss and to the good ear in sensorineural loss; a negative Rinne (bone longer than air) means conductive loss in that ear. Hard, fixed or supraclavicular nodes are suspicious; a left supraclavicular (Virchow) node suggests abdominal, especially gastric, cancer.

Chest patterns: dull with increased fremitus is consolidation; stony dull with decreased fremitus is effusion; hyperresonant with decreased breath sounds is pneumothorax or emphysema. The trachea moves away from a tension pneumothorax or large effusion and toward a collapsed lobe. In the heart, S3 suggests heart failure in an adult over about 40 and S4 a stiff ventricle. Aortic stenosis radiates to the carotids; mitral regurgitation radiates to the axilla; aortic regurgitation gives a wide pulse pressure and is linked to ankylosing spondylitis. Hypertrophic cardiomyopathy and mitral valve prolapse get louder with Valsalva and standing. A JVP over 3 cm above the sternal angle means raised right atrial pressure.

The **ankle brachial index** is the higher ankle pressure on each side divided by the higher brachial pressure: 1.00 to 1.40 normal, 0.91 to 0.99 borderline, 0.90 or less peripheral arterial disease, under about 0.40 critical limb ischemia, over 1.40 noncompressible vessels. Vascular claudication is calf cramping at a fixed distance relieved by standing still; neurogenic claudication is relieved by sitting or flexing and usually allows cycling. Acute limb ischemia has the 6 Ps and is an emergency.

Examine the abdomen in the order inspect, auscultate, percuss, palpate. The aorta bifurcates at about L4 near the umbilicus, so look for an **expansile** pulsation above it. An AAA is a diameter of 3 cm or more; a tender aneurysm or back pain with hypotension is an emergency. Know the signs: Murphy (cholecystitis), McBurney and Rovsing (appendicitis), psoas (retrocecal appendicitis or psoas abscess), Cullen and Grey Turner (hemorrhage), Kehr (splenic rupture), costovertebral angle tenderness (kidney), Carnett (abdominal wall source if tenderness stays the same or worsens).

Groin and perineum: a femoral hernia lies below the inguinal ligament and has the highest strangulation risk. Testicular torsion has an absent cremasteric reflex (L1 to L2), no relief with elevation, and needs surgery within about 6 hours; epididymitis keeps the reflex and eases with elevation (Prehn sign). For cauda equina, saddle sensation tests S2 to S5, and the anal wink and bulbocavernosus reflex test S2 to S4. A hard, nodular prostate suggests cancer with osteoblastic spinal metastases. Finally, list every abnormal finding and assign each one to treat, co-manage or refer, with matching urgency.

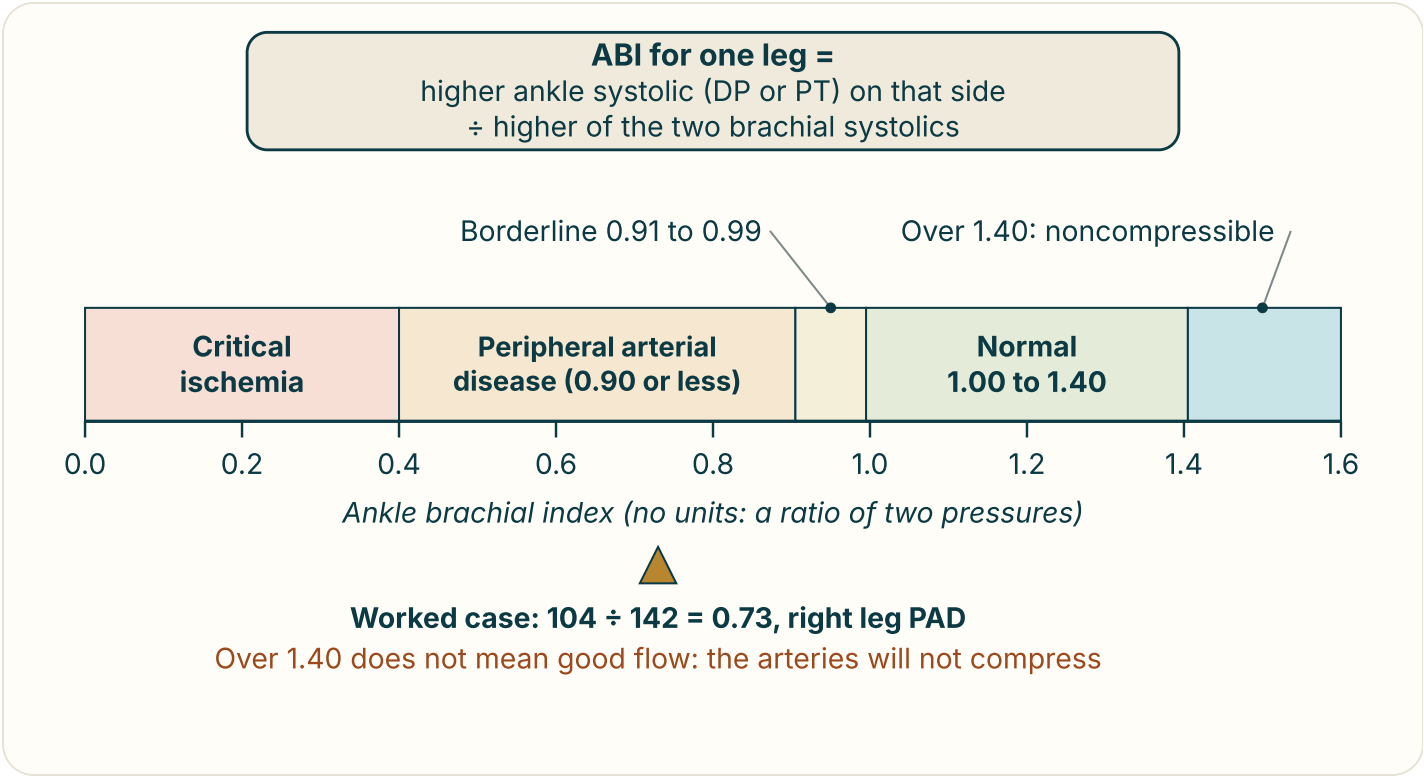

The ABI on a true scale. Divide the higher ankle pressure on each side by the higher arm pressure. An ABI of 0.90 or less defines peripheral arterial disease, and a value over 1.40 means stiff, calcified vessels, not better circulation.

LOCK THESE IN

- BP: small cuff reads high; palpate first to avoid an auscultatory gap; over 180 and/or 120 with symptoms is an emergency.
- Orthostatic hypotension: a fall of 20 systolic or 10 diastolic within 3 minutes of standing.
- Weber goes to the bad ear in conductive loss, the good ear in sensorineural loss.
- Dull plus increased fremitus is consolidation; dull plus decreased fremitus is effusion.
- Aortic stenosis to the carotids, mitral regurgitation to the axilla, HCM louder with Valsalva.
- ABI 0.90 or less is PAD; over 1.40 means calcified vessels.
- Expansile mass above the umbilicus, 3 cm or more, is AAA; tender plus back pain is an emergency.
- Torsion: absent cremasteric reflex, no relief on elevation, surgery within about 6 hours.

Vital signs and thresholds

Measure	Value	Meaning or action
Blood pressure	Under 120 and under 80	Normal
Blood pressure	130 to 139 or 80 to 89; 140 or 90 and above	Stage 1; stage 2 (confirm and refer to primary care)
Blood pressure	Over 180 and/or over 120	No symptoms: same or next day contact; with target organ symptoms: emergency
Orthostatic drop	20 systolic or 10 diastolic within 3 min	Dizziness on rising, fall risk
Pulse	60 to 100; irregularly irregular	Atrial fibrillation: stroke risk, refer if new
Respirations	12 to 20; over 24 is a marker of serious illness	qSOFA uses 22 or more
Temperature	38.0 °C (100.4 °F) or higher	Fever; with back pain think spinal infection
SpO_2	95 to 100%; under 92% at rest abnormal	Under 90% is an emergency
BMI	18.5 to 24.9 normal; 30 and above obese	kg ÷ m^2
JVP	3 cm or less above the sternal angle	Higher means raised right atrial pressure
ABI	0.90 or less PAD; over 1.40 noncompressible	Higher ankle ÷ higher brachial

Patterns that recur on the board

Finding	Pattern	Points to
Tuning forks	Weber to the left; left Rinne bone longer than air	Left conductive loss
Tuning forks	Weber to the left; Rinne air longer than bone both sides	Right sensorineural loss
Chest	Dull, increased fremitus, bronchial sounds, egophony	Consolidation (pneumonia)
Chest	Stony dull, decreased fremitus, trachea pushed away	Large pleural effusion
Heart	Harsh midsystolic murmur, right 2nd ICS, to carotids	Aortic stenosis
Heart	Early diastolic murmur, wide pulse pressure	Aortic regurgitation (ankylosing spondylitis link)
Abdomen	Psoas sign plus fever and a flexed hip	Psoas abscess or retrocecal appendicitis
Scrotum	High riding testis, absent cremasteric reflex	Testicular torsion: emergency
Perineum	Saddle loss, absent anal wink, weak tone	Cauda equina syndrome

Worked cases

WORKED CASE 1 · CALCULATING AND READING AN ABI

A 67 year old smoker has right calf cramping after 150 meters. Brachial pressures are 142 right and 136 left. Right ankle pressures are 104 at the dorsalis pedis and 96 at the posterior tibial.

STEP 1 · PICK THE NUMERATOR

Use the higher ankle pressure on the right: 104.

STEP 2 · PICK THE DENOMINATOR

Use the higher of the two arm pressures: 142.

STEP 3 · DIVIDE

104 ÷ 142 = **0.73**.

STEP 4 · INTERPRET AND ACT

0.73 is 0.90 or less, so this is peripheral arterial disease. Refer for vascular evaluation and risk factor care, and ask about chest pain and TIA, since PAD marks systemic atherosclerosis.

WORKED CASE 2 · A READING OVER 180

A 57 year old man at a low back follow up has a dull headache. His pressure is 196/124, then 194/122 after five minutes of rest. He stopped his blood pressure pill two weeks ago and has no chest pain, dyspnea, confusion, visual change or weakness.

STEP 1 · CONFIRM THE TECHNIQUE

Repeat, seated, correct cuff, arm at heart level. Both readings are over 180 and over 120.

STEP 2 · LOOK FOR TARGET ORGAN SYMPTOMS

None are present, so this is severe hypertension without an emergency.

STEP 3 · ACT

Defer manipulation and vigorous treatment, contact primary care the same day, and document readings and advice.

STEP 4 · KNOW THE SWITCH

Chest pain, dyspnea, confusion, visual loss or a focal deficit would make it a hypertensive emergency: call emergency services.

WORKED CASE 3 · A PULSATILE MASS BEHIND "A PULLED MUSCLE"

A 73 year old male smoker with hypertension has had deep, constant low back pain for three days, unchanged by position. Above the umbilicus you feel a tender pulsation that pushes your hands apart.

STEP 1 · DESCRIBE THE FINDING

Expansile (hands pushed apart), above the umbilicus, tender.

STEP 2 · MATCH THE RISK PROFILE

Older male, smoker, hypertensive: classic AAA risk.

STEP 3 · JUDGE URGENCY

A tender, symptomatic aneurysm may be leaking. That is an emergency even with stable vital signs.

STEP 4 · ACT

Stop palpating, no lumbar or abdominal manual therapy, immediate emergency transfer, document the time and findings.

TRAPS PEOPLE FALL INTO

- **Trusting a reading from a small cuff.** An undersized cuff reads falsely high. Re-measure with the right cuff before classifying.
- **Reading an ABI over 1.40 as excellent.** It means calcified, noncompressible vessels. Use a toe brachial index or duplex.
- **Using the lower arm pressure in the ABI.** The denominator is the higher of the two brachial pressures.
- **Palpating before auscultating the abdomen.** The order is inspect, auscultate, percuss, palpate, so palpation does not change bowel sounds.
- **Calling a psoas sign with fever a hip flexor strain.** Think psoas abscess, often from vertebral osteomyelitis or Crohn disease.
- **Treating a teenager's "pulled groin" that began at rest.** Sudden pain at rest with vomiting is torsion until proven otherwise.
- **Delaying referral to finish the sacral exam.** If you cannot perform saddle, anal wink and tone testing, send the suspected cauda equina patient anyway.
- **Mixing up the Weber directions.** Conductive: toward the bad ear. Sensorineural: toward the good ear.

Chapter 2 self-test · ten items

1. A patient's blood pressure is 162/98 with a standard cuff on an upper arm that measures 43 cm around. What should you do before classifying it?

A. Repeat with a large adult cuff
B. Repeat with the arm below the heart
C. Classify it as stage 2 and refer
D. Repeat after a cup of coffee

A. Repeat with a large adult cuff An undersized cuff reads falsely high. The bladder should encircle about 80 percent of the arm.

2. A 64 year old man's pressure is 136/84 supine and 112/80 after two minutes standing, and he feels lightheaded. What best describes this?

A. Pulsus paradoxus
B. Stage 1 hypertension
C. An auscultatory gap
D. Orthostatic hypotension

D. Orthostatic hypotension A systolic fall of 20 or more (here 24) within 3 minutes of standing defines orthostatic hypotension. Common causes are diuretics, antihypertensives and dehydration.

3. Weber lateralizes to the left ear. On the left, bone conduction is heard longer than air conduction. What is the finding?

A. Right conductive hearing loss
B. Left sensorineural hearing loss
C. Left conductive hearing loss
D. Right sensorineural hearing loss

C. Left conductive hearing loss In conductive loss, Weber goes to the affected ear and Rinne is negative (bone longer than air) on that side.

4. Over the left lower chest there is dullness, increased tactile fremitus, bronchial breath sounds and egophony. What is the most likely cause?

A. Emphysema with marked hyperinflation
B. Lobar consolidation from pneumonia
C. A large left pleural effusion
D. A left sided pneumothorax

B. Lobar consolidation from pneumonia Dullness with increased fremitus and bronchial sounds means solid lung. Effusion would be dull with decreased fremitus.

5. A 19 year old basketball player has a systolic murmur at the left sternal border that gets louder when he stands and with Valsalva. Which condition must be excluded?

A. Mitral valve stenosis
B. Aortic valve stenosis
C. Chronic aortic regurgitation
D. Hypertrophic cardiomyopathy

D. Hypertrophic cardiomyopathy HCM and mitral valve prolapse get louder with Valsalva and standing. HCM is a leading cause of sudden cardiac death in young athletes.

6. Left ankle pressures are 70 (dorsalis pedis) and 78 (posterior tibial). Brachial pressures are 130 right and 124 left. What is the left ABI?

A. About 0.60, peripheral arterial disease
B. About 0.63, peripheral arterial disease
C. About 0.56, peripheral arterial disease
D. About 0.54, critical limb ischemia

A. About 0.60, peripheral arterial disease Use the higher left ankle pressure (78) over the higher arm pressure (130): 78 ÷ 130 = 0.60. That is 0.90 or less, so PAD.

7. A 70 year old male smoker has new back pain and a tender, expansile pulsation above the umbilicus. Blood pressure is normal. What is the next step?

A. Gentle side lying mobilization
B. Abdominal ultrasound next week
C. Immediate emergency transfer
D. Repeat deep palpation to size it

C. Immediate emergency transfer A tender, symptomatic aneurysm may be leaking. Stop palpating, give no manual therapy and transfer now, even with normal vital signs.

8. A febrile 41 year old man with right back and groin pain holds the hip flexed, and resisted hip flexion causes deep pain. What must you consider?

A. A hip flexor strain
B. A psoas abscess
C. Femoral nerve entrapment
D. An adductor tendinopathy

B. A psoas abscess A psoas sign with fever and back pain suggests a retroperitoneal infection such as a psoas abscess, often from vertebral osteomyelitis. Refer the same day.

9. A 15 year old has sudden left scrotal pain at rest. The testis rides high and horizontal, elevation does not help, and the cremasteric reflex is absent. What is the diagnosis?

A. Testicular torsion
B. A reducible hydrocele
C. Acute epididymitis
D. A left varicocele

A. Testicular torsion Torsion has an absent cremasteric reflex and no relief on elevation. It is a surgical emergency, best within about 6 hours.

10. A 39 year old woman with mechanical neck pain has a pulse of 114 and irregularly irregular, a fine tremor and a diffusely enlarged thyroid. What is the best plan?

A. Refer routinely to endocrinology within three months
B. Treat the neck today and recheck the pulse next week
C. Same day primary care referral, then co-manage the neck
D. Order cervical radiographs before deciding anything

C. Same day primary care referral, then co-manage the neck New atrial fibrillation with likely hyperthyroidism needs same day medical care. The mechanical neck problem can be co-managed once she is evaluated.

ONE PAGE

Cram sheet

Everything from chapters 1 and 2 in one place. Cover the right column and see if you can rebuild each row.

Numbers to know

Item	Value	Note
Diagnostic bins	Serious 1 to 2%; radicular 5 to 10%; mechanical about 90%	History alone diagnoses 70 to 80%
Duration	Acute under 6 wk; subacute 6 to 12 wk; chronic over 12 wk	No improvement after about 4 wk: image or refer
Likelihood ratios	Prior cancer LR+ about 15; age over 50 about 2.7	LR+ over 10 or LR− under 0.1 is decisive
Cauda equina	Urinary retention about 90% sensitive	Saddle S2 to S5; anal wink S2 to S4
Axial load fracture	T11 to L2; calcaneal plus lumbar about 10%	Ask about heel pain
Blood pressure	Stage 1 130 to 139 or 80 to 89; stage 2 140 or 90+	Over 180 and/or 120: severe
Orthostatic	Drop of 20 systolic or 10 diastolic within 3 min	Interarm over 15 to 20: subclavian or dissection
Vital signs	Pulse 60 to 100; RR 12 to 20; SpO_2 95 to 100%	Fever 38.0 °C (100.4 °F)
qSOFA	RR 22+, altered mentation, SBP 100 or less	Two or more: emergency
BMI	Under 18.5; 18.5 to 24.9; 25 to 29.9; 30+	Waist over 102 cm men, 88 cm women
JVP	3 cm or less above sternal angle	HJR rise over 3 cm supports heart failure
ABI	1.00 to 1.40 normal; 0.91 to 0.99 borderline; 0.90 or less PAD	Under 0.40 critical; over 1.40 calcified
AAA	3 cm or more; surgery over about 5.5 cm	Bifurcation at L4, umbilicus
Torsion	Salvage best within about 6 h	Cremasteric L1 to L2

Key terms and comparisons

Pair	How to tell them apart
Neurogenic vs vascular claudication	Neurogenic: sit or bend forward, bike tolerated, pulses normal. Vascular: stand still, bike hurts, ABI 0.90 or less.
Radicular vs somatic referred	Radicular: narrow band, below the knee, burning. Somatic: deep diffuse ache, stops above the knee.
Red vs yellow flags	Red predict serious disease; yellow predict chronic disability.
Conductive vs sensorineural	Weber to the bad ear and Rinne negative; or Weber to the good ear and Rinne positive.
Consolidation vs effusion	Both dull; fremitus up in consolidation, down in effusion.
Torsion vs epididymitis	Torsion: no cremasteric reflex, no relief on elevation. Epididymitis: reflex present, Prehn sign.
Cullen vs Grey Turner	Periumbilical versus flank bruising.

Rules that are not numbers

Topic	The rule
Next question	Choose the question whose answer would change management.
Neck care	Screen the 5 Ds and 3 Ns first; suspected dissection means no provocative tests.
Documentation	Pertinent negatives in; corrections by single line, date, time, initials.
Interpreters	Trained medical interpreter, never a child; document their ID.
Problem list	Every abnormal finding: treat, co-manage or refer, with matched urgency.

Dr. Garg Learning · CC BY-SA 4.0
An independent study aid. Not affiliated with or endorsed by the National Board of Chiropractic Examiners.