PART II CLINICAL SCIENCES · BOARD REVIEW

Final Review Study Guide

The final review covers all fourteen chapters. Each chapter here is shorter than in the study guides: four paragraphs of what to know, the chapter diagram, the points to lock in, one table, a short worked case, the traps and six new board-style items. If a chapter feels shaky, go back to its study guide for the full treatment. The long cram sheet at the end pulls the numbers and rules of the whole course into one place. Work two chapters a day and the course fits into a week.

WHAT THIS GUIDE COVERS

- General diagnosis · Chapters 1 to 3: history, vital signs and physical examination; laboratory and special studies; internal disorders and referral.
- Neuromusculoskeletal diagnosis · Chapters 4 to 6: spinal and pelvic orthopedic tests; extremity examination and musculoskeletal diagnosis; the neurologic examination and diagnosis.
- Diagnostic imaging · Chapters 7 and 8: technology, protection, positioning, mensuration and special imaging; imaging diagnosis.
- Principles and practice · Chapters 9 to 12: history, paradigm and research; subluxation models and biomechanics; analysis and adjustive technique; patient care, community and occupational health.
- Associated clinical sciences · Chapters 13 and 14: geriatrics, dermatology, STIs, toxicology and emergency care; psychology, gynecology and obstetrics, pediatrics, jurisprudence and ethics.

CHAPTER 1

Case History, Vital Signs and the Physical Examination

Read it in full: **Chapter 1 in the textbook**. Practice it: **Practice exam 1** and the **flashcards**.

What to know

Take the history in order (CC, HPI, PMH, FH, SH, ROS), characterize symptoms with OPQRST and record pertinent negatives. Screen every new spinal patient for red flags of cancer, infection,

fracture, cauda equina syndrome and vascular emergency. Prior cancer is the strongest predictor of spinal malignancy.

Blood pressure: seated and rested, arm at heart level, correct cuff, palpatory estimate first, deflate 2 to 3 mm Hg per second; systolic is phase I and diastolic phase V. Stage 1 starts at 130 or 80, stage 2 at 140 or 90, crisis over 180 and/or 120. Orthostatic hypotension is a fall of 20 systolic or 10 diastolic.

Head and neck: Weber goes to the bad ear in conductive loss and the good ear in sensorineural loss; a negative Rinne means conductive loss. Chest: consolidation is dull with increased fremitus, effusion stony dull with decreased fremitus, pneumothorax hyperresonant. Heart: S3 volume overload, S4 stiff ventricle, fixed split S2 ASD; diastolic murmurs are always abnormal.

Abdomen: inspect, auscultate, percuss, palpate. Murphy sign means cholecystitis; McBurney, Rovsing, psoas and obturator signs mean appendicitis. Indirect hernias lie lateral to the inferior epigastric vessels. Testicular torsion with an absent cremasteric reflex is an emergency.

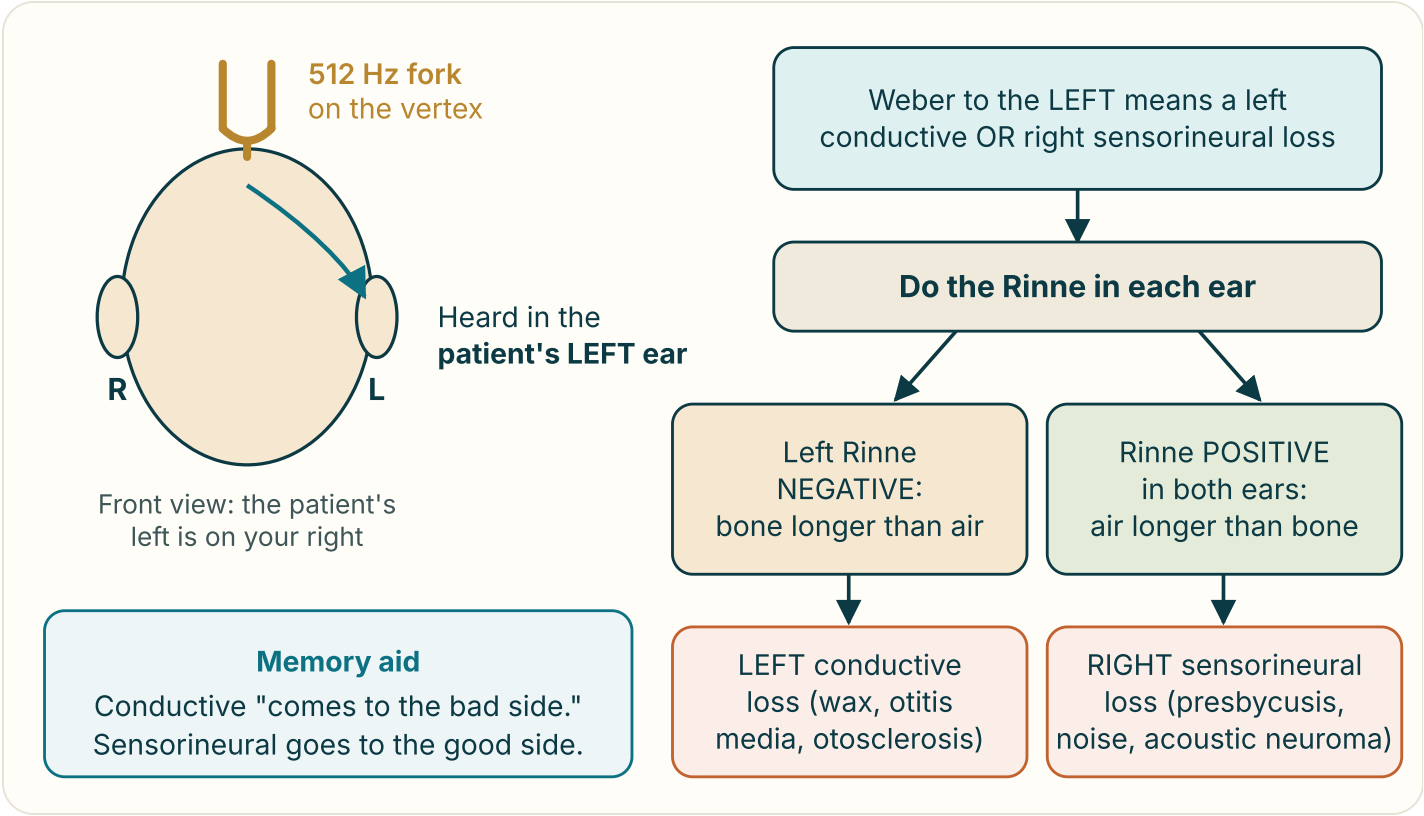

Weber first, Rinne decides. The Weber only tells you which side the sound goes to. A negative Rinne (bone longer than air) in that ear proves a conductive loss there; a positive Rinne in both ears means the other ear has a sensorineural loss.

LOCK THESE IN

- History order: CC, HPI, PMH, FH, SH, ROS. Characterize with OPQRST and record pertinent negatives.
- Prior cancer is the strongest predictor of spinal malignancy. Urinary retention is the most common cauda equina finding; saddle anesthesia is the classic sensory sign.
- Systolic is Korotkoff phase I, diastolic phase V. A cuff too small reads falsely high.
- Stage 1 starts at 130 or 80, stage 2 at 140 or 90, crisis over 180 and/or 120. Only one number needs to fall in a stage.
- Orthostatic hypotension: a fall of 20 systolic or 10 diastolic within 3 minutes of standing.
- Weber goes to the bad ear in conductive loss; a negative Rinne (BC greater than AC) confirms conductive loss.

Vital sign and exam numbers

Item	Value	Note
Pulse	60 to 100 per minute	Irregularly irregular means atrial fibrillation
Respiration	12 to 20 per minute	Count without telling the patient
Fever	38.0°C (100.4°F) or more	Rectal about 0.5°C higher, axillary 0.5°C lower
SpO_2	95 to 100%	Falsely normal in carbon monoxide poisoning
BMI	18.5 to 24.9 normal; 30 or more obesity	kg ÷ m^2
JVP	Over 3 to 4 cm above the sternal angle is high	Head of table at 30 to 45 degrees
ABI	1.0 to 1.4 normal; 0.90 or less PAD	Over 1.4 means calcified vessels
Murmur grade	IV/VI or louder has a thrill	Diastolic murmurs are always pathologic

Worked case

CASE 1.1 · BLOOD PRESSURE AND BMI

Two visits average 138/76 mm Hg. The patient weighs 95 kg and is 1.75 m tall.

STEP 1 · STAGE

Systolic 130 to 139 is stage 1, even with a normal diastolic.

STEP 2 · BMI

$95 \div 1.75^2 = 95 \div 3.06 =$ **31.0**: obesity class I (30 to 34.9).

STEP 3 · PLAN

Refer to the primary care provider for blood pressure and weight management.

TRAPS PEOPLE FALL INTO

- **Calling 134/78 "elevated."** Systolic 130 to 139 is stage 1 even when diastolic is normal. The higher category wins.
- **Recording diastolic at muffling in an adult.** Adults use phase V, disappearance. Phase IV is for children and pregnancy when sounds go to zero.
- **Blaming a large arm on the patient.** A cuff that is too small reads falsely high. Change the cuff, not the diagnosis.
- **Reading the Weber alone.** A Weber to the left fits a left conductive or a right sensorineural loss. The Rinne decides.

Chapter 1 self-test · six items

1. A seated reading averages 118/84 mm Hg on two visits. How is it classified?

A. Normal blood pressure
B. Stage 1 hypertension
C. Stage 2 hypertension
D. Elevated blood pressure

B. Stage 1 hypertension Diastolic 80 to 89 meets stage 1, even though systolic is normal.

2. Which item in a low back history most strongly predicts spinal malignancy?

A. A prior history of cancer
B. Pain at night in bed
C. Failure of a month of care
D. Age over 50 years

A. A prior history of cancer Prior cancer is the strongest single predictor; the others are weaker red flags.

3. Over the right base there is dullness, increased fremitus, bronchial sounds and egophony. What is present?

A. Pneumothorax
B. Pleural effusion
C. Consolidation
D. Emphysema

C. Consolidation Solid lung conducts vibration and sound well: consolidation, such as pneumonia.

4. A holosystolic blowing murmur at the apex radiates to the left axilla. Which lesion fits?

A. Mitral stenosis
B. Aortic regurgitation
C. Aortic stenosis
D. Mitral regurgitation

D. Mitral regurgitation Mitral regurgitation is holosystolic at the apex and radiates to the axilla.

5. A groin hernia enters the deep ring lateral to the inferior epigastric vessels. Which type is it?

A. Indirect inguinal hernia
B. Direct inguinal hernia
C. Femoral canal hernia
D. Umbilical wall hernia

A. Indirect inguinal hernia Indirect hernias pass lateral to the inferior epigastric vessels through the deep ring.

6. An ankle systolic of 76 and a brachial systolic of 152 mm Hg give what ABI and meaning?

A. 1.20, normal value
B. 0.50, arterial disease
C. 0.95, borderline value
D. 2.00, calcified vessels

B. 0.50, arterial disease 76 ÷ 152 = 0.50, well under the 0.90 threshold for PAD.

CHAPTER 2

Laboratory Interpretation and Special Studies

Read it in full: **Chapter 2 in the textbook**. Practice it: **Practice exam 1** and the **flashcards**.

What to know

Urinalysis: casts come from the kidney. Red cell casts mean glomerulonephritis, white cell casts pyelonephritis, muddy brown casts ATN, fatty casts nephrotic syndrome. A blood positive dipstick with no red cells means hemoglobin or myoglobin; the dipstick misses Bence Jones protein.

Anemia: MCV first, then reticulocytes. Low ferritin with high TIBC is iron deficiency, which in men and postmenopausal women means GI blood loss until proven otherwise. B12 deficiency raises methylmalonic acid and can damage the dorsal columns. PT/INR follows warfarin; aPTT follows heparin.

Chemistry: anion gap = Na − (Cl + HCO_3), normal 8 to 12. Diabetes is fasting 126, HbA1c 6.5% or OGTT 200. Osteoporosis has normal labs; Paget disease a very high ALP; myeloma high calcium with normal ALP; primary hyperparathyroidism high calcium and high PTH.

Test logic: sensitivity and specificity belong to the test; predictive values move with prevalence. SnNout, SpPin. A negative ANA nearly excludes lupus; anti-CCP is specific for RA; HLA-B27 is common in healthy people. Radiculopathy spares the SNAP and changes paraspinal EMG.

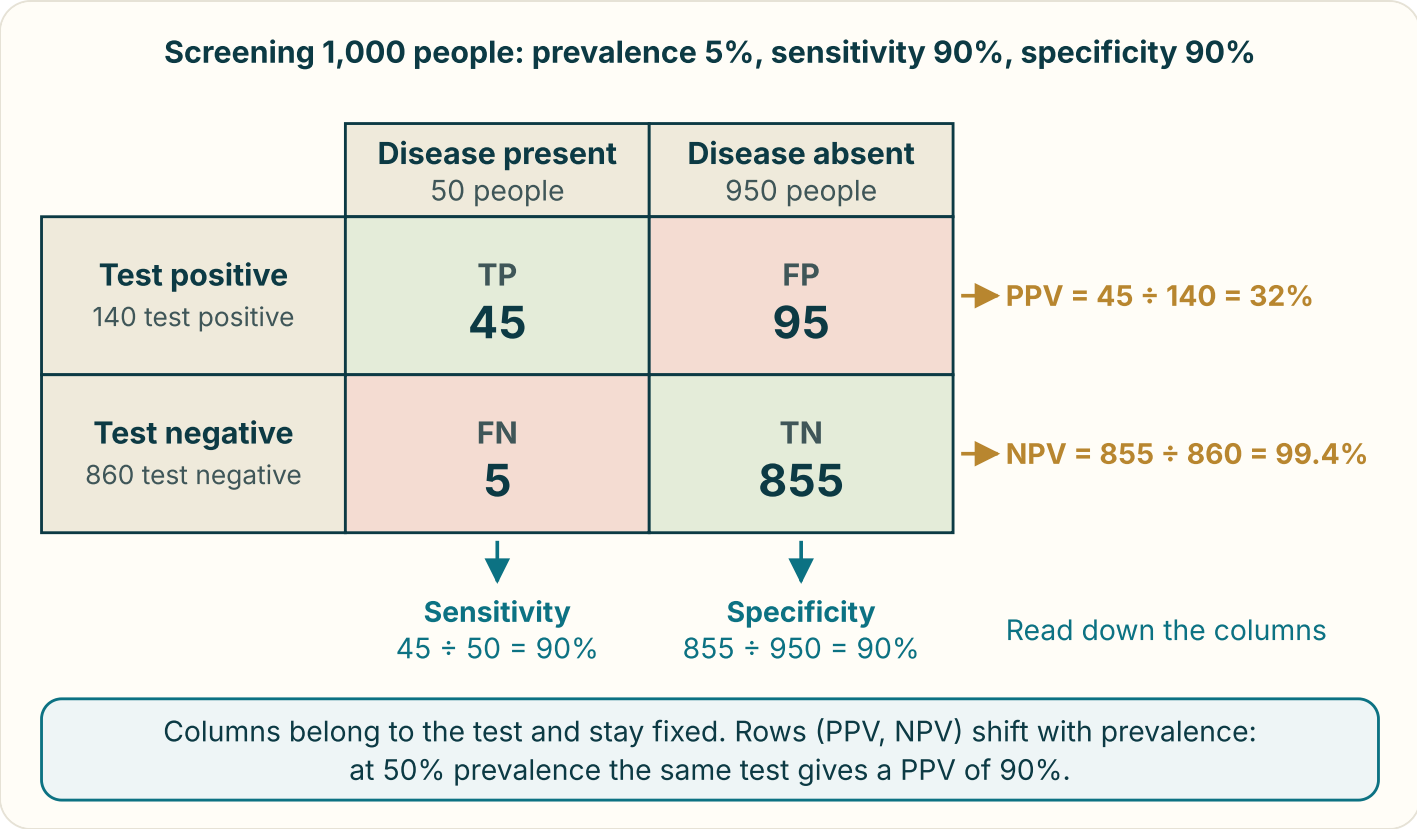

Read down for sensitivity and specificity, across for predictive values. With a rare disease, even a good test gives more false positives (95) than true positives (45), so the PPV is only 32% while the NPV is excellent.

LOCK THESE IN

- Casts localize to the kidney: red cell casts glomerulonephritis, white cell casts pyelonephritis, muddy brown casts ATN, fatty casts nephrotic syndrome.
- Blood on the dipstick with no red cells means hemoglobin or myoglobin. The dipstick misses Bence Jones protein.
- Low ferritin with high TIBC is iron deficiency; in men and postmenopausal women look for GI bleeding.
- PT/INR: warfarin, extrinsic, factor VII. aPTT: heparin, hemophilia, intrinsic.
- Anion gap = Na − (Cl + HCO_3), normal 8 to 12. Diabetes: fasting 126, OGTT 200, HbA1c 6.5%.
- Osteoporosis has normal labs. Paget: very high ALP. Myeloma: high calcium, normal ALP.

Formulas and ranges to know

Item	Formula or range	Use
Anion gap	Na − (Cl + HCO_3); normal 8 to 12	High gap: ketoacidosis, lactate, uremia, toxins
Corrected calcium	Ca + 0.8 × (4.0 − albumin)	Low albumin hides true calcium
Friedewald LDL	Total − HDL − TG ÷ 5	Invalid when TG is over about 400
ESR upper limit	Men age ÷ 2; women (age + 10) ÷ 2	mm/h, rough guide
Mentzer index	MCV ÷ RBC count	Under 13 favors thalassemia trait
Sensitivity	TP ÷ (TP + FN)	Rule out when negative
Specificity	TN ÷ (TN + FP)	Rule in when positive
PPV, NPV	TP ÷ (TP + FP); TN ÷ (TN + FN)	Change with prevalence
LR+, LR−	Sens ÷ (1 − spec); (1 − sens) ÷ spec	Over 10 or under 0.1 is strong
ECG rate	300 ÷ large boxes, or 1,500 ÷ small boxes	Irregular: QRS in 6 s × 10

Worked case

CASE 2.1 · CORRECTED CALCIUM

Calcium is 8.2 mg/dL and albumin is 3.0 g/dL.

STEP 1 · CORRECT

8.2 + 0.8 × (4.0 − 3.0) = 8.2 + 0.8 = **9.0 mg/dL**.

STEP 2 · READ

The corrected value is normal; the low measured calcium reflects low albumin.

TRAPS PEOPLE FALL INTO

- **Trusting a negative dipstick for protein in suspected myeloma.** The dipstick misses light chains. Order protein electrophoresis.
- **Calling a blood positive dipstick hematuria.** Check the microscopy. No red cells means hemoglobin or myoglobin.
- **Reassuring a 60 year old man with iron deficiency.** Iron deficiency in a man or postmenopausal woman is GI blood loss until proven otherwise. Refer.
- **Treating a positive ANA as lupus.** Low titers are common in healthy people. A negative ANA rules lupus out; anti-dsDNA and anti-Smith rule it in.

Chapter 2 self-test · six items

1. A febrile patient with flank pain has white cell casts. Where is the infection?

A. In the kidney

B. In the urethra

C. In the prostate

D. In the bladder only

A. In the kidney Casts form in the tubules, so white cell casts place the infection in the kidney.

2. Which test is most specific for iron deficiency?

A. Low serum iron
B. Low serum ferritin
C. A high RDW value
D. A low MCV value

B. Low serum ferritin Ferritin reflects stores and is the most specific test for iron deficiency.

3. Na 136, Cl 100 and HCO_3 24 mEq/L give what anion gap?

A. 24, high
B. 16, high
C. 12, normal
D. 8, low

C. 12, normal 136 − (100 + 24) = 12, within 8 to 12.

4. Which pattern fits osteomalacia?

A. All bone labs normal
B. High calcium, high PTH
C. Isolated very high ALP
D. Low phosphorus, high ALP

D. Low phosphorus, high ALP Osteomalacia lowers phosphorus and raises ALP and PTH; osteoporosis has normal labs.

5. A sensitive test is negative in a low risk patient. What does SnNout say?

A. It adds no information
B. It confirms the disease
C. It helps rule disease out
D. It raises the probability

C. It helps rule disease out A highly sensitive test has few false negatives, so a negative result rules out.

6. On ECG paper at 25 mm/s, there are 5 large boxes between R waves. What is the rate?

A. 75 per minute
B. 60 per minute
C. 100 per minute
D. 50 per minute

B. 60 per minute 300 ÷ 5 = 60 per minute.

CHAPTER 3

Diagnosis of Internal Disorders and When to Refer

Read it in full: **Chapter 3 in the textbook**. Practice it: **Practice exam 2** and the **flashcards**.

What to know

Internal disease presents to chiropractors as chest wall, interscapular, back and leg pain. Fremitus rises only in consolidation. Asthma is reversible; COPD is a post bronchodilator FEV_1/FVC under 0.70. PE follows Virchow triad and is an emergency.

Aorta: AAA is 3 cm or more; rupture risk climbs above 5.5 cm; screen men 65 to 75 who ever smoked. Dissection is sudden tearing pain with an arm difference over 20 mm Hg; Stanford A is a

surgical emergency. Vascular claudication eases standing still with low ABI; neurogenic claudication eases sitting or flexing.

Blood: myeloma (CRAB, punched out lesions, cold bone scan); B12 deficiency (subacute combined degeneration); platelet defects bleed into skin and mucosa, factor defects into joints. Visceral pain is segmental, unchanged by movement and tied to organ function.

Endocrine and infection: diabetes 126 or 6.5%; Chvostek and Trousseau mean hypocalcemia; osteoporosis T score −2.5. qSOFA 2 of 3 flags sepsis. One emergency flag means emergency referral, not more tests.

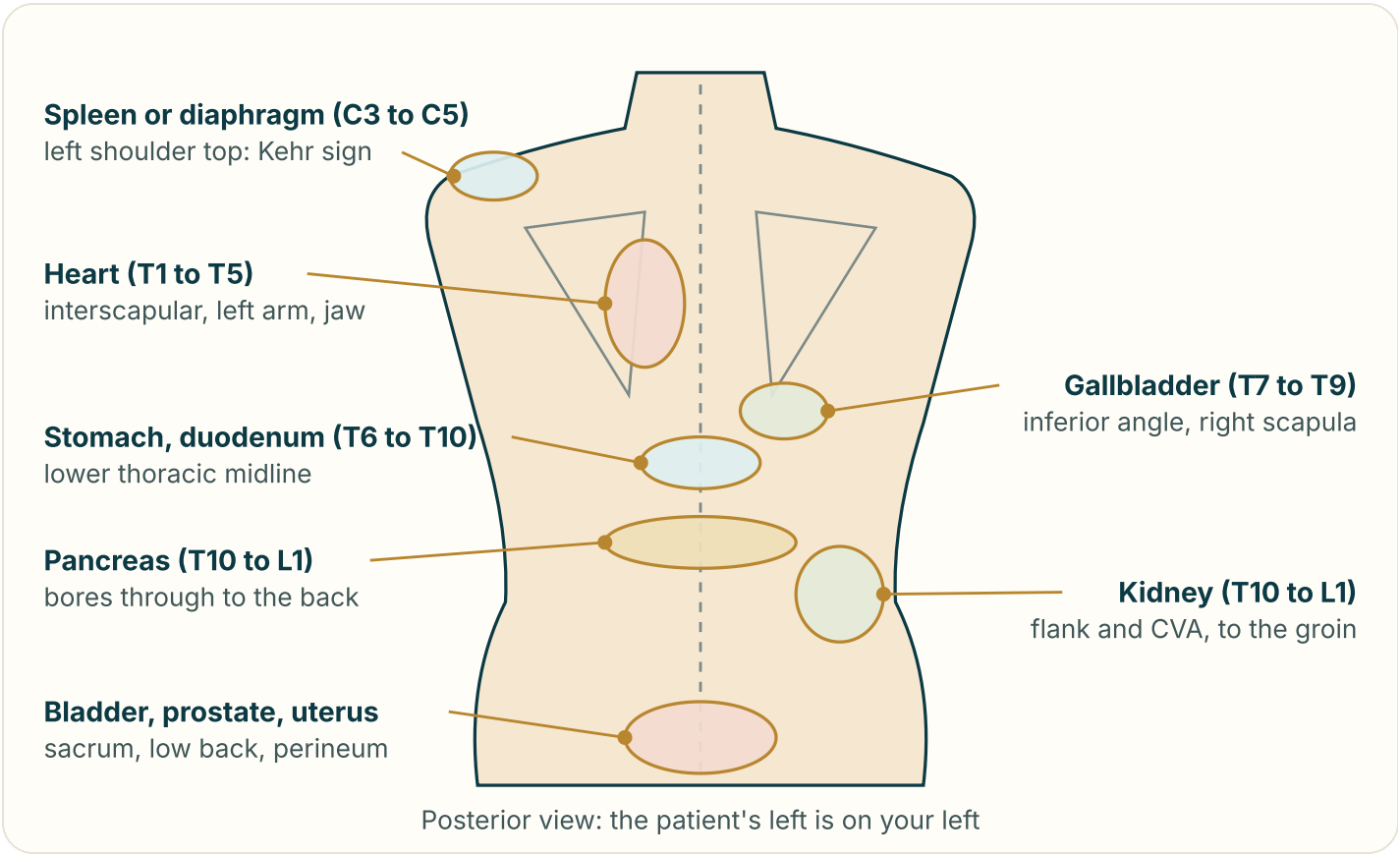

Organs project to the back along their segmental supply. None of these pains changes with spinal movement or palpation; each changes with the organ's own function, such as eating, urination or bowel habit.

LOCK THESE IN

- Fremitus rises only in consolidation. Effusion and pneumothorax lower it; percussion separates fluid (dull) from air (hyperresonant).
- AAA is 3 cm or more; rupture risk rises above 5.5 cm; screen men 65 to 75 who ever smoked.
- Dissection: sudden tearing pain, arm difference over 20 mm Hg. Stanford A (ascending) is a surgical emergency.
- Vascular claudication eases standing still with low ABI; neurogenic eases sitting or flexing with normal pulses.
- Myeloma: CRAB, punched out lesions, cold bone scan, pedicles spared early.
- B12 deficiency can damage the dorsal columns before anemia appears.

Visceral referral to the back

Organ	Segments (approx.)	Where pain is felt
Heart	T1 to T5	Substernal, left arm, jaw, interscapular
Esophagus	T4 to T6	Substernal, interscapular
Stomach, duodenum	T6 to T10	Epigastric, lower thoracic midline back
Gallbladder, liver	T7 to T9; phrenic C3 to C5	Right upper quadrant, right scapular angle, right shoulder
Pancreas	T10 to L1	Epigastric boring through to the thoracolumbar back
Kidney, upper ureter	T10 to L1	Flank and CVA, radiating to groin
Appendix	T10	Periumbilical, then right lower quadrant
Bladder, prostate, uterus	T11 to L2 and S2 to S4	Suprapubic, sacrum, low back, perineum
Spleen or diaphragm	Phrenic C3 to C5	Top of the shoulder (Kehr sign on the left)

Worked case

CASE 3.1 · ONE EMERGENCY FLAG

A 70 year old smoker has sudden tearing midback pain, a systolic of 168 in the right arm and 140 in the left.

STEP 1 · ARM DIFFERENCE

168 − 140 = 28 mm Hg, over 20.

STEP 2 · PATTERN

Sudden tearing pain with an arm difference suggests aortic dissection.

STEP 3 · ACT

Call emergency services now; do not image or treat in the office.

TRAPS PEOPLE FALL INTO

- **Reassuring because the chest wall is tender.** Reproducible tenderness lowers but never removes cardiac risk. An ischemic history means referral.
- **Ordering more tests when one emergency flag is present.** Saddle anesthesia, tearing pain, a pulsatile mass or fever with confusion means emergency referral now.
- **Using a provocative or Homans sign to clear a DVT.** Homans is neither sensitive nor specific. Refer for duplex ultrasound and do not massage the limb.
- **Trusting a normal bone scan in suspected myeloma.** Myeloma is often cold on bone scan because the lesions are purely lytic.

Chapter 3 self-test · six items

1. Which finding favors vascular over neurogenic claudication?

A. Relief by standing still

B. Normal pedal pulses

C. A shopping cart sign

D. Relief only by sitting

A. Relief by standing still Vascular claudication eases on standing still; the others point to spinal stenosis.

2. Epigastric pain boring to the back, eased by leaning forward, after heavy drinking suggests?

A. Renal colic
B. Cholecystitis
C. Appendicitis
D. Pancreatitis

D. Pancreatitis Pancreatic pain bores through to the back and eases leaning forward.

3. Older adult, back pain at rest, anemia, high calcium and a cold bone scan. Most likely?

A. Osteoporosis
B. Metastatic prostate
C. Multiple myeloma
D. Paget disease

C. Multiple myeloma CRAB features with a cold scan point to myeloma.

4. Which bleeding pattern suggests hemophilia rather than a platelet disorder?

A. Heavy menstrual flow
B. Recurrent hemarthroses
C. Bleeding of the gums
D. Petechiae and purpura

B. Recurrent hemarthroses Factor defects bleed deep into joints and muscles; platelet defects bleed into skin and mucosa.

5. Tapping the facial nerve makes the mouth twitch. What is the likely electrolyte problem?

A. High calcium
B. High potassium
C. Low sodium
D. Low calcium

D. Low calcium A positive Chvostek sign means hypocalcemia.

6. A pulsatile, expansile mass above the umbilicus with deep back pain unchanged by position needs what?

A. A trial of care first
B. Emergency referral
C. Lumbar manipulation
D. Deep palpation to size it

B. Emergency referral This suggests a leaking abdominal aortic aneurysm.

CHAPTER 4

History, Posture, Gait and Orthopedic Tests of the Spine and Pelvis

Read it in full: **Chapter 4 in the textbook**. Practice it: **Practice exam 2** and the **flashcards**.

What to know

Pain types: radicular pain is sharp, dermatomal and usually below the knee; somatic referred pain is dull, diffuse and above it; radiculopathy adds objective deficits; myelopathy adds UMN signs. Inflammatory back pain: under 40, insidious, better with exercise, not rest, night pain.

Posture and gait: the lateral plumb line runs slightly anterior to the lateral malleolus and knee axis, then through the trochanter, lumbar bodies, acromion and ear. A rib hump on the Adams test means a structural curve. Trendelenburg gait means a weak gluteus medius on the stance side; steppage gait means weak dorsiflexors.

Cervical and thoracic tests: Spurling with arm pain means root; local pain means facet; distraction relief supports root compression. Vertebral artery tests have poor sensitivity. Schepelmann concave pain is intercostal neuritis; Beevor sign localizes to about T10; Adson, Eden and Wright target the three outlet sites.

Lumbopelvic tests: SLR positive 30 to 70 degrees; crossed SLR specific; Kemp local pain facet; Milgram, Valsalva and Naffziger space occupying lesion; FABERE groin hip, posterior SI; Thomas iliopsoas, Ely rectus femoris, Ober IT band. Waddell 3 of 5 and Hoover flag nonorganic behavior.

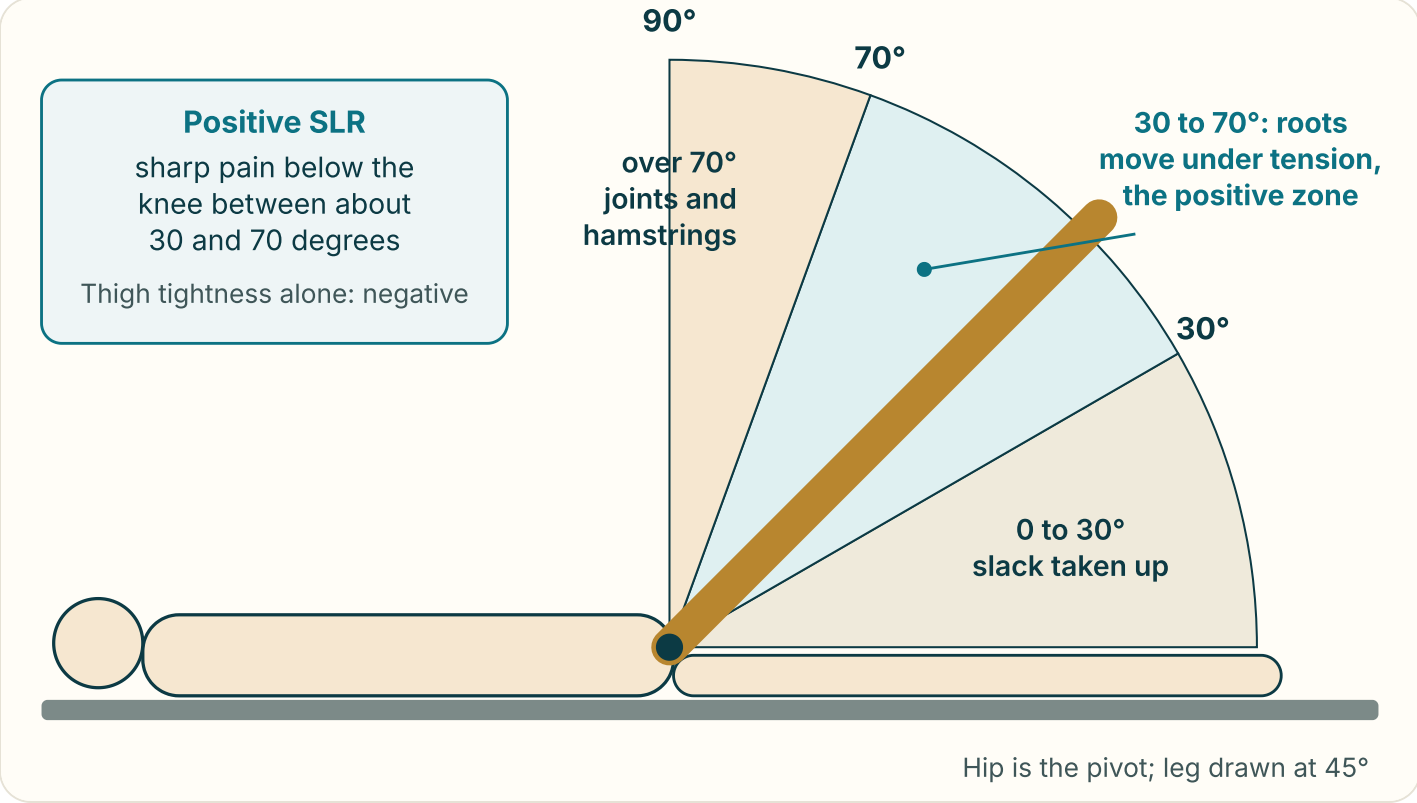

Where the pain appears matters as much as whether it appears. Radicular pain below the knee between about 30 and 70 degrees is the classic positive. Tightness behind the thigh, or pain only past 70 degrees, comes from hamstrings and joints.

LOCK THESE IN

- Radicular pain is sharp and below the knee; somatic referred pain is dull and above it; radiculopathy adds objective deficits.
- Inflammatory back pain: under 40, insidious, better with exercise, not with rest, night pain (4 of 5).
- Adams: rib hump means structural; the hump is on the convex side. Painful or left thoracic curves need MRI.
- Trendelenburg gait means a weak gluteus medius on the stance side; steppage means weak dorsiflexors.
- Spurling arm pain means root; local pain means facet. Distraction relief supports root compression.
- Vertebral artery tests have poor sensitivity; history decides, and any positive means no manipulation.

Key spinal and pelvic tests

Test	Positive finding	Suggests
Spurling	Radicular arm pain with extension, bend and axial load	Cervical radiculopathy (specific)
Distraction	Relief of arm or neck pain	Root compression or facet capsulitis
Bakody	Hand on head relieves arm pain	C5 or C6 root compression
Lhermitte	Electric shock with neck flexion	Dural or cord irritation (MS, myelopathy)
Soto Hall	Local spinous pain on neck flexion	Posterior ligament or vertebral lesion
Schepelmann	Concave pain; convex pain	Intercostal neuritis; pleuritis or muscle
Beevor	Umbilicus moves up	Lesion around T10
Adson / Eden / Wright	Symptoms with pulse change	Interscalene / costoclavicular / pectoralis minor
SLR	Radicular pain 30 to 70 degrees	L4 to S1 root tension (sensitive)
Crossed SLR	Pain in the symptomatic leg	Disc herniation (specific)
Kemp	Local pain; radiating pain	Facet; nerve root
Milgram, Valsalva, Naffziger	Back or leg pain	Space occupying lesion
FABERE	Groin; posterior pelvis	Hip; sacroiliac
Thomas / Ely / Ober	Thigh rises / buttock rises / leg stays up	Iliopsoas / rectus femoris / IT band

Worked case

CASE 4.1 · SCORING THE NDI

A patient's Neck Disability Index is 24 of 50 at intake and 16 at follow up.

STEP 1 · PERCENT

24 ÷ 50 = 48% at intake; 16 ÷ 50 = 32% at follow up.

STEP 2 · CHANGE

24 − 16 = 8 points, more than the 5 to 7 point MCID: a meaningful improvement.

TRAPS PEOPLE FALL INTO

- **Clearing the neck with a negative vertebral artery test.** These tests have poor sensitivity. The history of sudden unusual pain with brainstem signs decides.
- **Calling buttock and thigh pain radicular.** Somatic referred pain stays above the knee and has no deficits. Radicular pain usually goes below.
- **Calling a hamstring pull at 80 degrees a positive SLR.** Back or posterior thigh tightness, or pain only beyond 70 degrees, is not a positive.
- **Mixing up Thomas and Ely.** Thomas: the thigh rises (iliopsoas). Ely: the buttock rises (rectus femoris).

Chapter 4 self-test · six items

1. Sharp pain from the buttock to the lateral foot that worsens with coughing is best described as?

A. Radicular pain
B. Visceral referred
C. Nociplastic
D. Somatic referred

A. Radicular pain Sharp, narrow, below the knee and worse with cough is radicular.

2. A rib hump appears on the right during the Adams test. What does it indicate?

A. A leg length difference
B. A functional curve
C. A structural right curve
D. A left convex curve

C. A structural right curve A rib hump means rotation, a structural curve, with the hump on the convex side.

3. Spurling testing on the left gives only local left neck pain. What is suggested?

A. Thoracic outlet syndrome
B. Left C6 radiculopathy
C. Cervical myelopathy
D. Left facet irritation

D. Left facet irritation Local pain with compression points to the facet; arm pain would point to the root.

4. Which test targets compression beneath the pectoralis minor?

A. Adson test
B. Wright test
C. Roos test
D. Eden test

B. Wright test Wright targets the subcoracoid space; Adson the interscalene triangle; Eden the costoclavicular space.

5. In the prone Ely test the buttock rises as the knee flexes. What is tight?

A. Rectus femoris
B. Hamstrings
C. Iliotibial band
D. Iliopsoas

A. Rectus femoris Buttock rise in Ely means rectus femoris tightness.

6. A patient lifts the affected leg but the opposite heel does not press down. What is this sign?

A. A positive Patrick sign
B. A positive Milgram sign
C. A positive Hoover sign
D. A positive Lasegue sign

C. A positive Hoover sign No counterpressure means no genuine effort, a nonorganic finding.

CHAPTER 5

Orthopedic Examination of the Extremities and Musculoskeletal Diagnosis

Read it in full: **Chapter 5 in the textbook**. Practice it: **Practice exam 3** and the **flashcards**.

What to know

Shoulder: painful arc 60 to 120 degrees means impingement; pain at 170 to 180 degrees means the AC joint. Strength tests find tears (empty can, drop arm, ER lag, lift off). Apprehension and relocation find anterior instability. Adhesive capsulitis loses active and passive motion, external rotation worst.

Elbow, wrist and hand: Cozen and Mill find lateral epicondylopathy; Tinel, Phalen and Durkan find carpal tunnel syndrome, which spares thenar skin; Froment and Wartenberg mean ulnar palsy; Finkelstein finds de Quervain. Snuffbox tenderness after a fall means a scaphoid fracture until proven otherwise.

Hip and knee: lost internal rotation is the first sign of hip joint disease; SCFE shows obligatory external rotation with flexion. Lachman is the most sensitive ACL test, pivot shift the most specific; posterior sag finds the PCL; McMurray and Apley find menisci.

Ankle and diagnosis: inversion sprains tear the ATFL first; Thompson finds Achilles rupture; Ottawa rules decide films. OA favors DIP and PIP; RA symmetric MCP and wrist, sparing DIP; gout negative and CPPD positive birefringence. Compartment syndrome shows pain out of proportion first.

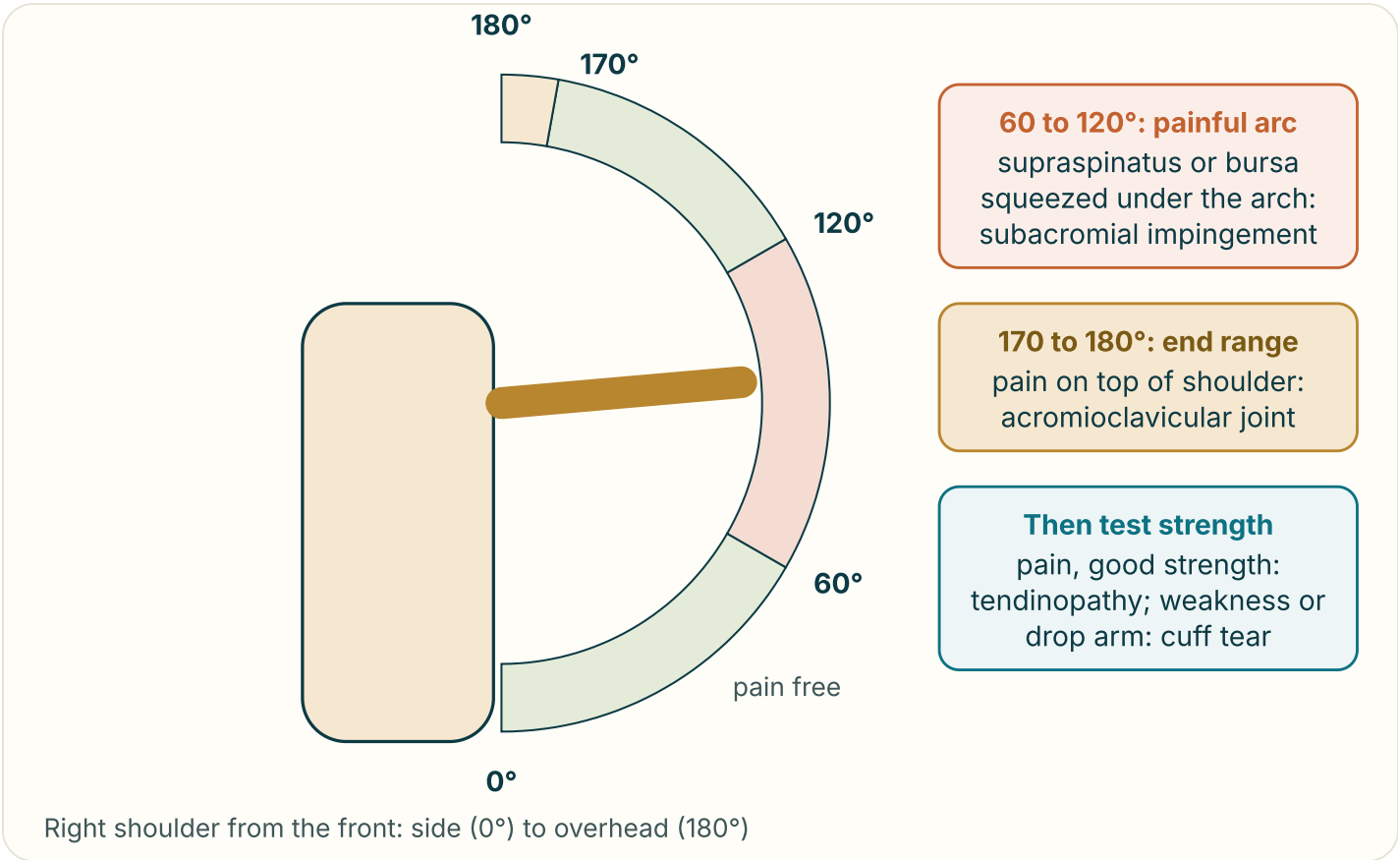

Right shoulder from the front: side (0°) to overhead (180°)

Where in the arc it hurts tells you which structure is pinched. Mid range pain that eases above 120° is subacromial impingement; pain only at the top of the arc is the AC joint. Strength testing then separates tendinopathy from a tear.

LOCK THESE IN

- Painful arc 60 to 120° is impingement; 170 to 180° is the AC joint.
- Pain with good strength is tendinopathy; weakness, drop arm or ER lag is a tear.
- Adhesive capsulitis loses active and passive motion, external rotation worst, with normal films.
- Carpal tunnel spares thenar skin; Froment and Wartenberg mean ulnar palsy.
- Lachman is the most sensitive ACL test, pivot shift the most specific; sag sign finds the PCL.
- Ottawa ankle: posterior edge or tip of either malleolus, navicular, fifth metatarsal base, or four steps.

Extremity tests by structure

Test	Positive finding	Suggests
Neer, Hawkins	Pain under the acromion	Subacromial impingement
Empty can / drop arm	Weakness / arm drops	Supraspinatus tear / full thickness tear
Lift off, belly press	Cannot lift hand off back / elbow drops back	Subscapularis tear
Apprehension, relocation	Fear relieved by posterior force	Anterior instability
Yergason, Speed / O'Brien	Bicipital groove pain / deep pain thumb down	Biceps tendinopathy / SLAP lesion
Cozen, Mill	Lateral epicondyle pain	Lateral epicondylopathy (ECRB)
Tinel, Phalen, Durkan	Median paresthesia	Carpal tunnel syndrome
Finkelstein	Radial styloid pain	de Quervain tenosynovitis
Lachman / pivot shift	Anterior translation / clunk	ACL tear (sensitive / specific)
Posterior sag	Tibia sags back	PCL tear
McMurray, Apley compression	Painful click; pain	Meniscal tear
Anterior drawer (ankle) / talar tilt	Talus translates / tilts	ATFL / CFL tear
Thompson	No plantarflexion	Complete Achilles rupture
Mulder	Painful click	Morton neuroma

Worked case

CASE 5.1 · OTTAWA ANKLE

After an inversion injury, a patient cannot take four steps in the office and the posterior tip of the lateral malleolus is tender.

STEP 1 · CRITERIA

Both bone tenderness at the posterior tip of the lateral malleolus and inability to bear weight four steps are met.

STEP 2 · DECIDE

An ankle series is indicated before any treatment.

TRAPS PEOPLE FALL INTO

- **Trusting Neer and Hawkins to find a tear.** They are sensitive for a painful subacromial space, not specific. Strength tests find tears.
- **Calling every stiff shoulder frozen.** A shoulder that cannot externally rotate passively may be arthritic or posteriorly dislocated. Get an axillary or Y view.
- **Expecting thenar numbness in carpal tunnel.** The palmar cutaneous branch passes over the ligament, so thenar skin is spared. Thenar numbness means a proximal lesion.
- **Clearing a FOOSH wrist with normal films.** Scaphoid fractures may be occult. Snuffbox tenderness means a thumb spica and repeat imaging or MRI.

Chapter 5 self-test · six items

1. Shoulder pain appears at 70 degrees of abduction and eases above 120 degrees. What is suggested?

A. Subacromial impingement

B. Adhesive capsulitis

C. Biceps tendon rupture

D. AC joint arthrosis

A. Subacromial impingement A painful arc from about 60 to 120 degrees means impingement.

2. Which test is used to look for a SLAP lesion of the superior labrum?

A. Hawkins test
B. Sulcus sign
C. Speed test
D. O'Brien test

D. O'Brien test Deep pain thumb down that eases palm up suggests a SLAP lesion.

3. Ring and little finger numbness with a positive Froment sign suggests which nerve?

A. Median nerve
B. Axillary nerve
C. Ulnar nerve
D. Radial nerve

C. Ulnar nerve Froment sign shows a weak adductor pollicis from ulnar palsy.

4. Which hip condition affects boys aged about 4 to 8 with a painless limp?

A. Slipped capital epiphysis
B. Legg Calvé Perthes disease
C. Transient synovitis
D. Developmental dysplasia

B. Legg Calvé Perthes disease Perthes is avascular necrosis of the femoral head in boys about 4 to 8.

5. Which knee test is the most specific for an ACL tear?

A. Pivot shift
B. McMurray
C. Lachman
D. Anterior drawer

A. Pivot shift The pivot shift is the most specific; Lachman is the most sensitive.

6. Needle shaped, negatively birefringent crystals in joint fluid indicate what?

A. Sepsis
B. OA
C. Gout
D. CPPD

C. Gout Monosodium urate crystals are needle shaped and negatively birefringent.

CHAPTER 6

The Neurologic Examination and Neurologic Diagnosis

Read it in full: **Chapter 6 in the textbook**. Practice it: **Practice exam 3** and the **flashcards**.

What to know

Cranial nerves follow the rule of four; crossed signs mean brainstem. UMN facial palsy spares the forehead. The uvula deviates away from and the tongue toward the lesion. Cerebellar signs are ipsilateral; Romberg tests proprioception.

Motor: grade 3 is full range against gravity. UMN lesions are spastic with brisk reflexes and Babinski; LMN lesions are flaccid with atrophy and fasciculations. UMN and LMN signs together with normal sensation suggest ALS.

Sensory and reflexes: dorsal columns stay ipsilateral to the medulla; spinothalamic fibers cross within a segment or two (Brown Séquard splits the deficits). Reflexes: biceps C5, brachioradialis C6, triceps C7, patellar L4, medial hamstring L5, Achilles S1.

Diagnosis: a posterolateral L4 to L5 disc catches L5; a C5 to C6 disc catches C6. Myelopathy gives clumsy hands and UMN signs; cauda equina gives saddle anesthesia, retention and LMN signs. Dissection starts as new neck pain or headache with the 5 Ds and 3 Ns.

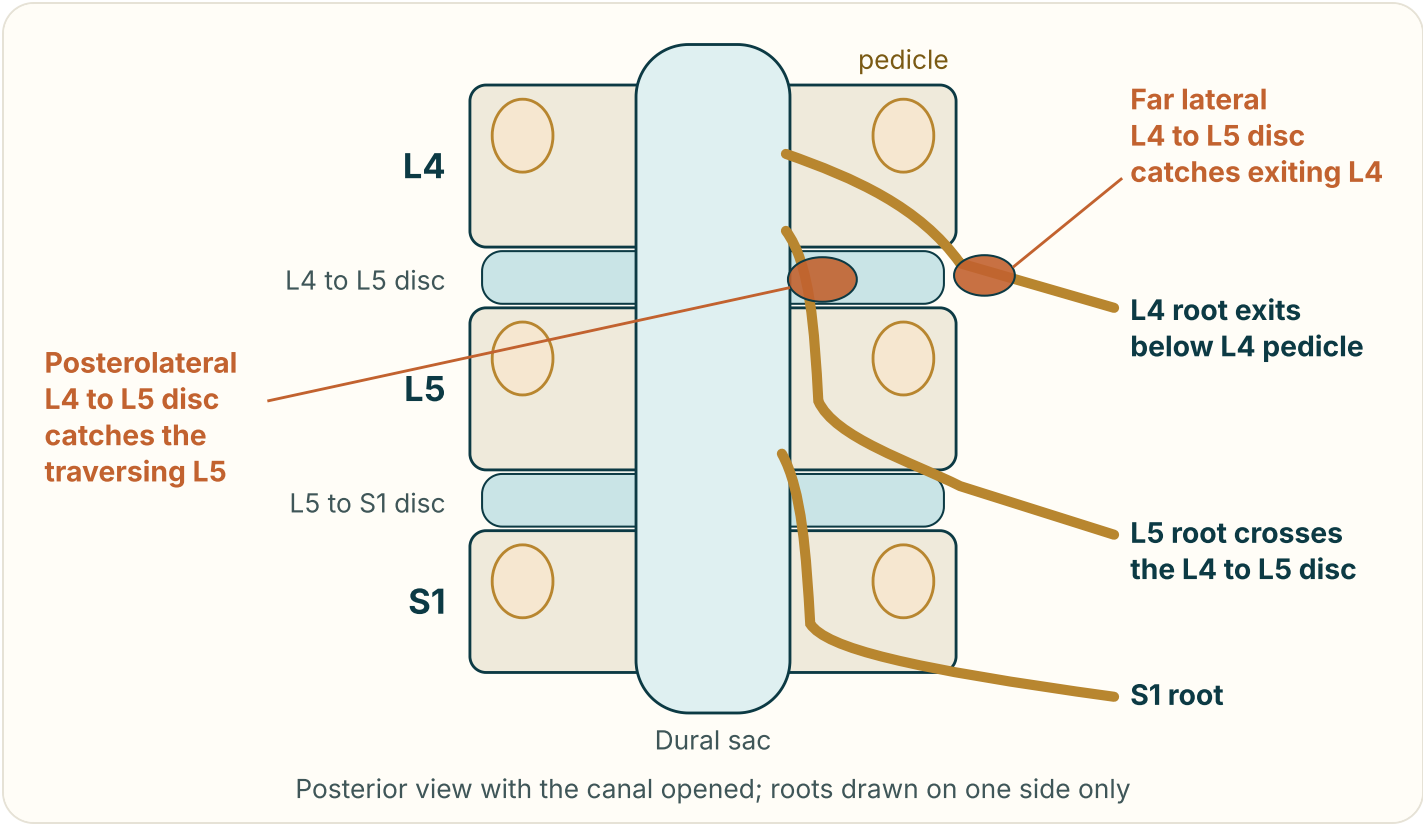

Posterior view with the canal opened; roots drawn on one side only

Posterolateral L4 to L5 catches L5; far lateral catches L4. Each lumbar root exits below the pedicle of its own vertebra, so it first crosses the disc above. A typical posterolateral herniation therefore hits the next root down.

LOCK THESE IN

- Rule of four: I to II above, III to IV midbrain, V to VIII pons, IX to XII medulla. Crossed signs mean brainstem.
- UMN facial palsy spares the forehead. Uvula away from, tongue toward the lesion.
- Cerebellar signs are ipsilateral; Romberg tests proprioception, not the cerebellum.
- Strength grade 3 is full range against gravity only.
- Reflexes: biceps C5, brachioradialis C6, triceps C7, patellar L4, medial hamstring L5, Achilles S1.
- Brown Séquard: everything ipsilateral except pain and temperature.

Root levels at a glance

Root (usual disc)	Sensory	Weakness	Reflex
C5 (C4 to C5)	Lateral arm	Deltoid, biceps	Biceps
C6 (C5 to C6)	Lateral forearm, thumb, index	Wrist extensors, biceps	Brachioradialis
C7 (C6 to C7)	Middle finger	Triceps, wrist flexors	Triceps
C8 (C7 to T1)	Little finger, medial forearm	Finger flexors, intrinsics	Finger flexor
L4 (L3 to L4)	Medial leg, medial malleolus	Tibialis anterior, quadriceps	Patellar
L5 (L4 to L5)	Lateral leg, dorsum of foot, great toe	EHL, gluteus medius, inversion	Medial hamstring (unreliable)
S1 (L5 to S1)	Lateral foot, sole, little toe	Gastrocnemius, peroneals, gluteus maximus	Achilles

Worked case

CASE 6.1 · LOCALIZE BY REFLEX

A patient has thumb numbness, weak wrist extension and a reduced brachioradialis reflex.

STEP 1 · MATCH

Thumb, wrist extensors and brachioradialis all point to **C6**.

STEP 2 · FIND THE DISC

Cervical roots exit above their pedicle, so a C5 to C6 disc compresses C6.

TRAPS PEOPLE FALL INTO

- **Calling a positive Romberg cerebellar.** Romberg tests proprioception and vestibular input. Cerebellar patients sway with eyes open too.
- **Calling a forehead sparing palsy Bell palsy.** Forehead sparing means an UMN lesion such as stroke. Bell palsy weakens the whole half face.

- **Expecting Babinski in cauda equina syndrome.** Cauda equina is a root (LMN) syndrome: reduced reflexes and flaccid weakness.
- **Assigning an L4 to L5 disc to the L4 root.** A posterolateral L4 to L5 disc catches the traversing L5 root. Only a far lateral disc catches L4.

Chapter 6 self-test · six items

1. A brisk jaw jerk places an UMN lesion where?

A. In the medulla
B. At the trigeminal
C. Above the pons
D. In the cervical cord

C. Above the pons A brisk jaw jerk means an UMN lesion above the pons.

2. Which reflex tests mainly the L4 root?

A. Patellar reflex
B. Medial hamstring reflex
C. Achilles reflex
D. Cremasteric reflex

A. Patellar reflex The patellar reflex is L4 (L2 to L4).

3. Spastic weakness of the right leg with right vibration loss and left pain loss suggests?

A. Anterior cord syndrome
B. Right cord hemisection
C. Left cord hemisection
D. Central cord syndrome

B. Right cord hemisection Brown Séquard: ipsilateral motor and dorsal column loss, contralateral pain loss.

4. Which sign is expected in cauda equina syndrome?

A. Positive Babinski sign
B. Sustained ankle clonus
C. A positive Hoffmann
D. Reduced ankle reflexes

D. Reduced ankle reflexes Cauda equina is a root (LMN) syndrome with reduced reflexes.

5. Ptosis, miosis and anhidrosis on one side describe what?

A. Horner syndrome
B. Argyll Robertson pupil
C. Third nerve palsy
D. Marcus Gunn pupil

A. Horner syndrome Interrupted oculosympathetic fibers give ptosis, miosis and anhidrosis.

6. A young adult cannot adduct the left eye on right gaze, with nystagmus of the right eye. Likely lesion?

A. Right CN III palsy
B. Left CN VI palsy
C. Right frontal lesion
D. Left MLF lesion

D. Left MLF lesion Internuclear ophthalmoplegia: failed adduction on the side of the MLF lesion.

CHAPTER 7

Imaging Technology, Positioning, Normal Anatomy and Special Imaging

Read it in full: **Chapter 7 in the textbook**. Practice it: **Practice exam 4** and the **flashcards**.

What to know

Physics: mAs controls quantity and density; kVp controls energy and contrast; the 15% rule trades them; the inverse square law sets mAs for distance. Photoelectric absorption makes contrast and patient dose; Compton scatter makes fog and staff dose. Collimation is the cheapest dose reduction.

Protection: ALARA, justify and optimize. Limits: 50 mSv a year for workers, 5 mSv for a declared pregnancy, 1 mSv for the public. Ask about pregnancy at about 12 to 50; the 10 day rule schedules elective pelvic films.

Positioning and anatomy: cervical posterior obliques show the far foramina; lumbar posterior obliques show the near pars (Scotty dog). ADI 3 mm adult, 5 mm child; retropharyngeal 7 mm at C2; retrotracheal 22 mm at C6. Know the Mach band and other variants.

Mensuration and MRI: McGregor, Chamberlain and McRae lines test basilar impression; Meyerding grades by quarters; Cobb 10 degrees is scoliosis. T1 fat bright; T2 and STIR fluid bright; scar enhances, disc does not. No imaging for uncomplicated spinal pain in the first 6 weeks.

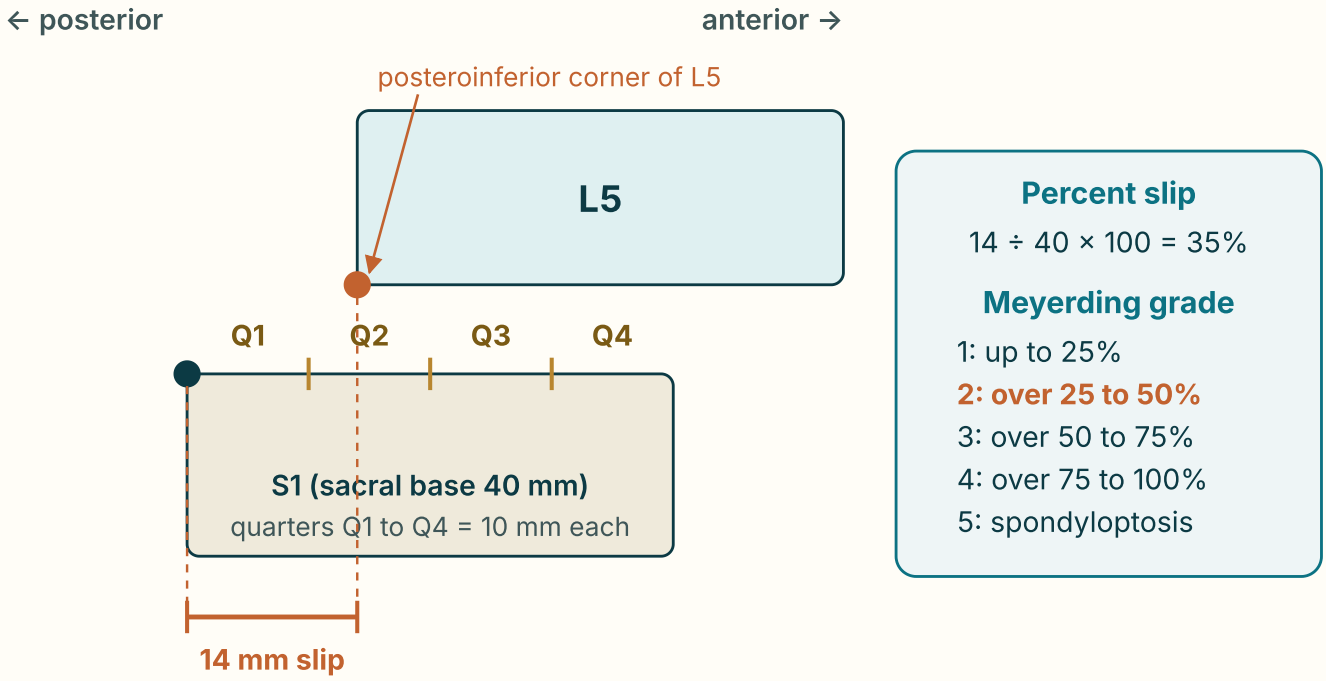

Which quarter has the corner reached? Divide the sacral base into quarters and find the posteroinferior corner of L5. Here a 14 mm slip on a 40 mm base is 35%, Meyerding grade 2.

LOCK THESE IN

- mAs controls density; kVp controls contrast; 15% kVp equals double mAs.
- Inverse square law: double the distance, one quarter the intensity, four times the mAs.
- Photoelectric makes contrast and patient dose; Compton makes fog and staff dose.
- Occupational limit 50 mSv a year; pregnant worker 5 mSv; public 1 mSv; background about 3 mSv.
- Cervical posterior oblique shows the far foramina; lumbar posterior oblique shows the near pars.
- ADI 3 mm adult, 5 mm child; retropharyngeal 7 mm at C2; retrotracheal 22 mm at C6.

Mensuration normals

Measurement	Normal	Abnormal means
ADI	3 mm or less adult; 5 mm child	Transverse ligament insufficiency
McGregor	Dens 8 mm (men) or 10 mm (women) above at most	Basilar impression
Chamberlain / McRae	About 3 mm above at most / dens below	Basilar impression
Martin basilar angle	120 to 150 degrees	Over 150: platybasia
Cervical canal	Over about 13 mm	Under 10 mm absolute stenosis
Flexion extension	Translation 3.5 mm, angulation 11 degrees at most	Ligamentous instability
Ferguson angle	About 26 to 57 degrees (average 41)	Increase: hyperlordosis, facet load
Meyerding	Grade 1 to 25%, 2 to 50%, 3 to 75%, 4 to 100%	Grade 5: spondyloptosis
Cardiothoracic ratio	Under 0.5 on a PA film	Cardiomegaly
Lumbar canal (Eisenstein)	Over about 15 mm	Stenosis

Worked case

CASE 7.1 · DISTANCE CHANGE

A chest technique of 5 mAs at 72 inches is repeated at 40 inches.

STEP 1 · RATIO

New mAs = $5 \times (40 \div 72)^2 = 5 \times 0.309 =$ **1.5 mAs**.

STEP 2 · WHY

A shorter distance raises intensity, so less mAs keeps the same exposure, but magnification rises.

TRAPS PEOPLE FALL INTO

- **Saying kVp controls density.** mAs is the primary controller of density; kVp is the primary controller of contrast.
- **Putting the thick end under the anode.** The heel effect lowers intensity on the anode side. Thick part under the cathode.
- **Trusting a nice digital image.** Digital rescaling hides overexposure. Watch the exposure index for dose creep.
- **Reading the near cervical foramen on a posterior oblique.** Cervical posterior obliques show the far foramina; lumbar posterior obliques show the near pars.

Chapter 7 self-test · six items

1. Doubling the mAs while keeping kVp the same mainly does what?

A. Reduces scatter fog
B. Doubles density and dose
C. Increases penetration
D. Raises image contrast

B. Doubles density and dose mAs controls the quantity of photons, density and dose.

2. Which interaction is responsible for most patient dose and image contrast?

A. Photoelectric effect
B. Compton scattering
C. Pair production
D. Coherent scatter

A. Photoelectric effect Photoelectric absorption rises with atomic number and makes contrast and dose.

3. What is the commonly taught public annual dose limit?

A. 20 mSv
B. 5 mSv
C. 50 mSv
D. 1 mSv

D. 1 mSv The public limit is 1 mSv a year.

4. On a lumbar posterior oblique, a lucent collar across the neck of the Scotty dog means what?

A. A pedicle break
B. A transitional L5
C. A pars defect
D. Facet arthrosis

C. A pars defect The neck of the dog is the pars interarticularis; a collar is spondylolysis.

5. What adult retrotracheal space at C6 is the upper limit of normal?

A. About 13 mm
B. About 7 mm
C. About 3 mm
D. About 22 mm

D. About 22 mm Retrotracheal up to about 22 mm in adults (14 mm in children).

6. On MRI, which tissue is bright on T1?

A. Edema
B. CSF
C. Fat
D. Bone

C. Fat Fat and normal fatty marrow are bright on T1; water is dark.

CHAPTER 8

Imaging Diagnosis

Read it in full: **Chapter 8 in the textbook**. Practice it: **Practice exam 4** and the **flashcards**.

What to know

Anomalies and trauma: a block vertebra has a wasp waist; os odontoideum is a smooth ossicle with a big rounded C1 arch. Jefferson overhang over 7 mm means transverse ligament rupture; type II odontoid heals worst; burst fractures widen the interpediculate distance; Chance fractures split all three columns.

Slips: isthmic at L5 with a pars defect; degenerative at L4 with an intact pars. Arthritis: OA non uniform with osteophytes; RA uniform with osteoporosis and atlantoaxial instability; AS bilateral symmetric sacroiliitis with marginal syndesmophytes; DISH four levels with normal discs.

Tumors: over 40, think metastasis (missing pedicle, disc spared) or myeloma (punched out lesions, cold bone scan). Hemangioma shows vertical striations; osteoid osteoma has night pain relieved by aspirin; giant cell tumor is epiphyseal to the joint surface.

Metabolic and infection: Paget disease enlarges bone; Looser zones mean osteomalacia; radial phalangeal resorption means hyperparathyroidism; rugger jersey spine means renal osteodystrophy. Infection crosses the disc; TB spares it early and forms a gibbus.

Pyogenic discitis

anterior → right

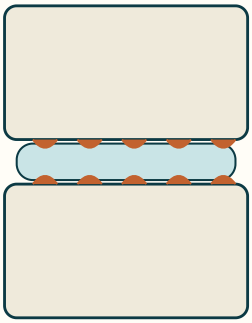

Disc narrows first, then both endplates erode: crosses the disc

Metastasis

anterior → right

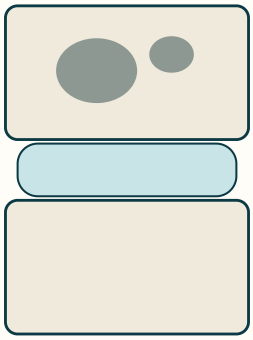

Disc preserved; body destroyed; pedicle lost on the AP (winking owl)

Tuberculosis

anterior → right

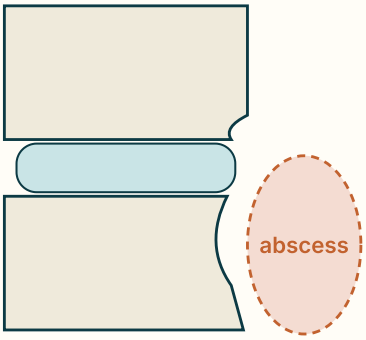

Spreads under the ALL: anterior scalloping, disc spared early, gibbus

Infection crosses the disc; tumor respects it.

Look at the disc first. Pyogenic infection narrows the disc and erodes both endplates; metastasis destroys bone but spares the disc; tuberculosis scallops the front of the bodies and spares the disc until late.

LOCK THESE IN

- Block vertebra: wasp waist. Os odontoideum: smooth ossicle, big rounded C1 anterior arch, often unstable.
- Jefferson overhang over 7 mm total means transverse ligament rupture. Odontoid type II: worst healing.
- Burst widens the interpediculate distance; Chance splits all three columns at T12 to L2.
- Isthmic slip: L5 with a pars defect. Degenerative slip: L4 with an intact pars.
- AS: bilateral symmetric sacroiliitis and marginal syndesmophytes. Psoriatic and reactive: nonmarginal.
- Metastasis: missing pedicle, disc spared. Myeloma: punched out lesions, cold bone scan.

Destructive spinal lesions compared

Feature	Pyogenic discitis	Tuberculosis	Metastasis
Disc	Narrowed early, destroyed	Spared early, lost late	Preserved
Bone	Endplates eroded on both sides	Anterior scalloping	Body and pedicle destroyed
Levels	One disc, two bodies	Several, skip lesions	Scattered
Soft tissue	Moderate swelling	Large calcified psoas abscess	Possible mass
Deformity	Mild	Gibbus	Collapse
Tempo	Weeks; fever, high CRP	Months; night sweats	Cancer history

Worked case

CASE 8.1 · WHICH SLIP

A 15 year old gymnast has a grade 1 L5 slip with a lucent pars defect; a 64 year old woman has a grade 1 L4 slip with intact pars.

STEP 1 · GYMNAST

Isthmic (Wiltse II), a pars stress fracture.

STEP 2 · OLDER WOMAN

Degenerative (Wiltse III), facet and disc degeneration.

TRAPS PEOPLE FALL INTO

- **Calling a block vertebra a surgical fusion.** The congenital block has a wasp waist at the fused disc. Acquired fusion does not.
- **Mistaking os odontoideum for a fresh fracture or for nothing.** It is smooth and corticated with a big C1 arch, and often unstable. No upper cervical thrust.
- **Calling every L4 slip isthmic.** L4 slips in older women are usually degenerative with an intact pars. Isthmic slips are usually L5.

- **Mixing marginal and nonmarginal syndesmophytes.** Thin vertical marginal ones mean AS or enteropathic; bulky nonmarginal ones mean psoriatic or reactive.

Chapter 8 self-test · six items

1. A fall onto the head causes lateral mass overhang of C1 on the APOM. Which fracture?

A. Odontoid type I
B. Clay shoveler fracture
C. Hangman fracture
D. Jefferson fracture

D. Jefferson fracture Axial load with lateral mass offset is a Jefferson burst fracture.

2. Which fracture involves only the anterior column?

A. Chance fracture
B. Wedge compression
C. Flexion teardrop
D. Burst fracture

B. Wedge compression A simple wedge compression fracture involves only the anterior column.

3. Bulky nonmarginal syndesmophytes with asymmetric sacroiliitis suggest what?

A. Psoriatic arthritis
B. Ankylosing spondylitis
C. Enteropathic arthritis
D. DISH (Forestier)

A. Psoriatic arthritis Nonmarginal syndesmophytes and asymmetric SI disease mark psoriatic and reactive arthritis.

4. A lytic, eccentric lesion reaching the subarticular bone of the distal femur in a 30 year old suggests?

A. Ewing sarcoma
B. Osteoid osteoma
C. Giant cell tumor
D. Osteosarcoma

C. Giant cell tumor Giant cell tumor is epiphyseal to the joint surface in skeletally mature young adults.

5. Dense bands under each endplate with a lucent middle on the lateral spine suggest?

A. Postmenopausal osteoporosis
B. Renal osteodystrophy
C. Paget disease of bone
D. Sickle cell disease

B. Renal osteodystrophy The rugger jersey spine is classic for renal osteodystrophy.

6. What is the earliest plain film sign of pyogenic discitis?

A. Loss of disc height
B. A sharp gibbus
C. An ivory vertebra
D. A vertebra plana

A. Loss of disc height Disc space narrowing comes first, then loss of the endplate white line.

CHAPTER 9

The Chiropractic Paradigm, History and Research Principles

Read it in full: **Chapter 9 in the textbook**. Practice it: **Practice exam 5** and the **flashcards**.

What to know

History: D.D. Palmer adjusted Harvey Lillard on September 18, 1895, in Davenport; Samuel Weed helped coin the name. D.D.: tone, Innate, traumas, toxins and autosuggestion. B.J.: x-ray, neurocalometer, HIO, straight chiropractic. Morikubo (1907) used philosophy as a defense; Wilk (1987) found an unlawful boycott.

Paradigm: the body's recuperative power, structure and function integrated by the nervous system, and the duty to diagnose. Stephenson's limits of adaptation principle supports referral. Selye's stages are alarm, resistance and exhaustion.

Research: RCT for therapy, cohort for prognosis, case control for rare harm. Concealment stops selection bias; blinding stops performance and detection bias. Motion palpation is slight to fair; pain provocation better. NNT = 1 ÷ ARR.

Evidence: SMT gives modest short term benefit for low back pain, neck pain and cervicogenic headache, similar to other recommended care; none for asthma, hypertension or colic. Evidence based practice combines research, expertise and patient values.

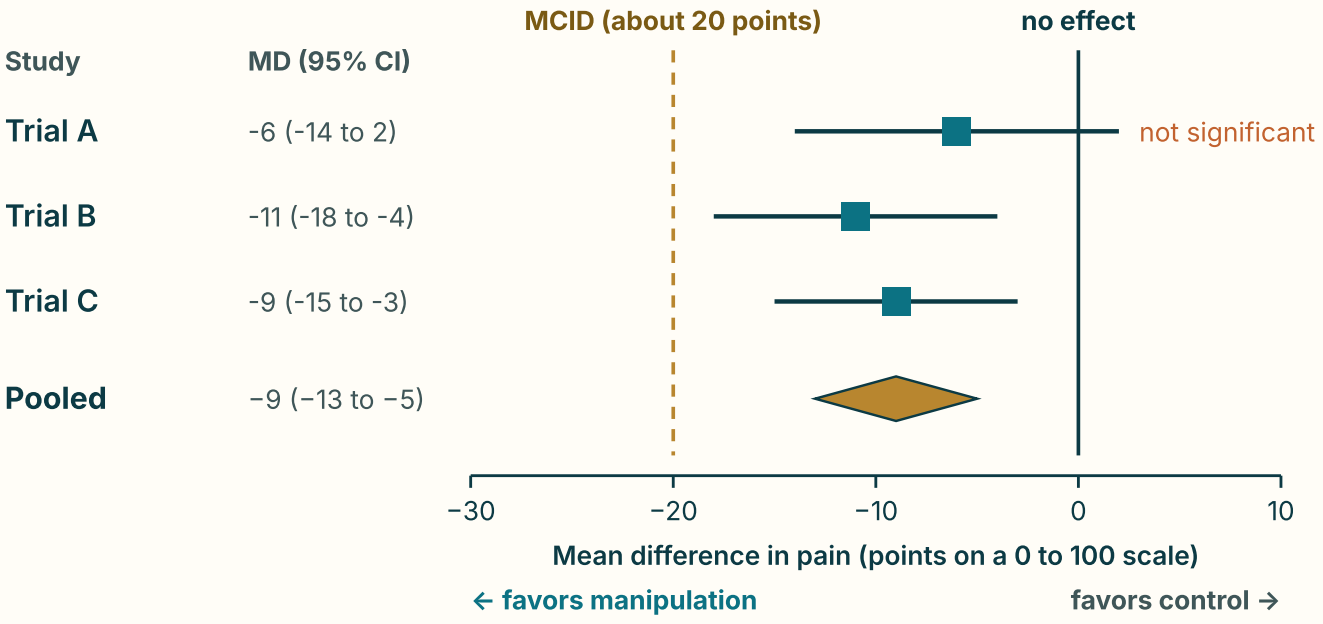

Illustrative numbers. The pooled diamond misses 0 (significant) but stops short of the MCID (modest).

Significant is not the same as important. A trial whose interval crosses 0 is not significant alone. Pooling narrows the interval, but here the effect still falls short of the MCID: real but modest, the usual finding for SMT.

LOCK THESE IN

- Palmer, Lillard, September 18, 1895, Davenport, upper thoracic, deafness; Weed coined cheir plus praxis.
- D.D.: tone, Innate, traumas, toxins, autosuggestion. B.J.: x-ray, neurocalometer, HIO, straight.
- Morikubo 1907: philosophy as legal defense. Wilk 1987: antitrust and a boycott.
- Kansas 1913 first license, Louisiana 1974 last; NBCE 1963; CCE 1974.
- Limits of adaptation: Innate is limited by matter, so diagnose and refer.
- Concealed allocation stops selection bias; blinding stops performance and detection bias.

Research formulas

Measure	Formula	Example
LR+	Sens ÷ (1 − spec)	0.90 ÷ 0.20 = 4.5
LR−	(1 − sens) ÷ spec	0.10 ÷ 0.80 = 0.125
Relative risk	EER ÷ CER	0.30 ÷ 0.40 = 0.75
RRR	1 − RR	25%
ARR	CER − EER	10 percentage points
NNT	1 ÷ ARR	1 ÷ 0.10 = 10
Odds ratio	(a × d) ÷ (b × c)	Case control studies
Kappa	(observed − chance) ÷ (1 − chance)	0.21 to 0.40 fair
Power	1 − beta	Conventionally 0.80
Cohen d	Mean difference ÷ pooled SD	0.2 small, 0.5 medium, 0.8 large

Worked case

CASE 9.1 · RELATIVE VERSUS ABSOLUTE

Recurrence falls from 20% to 10% with a program.

STEP 1 · RELATIVE

RRR = (20 − 10) ÷ 20 = **50%**.

STEP 2 · ABSOLUTE

ARR = 10 points; NNT = 1 ÷ 0.10 = **10**.

TRAPS PEOPLE FALL INTO

- **Mixing up Morikubo and Wilk.** Morikubo (1907) used philosophy as a defense against practicing osteopathy. Wilk (1987) was an antitrust ruling on a medical boycott.
- **Calling B.J. Palmer the founder.** D.D. is the discoverer or founder; B.J. is the developer.
- **Treating the paradigm as adjusting only.** The consensus paradigm includes establishing a diagnosis. Portal of entry means a duty to diagnose and refer.
- **Thinking blinding prevents selection bias.** Concealed allocation does that. Blinding prevents performance and detection bias.

Chapter 9 self-test · six items

1. Which state was the last to license chiropractic?

A. Louisiana

B. Kansas

C. New York

D. Iowa

A. Louisiana Kansas licensed first in 1913; Louisiana last in 1974.

2. In the triad of health, what are the three sides?

A. Trauma, toxin, thought

B. Innate, educated, universal

C. Structural, chemical, mental

D. Spiritual, social, physical

C. Structural, chemical, mental Structural, chemical and mental health; Palmer's three Ts map onto them.

3. Which design gives incidence and relative risk and best answers prognosis questions?

A. Cross sectional survey
B. Case control study
C. Case series
D. Cohort study

D. Cohort study Cohorts follow exposed groups forward for outcomes.

4. A type II error is best described as what?

A. A confounded estimate
B. Missing a real effect
C. A false positive result
D. A biased allocation

B. Missing a real effect Type II error (beta) is a false negative, often from too small a sample.

5. Which GRADE factor upgrades observational evidence?

A. A high risk of bias
B. Publication bias found
C. Imprecise estimates
D. A dose response gradient

D. A dose response gradient Large effects, dose response and confounding that would reduce the effect can upgrade.

6. Sackett's evidence based practice combines research evidence, clinical expertise and what?

A. Technique tradition
B. Patient values
C. Expert consensus
D. Insurance rules

B. Patient values The third element is patient values and preferences.

CHAPTER 10

Subluxation Models, Basic Science Concepts and Applied Principles

Read it in full: **Chapter 10 in the textbook**. Practice it: **Practice exam 5** and the **flashcards**.

What to know

The consensus subluxation keeps joint contact intact; the medical subluxation is a partial dislocation. Medicare accepts x-ray or PART (two of four, one A or R). The vertebral subluxation complex links kinesiopathology, neuropathophysiology, myopathology, histopathology and biochemical change.

Neurological models: dysafferentation, facilitation (Korr) and somatosomatic reflexes are best supported; viscerosomatic referral is a red flag mechanism. Sharpless: about 10 mm Hg on a root; Crelin: cadaver foramina; Sato: animal somatovisceral reflexes.

Biomechanics: cervical coupling same side, lumbar classically opposite; C1 to C2 gives about half of cervical rotation; the disc carries most compressive load; sitting flexed loads it most. Sandoz: the thrust enters the paraphysiological space short of the anatomical limit.

The thrust lasts about 100 to 200 ms; cavitation is gas with a 20 minute refractory period and does not predict outcome. Benign reactions are common; dissection is rare and causation unproven.

Maintenance helps selected patients with recurrent low back pain.

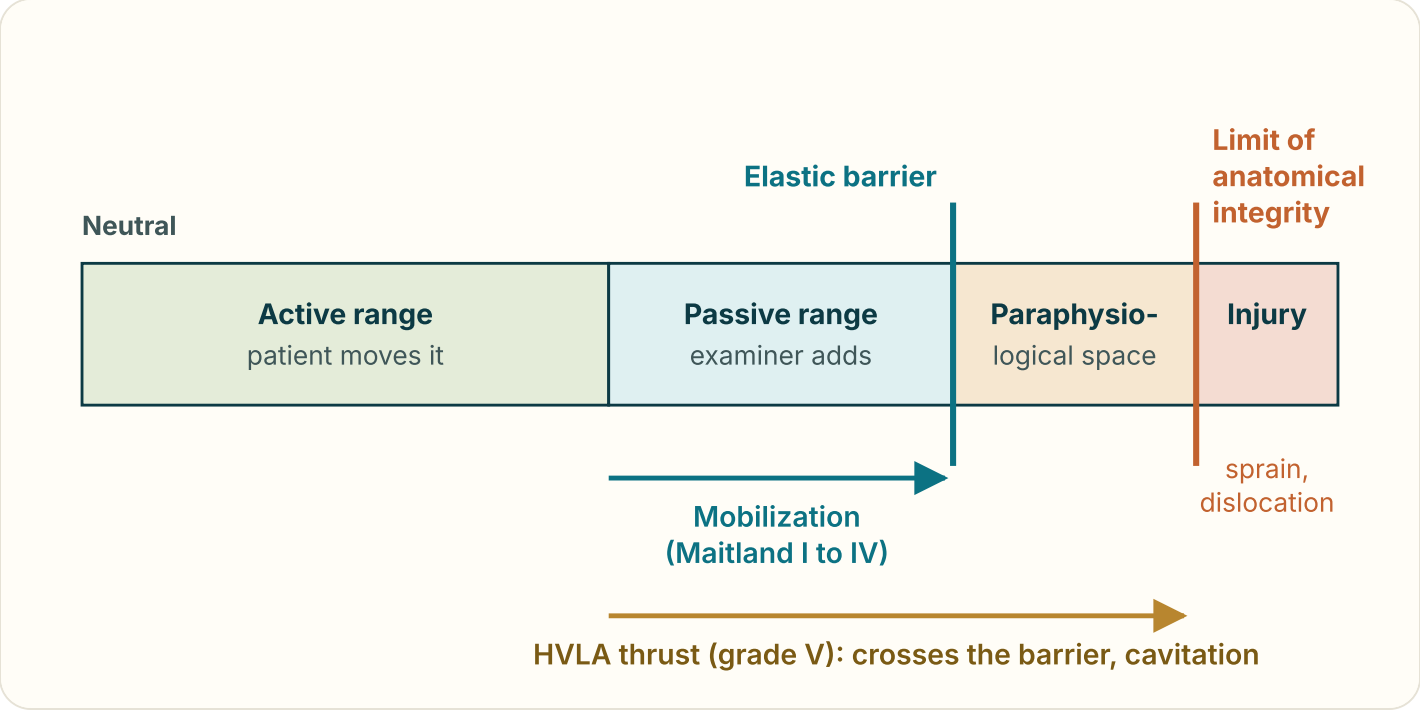

A thrust goes just past the elastic barrier and no farther. Mobilization stays within the passive range. A manipulation briefly enters the paraphysiological space, usually with cavitation, and must stop short of the limit of anatomical integrity.

LOCK THESE IN

- Medical subluxation is a partial dislocation; the consensus chiropractic subluxation keeps joint contact intact.
- PART: two of four, and one must be asymmetry or range of motion.
- VSC: kinesiopathology, neuropathophysiology, myopathology, histopathology, biochemical (Faye; Lantz added more).
- Sharpless about 10 mm Hg; Crelin cadavers; Korr facilitation; Sato animal somatovisceral reflexes.
- Cervical coupling same side; lumbar classically opposite; scoliosis bodies rotate to the convexity.
- Intradiscal pressure: supine 25, side lying 75, standing 100, sitting 140, standing flexed 150, sitting flexed 185.

Neurological models and their evidence

Model	Mechanism	Status
Dysafferentation, somatosomatic	Less mechanoreception, more nociception; guarding	Best supported
Facilitation (Korr)	Sustained input lowers segmental thresholds	Physiology established; link to subluxation uncertain
Nerve compression (Sharpless)	Pressure on root or DRG	Proven for disc and stenosis; unproven for minor subluxation
Somatovisceral (Sato)	Somatic input alters organ function	Animal data; human relevance not shown
Viscerosomatic	Visceral input refers pain to the back	Well established; red flag
Axoplasmic aberration	Slowed axonal transport	Animal compression data only
Neuroimmunomodulation	Altered immune regulation	Small transient lab changes
Vascular insufficiency	Vasomotor or venous change	Theoretical except venous congestion in stenosis

Worked case

CASE 10.1 · PART CHECK

A note records restricted L3 motion and paraspinal hypertonicity.

STEP 1 · COUNT

R (range of motion) and T (tissue tone): two of four.

STEP 2 · RULE

One of them is R, so the subluxation is documented by examination.

TRAPS PEOPLE FALL INTO

- **Equating the radiologist's subluxation with the chiropractic one.** A medical subluxation is a partial dislocation and may mean instability, not a lesion to adjust.
- **Accepting P and T for Medicare.** PART needs two of four and one must be A or R.
- **Claiming Sato proved subluxations cause organ disease.** He showed somatovisceral reflexes in anesthetized animals. Human clinical relevance is not shown.
- **Reversing cervical and lumbar coupling.** Cervical: same side. Lumbar: classically opposite side.

Chapter 10 self-test · six items

1. Which Wyke receptor signals the onset of movement and adapts rapidly?

A. Type III
B. Type II
C. Type IV
D. Type I

B. Type II Type II conical corpuscles in the deep capsule are rapidly adapting.

2. Who described the facilitated segment as a "neurological lens"?

A. Korr
B. Sato
C. Faye
D. Crelin

A. Korr Korr described facilitation, forerunner of central sensitization.

3. About how much of total cervical rotation comes from C1 to C2?

A. About a quarter
B. Nearly all
C. About a tenth
D. About half

D. About half C1 to C2 rotates about 40 degrees each way, about half of cervical rotation.

4. Which tissue property describes continued deformation under a constant load?

A. Hysteresis
B. Relaxation
C. Creep
D. Recoil

C. Creep Creep is ongoing deformation under constant load.

5. In which healing phase is type III collagen laid down?

A. Inflammation
B. Remodeling
C. Hemostasis
D. Repair phase

D. Repair phase Fibroblasts lay down weak type III collagen in the repair phase.

6. A patient who plans to start exercising within the next month is in which stage?

A. Contemplation
B. Preparation
C. Maintenance
D. Action

B. Preparation Planning within 30 days is preparation.

CHAPTER 11

Spinal Analysis, Patient Evaluation and Adjustive Technique

Read it in full: **Chapter 11 in the textbook**. Practice it: **Practice exam 6** and the **flashcards**.

What to know

Analysis: is manual care appropriate, where is the lesion, and what is its character. Document with PARTS. Count levels from at least two landmarks: C7, T3, T7, L4, S2. Motion palpation is less reliable than pain provocation.

Listings: Gonstead names the spinous (P, side, S or I); National names the body; a spinous right is a body left. Atlas listings read AS, laterality, then A or P of that transverse.

Set ups: lower cervical rotary break on the pillar, P to A and I to S toward the opposite eye; avoid end range rotation with extension. Thoracic thrusts at end of exhalation. Mammillary push P to A; spinous push L to M. PI ilium: PSIS contact; AS ilium: ischial contact.

Extremities follow the convex concave rule in the loose packed position. Systems: Gonstead (disc, five criteria), Thompson (drop, Derefield), Activator (instrument, isolation tests), flexion distraction (disc and stenosis), SOT (blocks), AK (unsupported diagnostically).

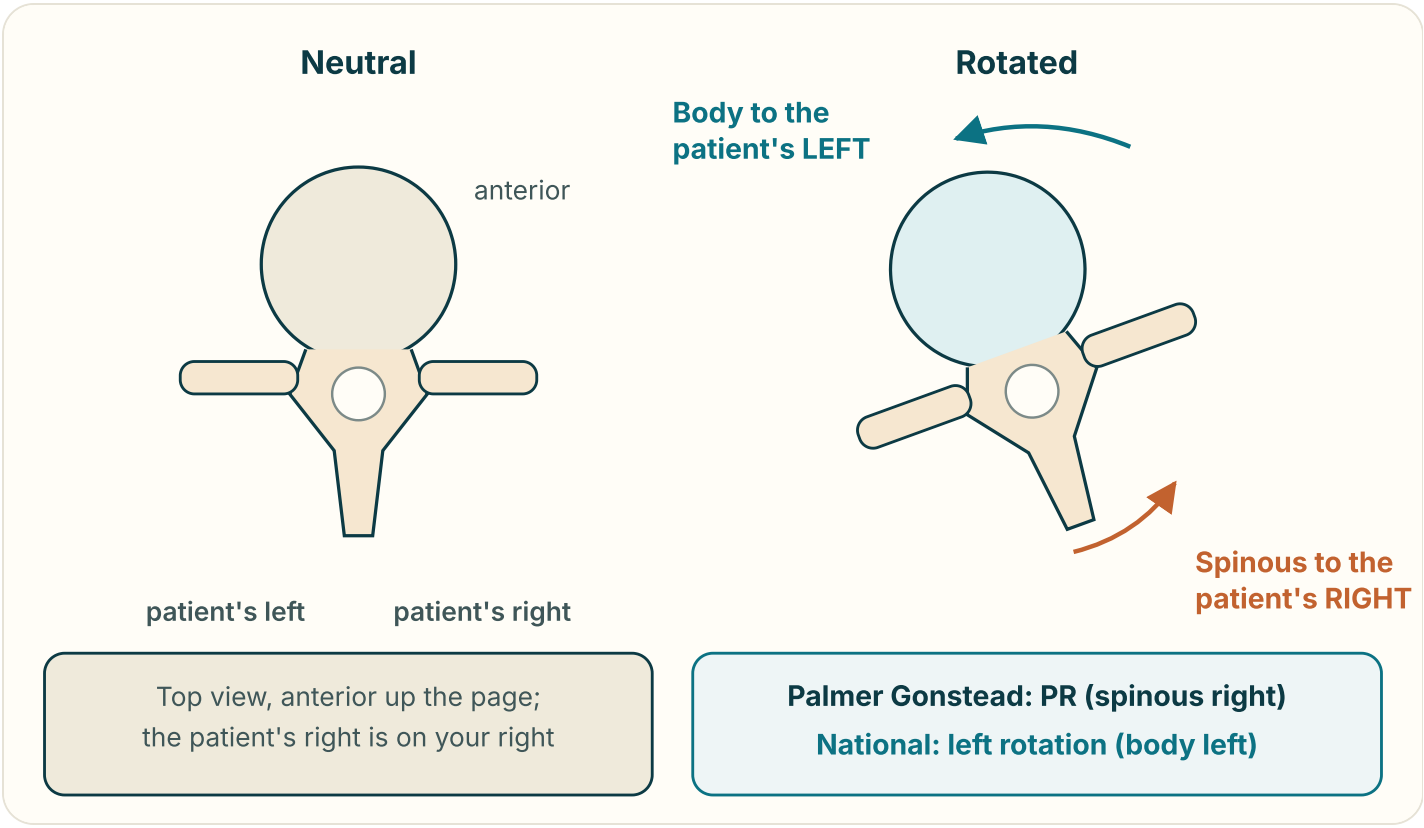

One rotation, two names. A spinous palpated to the right (Palmer Gonstead PR) belongs to a body that has rotated left (National left rotation), because the two ends of the vertebra swing opposite ways around the vertical axis.

LOCK THESE IN

- PARTS documents a lesion; by exam, two of PART with one being A or R.
- Landmarks: C7 prominens, T3 scapular spine, T7 inferior angle, L4 iliac crests, S2 PSIS.
- Gonstead PR (spinous right) = National left body rotation.
- Lower cervical rotary break: pillar contact, P to A and I to S, toward the opposite eye; never end range.
- Thoracic thrust at end of exhalation; avoid long levers in osteoporosis.
- Mammillary push P to A; spinous push L to M; no P to A thrust on a slipped segment.

Set ups at a glance

Set up	Contact and SCP	Line of drive
Atlas laterality, supine	Index on lateral atlas transverse	L to M, slight I to S
Lower cervical rotary break	Index MCP on articular pillar	P to A, I to S, toward opposite eye
Lower cervical lateral break	Index on lateral pillar	L to M
Cervicothoracic thumb move	Thumb on lateral C7 or T1 spinous	L to M
Bilateral transverse (prone)	Both pisiforms on transverses	P to A, slight I to S, at exhalation
Anterior thoracic (supine)	Fist or pistol grip under segment	A to P through crossed elbows
Elevated first rib	Index MCP on superior first rib	S to I toward the opposite hip
Side posture mammillary push	Pisiform on up side mammillary	P to A with body drop
Side posture spinous push	Pisiform on up side of spinous	L to M toward the table
PI ilium	Pisiform on PSIS, PI side up	P to A and I to S
AS ilium	Ischial tuberosity, AS side up	P to A along the flexed femur

Worked case

CASE 11.1 · ELEVATED FIRST RIB

A patient has a tender, elevated left first rib with neck and shoulder pain.

STEP 1 · POSITION

Seated, doctor behind; head laterally flexed toward and slightly rotated away from the contact.

STEP 2 · CONTACT AND DRIVE

Index MCP on the superior first rib; drive superior to inferior, toward the opposite hip.

TRAPS PEOPLE FALL INTO

- **Documenting P and T only.** By exam, one of the two findings must be asymmetry or range of motion.
- **Counting levels from one landmark.** Landmarks vary by a segment in many people. Count from at least two.
- **Translating PR as right rotation.** Spinous right is body left. The National system names the body.
- **Rotating the neck to end range before thrusting.** Rotation with extension narrows the contralateral vertebral artery. Use 30 to 45 degrees and short arcs.

Chapter 11 self-test · six items

1. Which landmark usually marks S2?

A. The xiphoid junction
B. The iliac crests
C. The scapular angles
D. The PSIS dimples

D. The PSIS dimples The PSIS (dimples of Venus) mark S2, where the dural sac ends.

2. A Gonstead listing of PLI-M means the wedge is open on which side?

A. The left side
B. The right side
C. Both sides
D. Neither side

B. The right side I means the wedge opens opposite the spinous side; spinous left means open right.

3. Which atlas listing indicates right laterality with a right transverse posterior?

A. ASRA
B. ASLA
C. ASRP
D. AILP

C. ASRP AS, R laterality, P for the right transverse posterior.

4. For knee extension, which tibial glide should be restored?

A. Anterior glide
B. Posterior glide
C. Lateral glide
D. Medial glide

A. Anterior glide The concave tibia glides the same way it moves, so extension needs anterior glide.

5. Which technique system bases analysis on five criteria including a thermal instrument?

A. Activator
B. Gonstead
C. SOT
D. Thompson

B. Gonstead Gonstead uses visualization, instrumentation, static and motion palpation, and x-ray.

6. Which pelvic listing gives a long leg on that side?

A. In ilium
B. PI ilium
C. AS ilium
D. Posterior sacrum

C. AS ilium An AS ilium gives a long leg; a PI ilium a short leg.

CHAPTER 12

Patient Care, Community Health and Occupational Health

Read it in full: **Chapter 12 in the textbook**. Practice it: **Practice exam 6** and the **flashcards**.

What to know

Case management: report of findings, consent as PARQ under a material risk standard, measurable goals, a trial of care about 2 weeks, re-examination every 2 to 4 weeks, validated outcomes and discharge without abandonment. SOAP notes: S report, O findings and scores, A progress, P plan.

Contraindications: absolute for fracture, tumor, infection, upper cervical instability, cauda equina, dissection, large aneurysm and prostheses; relative for osteoporosis, anticoagulation, spondylolisthesis and complicated pregnancy. Benign reactions are common; serious events rare.

Rehabilitation: protect, load, then strengthen across healing phases; stabilization, McKenzie centralization, PNF and crossed syndrome correction. Ultrasound 1 MHz deep, 3 MHz superficial; TENS high frequency gate, low frequency endorphins.

Public and occupational health: USPSTF screens (colorectal 45 to 75, mammography 40 to 74 every 2 years, lung 50 to 80 with 20 pack years, AAA men 65 to 75 who smoked); 5 As; standard drink 14 g; NIOSH 23 kg constant; hierarchy of controls; noise PEL 90 dBA.

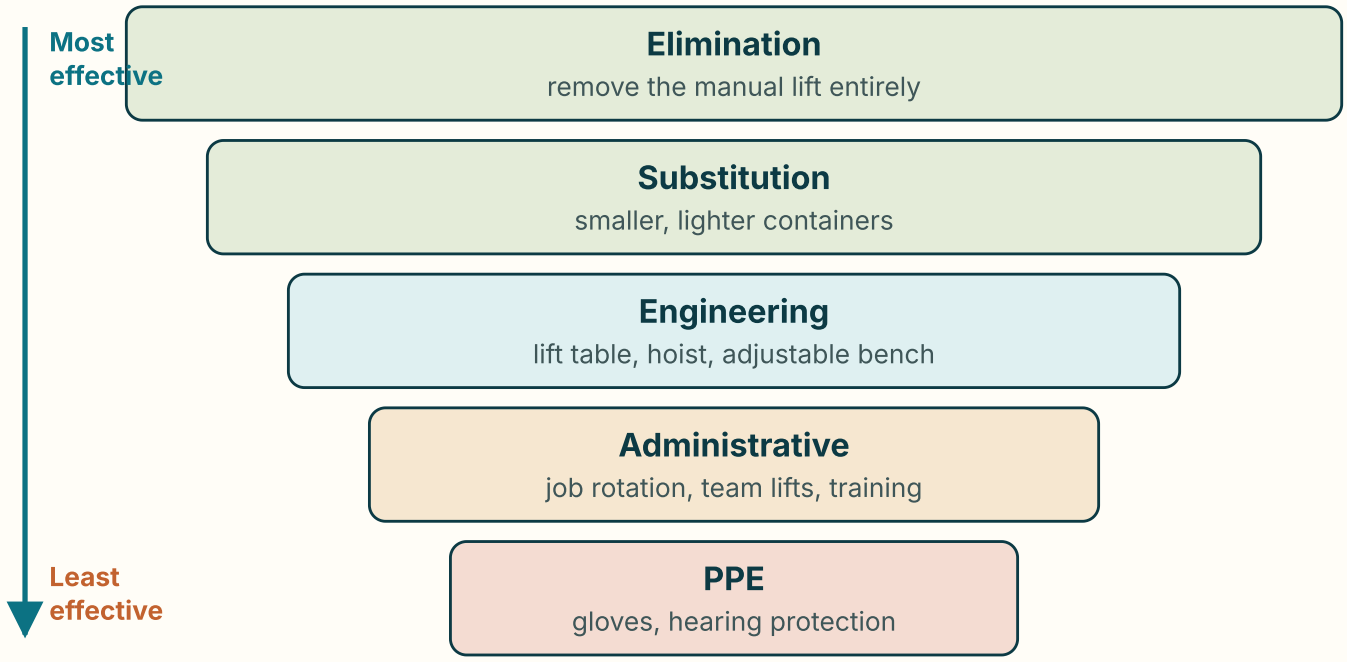

Remove the hazard before you protect the worker from it. Elimination and substitution remove the hazard, engineering isolates people from it, administrative controls change how people work, and PPE is the last line of defense.

LOCK THESE IN

- Consent is PARQ under a material risk standard; renew when the plan changes.
- Trial of care about 2 weeks; two trials without change means modify or refer.
- SOAP: S report, O findings and scores, A diagnosis and progress, P plan.
- Absolute: fracture, tumor, infection, instability, cauda equina, dissection, large aneurysm, prosthesis.
- Ultrasound 1 MHz deep, 3 MHz superficial; TENS high frequency gate, low frequency endorphins.
- USPSTF: colorectal 45 to 75; mammogram 40 to 74 every 2 years; lung 50 to 80 with 20 pack years; AAA men 65 to 75 who smoked.

Contraindications to thrust

Condition	Status	What to do
Acute fracture or dislocation	Absolute	Immobilize and refer
Tumor or infection in the area	Absolute	Refer; gentle care elsewhere may be fine
Upper cervical instability	Absolute for upper cervical thrust	Flexion and extension films
Cauda equina, myelopathy, dissection	Absolute	Emergency referral
Large or symptomatic AAA	Absolute for lumbar thrust	Emergency if pulsatile and painful
Anticoagulation, bleeding disorder	Relative	Reduce force
Osteoporosis	Relative	Low force, no long levers
Spondylolisthesis	Relative (local)	No P to A on the slipped level
Prosthesis or fused level	Absolute at that level	Treat adjacent regions with care
Complicated pregnancy	Relative to absolute	Obstetric referral

Worked case

CASE 12.1 · LIFTING INDEX

A 20 kg load has a recommended weight limit of 16 kg.

STEP 1 · INDEX

LI = 20 ÷ 16 = **1.25**.

STEP 2 · READ

Over 1.0 means increased risk; reduce horizontal distance or use an engineering control.

TRAPS PEOPLE FALL INTO

- **Treating a signed form as consent.** Consent is a process of disclosure, understanding and voluntary agreement, renewed when the plan changes.
- **Continuing high frequency care without progress.** After two trials of care without documented change, modify or refer.
- **Filing outcome scores under S.** Questionnaire scores are usually filed under O.
- **Calling uncomplicated pregnancy a contraindication.** Only complicated pregnancy (bleeding, previa, preterm labor) changes care.

Chapter 12 self-test · six items

1. Treating a patient without any consent, even competently, can be which wrong?

A. Defamation
B. Battery
C. Abandonment
D. Fraud

B. Battery Touching without consent is battery.

2. Which is a relative, not absolute, contraindication to thrust?

A. Acute fracture
B. Spinal infection
C. Spondylolisthesis
D. Cauda equina syndrome

C. Spondylolisthesis Spondylolisthesis calls for modification; the others forbid thrust.

3. Which TENS setting relies on endogenous opioid release?

A. Interferential beat
B. Sensory level, 150 Hz
C. High frequency, 100 Hz
D. Low frequency, 2 to 4 Hz

D. Low frequency, 2 to 4 Hz Acupuncture like low frequency TENS works through endorphins.

4. Which organization grades clinical preventive services A, B, C, D or I?

A. USPSTF
B. NIOSH
C. OSHA
D. CDC

A. USPSTF The US Preventive Services Task Force grades preventive services.

5. Which exposure is linked to mesothelioma and lower lobe fibrosis?

A. Beryllium
B. Asbestos
C. Silica
D. Coal dust

B. Asbestos Asbestos causes lower lobe asbestosis, pleural plaques and mesothelioma.

6. What is OSHA's permissible noise exposure limit for 8 hours?

A. 100 dBA
B. 85 dBA
C. 80 dBA
D. 90 dBA

D. 90 dBA OSHA's PEL is 90 dBA with a 5 dB exchange rate; 85 dBA is the action level.

CHAPTER 13

Geriatrics, Dermatology, Sexually Transmitted Infections, Toxicology and Emergency Care

Read it in full: **Chapter 13 in the textbook**. Practice it: **Practice exam 7** and the **flashcards**.

What to know

Geriatrics: reduced reserve and atypical presentation. TUG 12 seconds or more means fall risk. Osteoporosis has normal labs; glucocorticoids lead drug causes. Delirium is acute, fluctuating and inattentive and needs same day referral.

Dermatology: name lesions by type and size (1 cm cutoff). Zoster pain can precede the rash. ABCDE and the ugly duckling sign flag melanoma; evolving is most important. Nikolsky is positive in pemphigus and negative in pemphigoid.

STIs: disseminated gonococcal infection causes tenosynovitis, pustules and septic joints; reactive arthritis is sterile and HLA-B27 linked; tabes dorsalis gives a positive Romberg, Argyll Robertson pupils and Charcot joints. Use universal precautions with everyone.

Drugs and emergencies: NSAIDs harm gut, kidney and heart; steroids weaken bone and tendon; fluoroquinolones rupture Achilles tendons. CPR 100 to 120 a minute at least 2 inches, 30:2; sugar for hypoglycemia if they can swallow; IM epinephrine first for anaphylaxis.

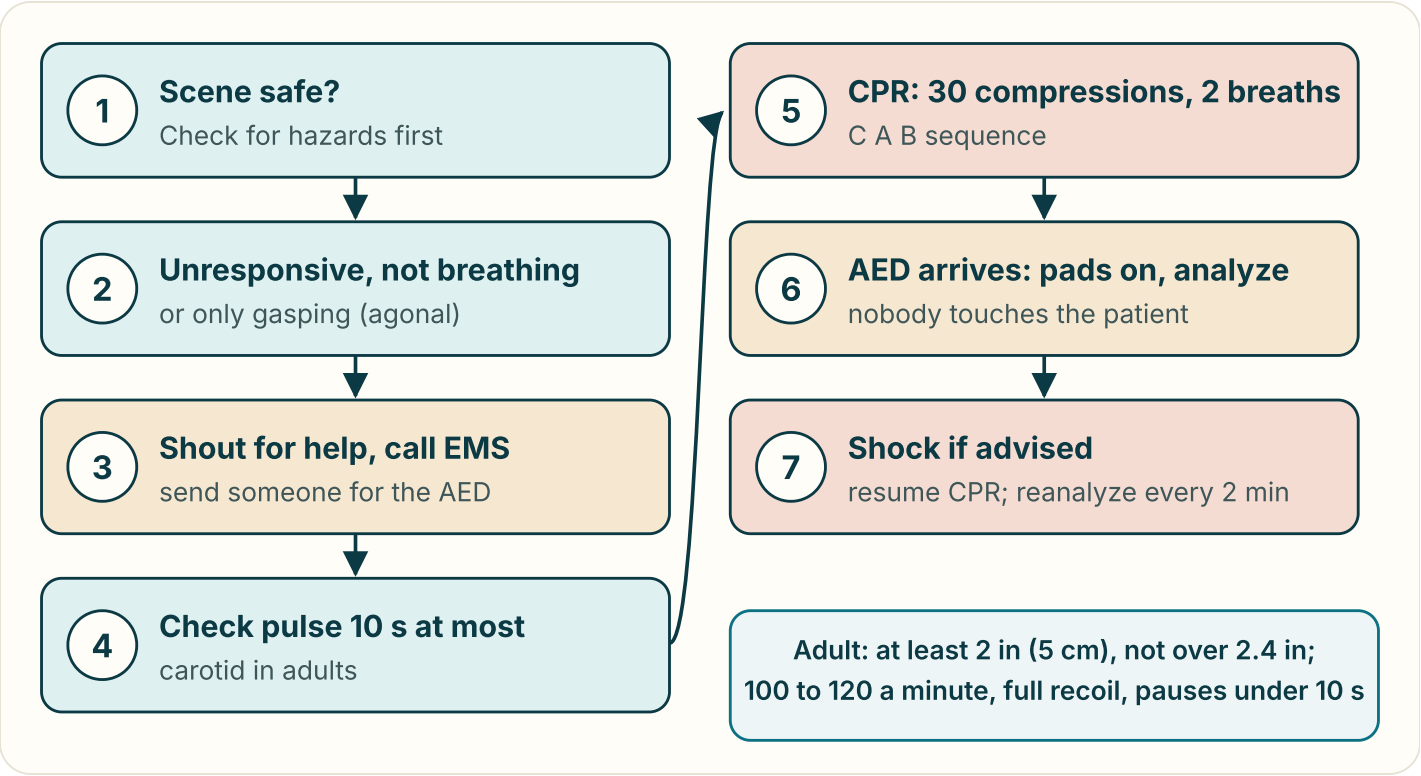

Recognize, call, compress, shock. Early recognition, an immediate call for EMS and the AED, high quality compressions with minimal pauses and early defibrillation are what save adults in cardiac arrest.

LOCK THESE IN

- Older adults present atypically; a sudden change in function is a symptom.
- TUG 12 seconds or more means fall risk; psychoactive drugs and orthostasis are modifiable.
- Delirium: acute, fluctuating, inattentive, same day referral. Dementia: chronic, attention normal early.
- ABCDE: evolving is the most important; Breslow depth drives melanoma prognosis.
- Nikolsky positive in pemphigus, negative in bullous pemphigoid.
- Gonococcal: tenosynovitis, pustules, septic joint. Reactive: sterile, HLA-B27, conjunctivitis, enthesitis.

Emergency numbers

Item	Value	Note
Adult compressions	At least 2 in (5 cm), not over 2.4 in; 100 to 120 per minute	30:2, full recoil
Child / infant	15:2 with two rescuers; infant about 1.5 in	Pulse check: carotid or femoral / brachial
AED pads	Below right clavicle and left lateral chest	Pediatric pads under 8 if available
Rule of nines	Head 9; each arm 9; front 18; back 18; each leg 18; perineum 1	Palm about 1%
Burn cooling	Cool running water about 20 minutes	No ice, butter or ointment
Heat stroke	Over 40°C with CNS dysfunction	Cold water immersion; EMS
Hypothermia	Core below 35°C	Handle gently; remove wet clothing
Hypoglycemia	Under 70 mg/dL; 15 to 20 g sugar, recheck in 15 min	Unconscious: nothing by mouth, EMS
Anaphylaxis	IM epinephrine 0.3 mg adult, 0.15 mg small child	Repeat in 5 to 15 min if needed

Worked case

CASE 13.1 · A PEDIATRIC CPR RATIO

One rescuer finds an unresponsive infant who is not breathing.

STEP 1 · RATIO

A single rescuer uses **30:2**; two rescuers would use 15:2.

STEP 2 · TECHNIQUE

Two fingers just below the nipple line, about 1.5 inches deep, 100 to 120 a minute; brachial pulse check.

TRAPS PEOPLE FALL INTO

- **Waiting for fever before suspecting infection in an older adult.** Immunosenescence blunts fever. Confusion or a fall may be the only sign.
- **Treating delirium as routine dementia.** Delirium is acute and an emergency with high mortality. Refer the same day.
- **Calling a burning dermatomal pain an intercostal strain.** Pre-eruptive zoster can come before the rash. Look at the skin and recheck in a few days.
- **Reading a negative Nikolsky as pemphigus.** Pemphigus is Nikolsky positive; bullous pemphigoid is negative.

Chapter 13 self-test · six items

1. In an 86 year old, which finding may be the only sign of pneumonia?

A. Rusty sputum
B. Pleuritic pain
C. New confusion
D. A high fever

C. New confusion Immunosenescence blunts fever; confusion or a fall may be the only sign.

2. Which skin lesion is a raised, solid, flat topped lesion 1 cm or larger?

A. Plaque
B. Papule
C. Macule
D. Vesicle

A. Plaque A plaque is elevated and 1 cm or more; a papule is under 1 cm.

3. A pearly papule with rolled borders and telangiectasias on the nose suggests?

A. Seborrheic keratosis
B. Basal cell carcinoma
C. Nodular melanoma
D. Squamous cell carcinoma

B. Basal cell carcinoma Pearly rolled borders with telangiectasias are classic for basal cell carcinoma.

4. Which stage of syphilis brings a rash on the palms and soles?

A. Tertiary
B. Primary
C. Latent
D. Secondary

D. Secondary Secondary syphilis brings a diffuse rash including the palms and soles.

5. What is the antidote for acetaminophen overdose?

A. Atropine sulfate
B. Naloxone HCl
C. N acetylcysteine
D. Flumazenil

C. N acetylcysteine N acetylcysteine restores glutathione and prevents liver injury.

6. What is the first drug for anaphylaxis?

A. Oral antihistamine
B. Inhaled albuterol
C. IV corticosteroid
D. IM epinephrine

D. IM epinephrine Intramuscular epinephrine in the thigh is first; delay is the main factor in deaths.

CHAPTER 14

Psychology, Gynecology and Obstetrics, Pediatrics, Jurisprudence and Ethics

Read it in full: **Chapter 14 in the textbook**. Practice it: **Practice exam 7** and the **flashcards**.

What to know

Psychology: operant conditioning reinforces pain behavior; the fear avoidance loop keeps pain going; yellow flags predict chronicity. Malingering is for external gain, factitious disorder for the sick role. Ask directly about suicide; a plan or intent is an emergency.

Gynecology: pregnancy first, then ectopic pregnancy, in women with pelvic or back pain and a late period. Endometriosis is cyclic; PID shows cervical motion tenderness; postmenopausal bleeding is endometrial cancer until proven otherwise; breast cancer favors the upper outer quadrant and seeds the spine.

Obstetrics: relaxin, a forward center of gravity and lordosis drive back and pelvic pain; avoid prolonged supine positioning after 20 weeks. Previa is painless bleeding, abruption painful; preeclampsia is 140/90 after 20 weeks with headache or vision change.

Pediatrics and law: APGAR at 1 and 5 minutes; examine the hip for knee pain; posterior rib and metaphyseal corner fractures suggest abuse, and reasonable suspicion means report. Negligence

needs duty, dereliction, direct cause and damages; capacity is clinical, competence legal; HIPAA allows treatment, payment and operations.

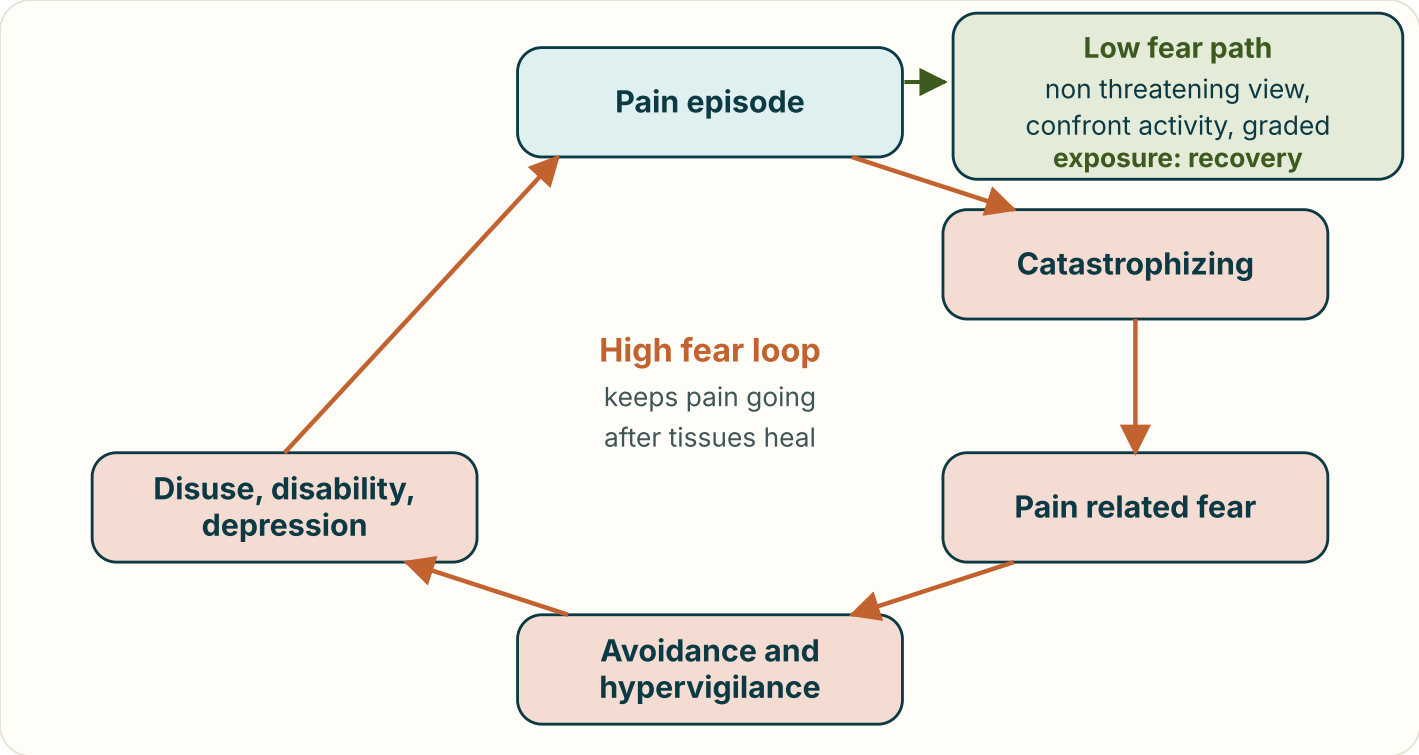

How fear keeps pain going. Catastrophic interpretation of pain drives fear, avoidance and disuse, which feed back into more pain. Accurate reassurance, pain education and graded activity move the patient onto the recovery path.

LOCK THESE IN

- Fear avoidance: catastrophizing, fear, avoidance, disuse, depression, more pain. Reassure, educate, grade activity.
- Malingering is for external gain; factitious is for the sick role; Waddell signs do not prove lying.
- A suicide plan, means or intent is an emergency; prior attempt is the strongest predictor.
- Pelvic or back pain with a late period: pregnancy, then ectopic pregnancy, first.
- Painless third trimester bleeding is previa; painful is abruption; hypertension with headache after 20 weeks is preeclampsia.
- APGAR at 1 and 5 minutes; 7 to 10 reassuring.

APGAR score

Sign	0	1	2
Appearance	Blue or pale all over	Pink body, blue extremities	Pink all over
Pulse	Absent	Under 100	100 or more
Grimace	No response	Grimace	Cry, cough or sneeze
Activity	Limp	Some flexion	Active motion
Respiration	Absent	Slow, irregular, weak cry	Good, strong cry

Worked case

CASE 14.1 · COLLECTION RATIO

A practice has net charges of $60,000 and collections of $42,000 in a month.

STEP 1 · RATIO

42,000 ÷ 60,000 = **0.70**, or 70%.

STEP 2 · READ

Collections, not charges, pay overhead, which is commonly 50 to 60% of collections.

TRAPS PEOPLE FALL INTO

- **Calling Waddell signs proof of malingering.** They flag nonorganic features and psychosocial distress, not conscious deception.
- **Avoiding the word suicide.** Asking directly does not increase risk. Ask about thoughts, plan, means and intent.
- **Forgetting pregnancy in a young woman with back pain.** Ask about the last menstrual period; think ectopic pregnancy with a late period and pelvic pain.
- **Treating a breech with Webster as an obstetric fix.** Evidence that it turns a breech baby is limited. Breech is an obstetric matter.

Chapter 14 self-test · six items

1. Angry at his boss, a patient snaps at the receptionist. Which defense mechanism is this?

A. Regression
B. Sublimation
C. Projection
D. Displacement

D. Displacement Displacement redirects emotion to a safer target.

2. What is the strongest single predictor of suicide?

A. A prior attempt
B. Younger age
C. Chronic back pain
D. Female sex

A. A prior attempt A previous attempt is the strongest predictor.

3. Painful third trimester bleeding with a rigid tender uterus suggests what?

A. Placenta previa
B. Preterm labor onset
C. Placental abruption
D. Preeclampsia

C. Placental abruption Abruption is painful; previa is painless.

4. By about what age does the anterior fontanelle close?

A. About 4 years
B. About 18 months
C. About 2 months
D. About 6 months

B. About 18 months The posterior closes by about 2 months, the anterior by about 18 months.

5. Which element of negligence is the link between the breach and the harm?

A. Direct cause
B. Duty owed
C. Dereliction
D. Damages

A. Direct cause Direct (proximate) cause links the breach to the injury.

6. Billing separately for parts of a service that belong under one code is called?

A. Upcoding
B. Unbundling
C. Kickback
D. Balance billing

B. Unbundling Unbundling splits components that should be billed together.

ONE PAGE

Cram sheet

The whole course on one sheet, two chapters at a time. Cover the right columns and rebuild each row from memory.

Chapters 1 and 2: numbers

Item	Value	Note
BP stages	Stage 1 130 to 139 or 80 to 89; stage 2 140 or 90	Crisis over 180 and/or 120
Korotkoff	Phase I systolic; phase V diastolic	Phase IV in children and pregnancy
Orthostatic	Fall of 20 systolic or 10 diastolic	Within 3 minutes of standing
Vitals	Pulse 60 to 100; RR 12 to 20; fever 38.0°C	SpO_2 95 to 100%
BMI	18.5 to 24.9 normal; 30 or more obesity	kg ÷ m^2
ABI	0.90 or less PAD; over 1.4 calcified	Under about 0.4 critical ischemia
Electrolytes	Na 135 to 145; K 3.5 to 5.0; HCO_3 22 to 28	Anion gap 8 to 12
Diabetes	Fasting 126; OGTT 200; HbA1c 6.5%	Prediabetes 100 to 125 or 5.7 to 6.4%
Troponin	Up at 3 to 4 h, peak 24 to 48 h, lasts 7 to 10 days	CK-MB clears in 2 to 3 days
DXA	T score −2.5 or lower is osteoporosis	−1.0 to −2.5 is low bone mass
ECG	Small box 0.04 s; large 0.20 s; PR 0.12 to 0.20 s	QRS under 0.12 s
EMG timing	Fibrillations after about 2 to 3 weeks	Defer EMG about 3 weeks

Chapters 1 and 2: rules

Topic	The rule
Malignancy	Prior cancer is the strongest predictor of spinal malignancy.
Cauda equina	Urinary retention most common; saddle anesthesia classic; emergency referral.
Hearing	Conductive "comes to the bad side" on Weber; negative Rinne only in conductive loss.
Chest	Consolidation dull with more fremitus; effusion stony dull with less.
Murmurs	AS to the carotids, MR to the axilla; diastolic always abnormal; thrill is grade IV or more.
Abdomen	Inspect, auscultate, percuss, palpate; Murphy cholecystitis; Rovsing, psoas, obturator appendicitis.
Casts	RBC glomerulonephritis; WBC pyelonephritis; muddy brown ATN; fatty nephrotic.
Anemia	MCV first, then reticulocytes; low ferritin is iron deficiency.
Bone labs	Osteoporosis normal; Paget very high ALP; myeloma high Ca, normal ALP.
Test logic	SnNout, SpPin; predictive values move with prevalence.
Radiculopathy	Normal SNAP, abnormal paraspinal EMG.

Chapters 3 and 4: numbers

Item	Value	Note
AAA	3 cm or more; repair threshold about 5.5 cm	Screen men 65 to 75 who ever smoked
Dissection	Arm systolic difference over 20 mm Hg	Stanford A ascending: surgery
ABI	0.90 or less PAD; under about 0.4 severe	Over 1.4 calcified
Asthma reversibility	FEV_1 up 12% and 200 mL	COPD: FEV_1/FVC under 0.70
CURB 65 / qSOFA	2 or more: hospital / 2 of 3: sepsis risk	qSOFA: RR 22, mentation, SBP 100
Diabetes	Fasting 126; HbA1c 6.5%; OGTT 200	Hypoglycemia: about 15 g fast sugar
Osteoporosis	T score −2.5 or fragility fracture	Women 65+ screened
Metabolic syndrome	3 of 5 criteria	BP 130/85; TG 150; glucose 100
Oswestry	Score ÷ 50 × 100; MCID about 10	Over 40% severe
SLR	Positive 30 to 70 degrees	Pain beyond 70 is joints and hamstrings
Schöber / expansion	Gain under 5 cm / under 2.5 cm	Ankylosing spondylitis
Scoliosis	Cobb 10 degrees; scoliometer 5 to 7	Rib hump on the convex side

Chapters 3 and 4: rules

Topic	The rule
Emergency flag	One flag in the vignette means emergency referral, not more tests.
Claudication	Vascular: standing still, bicycle pain, low ABI. Neurogenic: sitting or flexion, shopping cart sign.
Myeloma	CRAB, punched out lesions, pedicle spared early, cold bone scan.
Visceral pain	Unchanged by movement; tied to eating, urination, bowels, menses.
Calcium signs	Chvostek cheek, Trousseau tourniquet: hypocalcemia.
Pain types	Radicular sharp below the knee; somatic referred dull above it.
Cervical tests	Arm pain means root, local pain means facet; distraction relief supports root.
Artery tests	Poor sensitivity; history decides; positive means no manipulation.
Thoracic outlet	Adson scalene, Eden costoclavicular, Wright pectoralis minor; Roos best.
Hip and SI	FABERE groin hip, back SI; Thomas iliopsoas; Ely rectus femoris; Ober IT band.
Nonorganic	Waddell 3 of 5 and Hoover: manage, do not dismiss.

Chapters 5 and 6: numbers

Item	Value	Note
Painful arc	60 to 120° impingement; 170 to 180° AC	Scapulohumeral rhythm 2 to 1
Carrying angle	5 to 15°	Greater in women
Allen test	Color back in about 5 to 7 s	Longer means occluded artery
Q angle	About 13° men, 18° women	Larger means more lateral pull
Lachman	Knee at 20 to 30°	Valgus stress at 30° isolates MCL
Ottawa ankle	Distal 6 cm of malleoli; four steps	Navicular and fifth metatarsal base for foot
RA neck	ADI over 3 mm abnormal (adult)	No upper cervical thrust in active RA
Fibromyalgia	WPI 7+ and SSS 5+, or WPI 4 to 6 and SSS 9+	4 of 5 regions, 3 months
GCS	3 to 15; 8 or less coma	E 4, V 5, M 6
MMSE / MoCA	23 or below / under 26	Cognitive screens
Clonus	More than about 3 to 5 beats	Sustained means UMN
Myelopathy	Canal under about 10 mm; Torg Pavlov under 0.8	Grip and release under 20 in 10 s
Cauda equina	Post void residual over about 200 mL	Decompress ideally within 48 h

Chapters 5 and 6: rules

Topic	The rule
Shoulder	Pain with strength is tendinopathy; weakness is a tear; equal active and passive loss is capsule.
Hand nerves	Carpal tunnel spares thenar skin; Guyon spares the dorsal ulnar hand; ulnar paradox.
Hip by age	DDH newborn, Perthes 4 to 8, SCFE obese 10 to 16, septic hip febrile child.
Knee	Forward tibia ACL, backward PCL, valgus MCL, varus LCL, rotation with click meniscus.
Arthritis	DIP is OA or psoriatic; MCP and wrist is RA; gout negative, CPPD positive.
Cranial nerves	Rule of four; uvula away, tongue toward; UMN face spares forehead.
Cerebellum	Ipsilateral; DANISH; Romberg is not cerebellar.
UMN vs LMN	Spastic, brisk, Babinski versus flaccid, absent, atrophy, fasciculations.
Cord syndromes	Brown Séquard split; central cord arms; syrinx cape; anterior cord spares vibration.
Discs	Lumbar catches the traversing root; cervical catches the root of the lower vertebra.
Emergencies	Myelopathy, cauda equina, dissection, stroke, GBS, epidural abscess, metastatic compression.

Chapters 7 and 8: numbers

Item	Value	Note
Tube	99% heat; tungsten Z 74; K shell about 69 keV	Thick part under the cathode
Factors	15% kVp = double mAs; inverse square	72 inch lateral cervical, chest, full spine
Limits	Worker 50; pregnancy 5; public 1 mSv	Background about 3 mSv a year
Pregnancy	Fetal threshold about 50 mGy; 10 day rule	Ask about LMP at about 12 to 50
Cervical	ADI 3 adult, 5 child; RPS 7 mm C2; RTS 22 mm C6	Canal over 13 mm; Torg under 0.8
Instability	Translation over 3.5 mm; angulation over 11°	Flexion extension films
Meyerding	25, 50, 75, 100%; 5 is spondyloptosis	Percent slip for follow up
Cobb	10° scoliosis; 5° change for progression	Brace about 25 to 40°
Chest	CTR under 0.5 on PA; 10 posterior ribs	Effusion: about 200 mL to blunt PA angle
Jefferson	Combined overhang over 7 mm	Transverse ligament rupture
Scheuermann	5° wedging in 3 vertebrae	Kyphosis over about 40 to 45°
AAA	3 cm or more; repair about 5.5 cm	5.0 cm in women

Chapters 7 and 8: rules

Topic	The rule
Image quality	mAs density; kVp contrast; focal spot, distance and motion detail.
Interactions	Photoelectric: contrast and patient dose. Compton: fog and staff dose.
Obliques	Cervical posterior oblique: far foramina. Lumbar posterior oblique: near pars.
MRI	T1 fat bright; T2 and STIR fluid bright; scar enhances, disc does not.
Imaging timing	No imaging in the first 6 weeks without red flags or deficit.
Fracture stability	Two or more columns, especially the middle column, is unstable.
Slips	Isthmic L5 pars defect; degenerative L4 intact pars.
Arthritis	OA non uniform; RA uniform with osteoporosis; gout overhanging edges; CPPD chondrocalcinosis.
Syndesmophytes	Marginal: AS and enteropathic. Nonmarginal: psoriatic and reactive.
Tumor	Over 40: metastasis (missing pedicle) or myeloma (cold scan).
Infection	Crosses the disc; disc space loss first. TB spares the disc early, forms gibbus.

Chapters 9 and 10: numbers

Item	Value	Note
First adjustment	September 18, 1895; Harvey Lillard	Davenport, Iowa; upper thoracic; deafness
Name	1896, Rev. Samuel Weed	Cheir plus praxis
Legal	Morikubo 1907; Wilk 1987	Philosophy defense; antitrust
Licensure	Kansas 1913 to Louisiana 1974	NBCE 1963; CCE 1974
Kappa	Fair 0.21 to 0.40; moderate 0.41 to 0.60	Substantial 0.61 to 0.80
MCID	NPRS 2 points or 30%; ODI 10; NDI 5 of 50	Compare effect with MCID
Stats	Alpha 0.05; power 0.80	CI crossing 0 or 1 is not significant
NNT	1 ÷ ARR	ARR = CER − EER
Sharpless	About 10 mm Hg cuts root conduction up to half	15 to 30 minutes
C1 to C2	About 40° rotation each way	Half of cervical rotation
Disc pressure	Supine 25, standing 100, sitting 140, sitting flexed 185	Classic L3 values
Thrust and cavitation	100 to 200 ms; refractory about 20 min	Pop does not predict outcome
Dissection risk	About 1 in 400,000 to several million	Causation not established

Chapters 9 and 10: rules

Topic	The rule
Founder vs developer	D.D. founder (tone, Innate, three Ts); B.J. developer (x-ray, NCM, HIO, straight).
Paradigm	Includes diagnosis; portal of entry means diagnose and refer.
Limits of adaptation	Innate is limited by matter; supports referral.
Design	RCT therapy; cohort prognosis; case control rare harm; cross sectional diagnosis.
Bias	Concealment: selection. Blinding: performance and detection. ITT keeps randomization.
Reliability	Pain provocation better than motion palpation; reliable is not always valid.
Evidence	Modest short term benefit for LBP, neck pain, cervicogenic headache; none for visceral disease.
PART	Two of four, one must be A or R.
Coupling	Cervical same side; lumbar opposite; scoliosis bodies to the convexity.
Sandoz	Thrust into paraphysiological space, short of anatomical limit.
Care phases	Acute, corrective, supportive, maintenance, wellness; Medicare covers active only.

Chapters 11 and 12: numbers

Item	Value	Note
Landmarks	C7, T3, T7, T9, L4, S2	Prominens, scapular spine, inferior angle, xiphoid, crests, PSIS
Cervical set up	Rotation 30 to 45°, never end range	ADI over 3 mm adult is unstable
Strain counterstrain	Hold about 90 seconds	Static stretch about 30 seconds
Trial of care	About 2 weeks; re-exam every 2 to 4 weeks	Two failed trials: modify or refer
MCIDs	NRS 2; ODI 10; RMDQ 2 to 3; NDI 5 to 7; PSFS 2	
Benign reactions	A third to a half of patients	Resolve in 24 to 72 hours
Ultrasound	1 MHz deep; 3 MHz superficial	0.5 to 2.5 W/cm^2
TENS	80 to 150 Hz gate; 2 to 4 Hz endorphins	Interferential about 4,000 Hz
Screening ages	Colorectal 45 to 75; mammogram 40 to 74	Lung 50 to 80 with 20 pack years
Alcohol	Standard drink 14 g; men 4 a day or 14 a week	Women 3 a day or 7 a week
Activity	150 to 300 min moderate a week	Strength 2 days; children 60 min daily
NIOSH	Constant 23 kg; LI over 1.0 risk	Over about 3.0 high risk
Noise	PEL 90 dBA; action 85 dBA	NIOSH 85 dBA with 3 dB exchange

Chapters 11 and 12: rules

Topic	The rule
Listings	Gonstead names the spinous; National names the body; they turn oppositely.
Atlas	AS, laterality, then A or P of that transverse; laterality corrected L to M.
Thoracic	Thrust at end of exhalation; inhalation group top rib first, exhalation group bottom rib first.
Lumbar	Mammillary push P to A; spinous push L to M; no P to A on a slipped segment.
Pelvis	PI short leg, PSIS; AS long leg, ischium.
Extremity glide	Convex opposite, concave same: abduction inferior; knee extension anterior; dorsiflexion posterior.
Consent	PARQ, material risk; battery without consent; negligence for undisclosed risk.
Contraindications	Absolute: fracture, tumor, infection, instability, cauda equina, dissection, large AAA.
Prevention	Primary, secondary, tertiary, quaternary; USPSTF A and B recommended.
Stages of change	6 months and 30 days set the boundaries.
Exposures	Lead stippling; arsenic Mees lines; asbestos lower lobe; silica upper lobe and TB.

Chapters 13 and 14: numbers

Item	Value	Note
TUG	12 seconds or more	Fall risk
MMSE / MoCA	24 or below / below 26	Cognitive impairment
Calcium and vitamin D	About 1,200 mg over 50; 800 to 1,000 IU	Bisphosphonates first line
Skin lesion size	1 cm cutoff	Nodule 1 to 2 cm; tumor over 2 cm
Melanoma diameter	6 mm or more	Evolving is most important
HIV	AIDS at CD4 under 200	PCP under 200; CMV under 50
Acetaminophen	Max about 4 g a day	N acetylcysteine
Warfarin INR	Usually 2 to 3	Unstable INR: no thrust
CPR	100 to 120 a minute; at least 2 in; 30:2	Child two rescuers 15:2
Epinephrine	0.3 mg adult; 0.15 mg small child, IM thigh	Repeat in 5 to 15 minutes
Cycle	28 days (21 to 35); ovulation about day 14	Luteal phase about 14 days
Pregnancy	Supine hypotension after 20 weeks; GDM 24 to 28	Preeclampsia 140/90 after 20 weeks
APGAR	1 and 5 minutes; 7 to 10 reassuring	0 to 3 low
Fontanelles	Posterior 2 months; anterior 18 months	

Chapters 13 and 14: rules

Topic	The rule
Older adults	Atypical presentation; confusion or a fall may be infection or MI.
Delirium	Acute, fluctuating, inattentive: same day referral.
Blisters	Pemphigus flaccid, Nikolsky positive; pemphigoid tense, negative.
Hot knee, young adult	Gonococcal (pustules, tenosynovitis) versus reactive (sterile, HLA-B27).
Tabes dorsalis	Romberg positive, Argyll Robertson pupils, Charcot joints.
Emergencies	Scene, EMS and AED, ABC; sugar if they can swallow; epinephrine first.
Psychology	Malingering external gain; factitious sick role; Waddell is not lying.
Women with pain	Pregnancy first; previa painless, abruption painful.
Children	Examine the hip for knee pain; regression is a red flag.
Abuse	Reasonable suspicion: report; proof not needed.
Law	Four Ds; capacity clinical, competence legal; HIPAA treatment, payment, operations.

An independent study aid, not affiliated with or endorsed by the National Board of Chiropractic Examiners.
Dr. Garg Learning · CC BY-SA 4.0