PART II CLINICAL SCIENCES · BOARD REVIEW

Study Guide 6

This guide covers chiropractic practice. Chapter 11 is spinal analysis, listings, set ups for every region and the named technique systems. Chapter 12 is case management, consent and documentation, contraindications and referral, rehabilitation and modalities, community health and screening, and occupational and environmental health. You will learn how to translate a listing, choose a contact and line of drive, decide when not to thrust, and counsel and protect patients and workers. Work one chapter at a time, and finish each with its ten board-style items.

WHAT THIS GUIDE COVERS

- Chapter 11 · PARTS, observation, surface landmarks, static and motion palpation, end feel, instruments, Gonstead and National listings, leg checks, cervical, thoracic, rib, lumbar and pelvic set ups, the convex concave rule and extremity adjusting, and the technique systems (Diversified, Gonstead, Thompson, Activator, flexion distraction, upper cervical, SOT, AK, soft tissue).
- Chapter 12 · report of findings, informed consent, treatment plans and outcome measures, SOAP notes and coding, contraindications, adverse events, dissection screening and referral, healing and exercise, stretching, modalities, ergonomics, prevention, USPSTF screening, tobacco, alcohol, obesity, behavior change, OSHA, NIOSH, the lifting equation, hierarchy of controls, noise and environmental exposures.

CHAPTER 11

Spinal Analysis, Patient Evaluation and Adjustive Technique

Read it in full: **Chapter 11 in the textbook**. Practice it: **Practice exam 6** and the **flashcards**.

What to know

Spinal analysis asks three questions in order: is manual care appropriate at all (red flags, contraindications), where is the lesion, and what is its character (direction of restriction, side of tenderness, tissue). No single tool is reliable enough alone, so findings are combined. Document a segmental lesion with **PARTS**: pain and tenderness, asymmetry or misalignment, range of motion

abnormality, tissue tone, texture and temperature, and special tests. For federal documentation by examination, two of the four PART findings are needed and one must be A or R.

Observation: a lateral list away from the painful side suggests a disc lateral to the root; a list toward the painful side suggests a medial (axillary) disc. Surface landmarks: **C2** first palpable spinous below the occiput; hyoid C3; thyroid cartilage C4 to C5; cricoid and carotid tubercle C6 (never press both sides); vertebra prominens **C7**; root of the scapular spine **T3**; inferior angle **T7**; xiphisternal junction T9; iliac crests **L4** or L4 to L5; PSIS **S2**, where the dural sac ends. Count from at least two landmarks.

Motion palpation finds fixations; the restricted direction becomes the thrust direction in diversified care. Joint play (Mennell) is involuntary accessory motion. End feels: bony, capsular, soft tissue approximation are normal at the right joints; muscle spasm, springy block (meniscus) and **empty** (pain before resistance: bursitis, abscess, fracture, neoplasm) are abnormal. Interexaminer motion palpation kappa is often under 0.4; pain provocation is more reliable. Instruments: goniometry, dual inclinometry, algometry, dual probe heat readers (Gonstead); thermography, surface EMG and HRV are monitoring tools without validated subluxation detection. A scoliometer reading of about 7 degrees is a common referral threshold.

Listings: the **Palmer Gonstead** system names where the spinous went, always starting with P: then the side of spinous rotation (R or L), then S (wedge open on the side of spinous rotation) or I (open opposite), with -M for a mammillary or -Sp for a spinous contact. The **National** system names body motion: a spinous to the right is a body rotated **left**. Atlas listings start with AS (or AI), then laterality, then the rotation of the transverse on that side (A or P): ASRP means anterior superior, right laterality, right transverse posterior. Prone leg checks show functional short legs; anatomical inequality needs a standing film, and a heel lift usually starts at about half the measured difference.

Set up vocabulary: patient position, doctor stance (square or fencer), contact point (pisiform, thenar, index MCP, thumb), segmental contact point, line of drive (P to A, L to M, I to S), tissue pull, pre adjustive tension, thrust. Facet planes set the line of drive: cervical about 45 degrees, thoracic about 60 degrees, lumbar near sagittal (more coronal at L5 to S1).

Cervical: atlas laterality is corrected supine with an index contact on the lateral transverse, drive **L to M**, slightly I to S. The axis takes an index contact on the lamina or spinous, P to A. The lower cervical **rotary break**: index proximal phalanx on the articular pillar on the side of posterior body rotation, head rotated away 30 to 45 degrees (never end range), drive P to A and slightly I to S, **toward the opposite eye**. The lateral break drives L to M with little rotation. Rotation plus extension most narrows the contralateral vertebral artery at C1 to C2, so avoid end range rotation with extension. Screen every neck for dissection (sudden unusual pain, 5 Ds and 3 Ns) and instability (RA, Down syndrome, ankylosing spondylitis, os odontoideum; ADI over 3 mm adult or 5 mm child).

Thoracic: thrust at the **end of exhalation**. Bilateral transverse prone (pisiforms on both transverses, P to A, slight I to S) for extension restriction; unilateral transverse for rotation; anterior thoracic supine with arms crossed, thrust A to P through the elbows. Avoid seated lifts and long levers in osteoporosis. Ribs: upper ribs pump handle, ribs 7 to 10 bucket handle, 11 and 12 caliper. Treat the top rib of an inhalation restriction group and the bottom rib of an exhalation group first. Elevated first rib: index MCP on the superior first rib, drive superior to inferior toward the opposite hip. Screen chest wall pain for angina, PE, pneumothorax, fracture, metastasis and pre-eruptive zoster.

Lumbar side posture (lumbar roll): bottom leg straight, top hip and knee flexed, shoulder rotated back and pelvis rolled forward until the target moves. **Mammillary push**: pisiform on the up side mammillary, P to A with a body drop (up side is the side of posterior body rotation). **Spinous push**: up side of the spinous, L to M toward the table. Spinous pull hooks the down side. Side posture mainly gaps the up side facet. Reduce rotation when rotation reproduces leg pain. In spondylolisthesis, never thrust P to A on the slipped segment.

Pelvis: **PI ilium** (PSIS posterior and inferior) gives a short leg and a taller looking ilium on film; side posture, PI side up, pisiform on the PSIS, P to A and I to S. **AS ilium** gives a long leg and a shorter looking ilium; contact the ischial tuberosity, P to A along the flexed femur. In and Ex add a medial or lateral component. Posterior sacrum: prone, ala contact, P to A. Internal coccyx work needs written consent, a chaperone and scope confirmation.

Extremities: adjust in the loose packed position in the direction of the lost glide, using the **convex concave rule** (a convex surface glides opposite to its bone's motion; a concave surface glides the same way). Shoulder abduction needs **inferior** humeral glide; knee extension needs **anterior** tibial glide; ankle dorsiflexion needs **posterior** talar glide. Pulled elbow (ages about 1 to 4): supination then flexion or hyperpronation. Posterior fibular head: contact the head, not the neck, where the common fibular nerve lies. Cuboid whip for cuboid syndrome after inversion sprain. Apply the Ottawa rules first.

Technique systems: Diversified (largest trial base); **Gonstead** (disc focused, five criteria: visualization, instrumentation, static palpation, motion palpation, x-ray); **Thompson** drop table with the Derefield maneuver and cervical syndrome test; **Activator** spring loaded instrument with leg length positions 1 and 2 and isolation tests; **flexion distraction** (Cox) lowers intradiscal pressure and suits disc herniation and stenosis after a tolerance test; upper cervical (HIO toggle recoil, orthogonal); **SOT** categories I, II, III with pelvic blocks; applied kinesiology (muscle testing diagnosis no better than chance). Soft tissue: trigger points, post isometric relaxation, PNF, strain counterstrain (about 90 seconds), Cyriax friction.

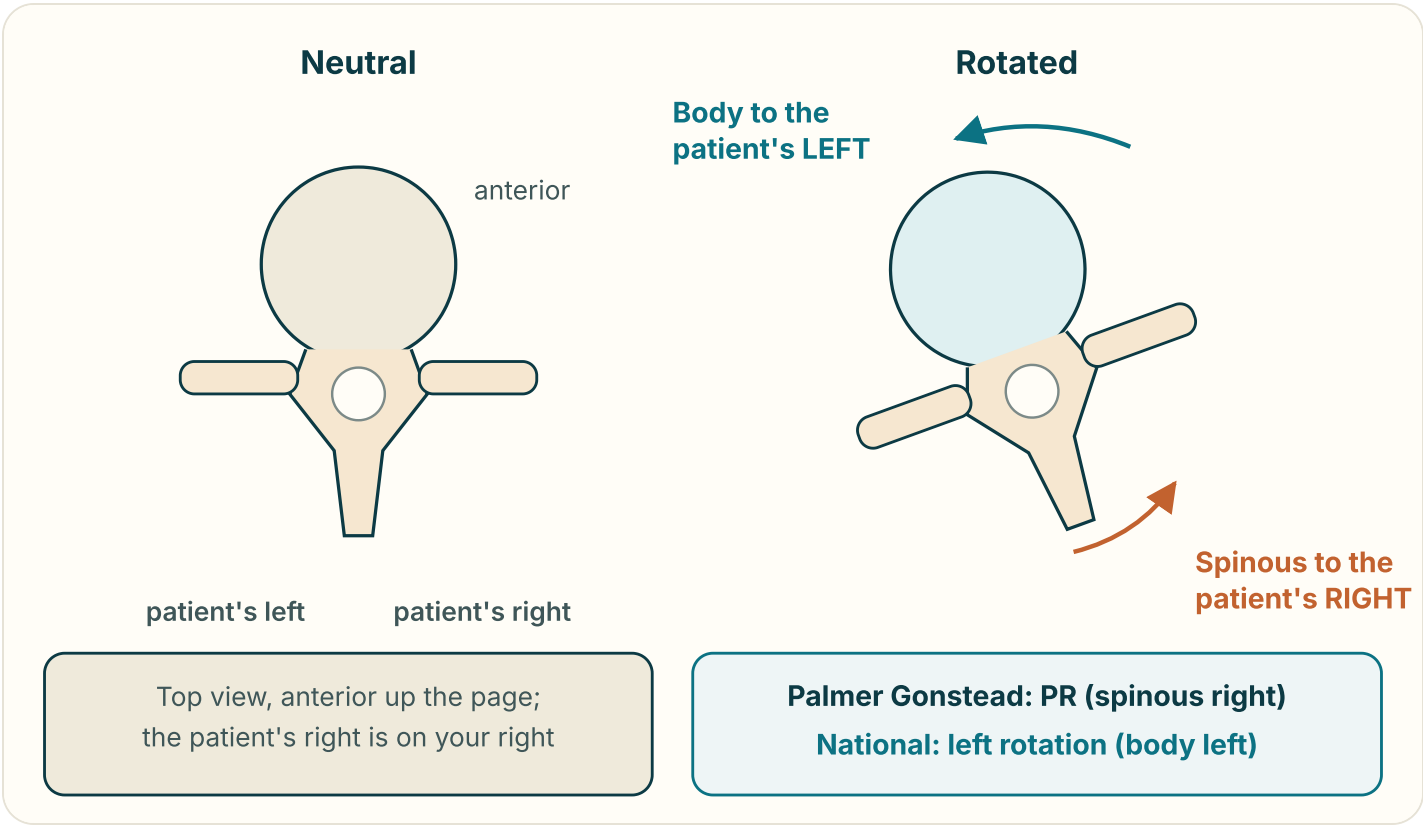

One rotation, two names. A spinous palpated to the right (Palmer Gonstead PR) belongs to a body that has rotated left (National left rotation), because the two ends of the vertebra swing opposite ways around the vertical axis.

LOCK THESE IN

- PARTS documents a lesion; by exam, two of PART with one being A or R.
- Landmarks: C7 prominens, T3 scapular spine, T7 inferior angle, L4 iliac crests, S2 PSIS.
- Gonstead PR (spinous right) = National left body rotation.
- Lower cervical rotary break: pillar contact, P to A and I to S, toward the opposite eye; never end range.
- Thoracic thrust at end of exhalation; avoid long levers in osteoporosis.
- Mammillary push P to A; spinous push L to M; no P to A thrust on a slipped segment.
- PI ilium: short leg, PSIS contact, P to A and I to S. AS ilium: long leg, ischial contact, P to A.
- Convex concave rule: abduction inferior glide, knee extension anterior tibial glide, dorsiflexion posterior talar glide.

Set ups at a glance

Set up	Contact and SCP	Line of drive
Atlas laterality, supine	Index on lateral atlas transverse	L to M, slight I to S
Lower cervical rotary break	Index MCP on articular pillar	P to A, I to S, toward opposite eye
Lower cervical lateral break	Index on lateral pillar	L to M
Cervicothoracic thumb move	Thumb on lateral C7 or T1 spinous	L to M
Bilateral transverse (prone)	Both pisiforms on transverses	P to A, slight I to S, at exhalation
Anterior thoracic (supine)	Fist or pistol grip under segment	A to P through crossed elbows
Elevated first rib	Index MCP on superior first rib	S to I toward the opposite hip
Side posture mammillary push	Pisiform on up side mammillary	P to A with body drop
Side posture spinous push	Pisiform on up side of spinous	L to M toward the table
PI ilium	Pisiform on PSIS, PI side up	P to A and I to S
AS ilium	Ischial tuberosity, AS side up	P to A along the flexed femur

Joint positions for extremity work

Joint	Loose packed	Close packed
Glenohumeral	About 55° abduction, 30° horizontal adduction	Full abduction with external rotation
Humeroulnar	About 70° flexion, 10° supination	Full extension with supination
Radiocarpal	Neutral, slight ulnar deviation	Full extension with radial deviation
Hip	About 30° flexion, 30° abduction, slight ER	Extension, internal rotation, abduction
Knee	About 25° flexion	Full extension with tibial ER
Talocrural	About 10° plantarflexion	Full dorsiflexion

Worked cases

WORKED CASE 1 · TRANSLATING A LISTING

Static and motion palpation of L3 show the spinous process rotated to the left, and the disc wedge is open on the left. The segment is posterior.

STEP 1 · BUILD THE GONSTEAD LISTING

Posterior (P), spinous left (L), wedge open on the same side as spinous rotation (S): **PLS**.

STEP 2 · TRANSLATE TO NATIONAL TERMS

A spinous to the left means the body has rotated **right**. A wedge open on the left means the body is laterally flexed to the right. So: right rotation with right lateral flexion.

STEP 3 · CHOOSE THE CONTACT

Gonstead places the open side up in side posture; an S listing takes a spinous contact, driving L to M.

CHECK

If the wedge were open on the right (PLI), the listing would take a mammillary contact (PLI-M).

WORKED CASE 2 · PI ILIUM

Prone, the right leg looks short in both knee positions. The right PSIS is posterior and inferior, and on the AP film the right ilium looks taller.

STEP 1 · NAME THE LISTING

Posterior inferior rotation of the right innominate: **right PI ilium**.

STEP 2 · CHECK THE LEG

A PI ilium gives a short leg on that side; an AS ilium gives a long leg.

STEP 3 · SET UP

Side posture with the right (PI) side up; pisiform on the right PSIS.

STEP 4 · LINE OF DRIVE

P to A and I to S, rotating the ilium forward and up.

IF IT WERE AS

An AS ilium would take an ischial tuberosity contact with a P to A drive along the flexed femur, rotating the ilium posteriorly.

WORKED CASE 3 · CHOOSING A GLIDE WITH THE CONVEX CONCAVE RULE

A patient lacks shoulder abduction and, separately, ankle dorsiflexion after a sprain.

STEP 1 · SHOULDER

The humeral head is convex on the concave glenoid, so it glides opposite to the arm's motion. Abduction moves the arm up, so the head must glide **inferiorly**.

STEP 2 · ANKLE

The talus is convex on the concave mortise. Dorsiflexion rolls it forward, so it must glide **posteriorly**; an anterior talus blocks dorsiflexion.

STEP 3 · KNEE FOR CONTRAST

The tibia is concave on the convex femur, so it glides the same way it moves: extension needs **anterior** tibial glide.

STEP 4 · SAFETY

Apply the Ottawa rules before adjusting an acute ankle, and use the loose packed position.

WORKED CASE 4 · MATCHING TECHNIQUE TO THE PATIENT

A 47 year old has an L5 to S1 disc herniation with leg pain that worsens with trunk rotation. There is no saddle numbness, bladder change or progressive weakness.

STEP 1 · SCREEN FIRST

Cauda equina signs are absent, and weakness is not progressing, so conservative care is reasonable.

STEP 2 · AVOID WHAT PROVOKES

Rotation reproduces leg pain, so reduce or avoid rotational side posture thrusts.

STEP 3 · PICK A METHOD

Flexion distraction lowers intradiscal pressure and increases posterior disc height and foraminal area.

STEP 4 · TOLERANCE TEST

Start with a tolerance test; stop or modify if leg pain increases or peripheralizes.

TRAPS PEOPLE FALL INTO

- **Documenting P and T only.** By exam, one of the two findings must be asymmetry or range of motion.
- **Counting levels from one landmark.** Landmarks vary by a segment in many people. Count from at least two.
- **Translating PR as right rotation.** Spinous right is body left. The National system names the body.
- **Rotating the neck to end range before thrusting.** Rotation with extension narrows the contralateral vertebral artery. Use 30 to 45 degrees and short arcs.
- **Thrusting at the start of inhalation.** Thoracic and rib thrusts go at the end of exhalation, when muscles relax.
- **Pushing P to A on a slipped L5.** That drives it further forward. Contact above or below or use flexion distraction.
- **Contacting the fibular neck.** The common fibular nerve lies at the neck. Stay on the head.
- **Believing AK diagnosis identifies nutrient needs.** Controlled studies show AK diagnosis is no better than chance.

Chapter 11 self-test · ten items

1. Which landmark is usually at the level of T7 with the arms at the sides?

A. Root of the scapular spine

B. Tops of the iliac crests

C. The xiphisternal junction

D. Inferior angle of the scapula

D. Inferior angle of the scapula The inferior scapular angle marks T7; the root of the scapular spine is T3, the xiphisternal junction T9 and the iliac crests L4.

2. In the Palmer Gonstead system, a segment listed PR is described how in the National system?

A. Right body rotation
B. Pure extension only
C. Left body rotation
D. Right lateral flexion

C. Left body rotation The spinous and body turn oppositely, so a spinous to the right means the body rotated left.

3. A chart documents tenderness at T6 and paraspinal hypertonicity, with no asymmetry or motion finding. Is a subluxation documented by examination?

A. No, all four are required
B. No, A or R is required
C. Yes, if an x-ray is on file
D. Yes, two findings are present

B. No, A or R is required Two of PART are needed, and one must be asymmetry or range of motion. P plus T alone does not qualify.

4. For a lower cervical rotary break, where is the contact and what is the line of drive?

A. Articular pillar; P to A, I to S
B. Lamina; A to P and inferior
C. Spinous process; L to M only
D. Transverse process; S to I

A. Articular pillar; P to A, I to S The index MCP sits on the articular pillar on the side of posterior body rotation, driving along the 45 degree facet plane toward the opposite eye.

5. Why is end range rotation combined with extension avoided in cervical adjusting?

A. It locks the facets on the contact side
B. It narrows the opposite vertebral artery
C. It compresses the hypoglossal nerve
D. It overstretches the anterior longitudinal ligament

B. It narrows the opposite vertebral artery Rotation with extension most narrows the contralateral vertebral artery at the atlantoaxial level, so set ups use partial rotation and short arcs.

6. You are set up for a bilateral transverse contact at T6. In the breathing cycle, when is the thrust timed?

A. At the start of inhalation
B. During a held breath
C. At the end of exhalation
D. At the peak of inhalation

C. At the end of exhalation At the end of exhalation the paraspinals are most relaxed and the chest least resistant.

7. A patient has an isthmic spondylolisthesis of L5. Which approach is inappropriate at that level?

A. P to A thrust on the L5 spinous
B. Flexion distraction at L5 to S1
C. Low force drop on the sacrum
D. Contact on the segment below

A. P to A thrust on the L5 spinous A P to A thrust on the slipped segment drives it further forward. Use flexion distraction or contact the segment above or below.

8. Prone, a patient's right leg is long, the right PSIS is anterior and superior, and the right ilium looks shorter on the AP film. What is the listing and contact?

A. PI ilium; PSIS contact
B. AS ilium; PSIS contact
C. PI ilium; ischial contact
D. AS ilium; ischial contact

D. AS ilium; ischial contact An AS ilium gives a long leg and a shorter looking ilium; the contact is the ischial tuberosity, P to A along the flexed femur.

9. A patient lacks shoulder abduction. Which glide of the humeral head should be restored?

A. Lateral glide
B. Inferior glide
C. Superior glide
D. Anterior glide

B. Inferior glide The convex humeral head glides opposite to the arm's motion, so abduction needs inferior glide.

10. Which technique uses a hand held spring loaded instrument with leg length positions 1 and 2 and isolation tests?

A. Thompson drop
B. Gonstead system
C. Cox flexion distraction
D. Activator Methods

D. Activator Methods Activator compares leg length with knees extended and flexed and uses isolation tests, then delivers a low force instrument impulse.

CHAPTER 12

Patient Care, Community Health and Occupational Health

Read it in full: **Chapter 12 in the textbook**. Practice it: **Practice exam 6** and the **flashcards**.

What to know

The **report of findings** explains the diagnosis, the findings, the prognosis with and without care, the plan, alternatives, costs and the patient's responsibilities, using teach back. It is also when red flag findings and referrals are explained.

Informed consent is a process: capacity, adequate information, understanding and voluntary agreement. Many jurisdictions use the **material risk** (reasonable patient) standard. PARQ: procedures, alternatives (including no treatment), risks (common soreness and headache; rare fracture, disc injury, cauda equina syndrome, stroke from dissection) and questions. Renew consent when the plan changes; minors need a guardian's consent with the child's assent; sensitive areas need specific consent and a chaperone offer. Treating without consent can be battery; failing to disclose a material risk that occurs is negligence.

Plans: measurable functional goals, phases (acute, corrective, rehabilitative, optional maintenance), frequency matched to natural history (most acute low back pain improves within about 6 weeks). A trial of care is about **2 weeks**; after two trials (about 4 weeks) with no documented improvement, change the plan or refer. Re-examine every 2 to 4 weeks or about every 12 visits. Outcome MCIDs: NRS about 2 points or 30%, Oswestry about 10, Roland Morris 2 to 3, NDI 5 to 7, PSFS about 2. Discharge at goals, maximum medical improvement, failure (refer), patient choice or futility, without abandonment.

SOAP: S is the patient's report; O the findings including outcome scores; A the diagnosis and progress; P the procedures, home care and next steps. Correct with a single line, the correct entry, date and initials; never obliterate or backdate. CMT codes are billed by number of spinal regions (1 to 2, 3 to 4, 5) plus extraspinal. HIPAA allows sharing for treatment, payment and operations under the minimum necessary rule. Negligence needs the four Ds: duty, dereliction, direct cause, damages. Child abuse, and in most states elder abuse, must be reported.

Contraindications to thrust: **absolute** for acute fracture or dislocation, tumor in the area, infection, upper cervical instability, cauda equina or acute myelopathy, suspected dissection, a large or symptomatic aneurysm, and prostheses or fused levels. **Relative** (modify) for anticoagulation and bleeding disorders, osteoporosis, inflammatory arthritis flares, spondylolisthesis, disc herniation with deficit, hypermobility disorders and complicated pregnancy. Uncomplicated pregnancy is not a contraindication.

Adverse events: benign reactions in about a third to a half of patients, starting within 24 hours and resolving in 24 to 72 hours. Stroke associated with cervical manipulation is about 1 in several hundred thousand to several million; cauda equina after lumbar manipulation well under 1 per million. Screen for dissection by history and exam (BE FAST, both arm pressures, cranial nerves, coordination, bruits). Positional tests (George, DeKleyn, Hautant, Underberg, Maigne, Barré Liéou) are still tested but have poor sensitivity. Refer at the right urgency: emergency, urgent or routine, in writing, and follow up.

Rehabilitation follows healing: inflammation (about 3 to 5 days: protect, POLICE, optimal loading), repair (to about 3 to 6 weeks: type III collagen, gentle loading), remodeling (to a year or more: type I collagen, progressive strengthening). Exercise: FITT, overload, SAID specificity, progression, reversibility; eccentric loading for tendinopathy; closed chain after knee ligament injury; about 8 to 12 reps at 60 to 80% of 1RM for strength. Stabilization: brace, curl up, side bridge, bird dog; deep neck flexor chin nod. **McKenzie**: centralization predicts a good outcome. Williams flexion for facet and stenosis. Janda upper and lower crossed syndromes. Static stretch about 30 seconds; PNF hold relax uses autogenic inhibition, CRAC adds reciprocal inhibition.

Modalities: ice 10 to 20 minutes; moist heat 15 to 20 minutes, about 1 cm deep; **ultrasound 1 MHz deep (up to about 5 cm), 3 MHz superficial**; high frequency TENS (80 to 150 Hz) works through the gate, low frequency (2 to 4 Hz) through endorphins; interferential uses about 4,000 Hz currents to make a beat; dexamethasone (negative) is delivered from the negative electrode; cervical traction about 20 to 30 lb in 20 to 30 degrees of flexion, lumbar up to about half body weight. Recurring contraindications: pacemaker, pregnant uterus, eyes, gonads, malignancy, thrombosis, impaired sensation.

Prevention: primary (stop it starting), secondary (screen early), tertiary (limit disability), quaternary (avoid overtreatment). Agencies: WHO, HHS (Healthy People), CDC, NIH, FDA, USPSTF (grades A to D and I), EPA, OSHA and NIOSH. USPSTF screens: colorectal **45 to 75**; mammography **40 to 74 every 2 years**; cervical 21 to 65; lung LDCT **50 to 80 with 20 pack years** (current or quit within 15 years); AAA ultrasound for **men 65 to 75 who ever smoked**; DXA women 65+; diabetes 35 to 70 with overweight; PSA 55 to 69 individual (C), 70+ not recommended (D); HIV 15 to 65; hepatitis C 18 to 79. Watch lead time and length bias.

Tobacco is the leading preventable cause of death and speeds disc degeneration. The **5 As**: ask, advise, assess, assist, arrange; the 5 Rs for those not ready: relevance, risks, rewards, roadblocks, repetition. A standard drink has about 14 g of alcohol. Low risk limits: men no more than 4 a day or 14 a week, women no more than 3 a day or 7 a week. CAGE 2 or more is significant; SBIRT follows a positive screen. BMI 30 or more is obesity; 5 to 10% weight loss improves risk factors; activity 150 to 300 minutes moderate a week plus strength twice. Stages of change hinge on time: precontemplation (no intent within 6 months), contemplation (within 6 months), preparation (within 30 days), action (under 6 months), maintenance (over 6 months).

Occupational: **OSHA** enforces (General Duty Clause, OSHA 300 log, Hazard Communication, Bloodborne Pathogens Standard); **NIOSH** researches. Workers' compensation is no fault. The **NIOSH lifting equation** starts from 23 kg (51 lb) and multiplies six factors of 1.0 or less; lifting index over 1.0 means increased risk, over about 3.0 high risk. Hierarchy of controls: elimination, substitution, engineering, administrative, PPE. Noise: OSHA PEL 90 dBA (8 hours, 5 dB exchange), action level 85 dBA; NIOSH 85 dBA with 3 dB exchange; noise loss notches at 4,000 Hz. Workplace violence type II (patient on worker) is most common in health care. Exposures: lead (basophilic stippling, wrist drop), arsenic (Mees lines), asbestos (lower lobe, mesothelioma), silica (upper lobe, eggshell nodes, TB), benzene (leukemia), vinyl chloride (hepatic angiosarcoma), radon (lung cancer in nonsmokers, mitigate at 4 pCi/L), CO (pulse oximetry falsely normal), organophosphates (atropine and pralidoxime), nitrates (methemoglobinemia).

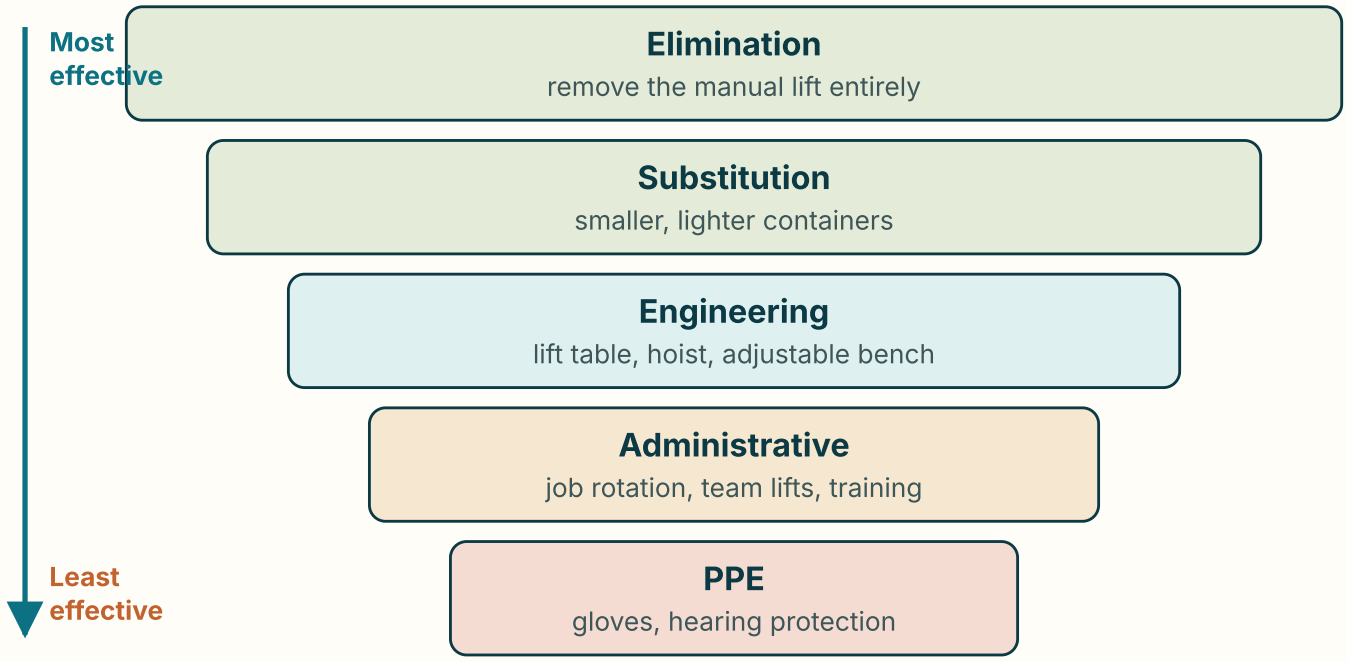

Remove the hazard before you protect the worker from it. Elimination and substitution remove the hazard, engineering isolates people from it, administrative controls change how people work, and PPE is the last line of defense.

LOCK THESE IN

- Consent is PARQ under a material risk standard; renew when the plan changes.
- Trial of care about 2 weeks; two trials without change means modify or refer.
- SOAP: S report, O findings and scores, A diagnosis and progress, P plan.
- Absolute: fracture, tumor, infection, instability, cauda equina, dissection, large aneurysm, prosthesis.
- Ultrasound 1 MHz deep, 3 MHz superficial; TENS high frequency gate, low frequency endorphins.
- USPSTF: colorectal 45 to 75; mammogram 40 to 74 every 2 years; lung 50 to 80 with 20 pack years; AAA men 65 to 75 who smoked.
- NIOSH constant 23 kg; lifting index over 1.0 means risk. Hierarchy: eliminate first, PPE last.
- Noise PEL 90 dBA; action level 85 dBA; 4,000 Hz notch.

Contraindications to thrust

Condition	Status	What to do
Acute fracture or dislocation	Absolute	Immobilize and refer
Tumor or infection in the area	Absolute	Refer; gentle care elsewhere may be fine
Upper cervical instability	Absolute for upper cervical thrust	Flexion and extension films
Cauda equina, myelopathy, dissection	Absolute	Emergency referral
Large or symptomatic AAA	Absolute for lumbar thrust	Emergency if pulsatile and painful
Anticoagulation, bleeding disorder	Relative	Reduce force
Osteoporosis	Relative	Low force, no long levers
Spondylolisthesis	Relative (local)	No P to A on the slipped level
Prosthesis or fused level	Absolute at that level	Treat adjacent regions with care
Complicated pregnancy	Relative to absolute	Obstetric referral

Modalities and parameters

Modality	Parameters	Key point
Cryotherapy	10 to 20 minutes	Cold, burning, aching, numbness
Moist heat	15 to 20 minutes, about 1 cm deep	Not in acute inflammation
Ultrasound	1 MHz deep (to 5 cm); 3 MHz superficial; 0.5 to 2.5 W/cm^2	Keep the head moving
Shortwave diathermy	27.12 MHz, about 20 minutes	No metal implants
TENS conventional	80 to 150 Hz, sensory level	Gate control
TENS acupuncture like	2 to 4 Hz, motor level	Endogenous opioids
Interferential	About 4,000 Hz carriers, low beat	Deep stimulation
Iontophoresis	Direct current; like charges repel	Dexamethasone from the negative pole
Traction	Cervical 20 to 30 lb at 20 to 30° flexion; lumbar to about half body weight	Not with instability or tumor

Worked cases

WORKED CASE 1 · NIOSH LIFTING INDEX

A worker lifts a 17 kg box held 50 cm in front of the ankles. All other multipliers equal 1.0. The horizontal multiplier is 25 ÷ H (H in cm).

STEP 1 · HORIZONTAL MULTIPLIER

HM = 25 ÷ 50 = **0.5**.

STEP 2 · RECOMMENDED WEIGHT LIMIT

RWL = 23 kg × 0.5 × 1 × 1 × 1 × 1 × 1 = **11.5 kg**.

STEP 3 · LIFTING INDEX

LI = 17 ÷ 11.5 = **1.48**: over 1.0, so increased risk.

STEP 4 · FIX IT

Bring the load in to 25 cm: HM = 1.0, RWL = 23 kg and LI = 17 ÷ 23 = 0.74. "Keep it close" halves the risk here. An engineering control such as a lift table beats training alone.

WORKED CASE 2 · SORTING A SOAP NOTE

Sort these entries: "Pain 4 of 10, can sit 30 minutes"; "Cervical rotation 60 degrees left, 45 right; NDI 18 of 50"; "Improving, about 50% toward goal"; "Re-examine in 2 weeks, add bird dog".

STEP 1 · SUBJECTIVE

"Pain 4 of 10, can sit 30 minutes" is the patient's report: **S**.

STEP 2 · OBJECTIVE

Measured ranges and the NDI score are findings: **O**. Questionnaire scores usually go under O.

STEP 3 · ASSESSMENT

"Improving, 50% toward goal" is your judgment of progress: **A**.

STEP 4 · PLAN

The re-examination date and home exercise are next steps: **P**.

WORKED CASE 3 · CONTRAINDICATION DECISIONS

Three patients: (1) a 74 year old woman with osteoporosis and mid back pain; (2) a man on warfarin with neck pain and an INR in range; (3) a woman with rheumatoid arthritis and an ADI of 5 mm.

STEP 1 · PATIENT 1

Osteoporosis is a **relative** contraindication: use low force, instrument or drop methods, and avoid long levers, seated lifts and rib loading.

STEP 2 · PATIENT 2

Anticoagulation is **relative**: reduce force and avoid high force thrust if poorly controlled. Watch for new back pain with leg weakness (epidural hematoma).

STEP 3 · PATIENT 3

An ADI over 3 mm in an adult means upper cervical instability: an **absolute** contraindication to upper cervical thrust; refer.

WORKED CASE 4 · SCREENING AND COUNSELING

A 58 year old man who smoked 1 pack a day for 30 years and quit 10 years ago asks which screening he needs, and says he drinks 3 beers most nights.

STEP 1 · PACK YEARS

1 pack × 30 years = **30 pack years**; he quit 10 years ago (within 15).

STEP 2 · LUNG CANCER

Age 50 to 80, at least 20 pack years, quit within 15 years: yearly **low dose CT**.

STEP 3 · COLORECTAL

Age 45 to 75: colonoscopy every 10 years or a stool based option.

STEP 4 · ALCOHOL

3 drinks most nights is about 21 a week, over the 14 per week limit for men. Screen with AUDIT-C or CAGE and use SBIRT.

STEP 5 · LATER

At 65 to 75, as a man who ever smoked, a one time AAA ultrasound.

TRAPS PEOPLE FALL INTO

- **Treating a signed form as consent.** Consent is a process of disclosure, understanding and voluntary agreement, renewed when the plan changes.
- **Continuing high frequency care without progress.** After two trials of care without documented change, modify or refer.
- **Filing outcome scores under S.** Questionnaire scores are usually filed under O.
- **Calling uncomplicated pregnancy a contraindication.** Only complicated pregnancy (bleeding, previa, preterm labor) changes care.
- **Relying on positional tests to clear a dissection.** They have poor sensitivity. The history and exam decide.
- **Mixing up ultrasound frequencies.** 1 MHz goes deep; 3 MHz stays superficial.
- **Choosing PPE first in the hierarchy.** Elimination and substitution are most effective; PPE is the last line.
- **Confusing OSHA and NIOSH.** OSHA enforces standards; NIOSH researches and recommends.

Chapter 12 self-test · ten items

1. Which consent standard asks what a reasonable patient would want to know to decide?

A. Therapeutic privilege
B. Implied consent rule
C. Professional standard
D. Material risk standard

D. Material risk standard The material risk (reasonable patient) standard requires disclosure of what a reasonable person in the patient's position would want to know, including rare serious risks.

2. A patient has had two 2 week trials of care with different approaches and no documented improvement. What is appropriate?

A. Continue the same plan longer
B. Change the plan or refer
C. Begin maintenance care now
D. Increase visits to five a week

B. Change the plan or refer Lack of measured progress after two trials (about 4 weeks) means modifying the plan or referring.

3. In a SOAP note, where does "Oswestry 32% today, down from 48%" belong?

A. Assessment
B. Plan
C. Objective
D. Subjective

C. Objective Measured findings, including outcome questionnaire scores, are usually filed under O.

4. Which condition is an absolute contraindication to thrust at the involved level?

A. Vertebral osteomyelitis
B. Well controlled anticoagulation
C. Mild osteopenia
D. Uncomplicated pregnancy

A. Vertebral osteomyelitis Spinal infection is absolute; anticoagulation and osteopenia call for modification, and uncomplicated pregnancy is not a contraindication.

5. Three days after a whiplash injury, a 39 year old reports a new ache along the left jaw and eye. The left eyelid droops and the left pupil is small. What is most likely?

A. Left facet syndrome
B. Left facial Bell palsy
C. Left carotid dissection
D. Left C8 radiculopathy

C. Left carotid dissection Ptosis and miosis on the side of new face and eye pain is a Horner syndrome from internal carotid dissection. Do not treat the neck; send to the emergency department.

6. Which ultrasound frequency best heats tissue about 4 cm deep?

A. 3 MHz
B. 1 MHz
C. 4,000 Hz
D. 80 Hz

B. 1 MHz 1 MHz penetrates up to about 5 cm; 3 MHz stays at 1 to 2 cm. The hertz values belong to TENS and interferential current.

7. A patient with leg pain finds that repeated lumbar extension moves the pain from the calf to the low back. What does this suggest?

A. Cauda equina compression
B. A nonorganic pain pattern
C. Peripheralization, a bad sign
D. Centralization, a good sign

D. Centralization, a good sign Centralization with repeated movement predicts a good outcome and gives a directional preference for home exercise.

8. Which person meets USPSTF criteria for yearly low dose CT lung screening?

A. Age 60, 25 pack years, quit 5 years ago
B. Age 45, 30 pack years, smokes now
C. Age 70, 40 pack years, quit 20 years ago
D. Age 62, 10 pack years, smokes now

A. Age 60, 25 pack years, quit 5 years ago Criteria are age 50 to 80, at least 20 pack years, and current smoking or quitting within 15 years.

9. In the hierarchy of controls, which is the most effective way to reduce a lifting hazard?

A. Train workers in safe lifting
B. Issue back support belts
C. Eliminate the manual lift
D. Rotate workers between tasks

C. Eliminate the manual lift Elimination removes the hazard. Administrative controls (training, rotation) and PPE are less effective.

10. A worker has microcytic anemia with basophilic stippling and wrist drop. Which exposure is most likely?

A. Lead
B. Benzene
C. Mercury
D. Arsenic

A. Lead Lead causes microcytic anemia with basophilic stippling and a radial neuropathy (wrist drop). Arsenic gives Mees lines; benzene gives aplastic anemia and leukemia.

ONE PAGE

Cram sheet

Everything from chapters 11 and 12 in one place. Cover the right columns and see if you can rebuild each row.

Numbers to know

Item	Value	Note
Landmarks	C7, T3, T7, T9, L4, S2	Prominens, scapular spine, inferior angle, xiphoid, crests, PSIS
Cervical set up	Rotation 30 to 45°, never end range	ADI over 3 mm adult is unstable
Strain counterstrain	Hold about 90 seconds	Static stretch about 30 seconds
Trial of care	About 2 weeks; re-exam every 2 to 4 weeks	Two failed trials: modify or refer
MCIDs	NRS 2; ODI 10; RMDQ 2 to 3; NDI 5 to 7; PSFS 2	
Benign reactions	A third to a half of patients	Resolve in 24 to 72 hours
Ultrasound	1 MHz deep; 3 MHz superficial	0.5 to 2.5 W/cm^2
TENS	80 to 150 Hz gate; 2 to 4 Hz endorphins	Interferential about 4,000 Hz
Screening ages	Colorectal 45 to 75; mammogram 40 to 74	Lung 50 to 80 with 20 pack years
Alcohol	Standard drink 14 g; men 4 a day or 14 a week	Women 3 a day or 7 a week
Activity	150 to 300 min moderate a week	Strength 2 days; children 60 min daily
NIOSH	Constant 23 kg; LI over 1.0 risk	Over about 3.0 high risk
Noise	PEL 90 dBA; action 85 dBA	NIOSH 85 dBA with 3 dB exchange

Rules that decide questions

Topic	The rule
Listings	Gonstead names the spinous; National names the body; they turn oppositely.
Atlas	AS, laterality, then A or P of that transverse; laterality corrected L to M.
Thoracic	Thrust at end of exhalation; inhalation group top rib first, exhalation group bottom rib first.
Lumbar	Mammillary push P to A; spinous push L to M; no P to A on a slipped segment.
Pelvis	PI short leg, PSIS; AS long leg, ischium.
Extremity glide	Convex opposite, concave same: abduction inferior; knee extension anterior; dorsiflexion posterior.
Consent	PARQ, material risk; battery without consent; negligence for undisclosed risk.
Contraindications	Absolute: fracture, tumor, infection, instability, cauda equina, dissection, large AAA.
Prevention	Primary, secondary, tertiary, quaternary; USPSTF A and B recommended.
Stages of change	6 months and 30 days set the boundaries.
Exposures	Lead stippling; arsenic Mees lines; asbestos lower lobe; silica upper lobe and TB.

An independent study aid, not affiliated with or endorsed by the National Board of Chiropractic Examiners.
Dr. Garg Learning · CC BY-SA 4.0