PART II CLINICAL SCIENCES · BOARD REVIEW

Study Guide 4

This guide covers diagnostic imaging. Chapter 7 is the technology, radiation protection, positioning, normal anatomy, mensuration and special imaging. Chapter 8 is imaging diagnosis: anomalies, fractures, arthritis, tumors, metabolic and infectious disease, and what else shows on a spinal film. You will learn which factor controls which image quality, how to protect patients and staff, how to measure the spine, and how to tell infection from tumor and one arthritis from another. Work one chapter at a time, and finish each with its ten board-style items.

WHAT THIS GUIDE COVERS

- Chapter 7 · the x-ray tube, bremsstrahlung and characteristic radiation, heel effect, kVp, mAs, the 15% rule and inverse square law, photoelectric and Compton interactions, grids, digital receptors, image quality, biologic effects, units and limits, pregnancy, positioning and the oblique rule, normal values and variants, extremity, chest and abdominal films, ABCS, mensuration, MRI, CT, bone scan, ultrasound, DEXA and appropriateness.
- Chapter 8 · block vertebra, Klippel Feil, os odontoideum, upper and lower cervical fractures, the three column model, spondylolysis and Wiltse types, OA, DISH, OPLL, RA, ankylosing spondylitis and the seronegatives, gout and CPPD, bone lesion analysis, metastasis, myeloma, benign and malignant tumors, osteoporosis, osteomalacia, Paget disease, hyperparathyroidism, sickle cell, avascular necrosis, osteomyelitis, discitis, TB, Scheuermann, scoliosis, chest findings and AAA.

CHAPTER 7

Imaging Technology, Positioning, Normal Anatomy and Special Imaging

Read it in full: **Chapter 7 in the textbook**. Practice it: **Practice exam 4** and the **flashcards**.

What to know

The x-ray tube: mA heats the tungsten filament (thermionic emission); kVp drives electrons onto the tungsten anode (atomic number 74). About 99% of the energy becomes heat and 1% x-rays. **Bremsstrahlung** (braking radiation) is a continuous spectrum and most of the beam; **characteristic** radiation is discrete (about 69 keV for the tungsten K shell) and appears only above about 70 kVp. The line focus principle keeps the effective spot small; its cost is the **anode heel effect**, so put the thicker part under the cathode (feet end on an AP thoracic film). Total filtration must be at least 2.5 mm aluminum above 70 kVp; wedge and trough filters even out unequal thickness.

Exposure factors: **mAs controls quantity and density**; **kVp controls energy and contrast** (higher kVp, longer gray scale, more scatter). The **15% rule**: raising kVp 15% equals doubling mAs. The **inverse square law**: doubling distance cuts intensity to one quarter, so new mAs = old mAs × (new distance ÷ old distance)^2. Use 72 inch SID for the lateral cervical, chest and full spine. Tight collimation is the cheapest dose reduction and also cuts scatter.

In the patient, the **photoelectric effect** (rises with Z cubed, falls with energy) makes contrast and most patient dose; **Compton scatter** makes fog and most staff exposure. Grids (ratio = strip height ÷ interspace, commonly 8:1 to 12:1) absorb angled scatter; use one for parts thicker than about 10 to 12 cm or above about 60 to 70 kVp. The air gap on the 72 inch lateral cervical also cuts scatter. Digital systems rescale automatically, so watch for **dose creep**; underexposure shows as quantum mottle.

The four image qualities: density (mAs), contrast (kVp), detail (focal spot, SID, OID, motion) and distortion. Magnification factor = SID ÷ SOD. Motion is the commonest cause of unsharpness.

Biology: the Law of Bergonié and Tribondeau says rapidly dividing, undifferentiated cells are most sensitive; lymphocytes are the most sensitive cell. Deterministic effects have a threshold (erythema, cataract, sterility); stochastic effects (cancer, genetic) have none and drive **ALARA**. Units: exposure in C/kg (roentgen), absorbed dose in gray (1 Gy = 100 rad), effective dose in sievert (1 Sv = 100 rem). Background is about 3 mSv a year; a lumbar series about 1.5 mSv. Limits: occupational 50 mSv a year, declared pregnant worker 5 mSv for the pregnancy (about 0.5

mSv a month), public 1 mSv. Aprons are at least 0.5 mm lead equivalent; badges are worn at the collar outside the apron.

Pregnancy: lethality risk is greatest in the first two weeks, malformation in weeks 2 to 8, neurologic effects in weeks 8 to 15. Fetal doses under about 50 mGy are not linked to malformation, and no single spinal plain film approaches that. Ask and document the last menstrual period for women about 12 to 50; the **10 day rule** schedules elective pelvic films in the first 10 days after menses begin. Current physics guidance favors collimation over routine gonadal shielding.

Cervical positioning: the Davis series is AP lower cervical, APOM, neutral lateral, two obliques and flexion and extension. Do not do flexion and extension films in acute trauma until fracture and gross instability are excluded. **Oblique rule**: a cervical posterior (AP) oblique shows the foramina **farther** from the receptor; a lumbar posterior oblique shows the pars and facets **closest** to the receptor. The **Scotty dog**: eye = pedicle, neck = pars; a collar on the neck is spondylolysis.

Normal cervical values: ADI 3 mm or less adult (5 mm child); retropharyngeal space up to about 7 mm at C2; retrotracheal up to about 22 mm at C6 (14 mm child); sagittal canal over about 13 mm (under 10 mm absolute stenosis); Torg Pavlov ratio about 1.0 (under 0.8 suggests stenosis). Variants not to call disease: posterior ponticle, os terminale, **Mach band** (mimics a type II odontoid fracture), cervical rib (C7 transverse processes slope down), pseudosubluxation of C2 on C3 in children (Swischuk line within about 1.5 to 2 mm), limbus bone, transitional segments, paraglenoid sulcus, osteitis condensans ilii.

Extremities: two views at 90 degrees, three for joints, no grid, low kVp. Acromiohumeral distance under 7 mm suggests a cuff tear; anterior humeral line crosses the middle third of the capitellum; a visible posterior fat pad after elbow trauma means an occult fracture; Klein line should cross the femoral epiphysis; Insall Salvati ratio about 1.0; Boehler angle 20 to 40 degrees. CRITOE gives elbow ossification order at about 1, 3, 5, 7, 9 and 11 years. A fat fluid level on a cross table lateral knee means an intra-articular fracture.

Chest: PA at 72 inches, about 10 posterior ribs above the right hemidiaphragm, no rotation, spine faintly through the heart. Cardiothoracic ratio under 0.5 on a PA (an AP film magnifies the heart).

The **silhouette sign**: lost right heart border means right middle lobe; lost left heart border means lingula; lost hemidiaphragm means lower lobe. Free air is best seen on an upright chest film. KUB gas: 3, 6, 9 cm for small bowel, colon and cecum. Every lumbar film is an abdominal film: look for aortic calcification and stones.

Reading: **ABCS** (alignment, bone, cartilage, soft tissue) prevents satisfaction of search. Mensuration: McGregor (dens no more than 8 mm above in men, 10 mm in women), Chamberlain (no more than about 3 mm), McRae (dens below the line); Martin basilar angle over 150 degrees is platybasia; cervical flexion extension translation over 3.5 mm or angulation over 11 degrees is instability; Ferguson sacral base angle about 26 to 57 degrees (average 41); gravity line from L3 falls on the anterior third of the sacrum; Ullmann line; **Meyerding** grades 1 to 25%, 2 to 50%, 3 to 75%, 4 to 100%, 5 spondyloptosis; **Cobb** 10 degrees or more is scoliosis, and 5 degrees of change is needed to call progression; lumbar canal under about 15 mm is stenosis.

Special imaging: on **T1** fat is bright and water dark; on **T2** water, edema and a healthy nucleus are bright and a desiccated disc dark; **STIR** nulls fat and shows marrow edema; FLAIR nulls free water for MS plaques; gadolinium enhances scar, tumor and infection but not avascular disc (so it separates scar from recurrent disc). Disc lexicon: bulge over 25% of the circumference, protrusion base wider than the fragment, extrusion fragment wider than its base, sequestration a free fragment. Modic 1 is edema, 2 fat, 3 sclerosis. CT is best for cortical bone; the bone scan is sensitive but not specific and may be cold in myeloma; ultrasound screens for AAA. No imaging for uncomplicated spinal pain in the first 6 weeks; image for red flags, progressive deficit or failed care.

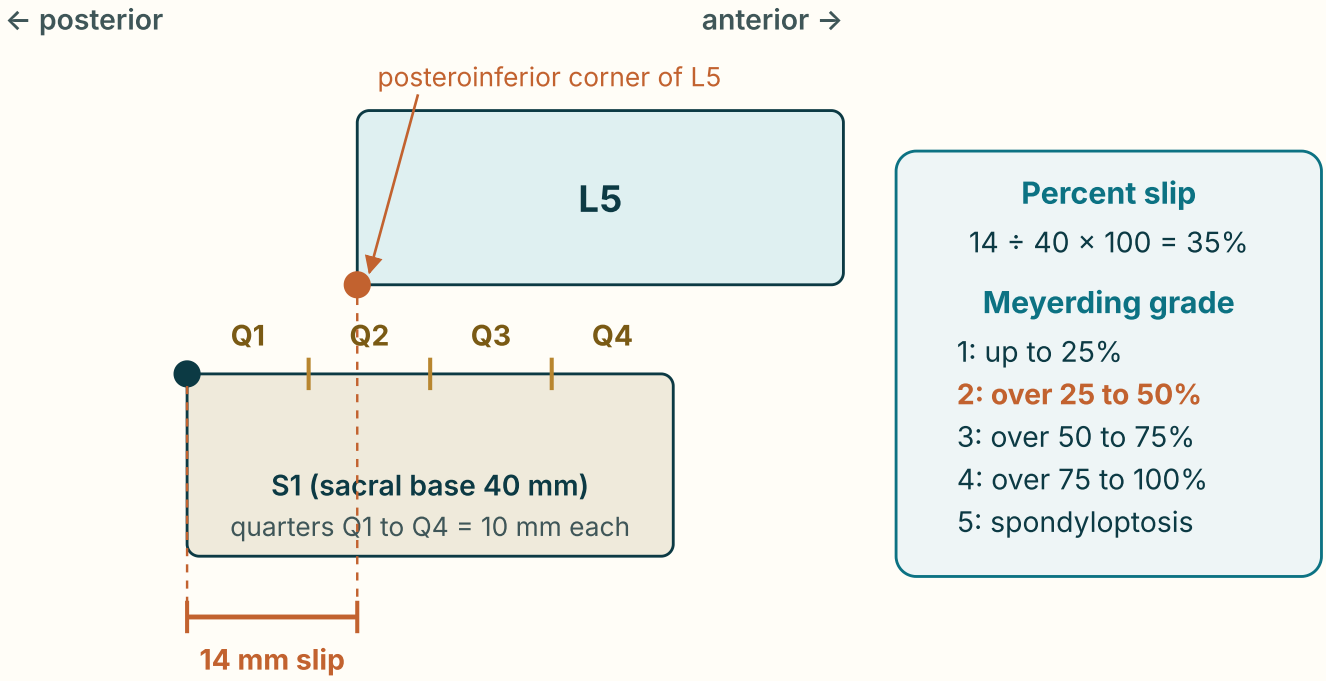

Which quarter has the corner reached? Divide the sacral base into quarters and find the posteroinferior corner of L5. Here a 14 mm slip on a 40 mm base is 35%, Meyerding grade 2.

LOCK THESE IN

- mAs controls density; kVp controls contrast; 15% kVp equals double mAs.
- Inverse square law: double the distance, one quarter the intensity, four times the mAs.
- Photoelectric makes contrast and patient dose; Compton makes fog and staff dose.
- Occupational limit 50 mSv a year; pregnant worker 5 mSv; public 1 mSv; background about 3 mSv.
- Cervical posterior oblique shows the far foramina; lumbar posterior oblique shows the near pars.
- ADI 3 mm adult, 5 mm child; retropharyngeal 7 mm at C2; retrotracheal 22 mm at C6.
- Meyerding: quarters of the sacral base. Cobb: 10 degrees is scoliosis; 5 degrees to call change.
- T1 fat bright; T2 and STIR water and edema bright; scar enhances, disc does not.

Exposure and dose numbers

Item	Value	Note
Energy to x-rays	About 1% (99% heat)	Rotating anode, heat ratings
Filtration	At least 2.5 mm Al above 70 kVp	Removes useless low energy photons
15% rule	kVp up 15% = mAs doubled	Lower dose, lower contrast
Inverse square	New mAs = old mAs × $(D_{new} \div D_{old})^2$	Also protects staff
Magnification	SID ÷ SOD	Long SID, short OID
Grid ratio	h ÷ D; commonly 8:1 to 12:1	Parts over 10 to 12 cm
Units	1 Gy = 100 rad; 1 Sv = 100 rem	Exposure in C/kg (R)
Doses	Chest 0.1; cervical 0.2; lumbar 1.5 mSv	CT abdomen and pelvis 8 to 10 mSv
Limits	50 mSv worker; 5 mSv pregnancy; 1 mSv public	Under 18 worker 5 mSv
Fetal threshold	About 50 mGy for malformation	Lumbar series: a few mGy to the fetus

Mensuration normals

Measurement	Normal	Abnormal means
ADI	3 mm or less adult; 5 mm child	Transverse ligament insufficiency
McGregor	Dens 8 mm (men) or 10 mm (women) above at most	Basilar impression
Chamberlain / McRae	About 3 mm above at most / dens below	Basilar impression
Martin basilar angle	120 to 150 degrees	Over 150: platybasia
Cervical canal	Over about 13 mm	Under 10 mm absolute stenosis
Flexion extension	Translation 3.5 mm, angulation 11 degrees at most	Ligamentous instability
Ferguson angle	About 26 to 57 degrees (average 41)	Increase: hyperlordosis, facet load
Meyerding	Grade 1 to 25%, 2 to 50%, 3 to 75%, 4 to 100%	Grade 5: spondyloptosis
Cardiothoracic ratio	Under 0.5 on a PA film	Cardiomegaly
Lumbar canal (Eisenstein)	Over about 15 mm	Stenosis

Worked cases

WORKED CASE 1 · INVERSE SQUARE LAW AND MAGNIFICATION

A lateral cervical film is made at 40 inches with 20 mAs. You move to 72 inches. The neck sits about 8 inches from the receptor (OID).

STEP 1 · SET UP THE RATIO

New mAs = $20 \times (72 \div 40)^2 = 20 \times 1.8^2 = 20 \times 3.24$.

STEP 2 · COMPUTE

New mAs = **64.8**, about 65 mAs to keep the same receptor exposure.

STEP 3 · MAGNIFICATION AT 40 INCHES

SOD = 40 − 8 = 32; MF = 40 ÷ 32 = **1.25**.

STEP 4 · MAGNIFICATION AT 72 INCHES

SOD = 72 − 8 = 64; MF = 72 ÷ 64 = **1.125**.

WHY IT MATTERS

The longer distance cuts magnification and sharpens detail across the wide object to image gap of the shoulders, and the air gap also reduces scatter.

WORKED CASE 2 · THE 15% RULE

A lumbar technique is 80 kVp at 40 mAs. You want less patient dose and can accept a little less contrast.

STEP 1 · RAISE KVP BY 15%

80 × 1.15 = **92 kVp**.

STEP 2 · HALVE THE MAS

40 ÷ 2 = **20 mAs**. Receptor exposure stays about the same.

STEP 3 · EFFECT ON THE IMAGE

Higher kVp means a longer gray scale (lower contrast) and a bit more scatter.

STEP 4 · EFFECT ON THE PATIENT

Less mAs means fewer photons absorbed, so the patient dose falls. Digital processing often tolerates the contrast change.

WORKED CASE 3 · MEYERDING GRADE BY PERCENT SLIP

On an upright lateral, the sacral base is 40 mm wide and the posteroinferior corner of L5 sits 14 mm forward of the posterosuperior corner of S1.

STEP 1 · PERCENT SLIP

14 ÷ 40 × 100 = **35%**.

STEP 2 · ASSIGN THE QUARTER

25% or less is grade 1; over 25 to 50% is grade 2. 35% is **Meyerding grade 2**.

STEP 3 · CHECK THE PARS

An L5 slip in a young person usually means an isthmic (pars) defect: look for the collar on the Scotty dog.

STEP 4 · PLAN

Flexion and extension laterals show whether it moves. A stable grade 2 slip can be treated conservatively, avoiding forceful extension at that level.

WORKED CASE 4 · OBLIQUE RULE AND THE FULL WORKUP

A right posterior oblique (right back against the receptor) is taken of the cervical spine and of the lumbar spine. Which side is shown on each?

STEP 1 · CERVICAL

A posterior oblique shows the foramina **farther** from the receptor: the **left** cervical foramina.

STEP 2 · LUMBAR

A posterior oblique shows the pars and facets **closest** to the receptor: the **right** lumbar pars.

CHECK

A right anterior oblique of the cervical spine shows the foramina closest to the receptor, the right side.

TRAPS PEOPLE FALL INTO

- **Saying kVp controls density.** mAs is the primary controller of density; kVp is the primary controller of contrast.
- **Putting the thick end under the anode.** The heel effect lowers intensity on the anode side. Thick part under the cathode.
- **Trusting a nice digital image.** Digital rescaling hides overexposure. Watch the exposure index for dose creep.
- **Reading the near cervical foramen on a posterior oblique.** Cervical posterior obliques show the far foramina; lumbar posterior obliques show the near pars.
- **Calling a Mach band an odontoid fracture.** It is an overlap line that runs beyond the bone margins. Recheck with another view.
- **Judging heart size on an AP film.** AP magnifies the heart. Use a PA at 72 inches.
- **Calling a 3 degree Cobb change progression.** Measurement error is 3 to 5 degrees. Five degrees or more is needed.
- **Ordering MRI for acute uncomplicated back pain.** No imaging in the first 6 weeks without red flags or progressive deficit.

Chapter 7 self-test · ten items

1. Which exposure factor is the primary controller of radiographic contrast?

A. Focal spot size
B. Milliampere seconds
C. Source to image distance
D. Kilovoltage peak

D. Kilovoltage peak kVp sets photon energy, penetration and the gray scale. mAs controls quantity and density.

2. A technique of 10 mAs at 40 inches is moved to 80 inches. What mAs keeps the same exposure?

A. 80 mAs
B. 40 mAs
C. 20 mAs
D. 5 mAs

B. 40 mAs Doubling distance cuts intensity to a quarter, so mAs is multiplied by $(80 \div 40)^2 = 4$: $10 \times 4 = 40$.

3. Which interaction is the main source of radiation exposure to staff standing in the room?

A. Compton scatter
B. Characteristic x-rays
C. Photoelectric effect
D. Pair production

A. Compton scatter Compton scatter sends lower energy photons in new directions, toward the operator. Photoelectric absorption deposits patient dose.

4. What is the annual effective dose limit commonly taught for an occupational radiation worker?

A. 5 mSv (0.5 rem)
B. 150 mSv (15 rem)
C. 50 mSv (5 rem)
D. 1 mSv (0.1 rem)

C. 50 mSv (5 rem) The whole body occupational limit is 50 mSv. The public limit is 1 mSv and the declared pregnant worker limit is 5 mSv for the pregnancy.

5. On a left posterior oblique (left back against the receptor) of the cervical spine, which foramina are seen best?

A. Neither side well
B. Both sides equally
C. The right foramina
D. The left foramina

C. The right foramina Cervical posterior obliques show the foramina farther from the receptor, here the right side.

6. On a lateral cervical film of an adult, the space between the anterior arch of C1 and the dens is 5 mm. What does this mean?

A. A normal adult finding
B. A normal value at any age
C. A type II odontoid fracture
D. Transverse ligament laxity

D. Transverse ligament laxity The adult ADI is 3 mm or less. 5 mm in an adult suggests transverse ligament laxity or rupture, as in rheumatoid arthritis.

7. A dark line crosses the base of the dens on the APOM and continues beyond the edges of the bone. Most likely explanation?

A. A Mach band overlap artifact
B. An os odontoideum ossicle
C. A Jefferson burst fracture
D. A type II odontoid fracture

A. A Mach band overlap artifact A Mach band is formed by overlapping edges (C1 arch, occiput, teeth) and extends past the bone margins. A fracture line stays within the bone.

8. On a PA chest film the right heart border cannot be seen and there is an opacity next to it. Which lobe is involved?

A. Right lower lobe
B. Right middle lobe
C. Left lingula
D. Right upper lobe

B. Right middle lobe Loss of the right heart border is the silhouette sign of right middle lobe disease; lower lobe disease hides the hemidiaphragm.

9. On MRI, a lesion of the vertebral marrow is dark on T1 and bright on STIR. What does this pattern indicate?

A. A desiccated disc nucleus
B. Normal fatty red marrow
C. Dense sclerotic cortical bone
D. Marrow edema or replacement

D. Marrow edema or replacement Water and edema are dark on T1 and bright on STIR, which nulls fat: acute fracture, infection or metastasis.

10. A 35 year old with 2 weeks of low back pain and no red flags or deficits asks for an MRI. What is appropriate?

A. No imaging now; reassess at 6 weeks
B. MRI with and without gadolinium
C. Full spine radiographs today
D. A lumbar CT scan and bone scan

A. No imaging now; reassess at 6 weeks Uncomplicated acute low back pain does not need imaging in the first 6 weeks; incidental findings are common and rarely change care.

CHAPTER 8

Imaging Diagnosis

Read it in full: **Chapter 8 in the textbook**. Practice it: **Practice exam 4** and the **flashcards**.

What to know

Congenital anomalies are smooth, corticated and longstanding. A **block vertebra** has a wasp waist and the height of two bodies plus a disc; acquired fusion lacks the waist. Klippel Feil is multiple cervical blocks with a short neck, low hairline and limited motion (Sprengel deformity, renal and cardiac anomalies). Hemivertebra causes congenital scoliosis; a butterfly vertebra is not a fracture. Agenesis of the C1 posterior arch has a hypertrophic anterior arch. **Os odontoideum** is a smooth round ossicle with a big rounded anterior arch of C1 and often instability: no upper cervical manipulation. A type II odontoid fracture is thin, irregular and non corticated.

Upper cervical fractures: **Jefferson** (axial load) shows lateral mass overhang on the APOM, and a combined overhang over about 7 mm (rule of Spence) means transverse ligament rupture. A posterior arch fracture of C1 is a stable hyperextension injury. **Hangman** is bilateral C2 pars or pedicle fractures with anterior slip of C2. Odontoid type I is the tip, **type II** the base (most common, worst healing), type III into the body (best healing).

Lower cervical: **clay shoveler** is a stable C7 spinous avulsion (ghost spinous on the AP). Flexion teardrop is three column, highly unstable, with anterior cord syndrome. Extension teardrop is a small C2 corner avulsion in older patients. Unilateral facet dislocation slips about 25% with a bow tie; bilateral about 50% or more and is highly unstable.

Denis three columns: injury to two or more, especially the **middle column**, is unstable. Compression (wedge) is anterior column only, stable unless over about 50% height loss. **Burst** fractures add the middle column, retropulse bone and widen the interpediculate distance. **Chance** (lap belt) fractures split all three columns horizontally at T12 to L2, with abdominal injury in about half. Transverse process fractures (L2, L3) call for a check for hematuria.

Spondylolysis is a pars stress fracture, about 90% at L5, in young extension athletes: a collar on the Scotty dog; CT shows the defect best and SPECT or STIR shows early stress reaction. Wiltse types: I dysplastic, II isthmic (most common in the young, L5 on S1), III degenerative (women over 40 to 50, **L4 on L5**, pars intact, rarely beyond grade 1), IV traumatic, V pathologic, VI iatrogenic. A severe L5 slip gives the inverted Napoleon hat sign.

Arthritis on film: **OA** has non uniform narrowing, sclerosis, osteophytes and cysts, no erosions or osteoporosis. Degenerative disc disease adds the vacuum phenomenon (essentially excludes infection at that level), traction spurs (instability) and uncovertebral arthrosis narrowing the cervical foramina, most at C5 to C6 and C6 to C7. **DISH** is flowing anterior ossification over at least 4 contiguous bodies with preserved discs and no facet or SI ankylosis, right sided in the thoracic spine. OPLL causes cervical stenosis, most often in people of East Asian descent. **RA** has uniform narrowing, periarticular osteoporosis, marginal erosions, ulnar styloid erosion, and cervical atlantoaxial instability (ADI over 3 mm), dens erosion, cranial settling and stair step subluxations.

Ankylosing spondylitis starts with bilateral symmetric sacroiliitis (iliac side first), then Romanus lesions and shiny corners, squared bodies, **marginal syndesmophytes** and bamboo spine with the trolley track sign. The fused spine fractures easily (carrot stick fracture). Enteropathic arthritis looks the same. Psoriatic and reactive arthritis give asymmetric sacroiliitis and bulky **nonmarginal** syndesmophytes; psoriatic adds DIP pencil in cup and fluffy periostitis without osteoporosis; reactive favors the feet. **Gout**: punched out erosions with overhanging edges (Martel

sign), joint space kept until late. **CPPD**: chondrocalcinosis of menisci, TFCC and symphysis, with OA in odd joints (patellofemoral, radiocarpal, second and third MCP hooks). Calcific tendinitis favors the supraspinatus. Charcot joints show the six Ds.

Bone lesion analysis: age, number, location, margin, matrix, periosteal reaction and cortex. Over 40, think **metastasis** and **myeloma**. Narrow sclerotic margins and solid periosteal bone are slow; moth eaten or permeative destruction, onion skin, sunburst and the Codman triangle are aggressive. Metastases favor red marrow via Batson plexus; the five primaries are breast, lung, thyroid, kidney and prostate (prostate blastic in men). The classic sign is the **missing pedicle** (winking owl), and metastasis **spares the disc**. Cancellous loss is not seen until 30 to 50% is gone. Myeloma gives punched out lesions without sclerotic rims, tends to spare pedicles early and is often cold on bone scan.

Benign spinal tumors: **hemangioma** is the commonest (about 10% of adults), with vertical striations (corduroy), polka dots on CT, bright on T1 and T2; not by itself a contraindication to adjusting. **Osteoid osteoma** (10 to 25) has a nidus under 1.5 cm, night pain relieved by aspirin, posterior element location and painful scoliosis concave toward the lesion. Osteoblastoma is larger. Aneurysmal bone cyst is expansile with fluid levels. Eosinophilic granuloma causes vertebra plana in a child. Elsewhere: giant cell tumor (20 to 40, epiphyseal to the joint surface, soap bubble), osteosarcoma (10 to 25, knee metaphysis, cloud like osteoid, sunburst, Codman), Ewing sarcoma (5 to 20, diaphysis, permeative, onion skin, fever mimics infection), chondrosarcoma (40 to 60, rings and arcs), chordoma (sacrum and clivus). Do not touch lesions: bone island, nonossifying fibroma, simple bone cyst (fallen fragment), fibrous dysplasia, enchondroma, osteochondroma, myositis ossificans (matures from the periphery inward).

Metabolic: **osteoporosis** shows penciled cortices, prominent vertical trabeculae, wedge and codfish vertebrae; steroid osteoporosis adds marginal endplate condensation. **Osteomalacia** shows smudged trabeculae and Looser zones on the compressive side (medial femoral neck, rami, scapula). **Paget disease** (over 55, pelvis most) shows enlargement, cortical thickening and coarse trabeculae: picture frame or enlarged ivory vertebra, brim sign, saber shin, very high ALP, rare sarcoma. **Hyperparathyroidism**: subperiosteal resorption on the radial middle phalanges of the second and third fingers, salt and pepper skull, brown tumors; renal osteodystrophy gives the

rugger jersey spine. Sickle cell gives H shaped vertebrae; avascular necrosis gives the crescent sign, with MRI most sensitive.

Infection: hematogenous osteomyelitis seeds the metaphysis in children (S. aureus) and radiographs lag 10 to 14 days; sequestrum, involucrum and cloaca mark chronic infection; Brodie abscess is subacute. In **pyogenic discitis** the earliest plain film sign is **disc space loss**, then loss of the endplate white line and erosion on both sides; MRI with gadolinium is the test of choice. **Tuberculous spondylitis** spreads under the ALL, scallops the anterior bodies, spares the disc early, forms cold psoas abscesses and a gibbus. **Infection crosses the disc; tumor respects it.**

Miscellaneous: Scheuermann disease is 5 degrees or more of wedging in 3 contiguous vertebrae with endplate irregularity and Schmorl nodes. Adolescent idiopathic scoliosis is usually right thoracic; observe under about 25 degrees, brace about 25 to 40 in a growing child, refer over 45 to 50; a left thoracic or painful curve needs MRI. Chest: pneumothorax is a pleural line with no markings beyond; effusion blunts the costophrenic angle (about 200 mL on PA, 50 to 75 mL on lateral); atelectasis pulls structures toward it; Pancoast tumor gives C8 to T1 pain and Horner syndrome. **AAA** on a lateral lumbar film is curvilinear calcification 3 cm or more apart (outer wall to outer wall); a normal film does not exclude it; repair at about 5.5 cm (5.0 in women). Phleboliths have lucent centers; uric acid stones are radiolucent.

Pyogenic discitis

anterior → right

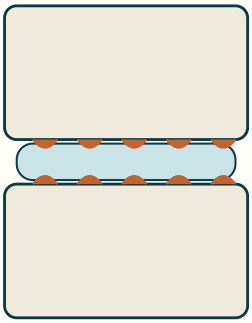

Disc narrows first, then both endplates erode: crosses the disc

Metastasis

anterior → right

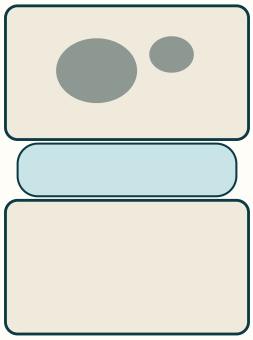

Disc preserved; body destroyed; pedicle lost on the AP (winking owl)

Tuberculosis

anterior → right

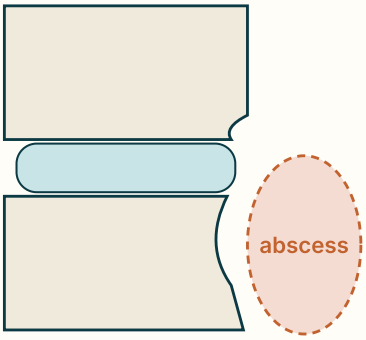

Spreads under the ALL: anterior scalloping, disc spared early, gibbus

Infection crosses the disc; tumor respects it.

Look at the disc first. Pyogenic infection narrows the disc and erodes both endplates; metastasis destroys bone but spares the disc; tuberculosis scallops the front of the bodies and spares the disc until late.

LOCK THESE IN

- Block vertebra: wasp waist. Os odontoideum: smooth ossicle, big rounded C1 anterior arch, often unstable.
- Jefferson overhang over 7 mm total means transverse ligament rupture. Odontoid type II: worst healing.
- Burst widens the interpediculate distance; Chance splits all three columns at T12 to L2.
- Isthmic slip: L5 with a pars defect. Degenerative slip: L4 with an intact pars.
- AS: bilateral symmetric sacroiliitis and marginal syndesmophytes. Psoriatic and reactive: nonmarginal.
- Metastasis: missing pedicle, disc spared. Myeloma: punched out lesions, cold bone scan.
- Infection crosses the disc; disc space loss is the earliest plain film sign of discitis.
- AAA: 3 cm or more on the lateral lumbar; a normal film does not exclude it.

Spinal fractures and stability

Fracture	Hallmark	Stability
Jefferson (C1 burst)	Lateral mass overhang on APOM; over 7 mm total	Unstable if transverse ligament torn
Hangman (C2)	Bilateral pars or pedicle fracture, C2 slips forward	Unstable; canal widens
Odontoid I / II / III	Tip / base / into body	Type II worst healing
Clay shoveler	C7 spinous avulsion, ghost spinous	Stable
Flexion teardrop	Anteroinferior fragment, body pushed back	Highly unstable; anterior cord
Compression (wedge)	Anterior height loss	Stable unless over about 50%
Burst	Retropulsion, wide interpediculate distance	Unstable (anterior and middle)
Chance	Horizontal split T12 to L2; visceral injury	Unstable (all three)

Destructive spinal lesions compared

Feature	Pyogenic discitis	Tuberculosis	Metastasis
Disc	Narrowed early, destroyed	Spared early, lost late	Preserved
Bone	Endplates eroded on both sides	Anterior scalloping	Body and pedicle destroyed
Levels	One disc, two bodies	Several, skip lesions	Scattered
Soft tissue	Moderate swelling	Large calcified psoas abscess	Possible mass
Deformity	Mild	Gibbus	Collapse
Tempo	Weeks; fever, high CRP	Months; night sweats	Cancer history

Worked cases

WORKED CASE 1 · THE RULE OF SPENCE

After a diving injury, the APOM shows the left C1 lateral mass overhanging C2 by 4 mm and the right by 4 mm.

STEP 1 · ADD THE OVERHANG

4 + 4 = **8 mm** combined lateral offset.

STEP 2 · APPLY THE RULE

Over about 7 mm combined implies **transverse ligament rupture**.

STEP 3 · NAME THE INJURY

Axial load with bilateral lateral mass offset is a **Jefferson** burst fracture of C1. CT confirms the ring fractures front and back.

STEP 4 · ACT

Unstable: immobilize and send to the emergency department. No manipulation.

WORKED CASE 2 · INFECTION OR TUMOR

A 58 year old diabetic on dialysis has constant lumbar pain and a fever. The L3 to L4 disc space has narrowed since films 4 weeks ago, and the endplates above and below it have lost their white cortical line.

STEP 1 · LOOK AT THE DISC

The disc is narrowed and the destruction involves **both sides** of it. Infection crosses the disc; tumor respects it.

STEP 2 · ORDER OF CHANGE

Disc space loss is the earliest plain film sign of discitis, followed by loss of the endplate white line.

STEP 3 · COMPARE

Metastasis would destroy a body or pedicle and spare the disc; TB would scallop several anterior bodies and spare the disc early.

STEP 4 · CONCLUDE

Pyogenic discitis and vertebral osteomyelitis. Refer urgently for MRI with gadolinium, blood cultures and treatment.

WORKED CASE 3 · READING A LATERAL LUMBAR FOR THE AORTA

On a lateral lumbar film of a 70 year old former smoker, curvilinear calcification lies in front of L2 to L4. At L3 the anterior and posterior walls are 3.8 cm apart, outer wall to outer wall.

STEP 1 · APPLY THE DEFINITION

An abdominal aorta of 3 cm or more is an **aneurysm**; 3.8 cm qualifies.

STEP 2 · CONFIRM

Ultrasound is the diagnostic test. Many aneurysms are not calcified, so a normal film never excludes one.

STEP 3 · URGENCY

Repair is usually considered at about 5.5 cm (about 5.0 in women) or with rapid growth. An asymptomatic 3.8 cm aneurysm gets routine but definite referral.

STEP 4 · TREATMENT

Avoid forceful lumbar and deep abdominal procedures. Any new severe pain, hypotension or syncope means an ambulance.

WORKED CASE 4 · THE OLDER ADULT WITH A DESTRUCTIVE LESION

A 64 year old former smoker has constant thoracic pain worse at night. The AP film shows the left pedicle of T8 is missing; the discs are normal.

STEP 1 · AGE AND NUMBER

Over 40, a destructive spinal lesion is metastasis or myeloma until proven otherwise.

STEP 2 · THE SIGN

A missing pedicle (winking owl) is the classic sign of **metastasis**; myeloma tends to spare pedicles early.

STEP 3 · THE DISC

Preserved discs fit tumor, not infection.

STEP 4 · ACT

No manipulation. Arrange urgent MRI and referral, and screen for cord compression (gait change, sensory level, bladder change), which is an emergency.

TRAPS PEOPLE FALL INTO

- **Calling a block vertebra a surgical fusion.** The congenital block has a wasp waist at the fused disc. Acquired fusion does not.
- **Mistaking os odontoideum for a fresh fracture or for nothing.** It is smooth and corticated with a big C1 arch, and often unstable. No upper cervical thrust.
- **Calling every L4 slip isthmic.** L4 slips in older women are usually degenerative with an intact pars. Isthmic slips are usually L5.

- **Mixing marginal and nonmarginal syndesmophytes.** Thin vertical marginal ones mean AS or enteropathic; bulky nonmarginal ones mean psoriatic or reactive.
- **Expecting a hot bone scan in myeloma.** Myeloma is often cold. Use skeletal survey, MRI or whole body CT.
- **Biopsying a do not touch lesion.** Bone island, nonossifying fibroma and myositis ossificans are diagnosed on the image. Healing tissue can look malignant under the microscope.
- **Expecting early bone destruction on films in osteomyelitis.** Films lag 10 to 14 days. MRI and bone scan detect it earlier.
- **Clearing an AAA because the film shows no calcification.** Many aneurysms are not calcified. Ultrasound decides.

Chapter 8 self-test · ten items

1. Two cervical bodies are fused, with a total height equal to two bodies plus a disc and a concave anterior waist at the fused level. Most likely cause?

A. Surgical anterior fusion
B. Juvenile arthritis fusion
C. Healed pyogenic discitis
D. Congenital block vertebra

D. Congenital block vertebra The wasp waist marks a congenital failure of segmentation. Acquired fusions lack it.

2. After a fall onto the head, the lateral film shows bilateral fractures through the C2 pars with anterior slip of the C2 body. What is this injury?

A. Hangman fracture
B. Type III odontoid
C. Jefferson fracture
D. Clay shoveler fracture

A. Hangman fracture Traumatic spondylolisthesis of C2 through the pars or pedicles is the hangman fracture.

3. Which odontoid fracture has the highest rate of nonunion?

A. Type I, at the tip
B. Type II, at the base
C. All heal equally well
D. Type III, into the body

B. Type II, at the base The base of the dens is poorly perfused, so type II fractures have the worst healing. Type III, in cancellous bone, heals best.

4. After a fall from a ladder onto the feet, the AP lumbar film shows abrupt widening of the interpediculate distance at L1. What is the fracture?

A. A process avulsion
B. A wedge compression
C. A burst fracture
D. A Chance fracture

C. A burst fracture Axial load with widened interpediculate distance means a burst fracture involving the anterior and middle columns, which is unstable.

5. A 62 year old woman has a grade 1 anterolisthesis of L4 on L5 with intact pars and facet arthrosis. Which Wiltse type is it?

A. Pathologic (type V) slip
B. Isthmic (type II)
C. Dysplastic (type I)
D. Degenerative (type III)

D. Degenerative (type III) Degenerative slips favor L4 in women over 40 to 50, with an intact pars, and rarely exceed grade 1.

6. Flowing anterior ossification spans five thoracic levels on the right, disc heights are preserved and the SI joints are normal. Diagnosis?

A. Ankylosing spondylitis
B. Degenerative disc disease
C. DISH (Forestier disease)
D. Psoriatic spondylitis

C. DISH (Forestier disease) Flowing ossification over 4 or more contiguous levels with preserved discs and normal SI and facet joints is DISH.

7. A 26 year old man has bilateral symmetric erosions on the iliac side of both SI joints and thin vertical marginal syndesmophytes at the thoracolumbar junction. Most likely?

A. Ankylosing spondylitis
B. Osteitis condensans ilii
C. Reactive arthritis
D. Psoriatic arthritis

A. Ankylosing spondylitis Bilateral symmetric sacroiliitis with marginal syndesmophytes is AS. Psoriatic and reactive disease give asymmetric sacroiliitis and nonmarginal syndesmophytes.

8. A 15 year old has night pain in the tibia relieved by aspirin. Films show a small lucent nidus surrounded by dense sclerosis. Diagnosis?

A. Brodie abscess
B. Osteoid osteoma
C. Ewing sarcoma
D. Osteosarcoma

B. Osteoid osteoma A nidus under 1.5 cm with reactive sclerosis and night pain relieved by aspirin is osteoid osteoma.

9. A vertebral body shows coarse vertical striations, is not expanded and is bright on both T1 and T2 MRI. What is it?

A. Osteoporotic fracture
B. Vertebral hemangioma
C. Paget disease
D. Blastic metastasis

B. Vertebral hemangioma Vertical striations (corduroy) with fat signal on T1 and T2 is a hemangioma, the commonest benign spinal tumor.

10. Which finding best separates tuberculous spondylitis from pyogenic discitis early in the disease?

A. Severe pain and constant fever
B. Narrowing of one disc only
C. Erosion of both endplates
D. Relative sparing of the disc

D. Relative sparing of the disc TB spreads under the anterior longitudinal ligament and spares the disc early. Pyogenic infection narrows the disc first.

ONE PAGE

Cram sheet

Everything from chapters 7 and 8 in one place. Cover the right columns and see if you can rebuild each row.

Numbers to know

Item	Value	Note
Tube	99% heat; tungsten Z 74; K shell about 69 keV	Thick part under the cathode
Factors	15% kVp = double mAs; inverse square	72 inch lateral cervical, chest, full spine
Limits	Worker 50; pregnancy 5; public 1 mSv	Background about 3 mSv a year
Pregnancy	Fetal threshold about 50 mGy; 10 day rule	Ask about LMP at about 12 to 50
Cervical	ADI 3 adult, 5 child; RPS 7 mm C2; RTS 22 mm C6	Canal over 13 mm; Torg under 0.8
Instability	Translation over 3.5 mm; angulation over 11°	Flexion extension films
Meyerding	25, 50, 75, 100%; 5 is spondyloptosis	Percent slip for follow up
Cobb	10° scoliosis; 5° change for progression	Brace about 25 to 40°
Chest	CTR under 0.5 on PA; 10 posterior ribs	Effusion: about 200 mL to blunt PA angle
Jefferson	Combined overhang over 7 mm	Transverse ligament rupture
Scheuermann	5° wedging in 3 vertebrae	Kyphosis over about 40 to 45°
AAA	3 cm or more; repair about 5.5 cm	5.0 cm in women

Rules that decide questions

Topic	The rule
Image quality	mAs density; kVp contrast; focal spot, distance and motion detail.
Interactions	Photoelectric: contrast and patient dose. Compton: fog and staff dose.
Obliques	Cervical posterior oblique: far foramina. Lumbar posterior oblique: near pars.
MRI	T1 fat bright; T2 and STIR fluid bright; scar enhances, disc does not.
Imaging timing	No imaging in the first 6 weeks without red flags or deficit.
Fracture stability	Two or more columns, especially the middle column, is unstable.
Slips	Isthmic L5 pars defect; degenerative L4 intact pars.
Arthritis	OA non uniform; RA uniform with osteoporosis; gout overhanging edges; CPPD chondrocalcinosis.
Syndesmophytes	Marginal: AS and enteropathic. Nonmarginal: psoriatic and reactive.
Tumor	Over 40: metastasis (missing pedicle) or myeloma (cold scan).
Infection	Crosses the disc; disc space loss first. TB spares the disc early, forms gibbus.

An independent study aid, not affiliated with or endorsed by the National Board of Chiropractic Examiners.
Dr. Garg Learning · CC BY-SA 4.0