PART II CLINICAL SCIENCES · BOARD REVIEW

Study Guide 3

This guide covers the extremity orthopedic examination and musculoskeletal diagnosis in Chapter 5 and the neurologic examination and diagnosis in Chapter 6. You will learn which test isolates which structure, how to read a joint pattern, which fractures are easy to miss, and how to localize a lesion from cranial nerves, strength, sensation and reflexes. Work one chapter at a time. Read the "what to know" paragraphs, study the diagram and tables, then try each worked case with the steps covered. Finish each chapter with its ten board-style items.

WHAT THIS GUIDE COVERS

- Chapter 5 · the shoulder (impingement, cuff, instability, biceps, AC joint, frozen shoulder), elbow, wrist and hand entrapments and fractures, hip conditions by age, knee ligaments and menisci, patellofemoral tests, ankle sprains and the Ottawa rules, sprain and strain grades, fractures, compartment syndrome, arthritis patterns, myofascial pain and fibromyalgia.
- Chapter 6 · mental status and GCS, the twelve cranial nerves, pupils, vertigo, the cerebellum and Romberg, tone and strength grading, myotomes, UMN and LMN signs, sensory pathways, dermatomes and nerve fields, cord syndromes, reflexes, radiculopathy by level, myelopathy, cauda equina, entrapments, dissection, stroke, MS and ALS.

CHAPTER 5

Orthopedic Examination of the Extremities and Musculoskeletal Diagnosis

Read it in full: **Chapter 5 in the textbook**. Practice it: **Practice exam 3** and the **flashcards**.

What to know

Organize every extremity exam by structure, and always compare active motion, passive motion and resisted isometric testing. Painful active motion, full painless passive motion and painful resisted motion point to a **contractile** lesion (muscle or tendon). Equal loss of active and passive

motion in the capsular pattern points to the **capsule**. Weakness with full passive range suggests a tear or a nerve lesion.

Shoulder: normal flexion and abduction about 180°, external rotation 90°; scapulohumeral rhythm about 2 to 1. The GH capsular pattern is external rotation most limited, then abduction, then internal rotation. **Impingement** of the supraspinatus and bursa under the coracoacromial arch is the commonest shoulder pain; Neer stages run from edema (under 25) to fibrosis (25 to 40) to spurs and tears (over 40). The **painful arc** from about 60 to 120° means subacromial impingement; pain only at 170 to 180° means the AC joint. Neer and Hawkins are sensitive but not specific (Hawkins is the most sensitive).

Rotator cuff strength tests find tears: empty can (supraspinatus; weakness favors tear), drop arm (full thickness tear), external rotation lag (infraspinatus), Hornblower (teres minor), lift off and belly press (subscapularis). Pain with good strength suggests tendinopathy; true weakness suggests a tear. About 95% of GH dislocations are anterior, injuring the axillary nerve (lateral deltoid skin); Hill Sachs is a posterolateral head impaction and Bankart an anteroinferior labral avulsion. Posterior dislocation follows seizure or electrocution (lightbulb sign). Apprehension and relocation test anterior instability; the sulcus sign tests inferior instability; Yergason and Speed test the biceps; O'Brien finds SLAP lesions. Rockwood types I to VI grade AC separations; IV to VI are surgical. A posterior SC dislocation with dyspnea or dysphagia is an emergency. **Adhesive capsulitis** (40 to 60, women, diabetes, thyroid disease) loses active and passive motion with external rotation worst and normal films.

Elbow: carrying angle 5 to 15°, greater in women. **Lateral epicondylopathy** is tendinosis of the ECRB origin (Cozen resisted wrist extension, Mill passive stretch), peaking at 35 to 55; most patients do not play tennis. Distinguish radial tunnel syndrome (tender 4 to 5 cm distal) and C6 radiculopathy. Valgus stress at 20 to 30° tests the UCL. Tinel at the cubital tunnel and the elbow flexion test find ulnar neuropathy.

Wrist and hand: **carpal tunnel syndrome** gives night numbness of the lateral three and a half digits eased by shaking, then thenar atrophy; thenar skin is spared because the palmar cutaneous branch passes over the ligament. Tinel, Phalen, reverse Phalen and Durkan (among the most sensitive) find it. Froment and Wartenberg signs mean ulnar palsy; a Guyon canal lesion spares

dorsal ulnar sensation. Ulnar paradox: an elbow lesion gives a milder claw. Radial nerve: spiral groove gives wrist drop with triceps spared; posterior interosseous gives finger drop without sensory loss. Finkelstein finds de Quervain; Allen tests the palmar arch (color back in about 5 to 7 seconds). **Scaphoid fracture**: snuffbox tenderness, early films may be normal, immobilize and re-image in 10 to 14 days; waist and proximal pole fractures risk avascular necrosis. Colles is dorsal (dinner fork), Smith volar, boxer's the fifth metacarpal neck, Bennett the intra-articular first metacarpal base.

Hip: intra-articular disease shows first as lost internal rotation and groin pain. Trendelenburg tests the stance side gluteus medius; Thomas, Ely and Ober find tight iliopsoas, rectus femoris and IT band; FABERE groin pain means hip, posterior pain means SI; FADIR finds femoroacetabular impingement. By age: DDH in newborns (Ortolani reduces, Barlow dislocates), septic hip in febrile children (emergency), **Perthes** in boys 4 to 8, **SCFE** in obese adolescent boys 10 to 16 with obligatory external rotation on flexion and a Klein line that misses the epiphysis (frog leg lateral most sensitive; no weight bearing, urgent referral). Any limping child with knee pain needs a hip exam.

Knee: **Lachman** (20 to 30°) is the most sensitive ACL test; the pivot shift is the most specific. Posterior sag and posterior drawer find the PCL (dashboard injury). Valgus stress at 30° isolates the MCL; at 0° it adds the capsule and possibly a cruciate. McMurray (external rotation tests medial, internal rotation tests lateral) and Apley compression find meniscal tears; Apley distraction pain points to ligament. The unhappy triad is ACL, MCL and medial meniscus. A Segond fracture nearly proves an ACL tear. A locked knee needs prompt referral; a knee dislocation threatens the popliteal artery. Q angle about 13° in men and 18° in women. Ottawa knee rules: age 55+, isolated patellar tenderness, fibular head tenderness, cannot flex to 90°, or cannot bear weight for four steps.

Ankle and foot: an inversion sprain in plantarflexion tears the ATFL, then the CFL, then the PTFL. Anterior drawer tests the ATFL, talar tilt the CFL, the squeeze test the syndesmosis. **Thompson** (no plantarflexion on calf squeeze) finds a complete Achilles rupture even when the patient can still plantarflex weakly. First step heel pain is plantar fasciopathy (windlass test); a third web space Mulder click is Morton neuroma. The **Ottawa ankle rules**: tenderness at the

posterior edge or tip of the distal 6 cm of either malleolus, the navicular or the fifth metatarsal base, or inability to bear weight for four steps both immediately and in the office. A Jones fracture (1.5 to 2 cm distal to the tuberosity) has a high nonunion rate; a Maisonneuve fracture means palpating the proximal fibula.

Grading: a sprain is a ligament, a strain a muscle or tendon. Grade I is microscopic tearing with a firm end point; grade II a partial tear with some laxity but an end point; grade III a complete rupture with a soft or absent end point, and sometimes less pain than grade II. Chronic tendon pain is mostly degenerative tendinosis. Salter Harris (SALTR) grades growth plate injuries; type II is most common, type V has the worst prognosis. **Compartment syndrome** shows pain out of proportion and pain on passive stretch first; pulselessness is late.

Arthritis by pattern: **OA** favors DIP (Heberden), PIP (Bouchard) and the first CMC, with stiffness under 30 minutes and normal labs. **RA** favors symmetric MCP, PIP and wrists and spares the DIP, with stiffness over an hour, RF and anti-CCP, and atlantoaxial instability (ADI over 3 mm in an adult; no high velocity upper cervical thrust in active RA). **Seronegative spondyloarthropathies** share HLA-B27, enthesitis, sacroiliitis and uveitis; psoriatic arthritis favors the DIP with dactylitis and pencil in cup. Gout crystals are needle shaped and negatively birefringent; CPPD crystals are rhomboid and positively birefringent. A hot single joint is septic until aspiration proves otherwise.

Myofascial pain is regional, with trigger points in a taut band, a twitch response and set referral patterns (gluteus minimus mimics L5). Fibromyalgia is widespread central pain with fatigue and poor sleep and normal labs; current criteria are WPI 7 or more with SSS 5 or more, or WPI 4 to 6 with SSS 9 or more, generalized pain in 4 of 5 regions for 3 months. Polymyalgia rheumatica (over 50, girdle stiffness, high ESR) coexists with giant cell arteritis in 15 to 20%.

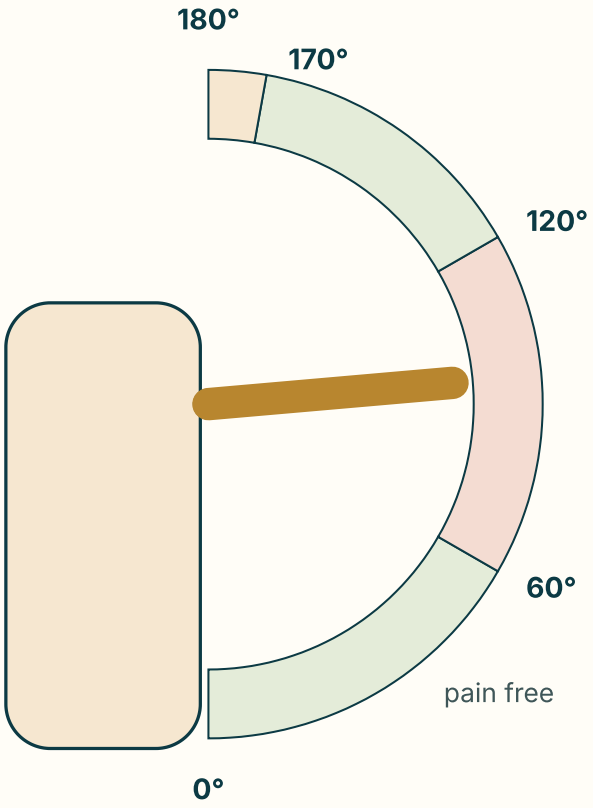

60 to 120°: painful arc
supraspinatus or bursa squeezed under the arch: subacromial impingement

170 to 180°: end range
pain on top of shoulder: acromioclavicular joint

Then test strength
pain, good strength: tendinopathy; weakness or drop arm: cuff tear

Right shoulder from the front: side (0°) to overhead (180°)

Where in the arc it hurts tells you which structure is pinched. Mid range pain that eases above 120° is subacromial impingement; pain only at the top of the arc is the AC joint. Strength testing then separates tendinopathy from a tear.

LOCK THESE IN

- Painful arc 60 to 120° is impingement; 170 to 180° is the AC joint.
- Pain with good strength is tendinopathy; weakness, drop arm or ER lag is a tear.
- Adhesive capsulitis loses active and passive motion, external rotation worst, with normal films.
- Carpal tunnel spares thenar skin; Froment and Wartenberg mean ulnar palsy.
- Lachman is the most sensitive ACL test, pivot shift the most specific; sag sign finds the PCL.
- Ottawa ankle: posterior edge or tip of either malleolus, navicular, fifth metatarsal base, or four steps.
- DIP means OA or psoriatic arthritis, never RA. Gout negative, CPPD positive birefringence.
- Compartment syndrome: pain out of proportion and on passive stretch come first.

Extremity tests by structure

Test	Positive finding	Suggests
Neer, Hawkins	Pain under the acromion	Subacromial impingement
Empty can / drop arm	Weakness / arm drops	Supraspinatus tear / full thickness tear
Lift off, belly press	Cannot lift hand off back / elbow drops back	Subscapularis tear
Apprehension, relocation	Fear relieved by posterior force	Anterior instability
Yergason, Speed / O'Brien	Bicipital groove pain / deep pain thumb down	Biceps tendinopathy / SLAP lesion
Cozen, Mill	Lateral epicondyle pain	Lateral epicondylopathy (ECRB)
Tinel, Phalen, Durkan	Median paresthesia	Carpal tunnel syndrome
Finkelstein	Radial styloid pain	de Quervain tenosynovitis
Lachman / pivot shift	Anterior translation / clunk	ACL tear (sensitive / specific)
Posterior sag	Tibia sags back	PCL tear
McMurray, Apley compression	Painful click; pain	Meniscal tear
Anterior drawer (ankle) / talar tilt	Talus translates / tilts	ATFL / CFL tear
Thompson	No plantarflexion	Complete Achilles rupture
Mulder	Painful click	Morton neuroma

Arthritis patterns

Feature	Osteoarthritis	Rheumatoid	Spondyloarthropathy	Gout / CPPD
Joints	DIP, PIP, first CMC, hips, knees	Symmetric MCP, PIP, wrist; C1 C2	SI joints, spine, entheses	First MTP / knee, wrist
Stiffness	Under 30 min	Over 1 hour	Over 1 hour, better with exercise	Acute attacks
Labs	Normal	RF, anti-CCP	HLA-B27, RF negative	Negative / positive birefringence
Film	Osteophytes, asymmetric narrowing	Erosions, periarticular osteopenia	Sacroiliitis, syndesmophytes	Rat bite erosions / chondrocalcinosis

Worked cases

WORKED CASE 1 · TENDINOPATHY OR TEAR

A 58 year old painter has lateral shoulder pain. Active abduction hurts from about 70 to 115° then eases. Passive range is full. Hawkins is positive. On the empty can test he cannot hold the arm against light pressure, and when lowered from 90° the arm drops.

STEP 1 · READ THE ARC

Pain from about 60 to 120° that eases above is a **painful arc** of subacromial impingement.

STEP 2 · READ PASSIVE RANGE

Full passive range rules out a capsular problem such as adhesive capsulitis.

STEP 3 · READ STRENGTH

Real weakness on empty can and a positive drop arm point past tendinopathy to a **full thickness supraspinatus tear**.

STEP 4 · AGE FITS

Neer stage III, bone spurs and tears, is typical over 40.

STEP 5 · ACT

Refer for imaging and orthopedic opinion, promptly if the tear followed trauma.

WORKED CASE 2 · THE OTTAWA ANKLE RULES

After rolling her ankle, a 34 year old walked four steps in the clinic with a limp. She is most tender over the front of the lateral ankle below the fibula. The posterior edge of both malleoli, the navicular and the fifth metatarsal base are not tender.

STEP 1 · MALLEOLAR ZONE

No tenderness at the posterior edge or tip of the distal 6 cm of either malleolus.

STEP 2 · WEIGHT BEARING

She took four steps (limping counts as bearing weight).

STEP 3 · MIDFOOT ZONE

Navicular and fifth metatarsal base are not tender.

STEP 4 · DECIDE

No Ottawa criterion is met, so **no films are needed**. Tenderness over the ATFL is typical of a sprain and is not an Ottawa site.

STEP 5 · TEST THE LIGAMENT

An anterior drawer in about 20° of plantarflexion grades the ATFL injury.

WORKED CASE 3 · WHICH ARTHRITIS

A 44 year old woman has 3 months of swollen MCP joints and wrists on both sides, with 90 minutes of morning stiffness. Her DIP joints are normal. Anti-CCP is positive.

STEP 1 · JOINT PATTERN

Symmetric MCP and wrist with DIP sparing fits **rheumatoid arthritis**; OA and psoriatic arthritis favor the DIP.

STEP 2 · STIFFNESS

Over an hour means inflammatory, not mechanical.

STEP 3 · LAB

Anti-CCP is about 95% specific for RA.

STEP 4 · NECK

Before any cervical manipulation, obtain flexion and extension films for atlantoaxial instability. An ADI over 3 mm in an adult is abnormal, and high velocity upper cervical thrust is contraindicated in active RA.

WORKED CASE 4 · FIBROMYALGIA CRITERIA

A patient has widespread pain for 8 months with a widespread pain index of 5, a symptom severity score of 10, and pain in 4 of 5 body regions. Labs are normal.

STEP 1 · FIRST PATHWAY

WPI 7 or more with SSS 5 or more: not met, because WPI is 5.

STEP 2 · SECOND PATHWAY

WPI 4 to 6 with SSS 9 or more: WPI 5 and SSS 10 meet it.

STEP 3 · OTHER REQUIREMENTS

Generalized pain in at least 4 of 5 regions and duration of at least 3 months: both met.

STEP 4 · CONCLUDE

Criteria for **fibromyalgia** are met. Screen for mimics first (polymyalgia rheumatica, myositis, hypothyroidism) and favor graded aerobic exercise.

TRAPS PEOPLE FALL INTO

- **Trusting Neer and Hawkins to find a tear.** They are sensitive for a painful subacromial space, not specific. Strength tests find tears.
- **Calling every stiff shoulder frozen.** A shoulder that cannot externally rotate passively may be arthritic or posteriorly dislocated. Get an axillary or Y view.
- **Expecting thenar numbness in carpal tunnel.** The palmar cutaneous branch passes over the ligament, so thenar skin is spared. Thenar numbness means a proximal lesion.
- **Clearing a FOOSH wrist with normal films.** Scaphoid fractures may be occult. Snuffbox tenderness means a thumb spica and repeat imaging or MRI.
- **Examining only the knee in a limping teenager.** SCFE and Perthes present as knee pain. Check hip internal rotation.
- **Ruling out Achilles rupture because the patient can plantarflex.** Toe flexors and peroneals still plantarflex. Use the Thompson test.
- **Calling grade III worse because it hurts more.** A complete rupture can hurt less than grade II because the pain fibers are torn. Laxity and end feel decide.
- **Putting RA in the DIP joints.** RA spares the DIP. DIP disease is OA or psoriatic arthritis.

Chapter 5 self-test · ten items

1. A 52 year old woman with type 2 diabetes has 5 months of shoulder pain and stiffness. Passive and active external rotation are both markedly limited, and radiographs are normal. Most likely diagnosis?

A. Subacromial bursitis
B. Acromioclavicular sprain
C. Adhesive capsulitis
D. Supraspinatus tendinopathy

C. Adhesive capsulitis Equal loss of active and passive motion in the capsular pattern, external rotation worst, with normal films and diabetes, is adhesive capsulitis.

2. The patient places the back of the hand on the low back but cannot push it away from the spine. Which muscle is torn?

A. Infraspinatus
B. Supraspinatus
C. Teres minor
D. Subscapularis

D. Subscapularis The Gerber lift off test isolates the subscapularis, the internal rotator.

3. With the arm abducted 90° and the elbow flexed, slow external rotation makes the patient grab your hand in fear. A posterior push on the humeral head relieves it. What is present?

A. Anterior glenohumeral instability
B. Long head biceps tendinopathy
C. A SLAP lesion of the labrum
D. Inferior multidirectional laxity

A. Anterior glenohumeral instability Apprehension relieved by relocation confirms anterior instability.

4. A cashier has night numbness of the thumb, index and middle fingers that eases when she shakes the hand. Sensation over the thenar eminence is normal. Where is the lesion?

A. The C6 nerve root
B. Median nerve at the wrist
C. Median nerve at the elbow
D. Ulnar nerve at the wrist

B. Median nerve at the wrist Carpal tunnel syndrome spares thenar skin because the palmar cutaneous branch passes superficial to the transverse carpal ligament.

5. A young adult fell on an outstretched hand. Films are normal but the anatomic snuffbox is tender. What is the best next step?

A. Wrist manipulation and taping
B. Heat and range of motion only
C. Reassure and return to sport
D. Thumb spica and repeat imaging

D. Thumb spica and repeat imaging Scaphoid fractures can be occult. Immobilize and re-image in 10 to 14 days or obtain MRI because of the risk of avascular necrosis.

6. An obese 13 year old boy has 3 weeks of knee pain and a limp. When you flex his hip, the thigh rolls into external rotation. What is the most likely diagnosis?

A. Slipped capital femoral epiphysis
B. Legg Calvé Perthes disease
C. Osgood Schlatter tibial apophysitis
D. Patellofemoral pain syndrome

A. Slipped capital femoral epiphysis Obligatory external rotation with flexion in an obese adolescent with knee pain is SCFE. Avoid weight bearing and refer urgently.

7. Which test is the most sensitive for an acute ACL tear?

A. The anterior drawer
B. The posterior sag
C. The Lachman test
D. The pivot shift

C. The Lachman test Lachman at 20 to 30° is the most sensitive ACL test. The pivot shift is the most specific but hard to elicit in an awake patient.

8. Squeezing the calf of a prone patient produces no plantarflexion, though the patient can weakly point the foot when asked. What is the diagnosis?

A. Partial gastrocnemius strain
B. Complete Achilles tendon rupture
C. Posterior tibial tendinopathy
D. Tibial nerve tarsal tunnel entrapment

B. Complete Achilles tendon rupture A positive Thompson test means a complete rupture. Toe flexors and peroneals still allow weak active plantarflexion.

9. A 63 year old has bony enlargement of the DIP and PIP joints, a painful thumb base, and 15 minutes of morning stiffness. Labs are normal. Most likely diagnosis?

A. Psoriatic arthritis
B. Tophaceous gout
C. Hand osteoarthritis
D. Rheumatoid arthritis

C. Hand osteoarthritis Heberden and Bouchard nodes, first CMC involvement, brief stiffness and normal labs are osteoarthritis.

10. After a tibial shaft fracture, a patient has pain far out of proportion and severe pain when the toes are passively stretched. Pulses are present. What is needed?

A. Urgent referral for fasciotomy
B. Elevation and recheck tomorrow
C. Ice and compression wrapping
D. Wait until pulses disappear

A. Urgent referral for fasciotomy Pain out of proportion and pain on passive stretch are the earliest signs of compartment syndrome. Pulselessness is a late sign.

CHAPTER 6

The Neurologic Examination and Neurologic Diagnosis

Read it in full: **Chapter 6 in the textbook**. Practice it: **Practice exam 3** and the **flashcards**.

What to know

Mental status: orientation, attention, recall, language, visuospatial skill and judgment. MMSE 23 or below suggests impairment; MoCA under 26 is abnormal. The **Glasgow Coma Scale** scores eyes 1 to 4, verbal 1 to 5 and motor 1 to 6, for 3 to 15; 8 or less means coma and a threatened airway. Broca aphasia is halting with good comprehension; Wernicke aphasia is fluent but meaningless with poor comprehension.

Cranial nerves by the **rule of four**: I and II above the brainstem, III and IV midbrain, V to VIII pons, IX to XII medulla. Crossed signs (a cranial nerve deficit on one side, body weakness on the other) mean brainstem. CN III palsy gives an eye down and out with ptosis and a dilated pupil; a painful, pupil involving palsy suggests a posterior communicating artery aneurysm. CN VI palsy is a false localizing sign of raised pressure. An **LMN facial palsy** (Bell) weakens the whole half face; an UMN lesion spares the forehead. The uvula deviates **away** from a CN X lesion; the tongue deviates **toward** a CN XII lesion. CN XI weakness drops the shoulder.

Eyes and ears: a Marcus Gunn pupil means optic nerve disease; Horner syndrome is ptosis, miosis and anhidrosis (Pancoast, carotid dissection, lateral medullary infarct). Internuclear ophthalmoplegia (MLF) is failure of adduction on the lesion side with nystagmus of the abducting eye; bilateral INO in a young adult suggests MS. BPPV gives brief positional vertigo with delayed, fatiguing torsional nystagmus on Dix Hallpike; central vertigo has nonfatiguing, direction changing or vertical nystagmus and is a red flag.

The cerebellum works on the **same side**. Signs are DANISH: dysdiadochokinesia, ataxia, nystagmus, intention tremor, scanning speech, hypotonia. The vermis controls trunk and gait. **Romberg** tests proprioception and vestibular input, not the cerebellum: a cerebellar patient is unsteady with eyes open too.

Motor: spasticity is velocity dependent (clasp knife, UMN); rigidity is uniform (lead pipe or cogwheel, basal ganglia). Pronator drift screens for subtle UMN weakness. Strength 0 to 5, where **grade 3** is full range against gravity only. A single root lesion gives partial weakness, never paralysis. UMN lesions: spastic, hyperreflexic, Babinski, little atrophy. LMN lesions: flaccid, areflexic, atrophy, fasciculations. Spinal shock looks LMN at first; return of the bulbocavernosus reflex ends it. UMN and LMN signs in the same limb with normal sensation is ALS until proven otherwise.

Sensory: the **dorsal columns** (vibration, position, two point discrimination) ascend on the same side and cross in the medulla; the **spinothalamic tract** (pain, temperature) crosses within one or two segments. Stocking and glove loss is polyneuropathy; a trunk sensory level with UMN signs is cord. **Brown Séquard**: ipsilateral weakness and loss of vibration and position, contralateral loss of pain and temperature. Central cord: arms weaker than legs (hyperextension in an older spondylotic neck). Syringomyelia: cape like dissociated loss. Anterior cord: motor and pain lost, dorsal columns spared. Parietal lesions impair stereognosis and graphesthesia with intact primary sensation.

Dermatome landmarks: C6 thumb, C7 middle finger, C8 little finger, T4 nipple, T10 umbilicus, L4 medial malleolus, L5 dorsum of foot and great toe, S1 lateral foot and sole, S3 to S5 saddle. A peripheral nerve field has sharper borders: meralgia paresthetica (lateral femoral cutaneous) is

pure sensory on the anterolateral thigh; a common fibular palsy spares inversion and hip abduction, which L5 weakens.

Reflexes: **biceps C5, brachioradialis C6, triceps C7, patellar L4, medial hamstring L5, Achilles S1**; jaw jerk is the pons. Grades 0 to 4+, where 4+ has clonus. Asymmetry matters more than the grade. Superficial reflexes: upper abdominal T8 to T10, lower T10 to T12, cremasteric L1 to L2, anal wink and bulbocavernosus S2 to S4. Babinski, Chaddock, Oppenheim, Gordon, Hoffmann, sustained clonus (more than about 3 to 5 beats) and the **inverted supinator** reflex mean UMN. Babinski is normal until about age 1 to 2.

Radiculopathy: cervical roots exit above their pedicle (a C5 to C6 disc catches C6; C8 exits at C7 to T1). Lumbar roots exit below their pedicle, so a posterolateral L4 to L5 disc catches the **traversing L5** root and a far lateral L4 to L5 disc catches the exiting L4 root. C7 is the most common cervical root; L5 and S1 most lumbar. Progressive or grade 3 or worse weakness, intractable pain, or cord or cauda equina signs need referral.

Cervical spondylotic myelopathy is the commonest cord dysfunction over 55: clumsy hands, broad based spastic gait, Lhermitte, then bladder urgency, with UMN signs below the level, finger escape and a slow grip and release (under about 20 in 10 seconds). A canal under about 10 mm or a Torg Pavlov ratio under 0.8 is stenotic. Myelopathy contraindicates cervical manipulation. New back pain in a patient with cancer is metastasis until proven otherwise.

Cauda equina syndrome is an LMN syndrome of the roots (reduced reflexes, no Babinski): saddle anesthesia, urinary retention with overflow (most consistent), fecal incontinence, bilateral or progressive leg weakness. Post void residual over about 200 mL supports it. Same day emergency MRI and decompression, ideally within 48 hours. Conus medullaris syndrome is sudden, symmetric, with early bladder loss and possible mixed UMN and LMN signs.

Vascular: cervical artery dissection is a leading cause of stroke under 45. Vertebral dissection gives posterior neck and occipital pain then the 5 Ds and 3 Ns; carotid dissection gives anterolateral neck, face or eye pain with a partial Horner and pulsatile tinnitus. Case control studies show stroke patients saw chiropractors and primary care physicians at similar rates, consistent with patients seeking care for the pain of an evolving dissection; positional screening

tests are unreliable. Stroke: BE FAST; thrombolysis within 4.5 hours. MCA strokes hit face and arm more than leg; ACA strokes hit the leg; Wallenberg gives crossed facial and body pain loss. MS is demyelination disseminated in time and space; Guillain Barré is ascending weakness with areflexia; myasthenia is fatigable weakness with normal reflexes.

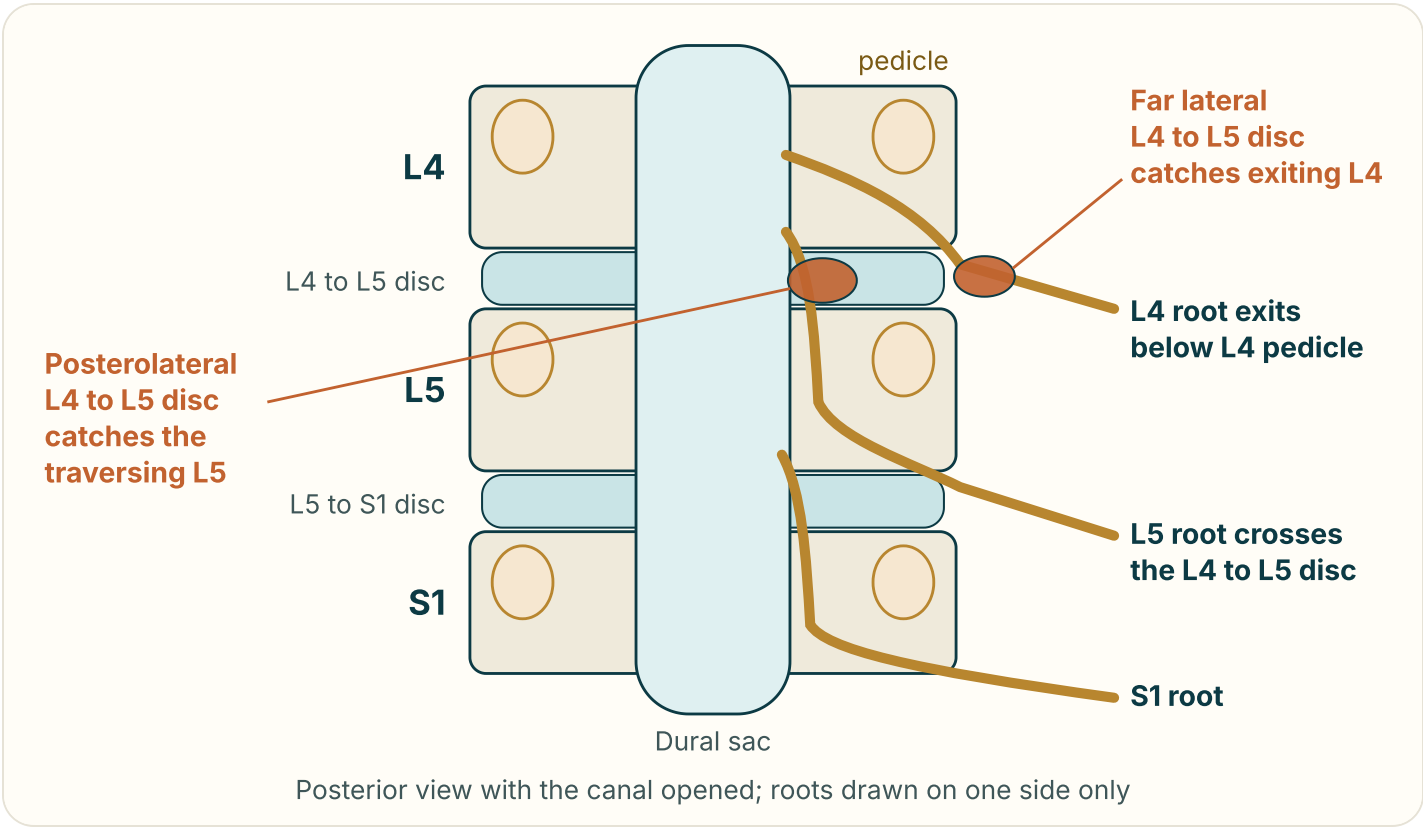

Posterolateral L4 to L5 catches L5; far lateral catches L4. Each lumbar root exits below the pedicle of its own vertebra, so it first crosses the disc above. A typical posterolateral herniation therefore hits the next root down.

LOCK THESE IN

- Rule of four: I to II above, III to IV midbrain, V to VIII pons, IX to XII medulla. Crossed signs mean brainstem.
- UMN facial palsy spares the forehead. Uvula away from, tongue toward the lesion.
- Cerebellar signs are ipsilateral; Romberg tests proprioception, not the cerebellum.
- Strength grade 3 is full range against gravity only.
- Reflexes: biceps C5, brachioradialis C6, triceps C7, patellar L4, medial hamstring L5, Achilles S1.
- Brown Séquard: everything ipsilateral except pain and temperature.
- Posterolateral L4 to L5 disc catches L5; far lateral catches L4; C5 to C6 disc catches C6.
- Cauda equina is LMN: retention most consistent, saddle anesthesia classic, emergency MRI.

Root levels at a glance

Root (usual disc)	Sensory	Weakness	Reflex
C5 (C4 to C5)	Lateral arm	Deltoid, biceps	Biceps
C6 (C5 to C6)	Lateral forearm, thumb, index	Wrist extensors, biceps	Brachioradialis
C7 (C6 to C7)	Middle finger	Triceps, wrist flexors	Triceps
C8 (C7 to T1)	Little finger, medial forearm	Finger flexors, intrinsics	Finger flexor
L4 (L3 to L4)	Medial leg, medial malleolus	Tibialis anterior, quadriceps	Patellar
L5 (L4 to L5)	Lateral leg, dorsum of foot, great toe	EHL, gluteus medius, inversion	Medial hamstring (unreliable)
S1 (L5 to S1)	Lateral foot, sole, little toe	Gastrocnemius, peroneals, gluteus maximus	Achilles

Localizing patterns

Pattern	Findings	Level
UMN	Spastic, hyperreflexic, Babinski, little atrophy	Brain or cord
LMN	Flaccid, areflexic, atrophy, fasciculations	Anterior horn, root, nerve
Brown Séquard	Ipsilateral motor and dorsal column loss; contralateral pain and temperature	Cord hemisection
Central cord	Arms weaker than legs, hands worst	Cervical cord, hyperextension
Syringomyelia	Cape like pain and temperature loss, touch kept	Central cervical cord
Anterior cord	Motor and pain lost, vibration kept	Anterior spinal artery
Cauda equina	Saddle anesthesia, retention, LMN legs	Lumbosacral roots
Stocking and glove	Distal symmetric loss, low ankle reflexes	Polyneuropathy
GCS	Eyes 1 to 4, verbal 1 to 5, motor 1 to 6	8 or less: coma

Worked cases

WORKED CASE 1 · GLASGOW COMA SCALE

After a fall, a patient opens his eyes only to a painful stimulus, answers in a confused way, and reaches up to push your hand away from a painful stimulus.

STEP 1 · EYES

Opens to pain: **2** of 4.

STEP 2 · VERBAL

Confused conversation: **4** of 5.

STEP 3 · MOTOR

Localizes pain: **5** of 6.

STEP 4 · TOTAL

2 + 4 + 5 = **11** of 15. It is above 8, so not coma, but any reduced GCS after head trauma means emergency services.

WORKED CASE 2 · WHICH ROOT

A 46 year old has pain from the buttock down the lateral leg to the great toe. Great toe extension and hip abduction are weak, and heel walking is difficult. Patellar and Achilles reflexes are normal. Sensation is reduced over the dorsum of the foot.

STEP 1 · MAP THE SENSORY LOSS

Dorsum of the foot and great toe is the **L5** dermatome.

STEP 2 · MAP THE WEAKNESS

EHL and gluteus medius are L5 muscles. Hip abduction weakness also rules out a common fibular palsy.

STEP 3 · CHECK THE REFLEXES

L5 has no reliable reflex, so normal patellar (L4) and Achilles (S1) reflexes fit.

STEP 4 · FIND THE DISC

Lumbar roots exit below their pedicle, so the L5 root traverses the L4 to L5 disc: a **posterolateral L4 to L5 herniation** is most likely.

WORKED CASE 3 · A STAB WOUND AND A SPLIT DEFICIT

After a knife wound to the left side of the back at about T8, a patient has a weak, hyperreflexic left leg with loss of vibration and position in the left leg, and loss of pain and temperature in the right leg.

STEP 1 · MOTOR

Corticospinal fibers have already crossed in the medulla, so the weak leg is on the side of the lesion: left.

STEP 2 · DORSAL COLUMNS

They have not crossed yet, so vibration and position are lost on the same side: left.

STEP 3 · SPINOTHALAMIC

Pain and temperature fibers crossed within a segment or two, so loss is on the opposite side: right.

STEP 4 · CONCLUDE

A left **Brown Séquard** hemisection near T8. Everything is on the side of the lesion except pain and temperature.

WORKED CASE 4 · MYELOPATHY OR RADICULOPATHY

A 64 year old has dropped things for months and fumbles buttons. Hand numbness is diffuse, not dermatomal. The biceps and brachioradialis reflexes are reduced, but tapping the brachioradialis flexes the fingers. Hoffmann is positive and the gait is broad based.

STEP 1 · THE HANDS

Clumsy, diffusely numb hands without a dermatome fit cord disease, not a single root.

STEP 2 · THE INVERTED SUPINATOR

Lost brachioradialis with finger flexion means an LMN lesion at C5 to C6 with UMN signs below it.

STEP 3 · UMN SIGNS

Positive Hoffmann and a broad based gait add to the picture.

STEP 4 · CONCLUDE

Cervical spondylotic myelopathy at about C5 to C6. Cervical manipulation is contraindicated; refer for MRI and spine surgical opinion.

TRAPS PEOPLE FALL INTO

- **Calling a positive Romberg cerebellar.** Romberg tests proprioception and vestibular input. Cerebellar patients sway with eyes open too.
- **Calling a forehead sparing palsy Bell palsy.** Forehead sparing means an UMN lesion such as stroke. Bell palsy weakens the whole half face.
- **Expecting Babinski in cauda equina syndrome.** Cauda equina is a root (LMN) syndrome: reduced reflexes and flaccid weakness.
- **Assigning an L4 to L5 disc to the L4 root.** A posterolateral L4 to L5 disc catches the traversing L5 root. Only a far lateral disc catches L4.
- **Reading total paralysis of one muscle as a root lesion.** Muscles get two or three roots. Complete paralysis points to a peripheral nerve.
- **Calling brisk symmetric reflexes abnormal by themselves.** Symmetric 3+ can be normal. Asymmetry and company (clonus, Babinski, Hoffmann) matter.
- **Using a negative positional test to clear a dissection.** Positional tests are unreliable. History and a neurological screen protect the patient.
- **Flipping Brown Séquard.** Weakness and dorsal column loss are ipsilateral; only pain and temperature are contralateral.

Chapter 6 self-test · ten items

1. A patient cannot wrinkle the left forehead, close the left eye or smile on the left. There is no limb weakness. Where is the lesion?

A. Left facial nerve, lower motor neuron
B. Left motor cortex, upper motor neuron
C. Right facial nerve, lower motor neuron
D. Right motor cortex, upper motor neuron

A. Left facial nerve, lower motor neuron Whole half face weakness including the forehead is an LMN (Bell type) lesion on the same side. An UMN lesion spares the forehead.

2. On protrusion, the tongue deviates to the right. Which nerve is affected?

A. Left glossopharyngeal nerve
B. Right hypoglossal nerve
C. Left hypoglossal nerve
D. Right vagus nerve

B. Right hypoglossal nerve The intact genioglossus pushes the tongue toward the weak side, so it points toward the lesion.

3. A patient stands steady with eyes open but falls when the eyes close. What is the most likely problem?

A. Cerebellar vermis atrophy
B. A left cerebellar lesion
C. Loss of joint position sense
D. Upper motor neuron weakness

C. Loss of joint position sense A positive Romberg means dependence on vision because position sense (dorsal columns or large fiber nerves) or vestibular input is lost.

4. A muscle moves the joint through full range against gravity but gives way to any added resistance. What grade is it?

A. Grade 1
B. Grade 4
C. Grade 2
D. Grade 3

D. Grade 3 Grade 3 is full range against gravity only. Grade 4 tolerates some resistance; grade 2 needs gravity eliminated.

5. Which reflex is reduced in an S1 radiculopathy?

A. Medial hamstring reflex
B. Patellar reflex
C. Achilles reflex
D. Cremasteric reflex

C. Achilles reflex The Achilles reflex is S1. Patellar is L4, medial hamstring L5 and cremasteric L1 to L2.

6. A 50 year old has asymmetric hand weakness with atrophy and fasciculations, brisk reflexes and Babinski signs in the same limbs, and normal sensation. Most likely diagnosis?

A. Guillain Barré syndrome
B. Amyotrophic lateral sclerosis
C. Multiple sclerosis relapse
D. Cervical radiculopathy at C8

B. Amyotrophic lateral sclerosis UMN and LMN signs together in the same region with normal sensation is ALS until proven otherwise.

7. A patient has loss of pain and temperature in a cape over both shoulders and arms, with light touch and vibration preserved. Where is the lesion?

A. Central cervical cord
B. The dorsal columns
C. The cauda equina
D. The right parietal lobe

A. Central cervical cord Dissociated cape like loss is syringomyelia: a central cavity interrupts the crossing spinothalamic fibers.

8. A far lateral disc herniation at L4 to L5 is most likely to compress which root?

A. S1 nerve root
B. L3 nerve root
C. L5 nerve root
D. L4 nerve root

D. L4 nerve root A far lateral herniation catches the root exiting at that level, L4. A posterolateral L4 to L5 disc catches the traversing L5.

9. A man with acute low back pain reports numbness of the inner buttocks and new difficulty passing urine. Ankle reflexes are reduced. What is the next step?

A. Same day emergency referral
B. Lumbar films then reassess
C. Flexion distraction and recheck
D. Routine MRI within a month

A. Same day emergency referral Saddle anesthesia with urinary retention is cauda equina syndrome. Outcome depends on early decompression, so refer to the emergency department now.

10. A 38 year old has sudden severe occipital headache and neck pain after a minor strain, and this morning had brief double vision and slurred speech. What should you do?

A. Perform positional artery tests first
B. Gentle mobilization of the upper neck
C. Call emergency services; no treatment
D. Ice and recheck in two days

C. Call emergency services; no treatment New unusual neck pain and headache with diplopia and dysarthria suggests vertebral artery dissection. Do not treat; call emergency services.

ONE PAGE

Cram sheet

Everything from chapters 5 and 6 in one place. Cover the right columns and see if you can rebuild each row.

Numbers to know

Item	Value	Note
Painful arc	60 to 120° impingement; 170 to 180° AC	Scapulohumeral rhythm 2 to 1
Carrying angle	5 to 15°	Greater in women
Allen test	Color back in about 5 to 7 s	Longer means occluded artery
Q angle	About 13° men, 18° women	Larger means more lateral pull
Lachman	Knee at 20 to 30°	Valgus stress at 30° isolates MCL
Ottawa ankle	Distal 6 cm of malleoli; four steps	Navicular and fifth metatarsal base for foot
RA neck	ADI over 3 mm abnormal (adult)	No upper cervical thrust in active RA
Fibromyalgia	WPI 7+ and SSS 5+, or WPI 4 to 6 and SSS 9+	4 of 5 regions, 3 months
GCS	3 to 15; 8 or less coma	E 4, V 5, M 6
MMSE / MoCA	23 or below / under 26	Cognitive screens
Clonus	More than about 3 to 5 beats	Sustained means UMN
Myelopathy	Canal under about 10 mm; Torg Pavlov under 0.8	Grip and release under 20 in 10 s
Cauda equina	Post void residual over about 200 mL	Decompress ideally within 48 h

Rules that decide questions

Topic	The rule
Shoulder	Pain with strength is tendinopathy; weakness is a tear; equal active and passive loss is capsule.
Hand nerves	Carpal tunnel spares thenar skin; Guyon spares the dorsal ulnar hand; ulnar paradox.
Hip by age	DDH newborn, Perthes 4 to 8, SCFE obese 10 to 16, septic hip febrile child.
Knee	Forward tibia ACL, backward PCL, valgus MCL, varus LCL, rotation with click meniscus.
Arthritis	DIP is OA or psoriatic; MCP and wrist is RA; gout negative, CPPD positive.
Cranial nerves	Rule of four; uvula away, tongue toward; UMN face spares forehead.
Cerebellum	Ipsilateral; DANISH; Romberg is not cerebellar.
UMN vs LMN	Spastic, brisk, Babinski versus flaccid, absent, atrophy, fasciculations.
Cord syndromes	Brown Séquard split; central cord arms; syrinx cape; anterior cord spares vibration.
Discs	Lumbar catches the traversing root; cervical catches the root of the lower vertebra.
Emergencies	Myelopathy, cauda equina, dissection, stroke, GBS, epidural abscess, metastatic compression.

An independent study aid, not affiliated with or endorsed by the National Board of Chiropractic Examiners.
Dr. Garg Learning · CC BY-SA 4.0