PART II CLINICAL SCIENCES · BOARD REVIEW

Study Guide 2

This guide covers the internal disorders a chiropractor must recognize in Chapter 3 and the spinal and pelvic examination in Chapter 4. You will learn how heart, lung, aortic, blood, gut, kidney and endocrine disease show up as back or limb pain, how to set the urgency of a referral, and how to read posture, gait and the classic orthopedic tests. Work one chapter at a time. Read the "what to know" paragraphs, study the diagram and tables, then try each worked case with the steps covered. Finish each chapter with its ten board-style items.

WHAT THIS GUIDE COVERS

- Chapter 3 · sinusitis, pharyngitis and mononucleosis, asthma and COPD, pneumonia, pneumothorax and PE, hypertension, coronary disease and heart failure, AAA and dissection, PAD and claudication, anemia, myeloma, bleeding disorders, lymph nodes, autoimmune disease, visceral referral, GI, renal and prostate disease, endocrine disorders, infection, sepsis and referral urgency.
- Chapter 4 · OPQRST and mechanism of injury, whiplash grades, pain types, mechanical and inflammatory pain, red and yellow flags, outcome measures, plumb line posture, crossed syndromes, scoliosis and Adams, leg length, gait, and the cervical, thoracic, thoracic outlet, lumbar, sacroiliac and nonorganic tests.

CHAPTER 3

Diagnosis of Internal Disorders and When to Refer

Read it in full: **Chapter 3 in the textbook**. Practice it: **Practice exam 2** and the **flashcards**.

What to know

Internal disease reaches the chiropractic office as chest wall, interscapular, shoulder, back and leg pain. Your job is to recognize it, set the urgency and refer. The history (exertional, positional, pleuritic), vital signs, the lung exam, pulses and blood pressure in both arms sort out most of it.

Upper airway: sinusitis is usually viral; suspect bacteria after 10 days without improvement, a severe start or "double sickening." Orbital swelling, eye pain or neck stiffness means emergency. Strep pharyngitis is scored with the **Centor criteria** (fever, exudate, tender anterior nodes, no cough). Antibiotics prevent rheumatic fever but not poststreptococcal glomerulonephritis. In **mononucleosis** the spleen enlarges, so avoid contact sports and forceful thoracic or abdominal thrusts for at least 3 to 4 weeks. Epiglottitis (drooling, stridor, tripod posture): never examine the throat; call emergency services.

Lungs: **asthma** is reversible obstruction (FEV_1 up 12% and 200 mL after a bronchodilator); a "silent chest" is impending failure. **COPD** is a post bronchodilator FEV_1/FVC under 0.70. Chronic bronchitis is a productive cough 3 months a year for 2 years; emphysema gives a barrel chest and hyperresonance; panacinar lower lobe emphysema in a young nonsmoker suggests alpha 1 antitrypsin deficiency. Pneumonia gives dullness, increased fremitus and bronchial sounds; CURB 65 of 2 or more generally means hospital care. A tall thin young man with sudden pleuritic pain has a spontaneous pneumothorax until shown otherwise. **Pulmonary embolism** follows Virchow triad (stasis, hypercoagulability, endothelial injury) and is an emergency; do not massage a suspected DVT limb.

Hypertension is 90% primary. Suspect a secondary cause with onset before 30 or after 55, resistance to three drugs, or clues: abdominal bruit (renal artery stenosis), episodic headache, sweating and palpitations (pheochromocytoma), hypokalemia (aldosteronism), arm pressure higher than leg with rib notching (coarctation). Crisis range with organ damage is an emergency; without damage it is an urgency needing same day care. No high velocity thrust in the crisis range.

Heart: stable angina is exertional and eases with rest or nitroglycerin; MI pain lasts over 20 minutes with sweating and nausea, and women, people with diabetes and older adults often present atypically. Suspected acute coronary syndrome means emergency services, and the patient does not drive. Reproducible chest wall tenderness lowers but never removes cardiac risk. Left heart failure backs fluid into the lungs (orthopnea, PND, crackles, S3); right heart failure backs it into the veins (JVD, hepatomegaly, edema).

Aorta: an **AAA** is an infrarenal aorta of 3 cm or more; smoking is the strongest modifiable risk. Screen men 65 to 75 who ever smoked with one ultrasound. Rupture risk climbs above 5.5 cm. A

leaking aneurysm gives deep, boring back pain unchanged by position; rupture adds hypotension and a pulsatile mass. **Aortic dissection** is sudden tearing pain, chest or interscapular, with an arm pressure difference over 20 mm Hg and pulse deficits. Stanford type A involves the ascending aorta and is a surgical emergency; type B is distal to the left subclavian.

Peripheral arterial disease gives **vascular claudication**: calf pain at a fixed distance, relieved by standing still, with weak pulses and an ABI of 0.90 or less. Neurogenic claudication of spinal stenosis is relieved by sitting or flexing, worse downhill, painless on a bicycle, with a positive shopping cart sign and normal pulses. Acute limb ischemia (six Ps) is an emergency.

Blood: MCV sorts anemia. Iron deficiency in a man or postmenopausal woman means GI blood loss until proven otherwise. **B12 deficiency** causes subacute combined degeneration (dorsal columns and lateral corticospinal tracts), sometimes before anemia; folate alone can fix the blood while the nerves worsen. Sickle cell disease gives H shaped vertebrae and avascular necrosis. **Multiple myeloma** is the most common primary malignant bone tumor in adults: CRAB (calcium, renal failure, anemia, bone lesions), punched out lesions, pedicles spared early, a cold bone scan. Metastatic carcinoma destroys the pedicle (winking owl). Platelet defects cause mucocutaneous bleeding; factor defects (hemophilia) cause hemarthroses. Anticoagulation changes technique and raises epidural hematoma risk.

Lymph nodes: hard, fixed, matted, over about 1.5 to 2 cm, persistent past 4 to 6 weeks, supraclavicular, or with B symptoms (fever, night sweats, over 10% weight loss in 6 months) need referral. Immunosuppressed patients with new spinal pain may have osteomyelitis or abscess with little fever. Polymyalgia rheumatica and **giant cell arteritis** occur over 50 with a very high ESR; new headache, scalp tenderness or jaw claudication is a same day referral to protect vision. Rheumatoid arthritis needs flexion and extension films for atlantoaxial instability before cervical manipulation.

Visceral pain follows segmental supply, so organs project to the back. It is deep, diffuse, not changed by spinal movement or palpation, and tied to organ function (eating, urination, bowel habit, menstruation). Gallbladder refers to the right scapula, pancreas bores through to the thoracolumbar back and eases leaning forward, kidney goes to the flank and groin, and a posterior

duodenal ulcer can cause mid back pain. Posture is a clue: a stone patient writhes, a peritonitis patient lies still.

Endocrine: diabetes is fasting glucose 126, HbA1c 6.5% or OGTT 200; it brings adhesive capsulitis, carpal tunnel, DISH and Charcot joints. Treat office hypoglycemia with about 15 g of fast sugar if the patient can swallow. Primary thyroid disease moves TSH opposite to T4. **Chvostek** (cheek tap) and **Trousseau** (cuff on the arm) mean hypocalcemia. Cushing syndrome brings osteoporotic fractures and avascular necrosis. Osteoporosis is a T score of −2.5 or a fragility fracture; sudden thoracolumbar pain after a minor strain in an older woman is a fracture until proven otherwise. Metabolic syndrome is 3 of 5 criteria.

Infection and referral: vertebral osteomyelitis has fever in only about half; MRI is the earliest test and plain films lag 2 to 3 weeks. Epidural abscess (pain, fever, deficit) and meningitis are emergencies. Shingles pain precedes the rash. qSOFA flags sepsis with 2 of 3: respiratory rate 22 or more, altered mentation, systolic 100 or less. One emergency flag in a vignette means immediate referral, not more testing or a trial of care.

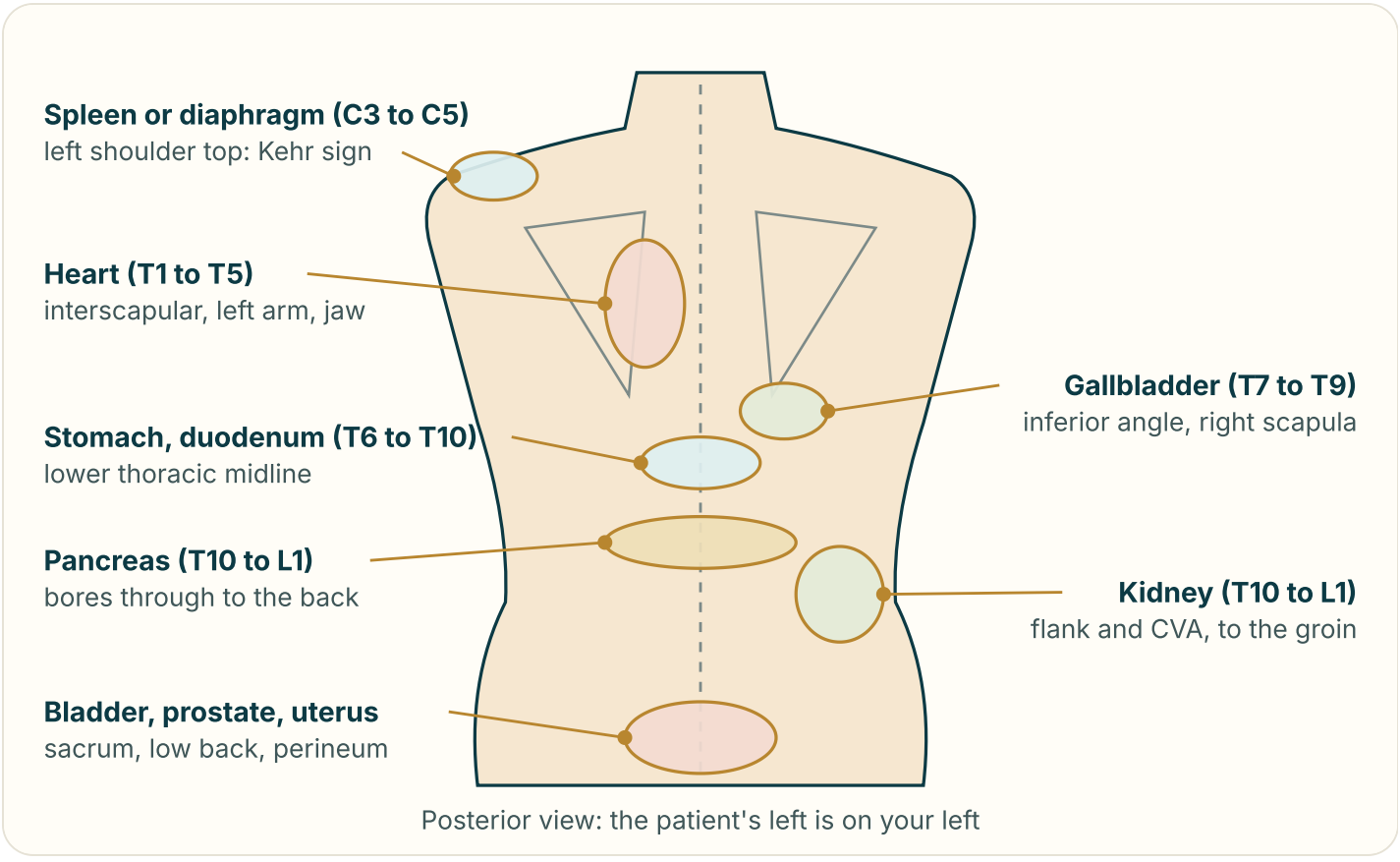

Organs project to the back along their segmental supply. None of these pains changes with spinal movement or palpation; each changes with the organ's own function, such as eating, urination or bowel habit.

LOCK THESE IN

- Fremitus rises only in consolidation. Effusion and pneumothorax lower it; percussion separates fluid (dull) from air (hyperresonant).
- AAA is 3 cm or more; rupture risk rises above 5.5 cm; screen men 65 to 75 who ever smoked.
- Dissection: sudden tearing pain, arm difference over 20 mm Hg. Stanford A (ascending) is a surgical emergency.
- Vascular claudication eases standing still with low ABI; neurogenic eases sitting or flexing with normal pulses.
- Myeloma: CRAB, punched out lesions, cold bone scan, pedicles spared early.
- B12 deficiency can damage the dorsal columns before anemia appears.
- Visceral pain is unchanged by spinal movement and tied to organ function.
- One emergency flag means emergency referral now. Urgency is set by the most dangerous likely cause.

Visceral referral to the back

Organ	Segments (approx.)	Where pain is felt
Heart	T1 to T5	Substernal, left arm, jaw, interscapular
Esophagus	T4 to T6	Substernal, interscapular
Stomach, duodenum	T6 to T10	Epigastric, lower thoracic midline back
Gallbladder, liver	T7 to T9; phrenic C3 to C5	Right upper quadrant, right scapular angle, right shoulder
Pancreas	T10 to L1	Epigastric boring through to the thoracolumbar back
Kidney, upper ureter	T10 to L1	Flank and CVA, radiating to groin
Appendix	T10	Periumbilical, then right lower quadrant
Bladder, prostate, uterus	T11 to L2 and S2 to S4	Suprapubic, sacrum, low back, perineum
Spleen or diaphragm	Phrenic C3 to C5	Top of the shoulder (Kehr sign on the left)

Scores and cutoffs for internal disease

Tool	Criteria	Meaning
Centor	Fever, exudate, tender anterior nodes, no cough (1 each)	Higher scores justify strep testing
CURB 65	Confusion, urea over 7 mmol/L, RR 30+, BP under 90/60, age 65+	2 or more: generally hospital care
qSOFA	RR 22+, altered mentation, systolic 100 or less	2 of 3 flags sepsis risk
ABI	Ankle ÷ higher arm systolic	0.90 or less PAD; under about 0.4 severe
Metabolic syndrome	Waist over 40 in (men) or 35 in (women); TG 150+; HDL under 40 (men) or 50 (women); BP 130/85+; fasting glucose 100+	3 of 5
B symptoms	Fever, drenching night sweats, over 10% weight loss in 6 months	Lymphoma concern
NYHA class	I none; II ordinary activity; III less than ordinary; IV at rest	Heart failure function

Worked cases

WORKED CASE 1 · CLAUDICATION: VASCULAR OR NEUROGENIC

A 71 year old smoker gets calf cramping after walking two blocks. It eases within 2 minutes of standing still. He also gets it riding an exercise bike. Dorsalis pedis pulses are faint. Ankle systolic is 88 mm Hg and the higher arm systolic is 142 mm Hg.

STEP 1 · COMPUTE THE ABI

88 ÷ 142 = **0.62**.

STEP 2 · READ THE ABI

0.90 or less confirms peripheral arterial disease; 0.62 is well below that, but above the severe range of about 0.4.

STEP 3 · READ THE HISTORY

Fixed distance, relief by simply standing still, pain on the bicycle and weak pulses all point to **vascular claudication**.

STEP 4 · CONTRAST

Neurogenic claudication would ease only with sitting or flexing, spare the bicycle, show a shopping cart sign and leave pulses normal.

STEP 5 · ACT

Refer for vascular evaluation. The two can coexist, so still examine the lumbar spine.

WORKED CASE 2 · CURB 65

A 72 year old woman with cough, fever and dullness at the right base is alert. Urea is 8 mmol/L, respiratory rate 32, blood pressure 95/58 mm Hg.

STEP 1 · CONFUSION

Alert: 0.

STEP 2 · UREA OVER 7 MMOL/L

8 is over 7: 1.

STEP 3 · RESPIRATORY RATE 30 OR MORE

32: 1.

STEP 4 · BLOOD PRESSURE UNDER 90 SYSTOLIC OR 60 DIASTOLIC

Diastolic 58 is under 60: 1.

STEP 5 · AGE 65 OR OLDER

72: 1.

STEP 6 · TOTAL

0 + 1 + 1 + 1 + 1 = **4**. A score of 2 or more generally means hospital care, so this is an emergency referral.

WORKED CASE 3 · THE OLDER ADULT WITH BACK PAIN AND ABNORMAL LABS

A 74 year old man has six weeks of thoracolumbar pain at rest and at night, fatigue and recurrent chest infections. Labs: hemoglobin 10.4, calcium 11.2, creatinine 1.9, ESR 105. A bone scan was normal.

STEP 1 · APPLY CRAB

Calcium high, renal function low, anemia, bone pain: all four features.

STEP 2 · EXPLAIN THE COLD SCAN

Myeloma lesions are purely lytic with little osteoblastic response, so the bone scan is often normal. Skeletal survey, low dose whole body CT or MRI is used instead.

STEP 3 · LOOK AT THE FILMS

Expect punched out lytic lesions, diffuse osteopenia and compression fractures, with pedicles spared early (metastatic carcinoma tends to destroy the pedicle).

STEP 4 · ACT

Refer for serum and urine protein electrophoresis. Do not manipulate the painful segment until a pathological fracture is excluded.

WORKED CASE 4 · METABOLIC SYNDROME COUNT

A man has a waist of 38 inches, triglycerides 180 mg/dL, HDL 36 mg/dL, blood pressure 134/82 mm Hg and fasting glucose 104 mg/dL.

STEP 1 · WAIST

Men need over 40 inches; 38 is not met.

STEP 2 · TRIGLYCERIDES

180 is 150 or more: met.

STEP 3 · HDL

Men need under 40; 36: met.

STEP 4 · BLOOD PRESSURE

The criterion is 130/85 or higher; systolic 134 meets it: met.

STEP 5 · GLUCOSE

104 is 100 or more: met.

STEP 6 · TOTAL

4 of 5; 3 are needed, so he has metabolic syndrome. Refer for medical management and counsel on activity.

TRAPS PEOPLE FALL INTO

- **Reassuring because the chest wall is tender.** Reproducible tenderness lowers but never removes cardiac risk. An ischemic history means referral.
- **Ordering more tests when one emergency flag is present.** Saddle anesthesia, tearing pain, a pulsatile mass or fever with confusion means emergency referral now.
- **Using a provocative or Homans sign to clear a DVT.** Homans is neither sensitive nor specific. Refer for duplex ultrasound and do not massage the limb.
- **Trusting a normal bone scan in suspected myeloma.** Myeloma is often cold on bone scan because the lesions are purely lytic.
- **Giving folate for macrocytic anemia without checking B12.** Folate can correct the blood count while the B12 neuropathy progresses.

- **Calling every lymph node concerning.** Tender, soft, mobile nodes under 1 cm that shrink are reactive. Hard, fixed, supraclavicular nodes are the concern.
- **Expecting fever in spinal infection.** Fever is present in only about half, and immunosuppressed or older patients may be afebrile.
- **Adjusting a neck in polymyalgia without asking about headache.** New headache, scalp tenderness or jaw claudication over 50 suggests giant cell arteritis, a same day referral.

Chapter 3 self-test · ten items

1. A 17 year old with sore throat, fatigue and posterior cervical nodes has a positive Monospot. Which advice is most important for the next month?

A. Start antibiotics to prevent rheumatic fever
B. Avoid contact sport and forceful thrusts
C. Begin a graded return to football now
D. Prone thoracic adjusting is unrestricted

B. Avoid contact sport and forceful thrusts Splenomegaly in mononucleosis risks rupture, so contact sport and forceful abdominal or thoracic manipulation are avoided for at least 3 to 4 weeks.

2. A 66 year old smoker has deep, boring low back pain that does not change with position. On exam a pulsatile mass pushes the examiner's hands apart above the umbilicus. Best action?

A. Lumbar films then adjust if clear
B. Deep palpation to size the mass
C. Immediate emergency referral
D. Routine vascular clinic referral

C. Immediate emergency referral An expansile mass with nonmechanical back pain suggests a leaking abdominal aortic aneurysm, an emergency. Avoid deep palpation and manipulation.

3. A 55 year old with long standing hypertension has sudden tearing interscapular pain and a 28 mm Hg difference in systolic pressure between the arms. Most likely diagnosis?

A. Acute aortic dissection
B. Thoracic facet syndrome
C. Stable exertional angina
D. Costovertebral joint sprain

A. Acute aortic dissection Sudden tearing pain with an arm pressure difference over 20 mm Hg and hypertension is classic for dissection.

4. Which feature favors neurogenic over vascular claudication?

A. An ankle brachial index of 0.70
B. Pain while riding a stationary bicycle
C. Pain relieved by standing still a minute
D. Relief only when sitting or bending forward

D. Relief only when sitting or bending forward Neurogenic claudication eases with flexion or sitting. Relief on standing still, pain on a bicycle and a low ABI point to vascular disease.

5. A 72 year old has rest and night back pain, anemia, hypercalcemia, a raised creatinine and a normal bone scan. Which test best pursues the likely diagnosis?

A. An HLA-B27 antigen test
B. Serum protein electrophoresis
C. A repeat whole body bone scan
D. A rheumatoid factor titer

B. Serum protein electrophoresis CRAB features with a cold bone scan point to multiple myeloma; protein electrophoresis shows the monoclonal protein.

6. A 48 year old vegan has numb feet, loss of vibration sense, a positive Romberg and upgoing toes, with a normal hemoglobin. Best explanation?

A. Vitamin B12 deficiency
B. Iron deficiency
C. Thiamine deficiency
D. Folic acid deficiency

A. Vitamin B12 deficiency Subacute combined degeneration (dorsal columns and corticospinal tracts) is a B12 effect and can occur before anemia.

7. Epigastric pain bores through to the back, eases when the patient sits up and leans forward, and follows heavy drinking. Most likely source?

A. Lumbar disc lesion
B. Kidney stone colic
C. Gallbladder colic
D. Acute pancreatitis

D. Acute pancreatitis Pancreatic pain bores through to the thoracolumbar back and eases leaning forward; alcohol and gallstones are the main causes.

8. Two days after thyroid surgery, tapping in front of the patient's ear makes the corner of the mouth twitch. What does this indicate?

A. Low serum sodium
B. High serum calcium
C. Low serum calcium
D. High serum potassium

C. Low serum calcium A positive Chvostek sign means hypocalcemia, typically after thyroid or parathyroid surgery.

9. A 69 year old woman on long term prednisone has sudden thoracolumbar pain after lifting a light bag. What should you assume first?

A. A posterior duodenal ulcer
B. A simple paraspinal muscle strain
C. A thoracic facet subluxation
D. A vertebral compression fracture

D. A vertebral compression fracture In an older patient on steroids, sudden pain after a minor strain is a fracture until proven otherwise; image before any thrust.

10. An infected patient has a respiratory rate of 24, new confusion and a systolic pressure of 96 mm Hg. What is the correct action?

A. Call emergency services for sepsis
B. Order a CBC and wait for results
C. Recheck vitals at the next visit
D. Send a routine referral letter

A. Call emergency services for sepsis All three qSOFA criteria are met (RR 22 or more, altered mentation, systolic 100 or less). Treat as sepsis and call emergency services.

CHAPTER 4

History, Posture, Gait and Orthopedic Tests of the Spine and Pelvis

Read it in full: **Chapter 4 in the textbook**. Practice it: **Practice exam 2** and the **flashcards**.

What to know

The neuromusculoskeletal history uses OPQRST, the **mechanism of injury**, medications (anticoagulants, steroids, fluoroquinolones), family and social history and a review of systems.

Flexion with rotation under load injures the posterolateral annulus; axial load causes compression or burst fractures at the thoracolumbar junction (and calcaneal fractures travel with lumbar ones); hyperextension stresses the facets and pars. Whiplash is graded by the **Quebec Task Force**: 0 no complaint, I pain only, II plus musculoskeletal signs, III plus neurological signs, IV fracture or dislocation.

Pain types point to tissues. Local somatic pain is aching and localized. **Somatic referred** pain is deep, diffuse, usually above the knee or elbow, with no deficits. **Radicular** pain is sharp, shooting, narrow, often below the knee, worse in the limb than the back, and aggravated by cough and tension tests. **Radiculopathy** is objective loss: dermatomal sensory loss, myotomal weakness, reduced reflex. Myelopathy brings clumsy hands, gait change and upper motor neuron signs.

Mechanical pain changes with posture and load, and morning stiffness lasts under about 30 minutes. Nonmechanical pain is constant and worse at night. **Inflammatory back pain**: onset before 40, insidious, better with exercise, not better with rest, night pain that improves on getting up (four of five support it). **Yellow flags** (fear avoidance, catastrophizing, low mood, passive coping, compensation issues) predict chronicity; blue flags are work perceptions, black flags system obstacles, orange flags psychiatric disorder. STarT Back stratifies risk.

Outcome measures: NPRS (MCID about 2 points or 30%), Oswestry (10 sections scored 0 to 5, expressed as a percent; MCID about 10 points; over 40% is severe), Roland Morris (24 items, better for mild to moderate disability), Neck Disability Index (0 to 50), FABQ (a high work subscale predicts poor return to work) and the Patient Specific Functional Scale.

Posture: the lateral plumb line falls slightly anterior to the lateral malleolus and knee axis, then through the greater trochanter, lumbar bodies, acromion and external auditory meatus. Upper crossed syndrome: tight upper trapezius, levator and pectorals; weak deep neck flexors and lower trapezius. Lower crossed syndrome: tight iliopsoas and erector spinae; weak abdominals and gluteals; anterior pelvic tilt.

Scoliosis is 10 degrees or more by Cobb. In the **Adams forward bend test** a rib hump means rotation and a structural curve; the hump sits on the convex side. A curve that disappears on bending is functional. A scoliometer reading of 5 to 7 degrees is the usual referral threshold. A

painful curve, a left thoracic curve, rapid progression, onset before 10 or neurological signs need MRI (osteoid osteoma, syrinx, tumor, tethered cord). Leg length: true length is ASIS to medial malleolus, apparent is umbilicus to medial malleolus. In the Derifield check, a short leg that stays short with knees flexed suggests anatomical; one that evens or becomes long suggests functional. Supine to long sitting: short to long means posterior innominate rotation.

Gait: stance about 60%, swing about 40%. **Trendelenburg** gait (pelvis drops on the swing side) means a weak gluteus medius (superior gluteal nerve, L5) on the stance side. **Steppage** gait means weak dorsiflexors: L5 radiculopathy or fibular nerve palsy. Test hip abduction and foot inversion: weak in L5 radiculopathy, spared in fibular palsy. Sensory ataxia worsens with eyes closed; magnetic gait suggests normal pressure hydrocephalus.

Cervical: clear trauma first with the **Canadian C spine rule** (age 65+, dangerous mechanism or paresthesias means imaging; low risk patients who can rotate 45 degrees each way need none) or NEXUS. Cyriax: pain on active and passive motion in the same direction implicates inert tissue; pain on resisted motion implicates contractile tissue. The foramen narrows with extension, ipsilateral bending and rotation. **Spurling**, foraminal compression and Jackson tests reproduce arm pain in radiculopathy; local pain only suggests the facet. Distraction relieving pain supports root compression; increasing pain suggests soft tissue injury. Bakody (hand on head) relief suggests C5 or C6. The cluster ULTT 1, rotation under 60 degrees, distraction relief and Spurling: 3 of 4 makes radiculopathy likely. Lhermitte sign means dural or cord irritation; Sharp Purser tests atlantoaxial instability.

Vertebral artery provocation tests (George, DeKleyn, Maigne, Hautant, Barré Liéou, Underburg) have **poor sensitivity**; a negative test does not clear a patient. The history matters most: sudden unusual neck pain or headache with the 5 Ds and 3 Ns, or a Horner syndrome with carotid dissection. Any positive finding means no manipulation and immediate referral.

Thoracic: chest expansion under about 2.5 cm suggests ankylosing spondylitis. **Schepelmann**: pain on the concave side is intercostal neuritis, on the convex side pleuritis or muscle. Soto Hall gives local spinous pain from a posterior ligament or vertebral lesion. **Beevor sign** (umbilicus moves up) localizes to about T10. Thoracic outlet: Adson targets the interscalene triangle, Eden the costoclavicular space, Wright the pectoralis minor space; Roos (3 minutes) is the best single

test. Over 90% of TOS is neurogenic, usually C8 and T1. Reproduction of symptoms, not pulse loss alone, counts.

Lumbopelvic: modified Schöber should lengthen at least about 5 cm. **SLR** is positive with radicular pain below the knee between about 30 and 70 degrees; it is sensitive, while the **crossed SLR** is specific for a (often large) disc herniation. Braggard and bowstring confirm a neural source; slump is more sensitive than SLR; the femoral nerve stretch tests L2 to L4. Kemp with local pain suggests facet. Valsalva, Milgram, Naffziger and the Dejerine triad suggest a space occupying lesion. FABERE groin pain means hip, posterior pain means sacroiliac. Thomas: thigh rises equals iliopsoas; Ely: buttock rises equals rectus femoris; Ober: IT band. Sacroiliac pain is likely with 3 or more of 5 provocation tests. Hoover and 3 or more of 5 Waddell categories flag nonorganic behavior to manage, not proof of malingering.

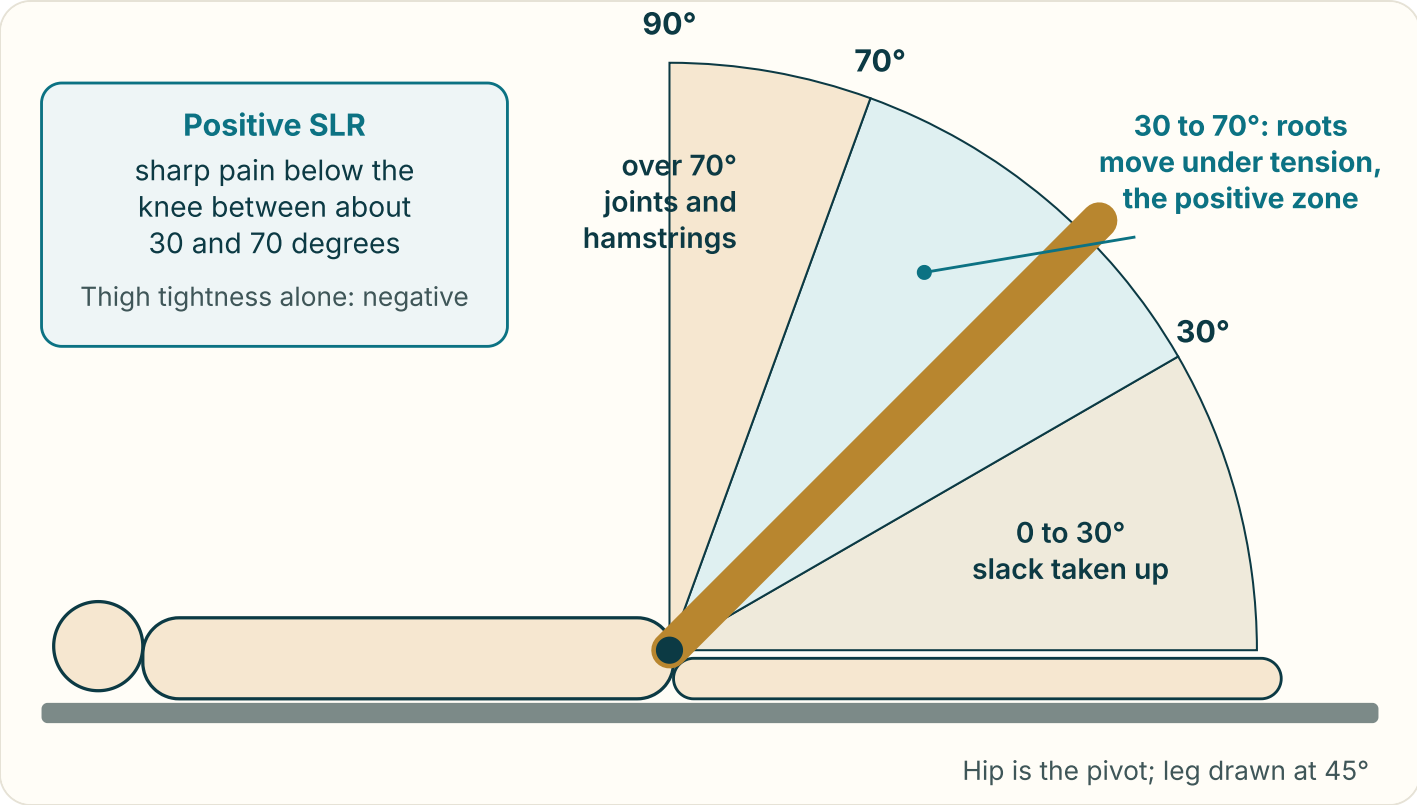

Where the pain appears matters as much as whether it appears. Radicular pain below the knee between about 30 and 70 degrees is the classic positive. Tightness behind the thigh, or pain only past 70 degrees, comes from hamstrings and joints.

LOCK THESE IN

- Radicular pain is sharp and below the knee; somatic referred pain is dull and above it; radiculopathy adds objective deficits.
- Inflammatory back pain: under 40, insidious, better with exercise, not with rest, night pain (4 of 5).
- Adams: rib hump means structural; the hump is on the convex side. Painful or left thoracic curves need MRI.
- Trendelenburg gait means a weak gluteus medius on the stance side; steppage means weak dorsiflexors.
- Spurling arm pain means root; local pain means facet. Distraction relief supports root compression.
- Vertebral artery tests have poor sensitivity; history decides, and any positive means no manipulation.
- SLR positive between 30 and 70 degrees; crossed SLR is specific. Thomas: iliopsoas; Ely: rectus femoris.
- Waddell 3 of 5 and Hoover flag nonorganic behavior; they are not proof of malingering.

Key spinal and pelvic tests

Test	Positive finding	Suggests
Spurling	Radicular arm pain with extension, bend and axial load	Cervical radiculopathy (specific)
Distraction	Relief of arm or neck pain	Root compression or facet capsulitis
Bakody	Hand on head relieves arm pain	C5 or C6 root compression
Lhermitte	Electric shock with neck flexion	Dural or cord irritation (MS, myelopathy)
Soto Hall	Local spinous pain on neck flexion	Posterior ligament or vertebral lesion
Schepelmann	Concave pain; convex pain	Intercostal neuritis; pleuritis or muscle
Beevor	Umbilicus moves up	Lesion around T10
Adson / Eden / Wright	Symptoms with pulse change	Interscalene / costoclavicular / pectoralis minor
SLR	Radicular pain 30 to 70 degrees	L4 to S1 root tension (sensitive)
Crossed SLR	Pain in the symptomatic leg	Disc herniation (specific)
Kemp	Local pain; radiating pain	Facet; nerve root
Milgram, Valsalva, Naffziger	Back or leg pain	Space occupying lesion
FABERE	Groin; posterior pelvis	Hip; sacroiliac
Thomas / Ely / Ober	Thigh rises / buttock rises / leg stays up	Iliopsoas / rectus femoris / IT band

Classification and outcome numbers

Item	Value	Note
Quebec WAD grades	0 none; I pain; II MSK signs; III neuro signs; IV fracture	Whiplash associated disorders
Oswestry	10 sections × 5 points; % = score ÷ 50 × 100	MCID about 10 points; over 40% severe
NPRS	0 to 10	MCID about 2 points or 30%
Neck Disability Index	0 to 50 or percent	Adapted from the Oswestry
Scoliosis	10 degrees or more (Cobb)	Scoliometer 5 to 7 degrees: refer for films
Gait cycle	Stance about 60%, swing about 40%	Two double support periods about 10% each
Modified Schöber	15 cm span should gain at least about 5 cm	Less supports restricted flexion (AS)
Chest expansion	Under about 2.5 cm is reduced	Measured at the fourth intercostal space
SI cluster	3 or more of 5 provocation tests	With pain below L5 and no centralization

Worked cases

WORKED CASE 1 · SCORING AN OSWESTRY AND JUDGING CHANGE

At intake a patient's ten Oswestry sections total 22 points. After six weeks they total 12 points.

STEP 1 · CONVERT INTAKE TO A PERCENT

22 ÷ 50 × 100 = **44%**, over 40%, so severe disability.

STEP 2 · CONVERT FOLLOW UP

12 ÷ 50 × 100 = **24%**.

STEP 3 · FIND THE CHANGE

44 − 24 = 20 percentage points.

STEP 4 · COMPARE WITH THE MCID

The MCID is about 10 points, so a 20 point drop is a clinically important improvement that supports the plan.

IF A SECTION IS SKIPPED

Divide by the maximum for the sections answered (for example 45 for nine sections) so the percentage stays fair.

WORKED CASE 2 · THE MODIFIED SCHÖBER AND CHEST EXPANSION

A 26 year old man has 8 months of low back pain with an hour of morning stiffness that improves with exercise. The 15 cm Schöber span measures 18.5 cm on full flexion. Chest expansion is 2.0 cm.

STEP 1 · SCHÖBER GAIN

18.5 − 15 = 3.5 cm, less than the expected 5 cm: restricted lumbar flexion.

STEP 2 · CHEST EXPANSION

2.0 cm is under about 2.5 cm: reduced, consistent with costovertebral involvement.

STEP 3 · HISTORY

Under 40, insidious, better with exercise, prolonged morning stiffness: an **inflammatory back pain** profile.

STEP 4 · CONCLUDE

This pattern suggests **ankylosing spondylitis**. Request sacroiliac imaging and CRP, and consider HLA-B27 now that pretest probability is high.

WORKED CASE 3 · STEPPAGE GAIT: ROOT OR NERVE

A man who recently lost 15 kg and sits with his legs crossed has a slapping right foot. Ankle dorsiflexion and great toe extension are weak. Hip abduction and foot inversion are strong. Reflexes are normal and the SLR is negative.

STEP 1 · NAME THE GAIT

A foot slap with high stepping is a **steppage gait**: weak dorsiflexors.

STEP 2 · LIST THE CANDIDATES

L5 radiculopathy or a common fibular nerve palsy at the fibular head.

STEP 3 · USE THE L5 FUNCTIONS OUTSIDE THE FIBULAR NERVE

Hip abduction (gluteus medius, superior gluteal nerve) and inversion (tibialis posterior, tibial nerve) are L5 muscles not supplied by the fibular nerve. Both are strong.

STEP 4 · CONCLUDE

A **common fibular nerve palsy**, fitting leg crossing and rapid weight loss. A negative SLR supports it.

WORKED CASE 4 · SLR AND THE DISC

Supine, raising the left leg to 45 degrees reproduces sharp pain into the left lateral foot. Lowering it slightly and dorsiflexing the foot brings the pain back. Raising the right leg also causes left leg pain.

STEP 1 · THE SLR

Radicular pain below the knee at 45 degrees, inside the 30 to 70 degree window: **positive**.

STEP 2 · BRAGGARD

Return of pain with dorsiflexion after lowering confirms a neural source rather than hamstring tightness.

STEP 3 · CROSSED SLR

Pain in the symptomatic leg when the well leg is raised: positive, a **highly specific** sign, often of a large or axillary herniation.

STEP 4 · NEXT

Confirm with the S1 neurological exam (lateral foot sensation, plantarflexion, ankle reflex) and screen for cauda equina red flags.

TRAPS PEOPLE FALL INTO

- **Clearing the neck with a negative vertebral artery test.** These tests have poor sensitivity. The history of sudden unusual pain with brainstem signs decides.
- **Calling buttock and thigh pain radicular.** Somatic referred pain stays above the knee and has no deficits. Radicular pain usually goes below.
- **Calling a hamstring pull at 80 degrees a positive SLR.** Back or posterior thigh tightness, or pain only beyond 70 degrees, is not a positive.
- **Mixing up Thomas and Ely.** Thomas: the thigh rises (iliopsoas). Ely: the buttock rises (rectus femoris).
- **Reading pulse loss alone as thoracic outlet syndrome.** Pulse changes occur in many healthy people. The patient's own symptoms must be reproduced.
- **Labeling a positive Waddell score as malingering.** It flags illness behavior and distress to manage. It can coexist with real disease.
- **Treating a painful left thoracic curve as idiopathic.** Pain, a left thoracic curve, rapid progression or neurological signs need MRI.
- **Putting the rib hump on the concave side.** The rib hump is on the convex side of a structural curve.

Chapter 4 self-test · ten items

1. Two days after being struck from behind at a stoplight, a driver reports neck soreness. You find limited rotation and tender paraspinals; reflexes, strength and sensation are intact. Which whiplash grade applies?

A. Grade I
B. Grade III
C. Grade II
D. Grade IV

C. Grade II Neck complaint plus musculoskeletal signs, without neurological signs or fracture, is grade II.

2. A 31 year old has buttock pain that alternates sides, wakes her in the second half of the night, and improves with exercise but not with rest. What kind of pain is this?

A. Somatic referred facet pain
B. Inflammatory back pain
C. Mechanical discogenic pain
D. Visceral referred pain

B. Inflammatory back pain Onset before 40, improvement with exercise but not rest, night pain and alternating buttock pain fit inflammatory back pain of axial spondyloarthritis.

3. On the Adams forward bend test, a curve seen standing disappears completely. What does this indicate?

A. A congenital curve
B. An osteoid osteoma
C. A structural curve
D. A functional curve

D. A functional curve A curve that disappears on bending has no rotation; it is functional, from leg length difference, spasm, pain or habit.

4. While standing on the right leg, the patient's left hip drops. Which muscle is weak?

A. Right gluteus medius
B. Left gluteus medius
C. Left iliopsoas
D. Right gluteus maximus

A. Right gluteus medius The stance side abductor holds the pelvis level. Weakness of the right gluteus medius lets the left (swing) side drop.

5. Extension, right lateral flexion and axial pressure cause pain down the right arm into the thumb. What is the test and its meaning?

A. Distraction, right muscle strain
B. Spurling, right C6 root compression
C. Jackson, right C8 facet syndrome
D. Spurling, right facet capsulitis

B. Spurling, right C6 root compression Spurling reproduces radicular arm pain when the foramen narrows on the symptomatic side. Thumb symptoms fit C6. Local neck pain only would suggest the facet.

6. When you bend a seated patient's head forward, she feels a jolt like electricity run down her back into both legs. What does this suggest?

A. Dural or cord irritation
B. Vertebral artery stenosis
C. Cervical facet syndrome
D. Thoracic outlet compression

A. Dural or cord irritation Lhermitte sign points to the cord or dura: multiple sclerosis, cervical myelopathy, a cord tumor or B12 deficiency.

7. Which statement about vertebral artery provocation tests is correct?

A. They predict stroke with high accuracy
B. A negative test rules out a dissection
C. A negative test does not clear manipulation
D. A positive test permits gentle thrust

C. A negative test does not clear manipulation These tests have poor sensitivity and cannot predict dissection. The history matters most, and any positive finding means no manipulation.

8. Seated with both arms overhead, the patient laterally flexes to the left and feels sharp pain on the left side of the chest. What is suggested?

A. A posterior rib subluxation
B. Pleuritis on the left
C. Intercostal muscle strain
D. Intercostal neuritis

D. Intercostal neuritis In the Schepelmann test, pain on the concave (compressed) side suggests intercostal neuritis; convex side pain suggests pleuritis or muscle.

9. Raising the asymptomatic right leg reproduces the patient's left sciatic pain. What does this most strongly suggest?

A. Tight right hamstrings
B. A left sacroiliac joint sprain
C. A left lumbar facet syndrome
D. A left lumbar disc herniation

D. A left lumbar disc herniation The crossed (well leg) SLR is highly specific for disc herniation, often a large or axillary one.

10. In the supine Thomas test, the patient hugs the left knee and the right thigh rises off the table with the knee staying flexed. What is tight?

A. Right iliopsoas
B. Right iliotibial band
C. Right rectus femoris
D. Left hamstrings

A. Right iliopsoas Thigh rising points to the iliopsoas. Knee extension would add rectus femoris tightness; abduction would point to the TFL and IT band.

ONE PAGE

Cram sheet

Everything from chapters 3 and 4 in one place. Cover the right columns and see if you can rebuild each row.

Numbers to know

Item	Value	Note
AAA	3 cm or more; repair threshold about 5.5 cm	Screen men 65 to 75 who ever smoked
Dissection	Arm systolic difference over 20 mm Hg	Stanford A ascending: surgery
ABI	0.90 or less PAD; under about 0.4 severe	Over 1.4 calcified
Asthma reversibility	FEV_1 up 12% and 200 mL	COPD: FEV_1/FVC under 0.70
CURB 65 / qSOFA	2 or more: hospital / 2 of 3: sepsis risk	qSOFA: RR 22, mentation, SBP 100
Diabetes	Fasting 126; HbA1c 6.5%; OGTT 200	Hypoglycemia: about 15 g fast sugar
Osteoporosis	T score −2.5 or fragility fracture	Women 65+ screened
Metabolic syndrome	3 of 5 criteria	BP 130/85; TG 150; glucose 100
Oswestry	Score ÷ 50 × 100; MCID about 10	Over 40% severe
SLR	Positive 30 to 70 degrees	Pain beyond 70 is joints and hamstrings
Schöber / expansion	Gain under 5 cm / under 2.5 cm	Ankylosing spondylitis
Scoliosis	Cobb 10 degrees; scoliometer 5 to 7	Rib hump on the convex side

Rules that decide questions

Topic	The rule
Emergency flag	One flag in the vignette means emergency referral, not more tests.
Claudication	Vascular: standing still, bicycle pain, low ABI. Neurogenic: sitting or flexion, shopping cart sign.
Myeloma	CRAB, punched out lesions, pedicle spared early, cold bone scan.
Visceral pain	Unchanged by movement; tied to eating, urination, bowels, menses.
Calcium signs	Chvostek cheek, Trousseau tourniquet: hypocalcemia.
Pain types	Radicular sharp below the knee; somatic referred dull above it.
Cervical tests	Arm pain means root, local pain means facet; distraction relief supports root.
Artery tests	Poor sensitivity; history decides; positive means no manipulation.
Thoracic outlet	Adson scalene, Eden costoclavicular, Wright pectoralis minor; Roos best.
Hip and SI	FABERE groin hip, back SI; Thomas iliopsoas; Ely rectus femoris; Ober IT band.
Nonorganic	Waddell 3 of 5 and Hoover: manage, do not dismiss.

An independent study aid, not affiliated with or endorsed by the National Board of Chiropractic Examiners.
Dr. Garg Learning · CC BY-SA 4.0