Final Study Guide

This guide covers all fourteen chapters. Each chapter here is shorter than in the exam guides: four paragraphs of what to know, the points to lock in, a table, one worked case, the traps and six new board-style items. If a chapter feels shaky, go back to its study guide for the full treatment. The diagrams repeat the ones from those guides, because a picture you have already studied is the fastest way back into a chapter. The long cram sheet at the end pulls every level, lab pattern, crossing point and formula into one place. Two chapters a day puts the whole review inside a week.

WHAT THIS GUIDE COVERS

- General anatomy: chapters 1 and 2 (planes, landmarks, skin and bones; muscles, plexuses, nerve lesions and vessels).
- Visceral and spinal anatomy: chapters 3 and 4 (heart, lungs, gut, kidney and endocrine glands; the vertebral column, disc, ligaments and muscles).
- Neuroanatomy: chapters 5 and 6 (cord, tracts, brainstem and brain; spinal nerves, cranial nerves, autonomics and the special senses).
- Physiology: chapters 7, 8 and 9 (membranes, synapses, reflexes and muscle; heart, lungs and kidneys; gut, endocrine, reproduction and exercise).
- Chemistry: chapters 10 and 11 (biomolecules, proteins, enzymes and nucleic acids; metabolism, hormones, vitamins and minerals).
- Pathology and microbiology: chapters 12, 13 and 14 (general pathology; systemic disease; immunology, organisms, epidemiology and infection control).

CHAPTER 1

Topographical Anatomy and the Appendicular Skeleton

Read it in full: **Chapter 1 in the review book**. Practice it: **the practice exams** (Exam 1 covers this chapter) and **the flashcards**.

What to know

Everything is described from the **anatomical position**. Movement happens in a plane about the axis perpendicular to it: flexion and extension sagittal, abduction and adduction frontal, rotation transverse. The thumb is rotated 90 degrees, so it flexes in the frontal plane.

Tie landmarks to levels: hyoid C3, thyroid cartilage C4, cricoid C6, vertebra prominens C7, scapular spine T3, inferior angle T7, **sternal angle T4 to T5** (rib 2, carina, both ends of the aortic arch, azygos into SVC), xiphisternum T9, transpyloric plane L1, umbilicus L3 to L4 and T10, iliac crests L4, PSIS S2.

Skin: the epidermis is avascular keratinized stratified squamous epithelium (basale, spinosum, granulosum, lucidum in thick skin, corneum). Eccrine glands are sympathetic cholinergic, sebaceous glands holocrine. Dermatome anchors: C6 thumb, C7 middle finger, C8 little finger, T4 nipple, T10 umbilicus, L4 medial leg, L5 great toe, S1 lateral foot.

Bone and joint facts the board reuses: axillary nerve at the surgical neck, radial nerve in the spiral groove, ulnar nerve behind the medial epicondyle; scaphoid fractures and risks avascular necrosis, lunate dislocates; femoral neck angle about 125 degrees with the head fed by the medial circumflex femoral artery; shoulders dislocate anteriorly and hips posteriorly; the ACL stops anterior tibial translation; the ATFL tears first in an inversion sprain.

Surface landmarks and their vertebral levels

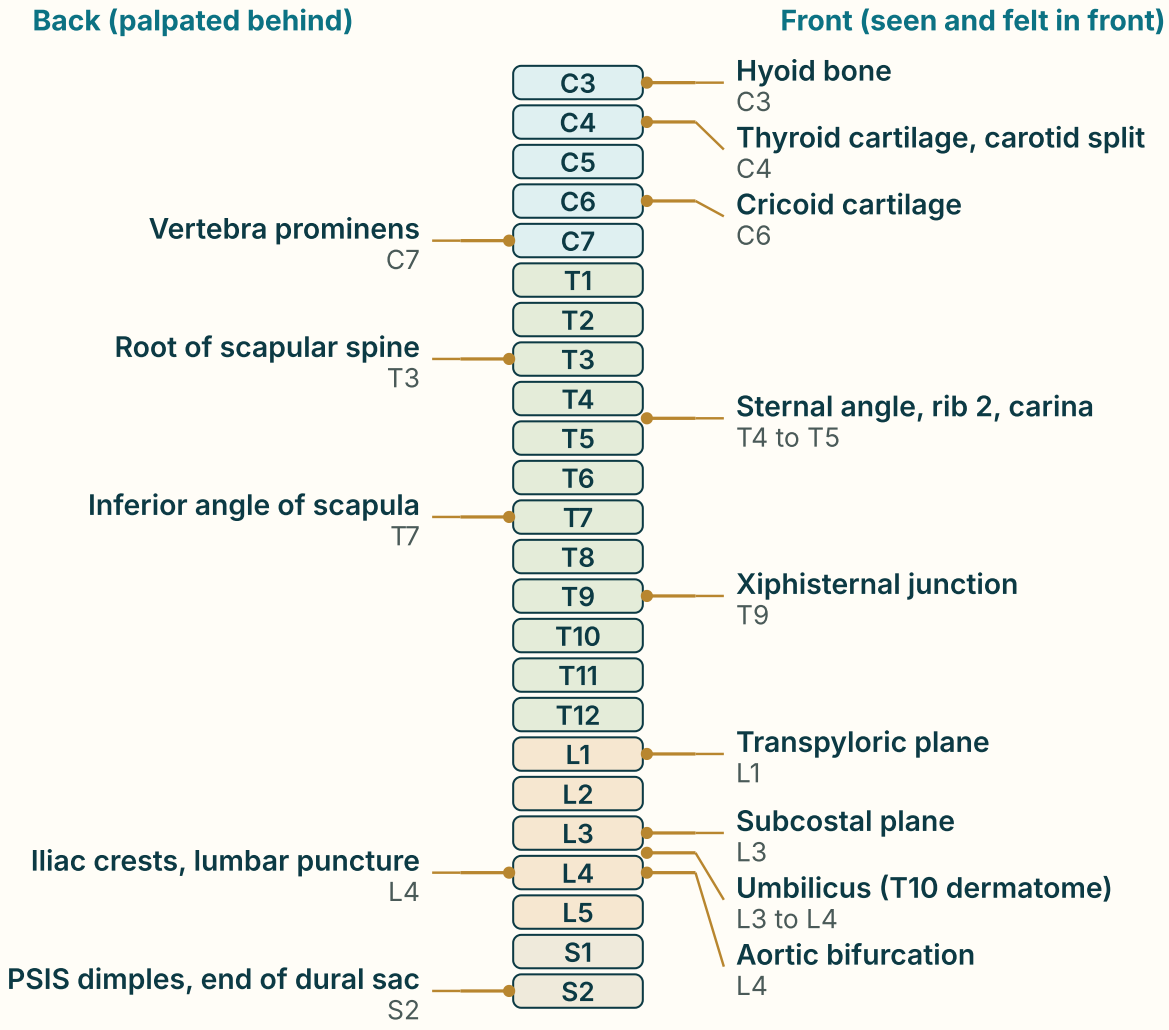

Board favorite: the sternal angle plane (T4 to T5) marks rib 2, the tracheal bifurcation, both ends of the aortic arch and the azygos entering the SVC.

Landmarks become levels. Tie every surface landmark to a vertebra and you can locate viscera, vessels and spinal segments from the outside.

LOCK THESE IN

- Abduction: frontal plane, anteroposterior axis.
- Sternal angle is the T4 to T5 plane.
- Stratum lucidum only in thick skin; eccrine glands are sympathetic cholinergic.
- Scaphoid fracture risks AVN; Colles is dorsal, Smith volar.
- Close-packed: knee extension, ankle dorsiflexion, hip extension with medial rotation.
- Hip capsular pattern: medial rotation, flexion, abduction.

Landmarks and levels

Landmark	Level	Use
Cricoid cartilage	C6	Larynx to trachea
Sternal angle	T4 to T5	Carina, aortic arch
Transpyloric plane	L1	Renal hila, SMA origin
Iliac crests	L4	Lumbar puncture
PSIS dimples	S2	End of the dural sac

Worked case

CASE 1.1 · SNUFFBOX TENDERNESS AFTER A FALL

A young adult falls on an outstretched hand and is tender in the anatomical snuffbox. The first film is normal.

STEP 1 · NAME THE FLOOR

The scaphoid lies in the snuffbox floor.

STEP 2 · RECALL THE SUPPLY

Blood enters distally, so a waist fracture can leave the proximal pole avascular.

STEP 3 · ACT

Treat as an occult scaphoid fracture: immobilize, repeat imaging or MRI.

TRAPS PEOPLE FALL INTO

- **Dermatome versus nerve.** A median nerve lesion gives a nerve pattern, not a band.
- **Anatomical versus surgical neck.** Fractures and the axillary nerve belong to the surgical neck.
- **Cruciate names.** They are named for their tibial attachments.

Chapter 1 self-test · six board-style items

1. A plane through the sternal angle also crosses

A. the origin of the SMA
B. the tracheal bifurcation
C. the pyloric sphincter
D. the carotid bifurcation

B. the tracheal bifurcation The T4 to T5 plane holds rib 2, the carina and both ends of the aortic arch.

2. Which epidermal layer is found only in thick skin?

A. Stratum lucidum
B. Stratum spinosum
C. Stratum corneum
D. Stratum granulosum

A. Stratum lucidum Palms and soles have five layers, including the clear stratum lucidum.

3. Numbness of the great toe and dorsum of the foot maps to

A. S1
B. L4
C. L5
D. S2

C. L5 L4 is the medial leg and malleolus, S1 the lateral foot.

4. A midshaft humeral fracture with a wrist drop and strong triceps injures

A. the median nerve at the elbow
B. the ulnar nerve at the elbow
C. the axillary nerve at the neck
D. the radial nerve at midshaft

D. the radial nerve at midshaft Triceps branches leave the nerve above the groove, so they are spared.

5. Which joint is a symphysis?

A. The pubic symphysis
B. The growth plate
C. The distal tibiofibular joint
D. The first sternocostal joint

A. The pubic symphysis Symphyses are midline fibrocartilage joints; the others are a synchondrosis and a syndesmosis.

6. Which ligament fails first in an inversion sprain?

A. Deltoid
B. Anterior talofibular
C. Posterior talofibular
D. Calcaneofibular

B. Anterior talofibular Plantarflexion loosens the mortise and the ATFL is the weakest lateral ligament.

CHAPTER 2

Appendicular Muscles, Nerves and Vessels

Read it in full: **Chapter 2 in the review book**. Practice it: **the practice exams** (Exam 1 covers this chapter) and **the flashcards**.

What to know

Scapular control: serratus anterior (long thoracic nerve) palsy gives **medial winging**; trapezius (spinal accessory) palsy gives a weak shrug and lateral winging. The rotator cuff centers the humeral head; supraspinatus starts abduction and is torn most often, and only subscapularis rotates medially.

Forearm flexors belong to the median nerve except flexor carpi ulnaris and medial FDP (ulnar); all extensors belong to the radial nerve, mostly the posterior interosseous branch. In the hand the median nerve supplies **LOAF** and the ulnar nerve everything else. The carpal tunnel holds the median nerve and nine tendons and spares thenar skin; Guyon canal holds the ulnar nerve and artery and spares dorsal ulnar skin.

The brachial plexus runs roots, trunks, divisions, cords, branches. All posterior divisions make the posterior cord (axillary and radial nerves); the median nerve takes a root from the lateral and medial cords. **Erb palsy** (C5, C6) gives the waiter's tip; **Klumpke palsy** (C8, T1) gives a claw hand, sometimes with Horner syndrome. The ulnar paradox: a proximal lesion claws less.

Lower limb: the **superior gluteal nerve** holds the pelvis level (Trendelenburg sign shows weakness on the stance side); the inferior gluteal nerve supplies gluteus maximus. Thigh compartments are femoral, obturator and sciatic; the leg is deep fibular (dorsiflexion), superficial fibular (eversion) and tibial (plantarflexion). **Foot drop with intact inversion and ankle reflex** is a common fibular lesion at the fibular neck, not L5. Arteries: femoral, popliteal, then anterior tibial to dorsalis pedis and posterior tibial behind the medial malleolus; the femoral triangle reads NAVEL.

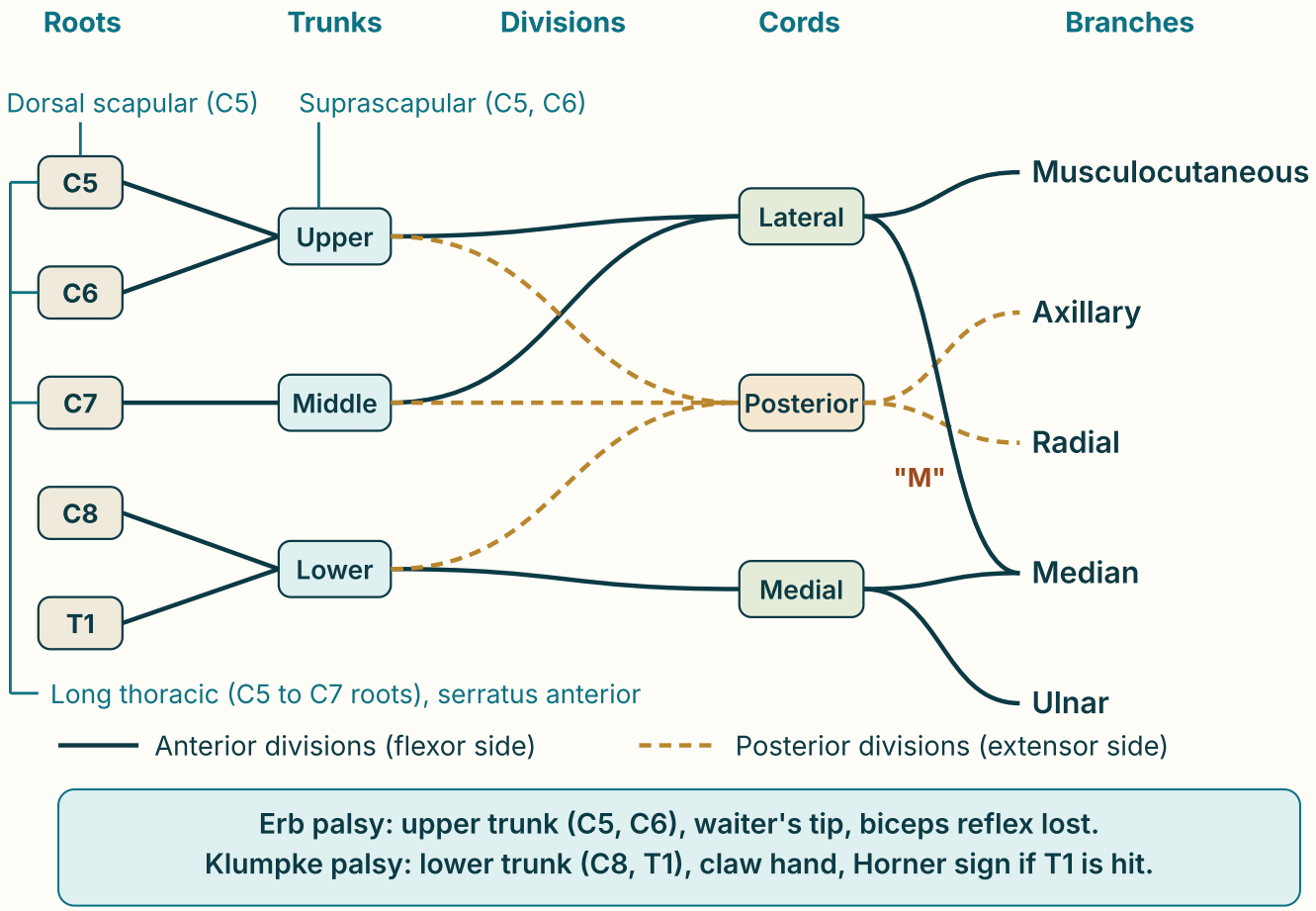

Posterior divisions make the extensor nerves. Every posterior division feeds the posterior cord, so the axillary and radial nerves supply the extensor side; the median nerve takes a root from both the lateral and medial cords.

LOCK THESE IN

- Medial winging: serratus anterior. Lateral winging: trapezius.
- Supraspinatus initiates abduction and tears most often.
- Median nerve in the hand: LOAF; ulnar nerve: the rest.
- Carpal tunnel spares thenar skin; Guyon canal spares dorsal ulnar skin.
- Trendelenburg means weak abductors on the standing side.
- Reflexes: biceps C5 to C6, brachioradialis C6, triceps C7, patellar L4, Achilles S1.

Nerve lesions to recognize

Lesion	Finding	Clue
Radial at midshaft	Wrist drop	Triceps spared
Median at wrist	Thenar atrophy	Thenar skin spared
Ulnar at wrist	Deeper claw	Dorsal ulnar skin spared
Axillary	Weak abduction past 15 degrees	Numb regimental badge
Common fibular	Foot drop, weak eversion	Inversion and ankle reflex normal

Worked case

CASE 2.1 · WHICH SIDE IS WEAK?

Standing on the right leg, a patient's left hip drops.

STEP 1 · ASK WHO HOLDS THE PELVIS

The stance-side abductors.

STEP 2 · NAME THE MUSCLES AND NERVE

Right gluteus medius and minimus, right superior gluteal nerve.

STEP 3 · THINK OF CAUSES

Misplaced gluteal injection, hip surgery, L5 radiculopathy.

TRAPS PEOPLE FALL INTO

- **Brachioradialis.** Radial nerve, extensor compartment, but it flexes the elbow.
- **Ulnar paradox.** Proximal lesions claw less because medial FDP is also out.
- **Foot drop.** Check inversion and the ankle reflex before blaming L5.

Chapter 2 self-test · six board-style items

1. Weak shrug with lateral scapular winging after neck surgery points to

A. the spinal accessory nerve
B. the suprascapular nerve
C. the dorsal scapular nerve
D. the long thoracic nerve

A. the spinal accessory nerve CN XI crosses the posterior triangle superficially and supplies trapezius.

2. Which structure runs inside the carpal tunnel?

A. Palmaris longus tendon
B. Flexor pollicis longus
C. The ulnar nerve here
D. The ulnar artery here

B. Flexor pollicis longus The tunnel holds the median nerve and nine flexor tendons; the ulnar structures pass over the retinaculum.

3. Erb palsy involves which roots?

A. C4 and C5
B. C7 alone
C. C5 and C6
D. C8 and T1

C. C5 and C6 Upper trunk injury gives the waiter's tip and a lost biceps reflex.

4. A cyclist has weak interossei and a numb palmar little finger with normal FCU strength. Where is the lesion?

A. C8 root
B. Ulnar nerve at the cubital tunnel
C. Lower trunk
D. Ulnar nerve at Guyon canal

D. Ulnar nerve at Guyon canal FCU and the dorsal cutaneous branch leave the nerve in the forearm, so sparing them localizes to the wrist.

5. Which nerve supplies the quadriceps?

A. Tibial
B. Obturator
C. Femoral
D. Superior gluteal

C. Femoral The femoral nerve comes from posterior divisions of L2 to L4 and extends the knee.

6. The dorsalis pedis pulse continues which artery?

A. Posterior tibial
B. Anterior tibial
C. Fibular
D. Popliteal directly

B. Anterior tibial It is felt lateral to the extensor hallucis longus tendon on the dorsum of the foot.

CHAPTER 3

Visceral Anatomy

Read it in full: **Chapter 3 in the review book**. Practice it: **the practice exams** (Exam 2 covers this chapter) and **the flashcards**.

What to know

The sternal angle plane (T4 to T5) splits the mediastinum. The right ventricle forms the anterior surface, the left atrium the base and the left ventricle the apex at the left fifth intercostal space. The **RCA** usually supplies the SA and AV nodes and the inferior wall; the **LAD** is the vessel most often occluded; dominance follows the posterior interventricular artery. Cardiac pain refers to T1 to T4 or T5.

Levels: **IVC through the diaphragm at T8, esophagus T10, aorta T12**; celiac trunk T12, SMA L1, renals L1 to L2, gonadals L2, IMA L3, bifurcation L4. The left gonadal and suprarenal veins drain into the left renal vein. The valveless Batson plexus carries tumor to the spine. The thoracic duct drains all but the right upper quadrant into the left venous angle.

Airway and lungs: the posterior cricoarytenoid is the only abductor of the cords; the right main bronchus is short, wide and vertical; the right lung has three lobes and the left two with a lingula; the pleura lies two ribs below the lung at every line. The diaphragm is phrenic (C3 to C5), so its irritation refers to the shoulder.

Abdomen and pelvis: the gut follows foregut (celiac, epigastric), midgut (SMA, periumbilical) and hindgut (IMA, suprapubic). Retroperitoneal organs are SAD PUCKER. The portal vein forms behind the pancreatic neck and decompresses through four portocaval anastomoses. Kidneys span T12 to L3 and stones lodge at the UPJ, pelvic brim and UVJ. **S2 to S4** run bladder, bowel and sexual function. The pituitary sits under the optic chiasm; each adrenal has three arteries and one vein.

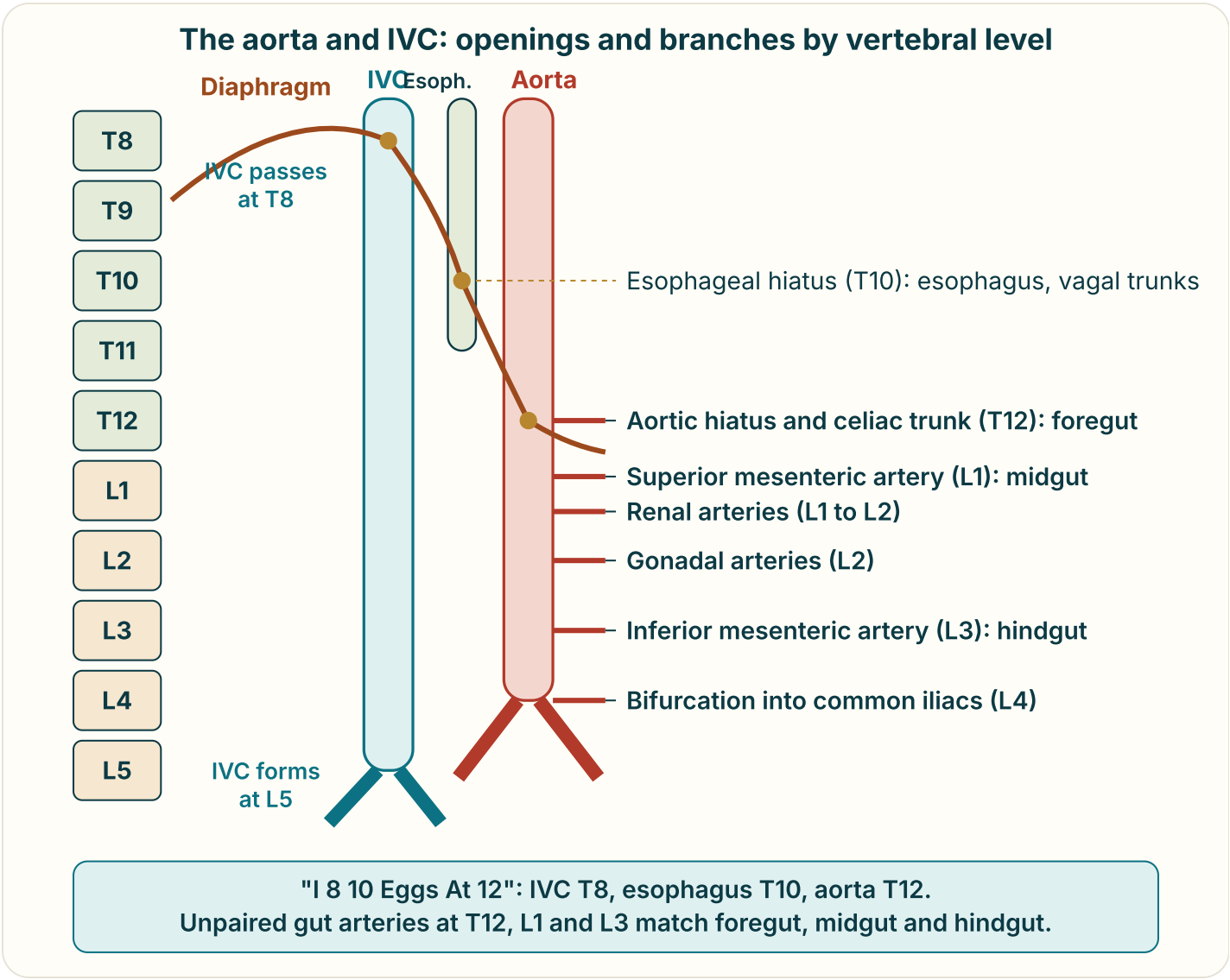

Levels organize the abdomen. The diaphragm openings and the unpaired gut arteries fall at fixed vertebral levels, which lets you find them on the surface and on film.

LOCK THESE IN

- RCA: nodes and inferior wall. LAD: anterior wall and septum.
- I 8 10 Eggs At 12 for the diaphragm openings.
- Celiac T12, SMA L1, IMA L3, bifurcation L4.
- Lung 6, 8, 10; pleura 8, 10, 12.
- Portocaval sites: esophageal, paraumbilical, anorectal, retroperitoneal.
- Stones lodge at UPJ, pelvic brim and UVJ.

Referred visceral pain

Organ	Segments	Felt at
Heart	T1 to T5	Substernal, left arm, jaw
Diaphragm	C3 to C5 (phrenic)	Shoulder
Gallbladder	T6 to T9	Right upper quadrant, right scapula
Appendix (early)	T10	Periumbilical
Kidney and ureter	T11 to L2	Loin to groin

Worked case

CASE 3.1 · SHOULDER PAIN THAT IS NOT THE SHOULDER

A patient has right shoulder pain with full painless motion, worse after fatty meals.

STEP 1 · NOTE THE MISMATCH

Full painless motion argues against a shoulder cause.

STEP 2 · RECALL THE REFERRAL

Diaphragmatic irritation travels on the phrenic nerve to C4.

STEP 3 · ACT

Examine the right upper quadrant and refer rather than treating the shoulder.

TRAPS PEOPLE FALL INTO

- **Base of the heart.** It faces posteriorly and is mostly left atrium.
- **Gonadal veins.** Left to the left renal vein, right straight to the IVC.
- **Pleural edge.** It dips below rib 12 medially.

Chapter 3 self-test · six board-style items

1. An inferior wall infarct with heart block suggests occlusion of

A. the right coronary artery
B. the left main artery
C. the circumflex artery
D. the anterior descending

A. the right coronary artery The RCA usually supplies the inferior wall and both nodal arteries.

2. Which structure passes the diaphragm at T10?

A. The aorta and duct at T12
B. The inferior vena cava
C. The azygos vein at T12
D. Esophagus and vagal trunks

D. Esophagus and vagal trunks IVC at T8, esophagus at T10, aorta at T12.

3. An aspirated object in an upright adult most often lodges in

A. the lingular segment
B. the left main bronchus
C. the right main bronchus
D. the trachea itself

C. the right main bronchus The right bronchus is wider, shorter and more vertical.

4. Which organ is retroperitoneal?

A. The stomach
B. The ascending colon
C. The spleen
D. The transverse colon

B. The ascending colon SAD PUCKER includes the ascending and descending colon.

5. Hematemesis in cirrhosis comes from which anastomosis?

A. Paraumbilical with epigastric veins
B. Colic with lumbar veins
C. Superior with inferior rectal veins
D. Left gastric with esophageal veins

D. Left gastric with esophageal veins Esophageal varices form where portal and azygos systems meet.

6. A new left varicocele that does not empty when supine suggests

A. an inguinal hernia on the left
B. a tumor in the renal vein
C. a right adrenal mass
D. testicular torsion

B. a tumor in the renal vein The left testicular vein drains into the left renal vein.

CHAPTER 4

The Vertebral Column

Read it in full: **Chapter 4 in the review book**. Practice it: **the practice exams** (Exam 2 covers this chapter) and **the flashcards**.

What to know

A typical vertebra has a body and an arch with seven processes; the **pars interarticularis** is the site of spondylolysis. Transverse foramina mean cervical, costal facets thoracic, mammillary processes lumbar. C1 has no body or spinous process, C2 carries the dens, C7 is the prominens, T12 is transitional and L5 is wedge shaped.

There are **23 discs**. The nucleus resists compression, the annulus tension and torsion, and the annulus is thinnest posterolaterally. Only the outer third is innervated, posteriorly by the sinuvertebral nerve. Facet planes: cervical 45, thoracic 60, lumbar 90 degrees, which is why rotation is free in the thorax and limited in the low back.

Cervical nerves exit above their vertebra (C8 between C7 and T1); below that each exits below its vertebra. A **posterolateral L4 to L5 herniation hits the traversing L5 root**; a far lateral herniation hits the exiting L4 root. Extension and ipsilateral lateral flexion narrow the foramen.

The ALL limits extension; the PLL, ligamentum flavum, interspinous and supraspinous ligaments limit flexion; the lumbar PLL is narrow. The transverse ligament holds the dens, so an **ADI over 3 mm** in an adult (5 mm in a child) means instability. All intrinsic back muscles are supplied by dorsal rami; the transversospinalis group rotates to the opposite side. Vertebrae form by resegmentation, which is why there are eight cervical nerves but seven cervical vertebrae.

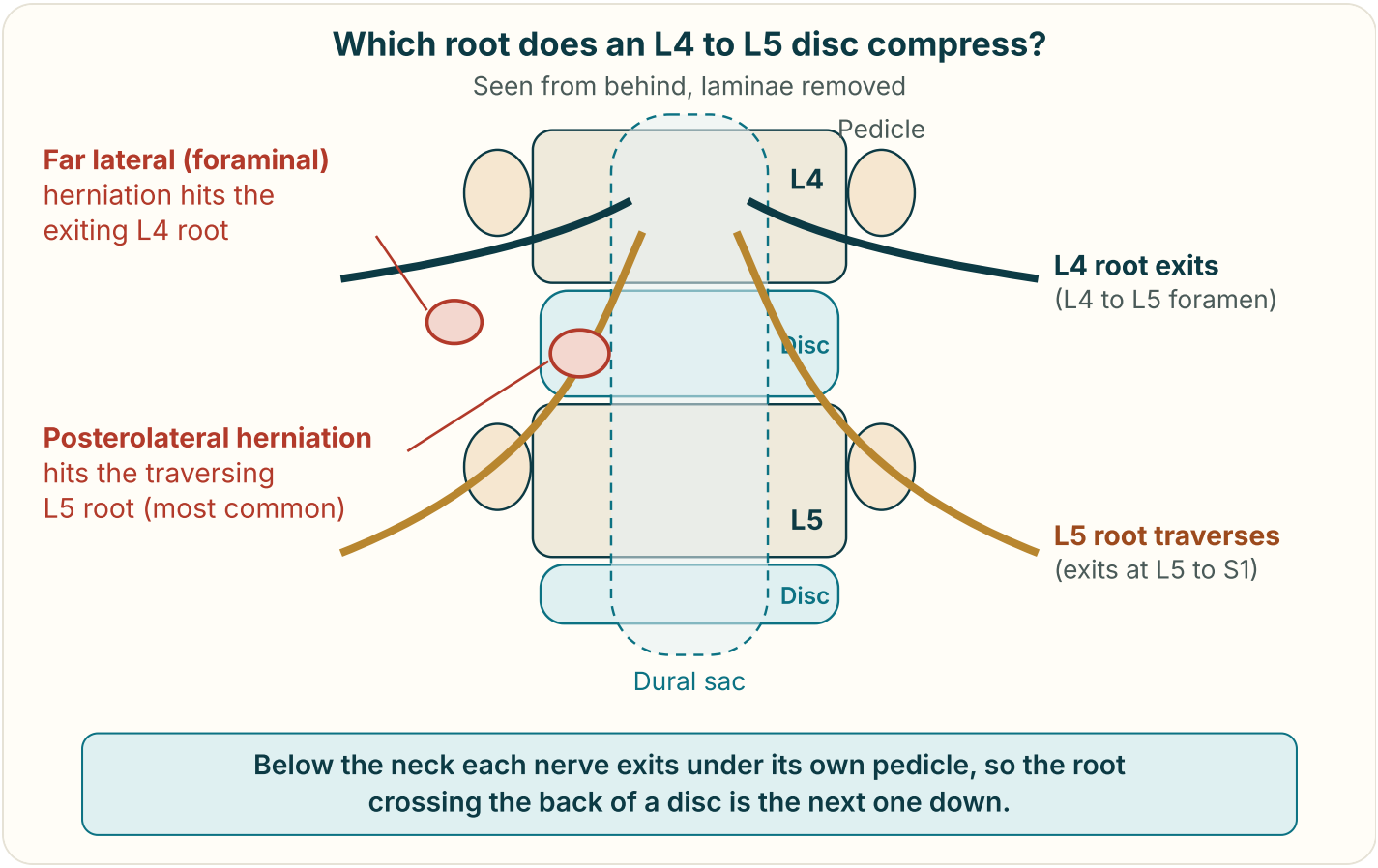

The traversing root takes the hit. A posterolateral L4 to L5 herniation compresses L5; only a far lateral herniation reaches the exiting L4 root.

LOCK THESE IN

- Transverse foramen cervical, costal facets thoracic, mammillary lumbar.
- Only the outer annulus is innervated (sinuvertebral nerve).
- Facet planes 45, 60, 90 degrees.
- L4 to L5 posterolateral herniation compresses L5.
- ADI over 3 mm in an adult contraindicates upper cervical manipulation.
- Multifidus and external oblique rotate to the opposite side.

Ligaments and limits

Ligament	Limits	Note
Anterior longitudinal	Extension	Widest in the lumbar spine
Posterior longitudinal	Flexion	Narrow in the lumbar spine
Ligamentum flavum	Flexion	Elastic; buckles in stenosis
Transverse ligament	Anterior translation of C1	Fails in RA and Down syndrome
Alar ligaments	Head rotation	Checked by the alar stress test

Worked case

CASE 4.1 · NAMING THE COMPRESSED ROOT

A patient has pain into the dorsum of the foot and great toe with a posterolateral L4 to L5 herniation.

STEP 1 · APPLY THE EXIT RULE

L4 exits under the L4 pedicle, above the disc.

STEP 2 · FOLLOW THE TRAVERSING ROOT

L5 crosses the back of the L4 to L5 disc.

STEP 3 · MATCH THE DERMATOME

Dorsum and great toe is L5, so the traversing root is compressed.

TRAPS PEOPLE FALL INTO

- **Disc count.** None between occiput and C1 or C1 and C2.
- **Vertebral artery entry.** It usually enters at C6, not C7.
- **Spondylolysis.** It is a fatigue fracture of the pars, most often at L5.

Chapter 4 self-test · six board-style items

1. A vertebra with a single full costal facet and no transverse costal facet is

A. T11 or T12
B. T5 or T6
C. L1 or L2
D. T1 or T2

A. T11 or T12 Floating ribs articulate with the body or pedicle only.

2. Which part of the disc has nerve endings?

A. The endplate center
B. The whole nucleus
C. The outer annulus
D. The inner annulus

C. The outer annulus The sinuvertebral nerve supplies the outer posterior annulus and PLL.

3. A C5 to C6 posterolateral disc most often compresses

A. the C8 root
B. the C5 root
C. the C7 root
D. the C6 root

D. the C6 root Cervical roots exit above their numbered vertebra.

4. Which region most limits axial rotation?

A. Cervical
B. Lumbar
C. Sacral
D. Thoracic

B. Lumbar Near-sagittal lumbar facets lock in rotation.

5. An adult ADI of 6 mm means

A. the transverse ligament failed
B. the alar ligaments are lax
C. the dens must be fractured
D. this is a normal variant

A. the transverse ligament failed Over 3 mm in an adult indicates atlantoaxial instability.

6. Which muscle rotates the trunk to the opposite side?

A. Longissimus
B. Splenius
C. Multifidus
D. Internal oblique

C. Multifidus The transversospinalis group and the external oblique rotate contralaterally.

CHAPTER 5

The Spinal Cord and Central Nervous System

Read it in full: **Chapter 5 in the review book**. Practice it: **the practice exams** (Exam 3 covers this chapter) and **the flashcards**.

What to know

The spinal epidural space is real (fat and the Batson plexus); the cranial one is potential. Epidural hematomas are arterial and biconvex with a lucid interval; subdural hematomas are venous and crescent shaped. CSF flows lateral ventricle, Monro, third ventricle, **aqueduct**, fourth ventricle, Magendie and Luschka, then granulations.

The cord ends at **L1 to L2** and the dural sac at S2, so lumbar puncture at L3 to L5 meets only cauda equina roots. The lateral horn exists only T1 to L2 and Clarke nucleus C8 to L3. The anterior spinal artery feeds the front two thirds, reinforced by the artery of Adamkiewicz (left, T9 to T12).

Three crossing points: the **DCML** crosses in the lower medulla, the **spinothalamic tract** within one or two segments, and the **corticospinal tract** at the pyramids. From these follow Brown Sequard (ipsilateral motor and vibration loss, contralateral pain loss), central cord (arms worse than legs), anterior cord (vibration spared) and syringomyelia (cape-like loss).

Brainstem strokes give crossed signs, and the cranial nerve gives the level: Weber in the midbrain, Wallenberg in the lateral medulla with no weakness. Cortically, the MCA spares the leg, the ACA takes it, and the PCA gives hemianopia with macular sparing. The cerebellum controls the ipsilateral body. Screen for vertebrobasilar ischemia before cervical manipulation.

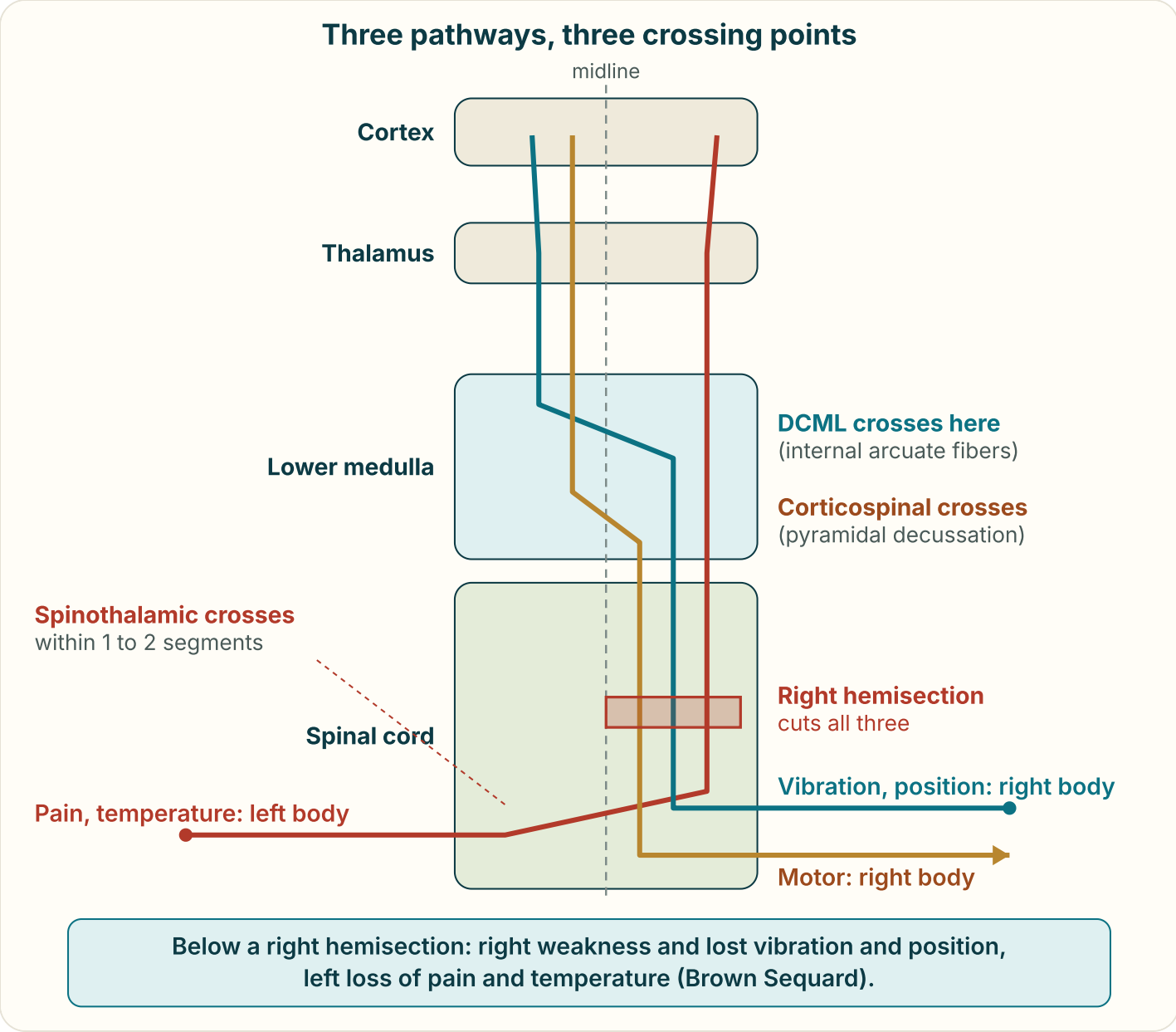

Crossing points decide the side. The DCML crosses in the medulla, the corticospinal tract at the pyramids and the spinothalamic tract within a segment or two, so a hemisection splits the deficits.

LOCK THESE IN

- Cord ends L1 to L2; dural sac S2.
- DCML crosses in the medulla; spinothalamic within segments; corticospinal at the pyramids.
- Brown Sequard: motor and vibration ipsilateral, pain contralateral.
- Central cord: hyperextension, arms worse than legs.
- Wallenberg has no hemiplegia.
- MCA face and arm; ACA leg; PCA vision.

Cord syndromes

Syndrome	Damaged	Finding
Brown Sequard	Half the cord	Split deficits by side
Central cord	Central gray, medial fibers	Arms worse than legs
Anterior cord	Anterior two thirds	Vibration and position spared
Syringomyelia	Anterior white commissure	Cape-like pain loss
Subacute combined degeneration	Dorsal columns and corticospinal	Romberg positive, Babinski

Worked case

CASE 5.1 · SPLIT DEFICITS AFTER A STAB WOUND

Weakness and lost vibration in the left leg; lost pinprick in the right leg.

STEP 1 · USE THE IPSILATERAL TRACTS

Motor and vibration mark the side of the lesion: the left half of the cord.

STEP 2 · USE THE CROSSED TRACT

Spinothalamic fibers crossed already, so pain is lost on the right.

STEP 3 · NAME IT

Left Brown Sequard syndrome.

TRAPS PEOPLE FALL INTO

- **Romberg.** It means proprioceptive loss, not cerebellar disease.
- **Hydrocephalus level.** A normal fourth ventricle puts the block at the aqueduct.
- **Facial weakness.** Cortical lesions spare the forehead.

Chapter 5 self-test · six board-style items

1. A biconvex clot that stops at sutures after temporal trauma comes from

A. the middle meningeal artery
B. a berry aneurysm at the ACoA
C. the superior sagittal sinus
D. the bridging cerebral veins

A. the middle meningeal artery Epidural hematomas are arterial and limited by sutures.

2. In an adult the spinal cord ends at about

A. the T12 vertebra
B. the L3 vertebra
C. the S2 segment
D. the L1 to L2 disc

D. the L1 to L2 disc The dural sac continues to S2, creating the lumbar cistern.

3. Which tract crosses in the lower medulla?

A. The spinothalamic tract
B. The spinocerebellar tract
C. The dorsal column pathway
D. The corticospinal tract

C. The dorsal column pathway Internal arcuate fibers cross at the sensory decussation.

4. Arms weaker than legs after a hyperextension fall suggests

A. anterior cord syndrome
B. central cord syndrome
C. cauda equina syndrome
D. Brown Sequard syndrome

B. central cord syndrome Arm fibers lie medially in the corticospinal tract.

5. Ipsilateral facial pain loss, hoarseness, Horner syndrome and contralateral body pain loss is

A. Wallenberg syndrome
B. locked-in syndrome
C. Weber syndrome
D. medial medullary syndrome

A. Wallenberg syndrome The lateral medulla is supplied by PICA or the vertebral artery.

6. A stroke causing leg weakness far greater than arm weakness involves

A. the posterior cerebral artery
B. the basilar artery
C. the anterior cerebral artery
D. the middle cerebral artery

C. the anterior cerebral artery The leg area sits on the medial surface in ACA territory.

Peripheral and Autonomic Nervous Systems and the Special Senses

Read it in full: **Chapter 6 in the review book**. Practice it: **the practice exams** (Exam 3 covers this chapter) and **the flashcards**.

What to know

Roots join beyond the dorsal root ganglion to form a spinal nerve that splits into a dorsal ramus (deep back muscles, facets, midline skin) and a ventral ramus (plexuses). **White rami exist only T1 to L2; gray rami join all 31 nerves.** The recurrent meningeal nerve carries disc and PLL pain.

Localize radiculopathy with the grid: biceps C5 to C6, brachioradialis C6, triceps C7, patellar L4, Achilles S1; C7 is the commonest cervical root and L5 and S1 the commonest lumbar ones. Cranial nerves: LR6 SO4, rest 3; parasympathetics in III, VII, IX and X; IX, X and XI leave through the jugular foramen; the tongue points toward and the uvula away from a lesion.

Autonomics: sympathetic outflow is thoracolumbar with short preganglionic fibers and long noradrenergic ones; parasympathetic outflow is craniosacral with the reverse. All ganglia use nicotinic receptors. Sweat glands are the sympathetic cholinergic exception, and the adrenal medulla is directly innervated. **Horner syndrome** (ptosis, miosis, anhidrosis) follows any break in the three-neuron chain to the head.

Vision: nasal retinal fibers cross, so a chiasm lesion gives **bitemporal hemianopia** and lesions behind it give contralateral homonymous defects. The light reflex is II in and III out through both Edinger Westphal nuclei. Hearing: the cochlear base hears high pitch; Weber lateralizes to the bad ear in conductive loss. Otoliths sense linear acceleration and canals angular; BPPV responds to repositioning.

The visual pathway and five classic lesions

Seen from above; lesions drawn on the left pathway

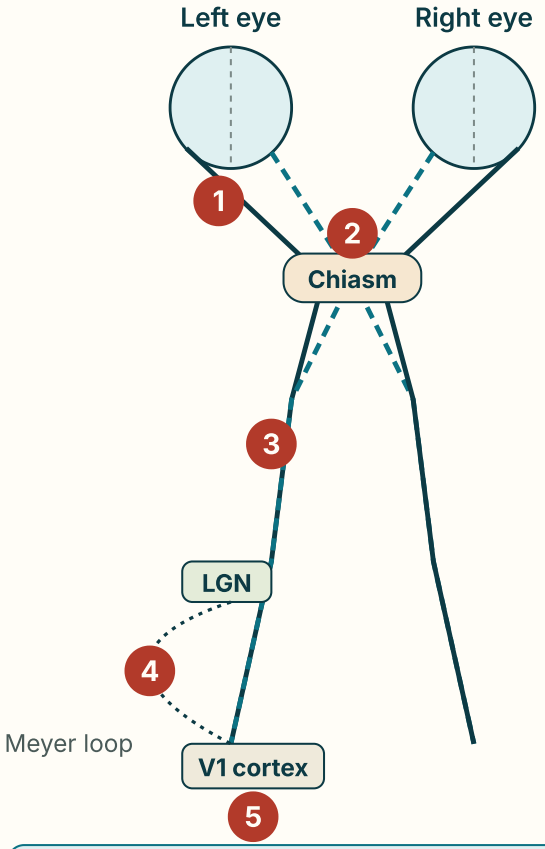

Lesion	L eye, R eye
1 **Left optic nerve** — Left eye blind	● ○
2 **Chiasm** — Bitemporal hemianopia	◐ ◐
3 **Left optic tract** — Right homonymous hemianopia	◑ ◑
4 **Left Meyer loop** — Right upper quadrant loss	◔ ◔
5 **Left visual cortex** — Right hemianopia, macula spared	◕ ◕

Dark = lost field

- - - - Nasal retinal fibers cross at the chiasm (temporal fields).
——— Temporal retinal fibers stay on their own side.

Crossing nasal fibers explain every defect. A chiasm lesion takes both temporal fields; any lesion behind the chiasm takes the opposite half field in both eyes.

LOCK THESE IN

- White rami T1 to L2 only; gray rami everywhere.
- Sinuvertebral nerve carries discogenic pain.
- Reflex levels: C5 to C6, C6, C7, L4, S1.
- Parasympathetic ganglia: ciliary, pterygopalatine, submandibular, otic.
- Chiasm lesion equals bitemporal hemianopia.
- Conductive loss: Weber to the affected ear, Rinne negative.

Radiculopathy grid

Root	Weakness	Reflex and sensation
C6	Wrist extensors, biceps	Brachioradialis; thumb
C7	Triceps, finger extensors	Triceps; middle finger
L4	Tibialis anterior, quadriceps	Patellar; medial leg
L5	EHL, heel walk	None; dorsum, great toe
S1	Toe walk, gastrocnemius	Achilles; lateral foot

Worked case

CASE 6.1 · PTOSIS, MIOSIS AND A NUMB ARM

A smoker has a droopy left lid, small pupil, dry face and aching medial left arm with weak intrinsics.

STEP 1 · NAME THE TRIAD

Horner syndrome from an interrupted sympathetic chain.

STEP 2 · ADD THE ARM FINDINGS

Medial arm pain and weak intrinsics point to the lower trunk (C8, T1).

STEP 3 · LOCATE

A left apical lung tumor near the stellate ganglion. Refer for imaging.

TRAPS PEOPLE FALL INTO

- **L5 reflex.** There is no reliable one; use the EHL and heel walk.
- **Parotid gland.** Its parasympathetic supply is CN IX through the otic ganglion.
- **Pupil-sparing CN III palsy.** It suggests ischemia; a blown pupil suggests compression.

Chapter 6 self-test · six board-style items

1. Preganglionic sympathetic fibers enter the chain through

A. gray rami at all levels
B. pelvic splanchnics
C. white rami at T1 to L2
D. the dorsal ramus

C. white rami at T1 to L2 Only T1 to L2 hold the intermediolateral cell column.

2. Weak elbow extension with a numb middle finger localizes to

A. the C7 root
B. the C8 root
C. the C6 root
D. the T1 root

A. the C7 root C7 pairs triceps weakness with middle finger numbness and a reduced triceps reflex.

3. Which cranial nerves carry parasympathetic fibers?

A. I, II, V and VIII
B. III, VII, IX and X
C. II, IV, VI and VIII
D. V, VI, XI and XII

B. III, VII, IX and X They serve the ciliary, pterygopalatine, submandibular and otic ganglia and the viscera.

4. Sweat glands receive

A. parasympathetic fibers releasing acetylcholine
B. sympathetic fibers releasing norepinephrine
C. somatic motor fibers
D. sympathetic fibers that release acetylcholine

D. sympathetic fibers that release acetylcholine They are the classic sympathetic cholinergic exception, acting on muscarinic receptors.

5. A pituitary adenoma pressing the chiasm gives

A. bitemporal hemianopia
B. monocular blindness
C. homonymous hemianopia
D. upper quadrantanopia

A. bitemporal hemianopia The crossing nasal fibers carry both temporal fields.

6. Brief vertigo on rolling over with torsional upbeating nystagmus is

A. Meniere disease
B. vestibular neuritis
C. a cerebellar stroke
D. otoconia in a canal

D. otoconia in a canal Otoconia in the posterior canal respond to the Epley maneuver.

CHAPTER 7

Neurophysiology and Muscle Physiology

Read it in full: **Chapter 7 in the review book**. Practice it: **the practice exams** (Exam 4 covers this chapter) and **the flashcards**.

What to know

The resting potential sits near E(K) because potassium permeability dominates; the Na+/K+ ATPase maintains the gradients. **Hyperkalemia depolarizes** cells and then blocks them by inactivating sodium channels. The action potential is sodium in, inactivation, then potassium out; inactivation explains the absolute refractory period.

Conduction speeds with diameter and myelin (saltatory at the nodes). **Local anesthetics block small fibers first** (pain before touch and power); pressure blocks large fibers first. Transmitter release needs calcium and SNARE fusion: botulinum toxin gives flaccid paralysis, tetanus toxin spastic paralysis.

Pain runs on A delta and C fibers, is amplified by sensitization and damped by **gate control** (large fibers close the gate in lamina II) and descending inhibition from the periaqueductal gray and raphe magnus. The spindle lies in parallel and senses length (Ia, the only monosynaptic reflex); the Golgi tendon organ lies in series and senses tension (Ib).

Muscle: the T tubule DHPR opens RyR1, calcium binds troponin C and cross bridges cycle; the **A band never changes length**. Motor units are recruited in size order. Smooth muscle uses calmodulin and MLCK and holds tone in the latch state; cardiac muscle needs trigger calcium and cannot tetanize. Energy: creatine phosphate for about 10 seconds, glycolysis to about 2 minutes, oxidative beyond.

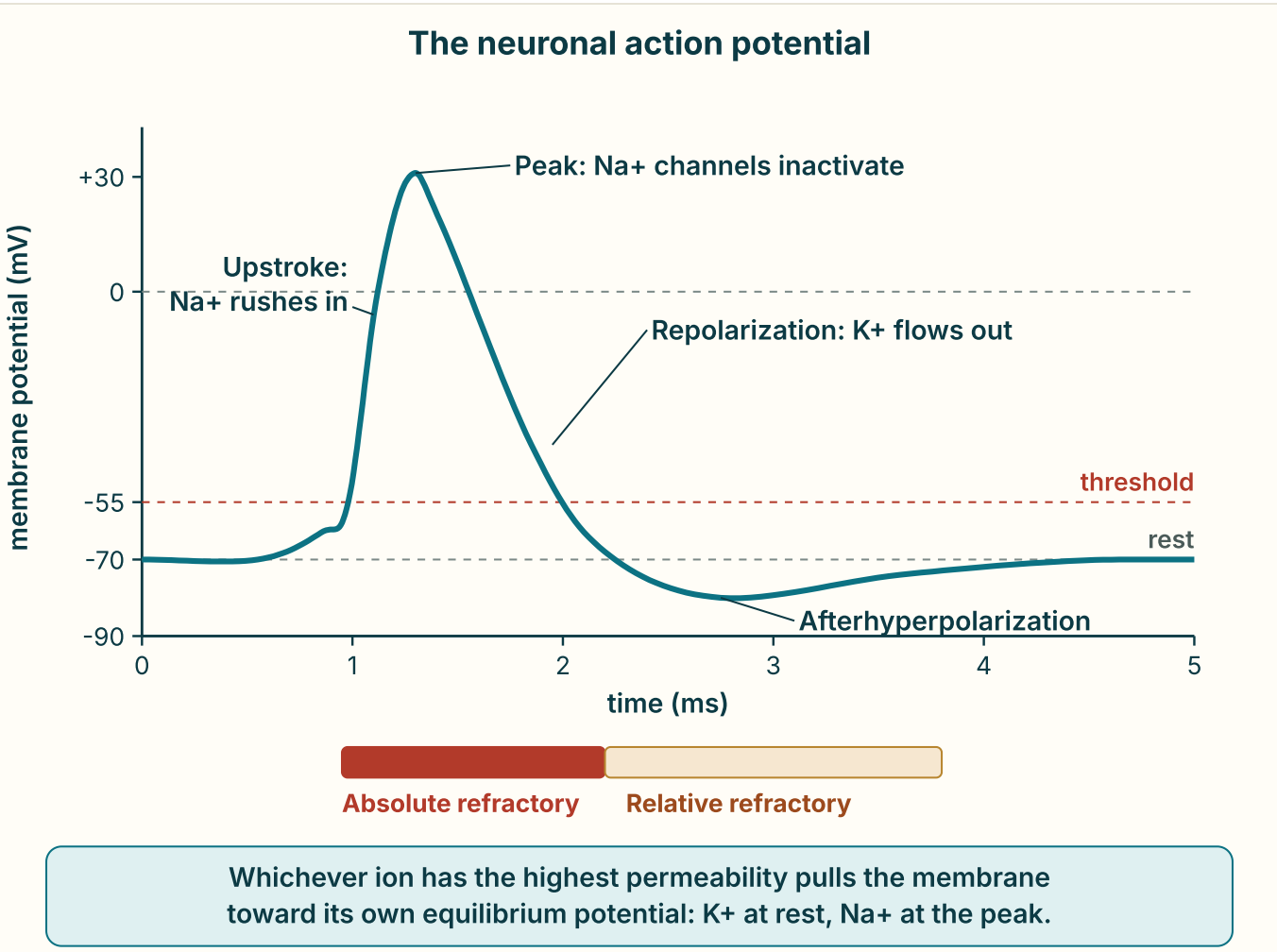

Permeability decides the voltage. The spike is a brief switch from potassium to sodium dominance and back; sodium channel inactivation creates the absolute refractory period.

LOCK THESE IN

- Potassium permeability sets the resting potential; the pump maintains gradients.
- Absolute refractory period comes from sodium channel inactivation.
- Botulinum flaccid, tetanus spastic.
- Gate control lives in the substantia gelatinosa (lamina II).
- Spindle parallel and length; tendon organ series and tension.
- Skeletal muscle needs no extracellular calcium; cardiac muscle does.

UMN versus LMN

Feature	Upper motor neuron	Lower motor neuron
Tone	Spastic	Flaccid
Reflexes	Brisk, clonus	Reduced or absent
Plantar response	Babinski	Flexor or absent
Atrophy	Mild, late	Marked, early
Fasciculations	Absent	Present

Worked case

CASE 7.1 · WEAKNESS WITH A HIGH POTASSIUM

A patient in kidney failure has a potassium of 6.8 mEq/L and new weakness.

STEP 1 · APPLY NERNST

E(K) moves from about -90 mV toward about -82 mV, so cells depolarize.

STEP 2 · EXPLAIN THE WEAKNESS

Sustained depolarization keeps sodium channels inactivated, so spikes fail.

STEP 3 · ACT

Treat it as an emergency, including the cardiac risk.

TRAPS PEOPLE FALL INTO

- **Maintains versus contributes.** The pump maintains gradients; potassium permeability sets the voltage.
- **Myasthenia versus Lambert-Eaton.** Worse with use versus better with repetition.
- **Lactate.** It is a fuel, not the main cause of fatigue.

Chapter 7 self-test · six board-style items

1. What ends the upstroke of an action potential?

A. Chloride leaking inward
B. Sodium channel inactivation
C. Calcium entry through L channels
D. The Na+/K+ ATPase pump

B. Sodium channel inactivation Inactivation gates close within about a millisecond; delayed potassium channels then repolarize.

2. Which fibers are blocked first by local anesthetic?

A. C fibers
B. A alpha
C. A beta
D. A gamma

A. C fibers Small fibers need only a short blocked segment, so pain goes first.

3. Tetanus toxin causes spastic paralysis by blocking release of

A. substance P
B. norepinephrine
C. acetylcholine
D. glycine and GABA

D. glycine and GABA It acts on spinal inhibitory interneurons, removing inhibition of motor neurons.

4. Which sarcomere band stays the same length?

A. I band
B. Z to Z distance
C. A band
D. H zone

C. A band Filaments slide, so only the I band and H zone shorten.

5. Which receptor signals muscle tension?

A. Ruffini ending in skin
B. Muscle spindle (Ia)
C. Pacinian corpuscle
D. Golgi tendon organ (Ib)

D. Golgi tendon organ (Ib) It lies in series at the musculotendinous junction.

6. Maximal effort lasting about 8 seconds relies mainly on

A. oxidative phosphorylation
B. anaerobic glycolysis
C. creatine phosphate
D. beta oxidation

C. creatine phosphate The phosphagen system is fastest and briefest.

CHAPTER 8

Cardiovascular, Respiratory and Renal Physiology

Read it in full: **Chapter 8 in the review book**. Practice it: **the practice exams** (Exam 4 covers this chapter) and **the flashcards**.

What to know

CO = HR × SV, about 5 L/min. Preload moves you along a Starling curve; contractility shifts the curve; afterload lowers stroke volume. S1 is AV valve closure, S2 semilunar closure; the pressure volume loop's width is stroke volume. EF is 55 to 70%.

MAP = CO × TPR, and resistance varies with $1/r^4$, so arterioles control pressure. Starling forces govern capillary exchange, and edema follows high hydrostatic pressure, low albumin, leaky capillaries or blocked lymph. The baroreflex corrects pressure in seconds; RAAS and the natriuretic peptides set long-term volume.

Spirometry: **obstructive** has FEV1/FVC under 0.70 with high TLC; **restrictive** keeps the ratio with a low TLC. Surfactant lowers surface tension. V/Q is high at the apex and low at the base; shunt does not correct with oxygen. The oxygen curve shifts right with CO2, acid, heat and 2,3-BPG; carbon monoxide lowers content with a normal PaO2. PaCO2 is the main drive through central chemoreceptors.

Kidney: GFR about 125 mL/min, filtration fraction about 20%; **efferent constriction raises GFR** and lowers plasma flow. Clearance = UV/P (inulin GFR, creatinine clinical, PAH plasma flow). The thick ascending limb drives the countercurrent multiplier; ADH sets water and aldosterone sodium. pH follows the bicarbonate to CO2 ratio; use the anion gap and Winters formula.

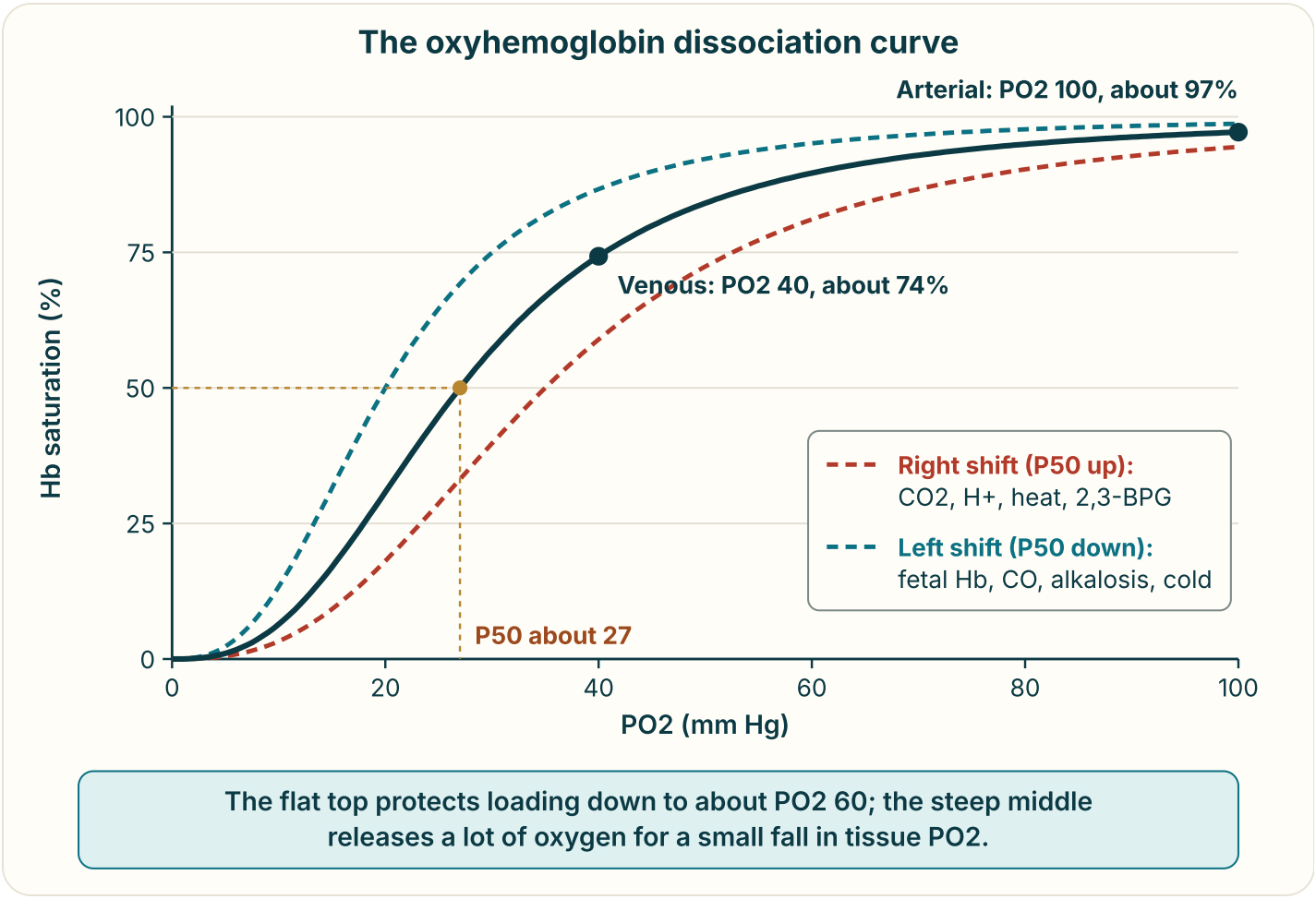

Shape and shift decide delivery. Right shifts unload oxygen in active tissue; left shifts hold it, which is why carbon monoxide starves tissue even when PaO2 is normal.

LOCK THESE IN

- Preload along a curve; contractility to a new curve.
- Halving the radius raises resistance 16 fold.
- Obstructive: ratio under 0.70 with high TLC.
- Shunt hypoxemia does not correct with oxygen.
- Inulin GFR, creatinine estimate, PAH plasma flow.
- Winters: PCO2 = 1.5 × HCO3- + 8 ± 2.

Numbers to know

Measure	Value	Note
Stroke volume	About 70 mL	EDV minus ESV
Ejection fraction	55 to 70%	Index of contractility
MAP	DBP + PP/3	120/80 is about 93
GFR	About 125 mL/min	180 L/day
Anion gap	8 to 12 mEq/L	Na+ minus Cl- and HCO3-

Worked case

CASE 8.1 · READING A GAS

pH 7.31, PCO2 29, HCO3- 14, Na+ 138, Cl- 100.

STEP 1 · PH AND PRIMARY CHANGE

Acidemia with a low bicarbonate: metabolic acidosis.

STEP 2 · ANION GAP

138 - (100 + 14) = 24, a high gap.

STEP 3 · COMPENSATION

Winters gives 1.5 × 14 + 8 = 29, which matches, so no second disorder.

TRAPS PEOPLE FALL INTO

- **Efferent constriction.** It lowers plasma flow but raises GFR.
- **Carbon monoxide.** PaO2 and pulse oximetry can look normal.
- **Lung hypoxia.** It constricts pulmonary arterioles, unlike systemic ones.

Chapter 8 self-test · six board-style items

1. An arteriole halves its radius. Resistance rises by a factor of

A. 8
B. 4
C. 2
D. 16

D. 16 Poiseuille: resistance varies with 1/r to the fourth power.

2. Generalized pitting edema with albumin of 1.8 g/dL reflects

A. increased permeability
B. low plasma oncotic pressure
C. blocked lymphatic drainage
D. high hydrostatic pressure

B. low plasma oncotic pressure Low albumin reduces the force holding fluid in capillaries.

3. Which pattern fits COPD?

A. Ratio under 0.70, high TLC
B. Normal ratio with a low TLC
C. High ratio with a low TLC
D. Normal ratio and normal TLC

A. Ratio under 0.70, high TLC Air trapping raises residual volume and total lung capacity.

4. Which change shifts the oxygen curve left?

A. Mild acidosis
B. High 2,3-BPG
C. Carbon monoxide
D. A high fever

C. Carbon monoxide Left shifts hold oxygen; the others unload it.

5. Angiotensin II constricting the efferent arteriole will

A. drop pressure
B. raise GFR
C. lower it
D. raise flow

B. raise GFR Glomerular pressure rises while plasma flow falls.

6. Vomiting gives pH 7.50, HCO3- 36 and PCO2 48. This is

A. compensated metabolic alkalosis
B. compensated respiratory acidosis
C. an uncompensated alkalosis
D. a mixed alkalosis picture

A. compensated metabolic alkalosis Expected PCO2 rises about 0.7 per mEq/L of bicarbonate.

CHAPTER 9

Gastrointestinal, Endocrine, Reproductive and Exercise Physiology

Read it in full: **Chapter 9 in the review book**. Practice it: **the practice exams** (Exam 5 covers this chapter) and **the flashcards**.

What to know

The myenteric plexus runs motility, the submucosal plexus secretion, and interstitial cells of Cajal set slow waves. Hormones: **gastrin** acid, **secretin** bicarbonate, **CCK** enzymes and gallbladder, GIP and GLP-1 incretins, motilin the fasting complex, somatostatin inhibits. The parietal cell pumps acid with the H+/K+ ATPase under acetylcholine, gastrin and histamine.

Absorption: glucose and galactose by SGLT1, fructose by GLUT5; fats through micelles into chylomicrons; iron and calcium in the duodenum; **B12 and bile salts in the terminal ileum**. Bilirubin is unconjugated in hemolysis and conjugated in obstruction.

Endocrine reading: in **primary** failure the pituitary hormone moves opposite the end hormone; in **secondary** failure both move together. Prolactin is held down by dopamine. Insulin release follows glucose, ATP, closure of K-ATP channels and calcium entry. PTH raises calcium and lowers phosphate; calcitriol raises both; the RANKL to OPG ratio sets resorption.

Reproduction and exercise: sustained estradiol triggers the **LH surge**, and the luteal phase is fixed at about 14 days; hCG rescues the corpus luteum; menopause raises FSH and speeds bone loss. **VO2 max is limited by cardiac output**; training raises stroke volume, not maximal heart rate. Exertional heat stroke is a core temperature above 40 °C with CNS dysfunction: cool first, then transport.

One axis, two kinds of failure: reading thyroid labs

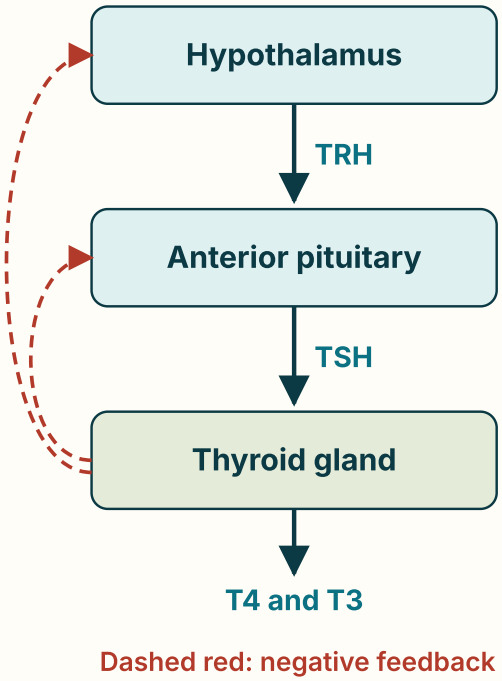

Pattern	Free T4	TSH	Level
Primary hypothyroid	↓	↑	Gland
Secondary hypothyroid	↓	↓	Pituitary
Graves disease	↑	↓	Gland
TSH-secreting tumor	↑	↑	Pituitary

Opposite directions: the gland is the problem.
Same direction: the pituitary is the problem.

The same rule reads every axis: compare the pituitary hormone with the end hormone (TSH with T4, ACTH with cortisol, FSH with estradiol).

Feedback locates the lesion. If the pituitary hormone and the end hormone move in opposite directions the gland has failed; if they move together the pituitary is at fault.

LOCK THESE IN

- Secretin answers acid; CCK answers fat and protein.
- Terminal ileum: B12 and bile salts.
- Primary failure raises the pituitary hormone.
- K-ATP channel closure releases insulin.
- PTH raises calcium, lowers phosphate.
- Heat stroke: cool first, then transport.

Lab patterns

Condition	End hormone	Pituitary hormone
Primary hypothyroidism	Low T4	High TSH
Secondary hypothyroidism	Low T4	Low TSH
Graves disease	High T4	Low TSH
Addison disease	Low cortisol	High ACTH
Menopause	Low estradiol	High FSH

Worked case

CASE 9.1 · FATIGUE WITH ABNORMAL THYROID LABS

Low free T4 with a high TSH.

STEP 1 · COMPARE DIRECTIONS

They moved oppositely.

STEP 2 · APPLY FEEDBACK

A healthy pituitary responds to a failing gland.

STEP 3 · NAME IT

Primary hypothyroidism, usually Hashimoto thyroiditis.

TRAPS PEOPLE FALL INTO

- **Secondary adrenal insufficiency.** Aldosterone is largely spared.
- **Total T4 in pregnancy.** TBG rises; free T4 and status stay normal.
- **Luteal phase.** It is the fixed one, about 14 days.

Chapter 9 self-test · six board-style items

1. Acid in the duodenum releases

A. secretin
B. gastrin
C. GIP
D. motilin

A. secretin Secretin drives pancreatic and biliary bicarbonate.

2. After ileal resection a patient develops macrocytic anemia because of lost

A. lactase activity
B. folate absorption
C. B12 absorption
D. iron absorption

C. B12 absorption B12 with intrinsic factor is absorbed in the terminal ileum.

3. Which step directly triggers insulin secretion?

A. Binding of glucagon
B. Insertion of GLUT4 carriers
C. Opening of K-ATP channels
D. Closure of K-ATP channels

D. Closure of K-ATP channels Depolarization opens calcium channels and releases granules.

4. Primary hyperparathyroidism shows

A. high calcium, high phosphate, low PTH
B. high calcium, low phosphate, high PTH
C. low calcium, high phosphate, high PTH
D. normal calcium, phosphate and PTH

B. high calcium, low phosphate, high PTH PTH drives resorption and phosphaturia.

5. The midcycle LH surge is triggered by

A. progesterone falling away
B. FSH dropping off
C. inhibin B rising
D. estradiol high for days

D. estradiol high for days Feedback switches from negative to positive above a threshold.

6. VO2 max in a healthy adult is limited mainly by

A. mitochondrial number
B. maximal cardiac output
C. minute ventilation
D. lung diffusing capacity

B. maximal cardiac output Central delivery, not the lungs, sets the ceiling.

CHAPTER 10

Biomolecules

Read it in full: **Chapter 10 in the review book**. Practice it: **the practice exams** (Exam 5 covers this chapter) and **the flashcards**.

What to know

Sugars: epimers differ at one chiral carbon (glucose and galactose at C4), anomers only at the anomeric carbon. **Sucrose is nonreducing**. Starch and glycogen use α-1,4 chains with α-1,6 branches; cellulose is indigestible β-1,4. **GAGs** are negatively charged and hold water; aggrecan on hyaluronic acid in a collagen net gives the disc its swelling pressure, which falls with degeneration.

Lipids: linoleic and α-linolenic acids are essential; HMG-CoA reductase is the statin target. Corticosteroids block phospholipase A2 and NSAIDs block COX; thromboxane aggregates, prostacyclin opposes it, and aspirin disables platelet COX for 7 to 10 days. Lipoproteins carry apoB-48 (chylomicron), apoB-100 (VLDL, LDL) and apoA-I (HDL).

Proteins: secondary structure rests on backbone hydrogen bonds, tertiary on side chains and disulfides. **Collagen** is Gly-X-Y and needs vitamin C for hydroxylation and copper for cross-linking; type I is bone, tendon and ligament, type II cartilage and nucleus pulposus, type III vessels and early scar, type IV basement membrane. Hemoglobin binds cooperatively with P50 about 27; myoglobin is hyperbolic.

Enzymes change rate, never equilibrium. **Km** is the substrate concentration at half Vmax (low Km means high affinity). Competitive inhibitors raise Km with Vmax unchanged (lines meet on the y axis); noncompetitive inhibitors lower Vmax with Km unchanged. Nucleic acids: purines have two rings, G-C three hydrogen bonds, the lagging strand is made in Okazaki fragments, and xanthine oxidase makes uric acid (gout: needle-shaped, negatively birefringent crystals).

Lineweaver Burk plot: two kinds of inhibitor

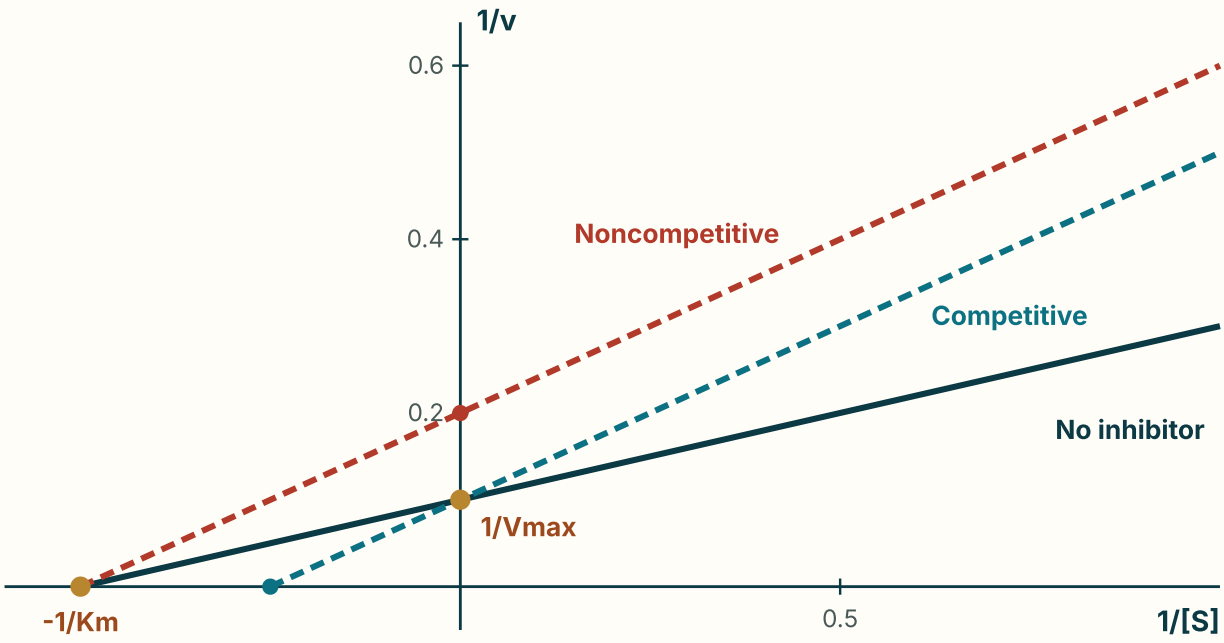

Competitive (Km 2 to 4): Km up, Vmax same, lines meet on the y axis.
Noncompetitive (Vmax 10 to 5): Vmax down, Km same, lines meet on the x axis.

Read the intercepts. The y-intercept is 1/Vmax and the x-intercept is -1/Km, so where the lines meet tells you the type of inhibitor.

LOCK THESE IN

- Sucrose is nonreducing; hyaluronic acid is unsulfated and has no core protein.
- Aspirin disables platelet COX for the platelet lifespan.
- Collagen needs vitamin C and copper.
- Low Km means high affinity.
- Competitive: Km up, Vmax same.
- Allopurinol blocks xanthine oxidase.

Collagen types

Type	Where	Disorder
I	Bone, tendon, ligament, annulus	Osteogenesis imperfecta
II	Cartilage, nucleus pulposus	Chondrodysplasias
III	Vessels, early granulation tissue	Vascular Ehlers-Danlos
IV	Basement membrane	Alport, Goodpasture

Worked case

CASE 10.1 · AN INHIBITOR THAT RAISES KM

An inhibitor doubles Km from 5 to 10 mM and leaves Vmax at 100.

STEP 1 · COMPUTE AT 10 MM

v = 100 × 10 / (10 + 10) = 50, half of the new Vmax-adjusted curve.

STEP 2 · CHECK VMAX

Enough substrate still reaches 100, so Vmax is unchanged.

STEP 3 · NAME THE TYPE

Competitive inhibition; the Lineweaver Burk lines meet on the y axis.

TRAPS PEOPLE FALL INTO

- **Hydrogen bonds.** Secondary structure uses backbone atoms, not side chains.
- **Enzymes and ΔG.** They never change it.
- **Crystals.** Gout needles are negatively birefringent; pseudogout rhomboids weakly positive.

Chapter 10 self-test · six board-style items

1. In which disaccharide are both anomeric carbons locked in the bond?

A. Lactose
B. Sucrose
C. Isomaltose
D. Maltose

B. Sucrose Glucose C1 and fructose C2 are both bonded, so sucrose cannot open and is nonreducing.

2. Which GAG has no core protein and no sulfate?

A. Hyaluronic acid
B. Chondroitin sulfate
C. Heparin
D. Keratan sulfate

A. Hyaluronic acid It forms the backbone that aggrecan binds.

3. Corticosteroids block prostaglandins and leukotrienes by inhibiting

A. 5-lipoxygenase
B. thromboxane synthase
C. COX-1
D. phospholipase A2

D. phospholipase A2 That step releases arachidonic acid for both branches.

4. Bleeding gums and poor wound healing reflect failure of

A. cleavage of the propeptides
B. lysyl oxidase cross-linking
C. proline and lysine hydroxylation
D. glycosylation in the Golgi

C. proline and lysine hydroxylation Those hydroxylases need vitamin C: scurvy.

5. An inhibitor lowers Vmax and leaves Km unchanged. It is

A. competitive
B. uncompetitive
C. irreversible and competitive
D. noncompetitive

D. noncompetitive The lines meet on the x axis.

6. Allopurinol inhibits

A. HGPRT
B. xanthine oxidase
C. uricase
D. adenosine deaminase

B. xanthine oxidase Humans lack uricase, so urate is the end product.

CHAPTER 11

Metabolism, Hormones, Vitamins and Minerals

Read it in full: **Chapter 11 in the review book**. Practice it: **the practice exams** (Exam 6 covers this chapter) and **the flashcards**.

What to know

Glycolysis is cytosolic with **PFK-1** rate limiting and nets 2 ATP; PDH is the irreversible bridge needing B1, lipoate, B5, B2 and B3; the citric acid cycle is limited by isocitrate dehydrogenase; the chain yields about **30 to 32 ATP per glucose**. Inhibitors (cyanide at Complex IV) stop oxygen use; uncouplers raise oxygen use and heat while lowering ATP.

Gluconeogenesis uses pyruvate carboxylase, PEPCK, fructose-1,6-bisphosphatase and glucose-6-phosphatase (liver and kidney only). Glycogen is switched by one phosphorylation: breakdown on, synthesis off. **Von Gierke** is glucose-6-phosphatase, **Pompe** lysosomal acid maltase, **McArdle** muscle phosphorylase. G6PD deficiency gives oxidant hemolysis.

Malonyl-CoA blocks CPT-I so a cell cannot make and burn fat at once; the liver makes ketones but cannot use them. Transamination needs B6; the urea cycle starts with CPS-I and the common defect is X-linked OTC with orotic aciduria. Inborn errors: PKU, alkaptonuria (dark urine, ochronosis, early spinal arthropathy), maple syrup urine disease and homocystinuria.

Hormone biochemistry: peptides act fast on membrane receptors, steroids slowly through the nucleus; 21-hydroxylase deficiency is the common congenital adrenal hyperplasia. Vitamins: B1 beriberi and Wernicke, B3 pellagra, B6 neuropathy and sideroblastic anemia, folate megaloblastic anemia, **B12** anemia plus subacute combined degeneration with raised methylmalonic acid, C scurvy, D rickets and osteomalacia, K bleeding. Iron studies separate deficiency (low ferritin, high TIBC) from chronic disease (high ferritin, low TIBC) and overload.

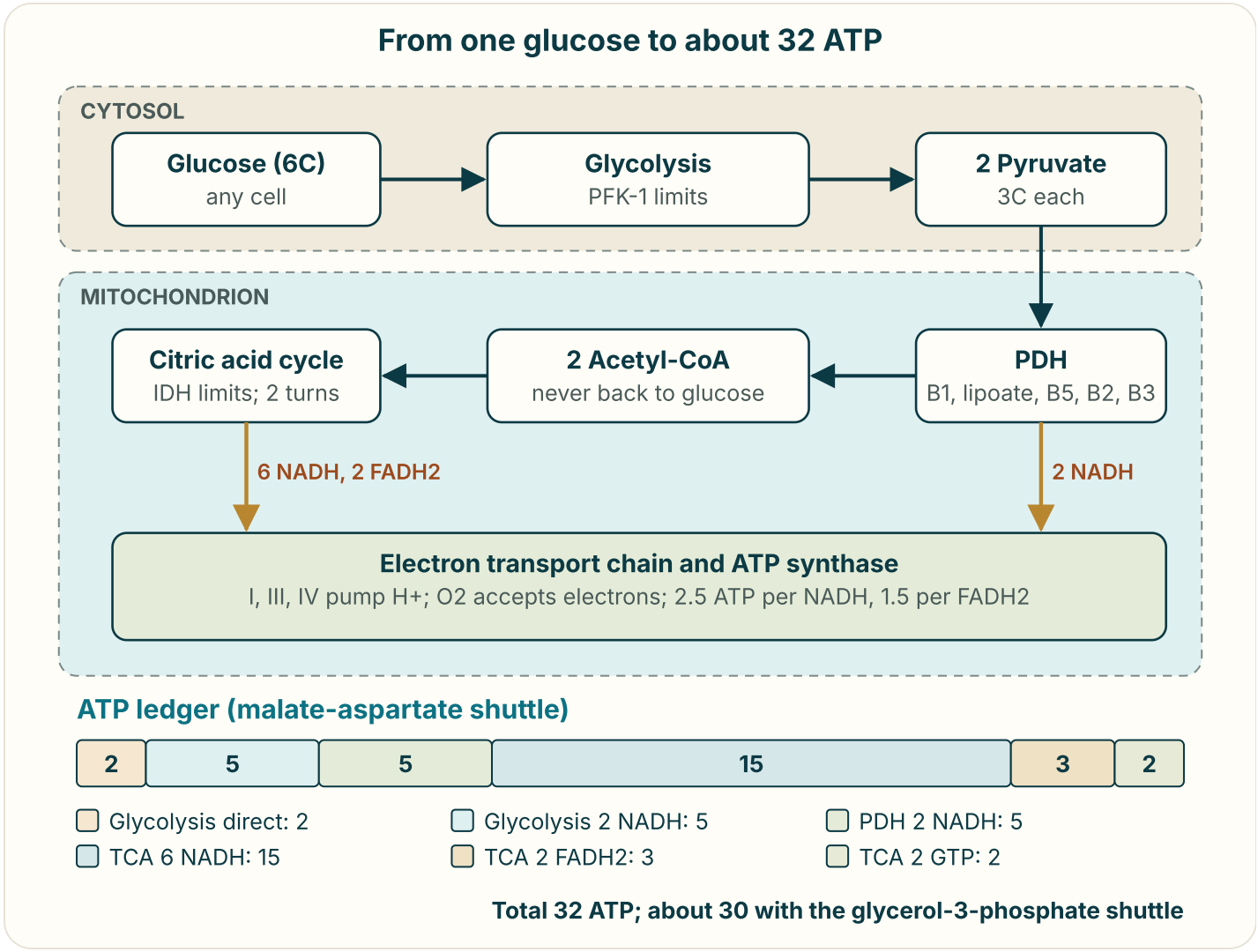

Most ATP comes from the mitochondrion. Glycolysis nets only 2 ATP; the electron carriers sent to the chain supply the rest.

LOCK THESE IN

- PFK-1, PDH cofactors, isocitrate dehydrogenase, 30 to 32 ATP.
- Uncouplers raise oxygen use and heat, lower ATP.
- Von Gierke, Pompe, Cori, McArdle in order.
- Malonyl-CoA inhibits CPT-I.
- OTC deficiency raises orotic acid.
- B12 adds neurologic signs; folate does not.

Glycogen storage diseases

Type	Enzyme	Clue
I von Gierke	Glucose-6-phosphatase	Hypoglycemia, lactic acidosis, high urate
II Pompe	Lysosomal acid maltase	Cardiomegaly in infancy
III Cori	Debranching enzyme	Milder, normal lactate
V McArdle	Muscle phosphorylase	Cramps, myoglobinuria, second wind

Worked case

CASE 11.1 · CRAMPS AND DARK URINE WITH EXERTION

A teenager cramps in the first minutes of exercise, passes dark urine and improves after a brief rest.

STEP 1 · LIVER OR MUSCLE

No hypoglycemia or hepatomegaly, so it is a muscle enzyme.

STEP 2 · NAME IT

Muscle glycogen phosphorylase: McArdle disease.

STEP 3 · ACT

Dark urine means myoglobinuria: check CK and kidney function, refer.

TRAPS PEOPLE FALL INTO

- **Thiamine first.** Give it before glucose in a malnourished drinker.
- **Muscle glycogen.** Muscle cannot release free glucose.
- **Folate masking B12.** The anemia corrects while nerve damage continues.

Chapter 11 self-test · six board-style items

1. The rate-limiting enzyme of glycolysis is

A. phosphoglucose isomerase
B. hexokinase
C. pyruvate kinase
D. phosphofructokinase

D. phosphofructokinase It is controlled by AMP, fructose-2,6-bisphosphate, ATP and citrate.

2. An agent that raises oxygen consumption and heat while ATP falls is

A. a Complex I block
B. an uncoupling agent
C. a Complex IV block
D. an ATP synthase block

B. an uncoupling agent The proton gradient is dissipated and the energy becomes heat.

3. Severe fasting hypoglycemia with hepatomegaly, lactic acidosis and high urate suggests deficiency of

A. muscle phosphorylase
B. lysosomal acid maltase
C. glucose-6-phosphatase
D. the branching enzyme

C. glucose-6-phosphatase Von Gierke disease shunts glucose-6-phosphate into other pathways.

4. Which molecule stops fatty acid oxidation during fat synthesis?

A. Malonyl-CoA
B. Citrate
C. Acetoacetate
D. Carnitine

A. Malonyl-CoA It inhibits CPT-I.

5. Hyperammonemia with high urinary orotic acid and no anemia suggests

A. carbamoyl phosphate synthetase I
B. ornithine transcarbamylase
C. the pyrimidine salvage path
D. arginase in the cytosol

B. ornithine transcarbamylase Carbamoyl phosphate spills into pyrimidine synthesis.

6. Megaloblastic anemia with raised methylmalonic acid indicates

A. B6 deficiency
B. folate deficiency
C. B12 deficiency
D. iron deficiency

C. B12 deficiency Only B12 serves methylmalonyl-CoA mutase.

CHAPTER 12

General Pathology

Read it in full: **Chapter 12 in the review book**. Practice it: **the practice exams** (Exam 6 covers this chapter) and **the flashcards**.

What to know

Cells adapt by hypertrophy, hyperplasia, atrophy and metaplasia; dysplasia can precede cancer. Swelling is the earliest reversible change, and mitochondrial and membrane failure mark the point of no return. Necrosis is coagulative in infarcts (liquefactive in the brain), caseous in tuberculosis, fat in pancreatitis and fibrinoid in vessels; **apoptosis** is caspase driven without inflammation.

Acute inflammation is vascular then cellular (selectins, integrins, PECAM-1, chemotaxis). Chronic inflammation brings macrophages and granulomas. Repair runs granulation tissue, type III collagen and then type I, reaching only 70 to 80% of strength; infection is the main obstacle.

Virchow triad explains thrombosis; most pulmonary emboli come from deep leg veins. Neoplasms are clonal; metastasis is the most reliable sign of malignancy; oncogenes need one hit and tumor suppressors two; stage outweighs grade. **Bone metastases** favor the vertebral bodies, destroy pedicles and spare discs, and prostate lesions are blastic.

Genetics: dominant disorders hit structural proteins, recessive ones enzymes, X-linked recessive ones the sons of carriers. **Down syndrome** brings atlantoaxial instability; Marfan syndrome risks aortic dissection; Ehlers-Danlos gives hypermobility and vascular fragility. Hypersensitivity follows ACID, with type IV delayed and T cell mediated. Amyloid is Congo red positive.

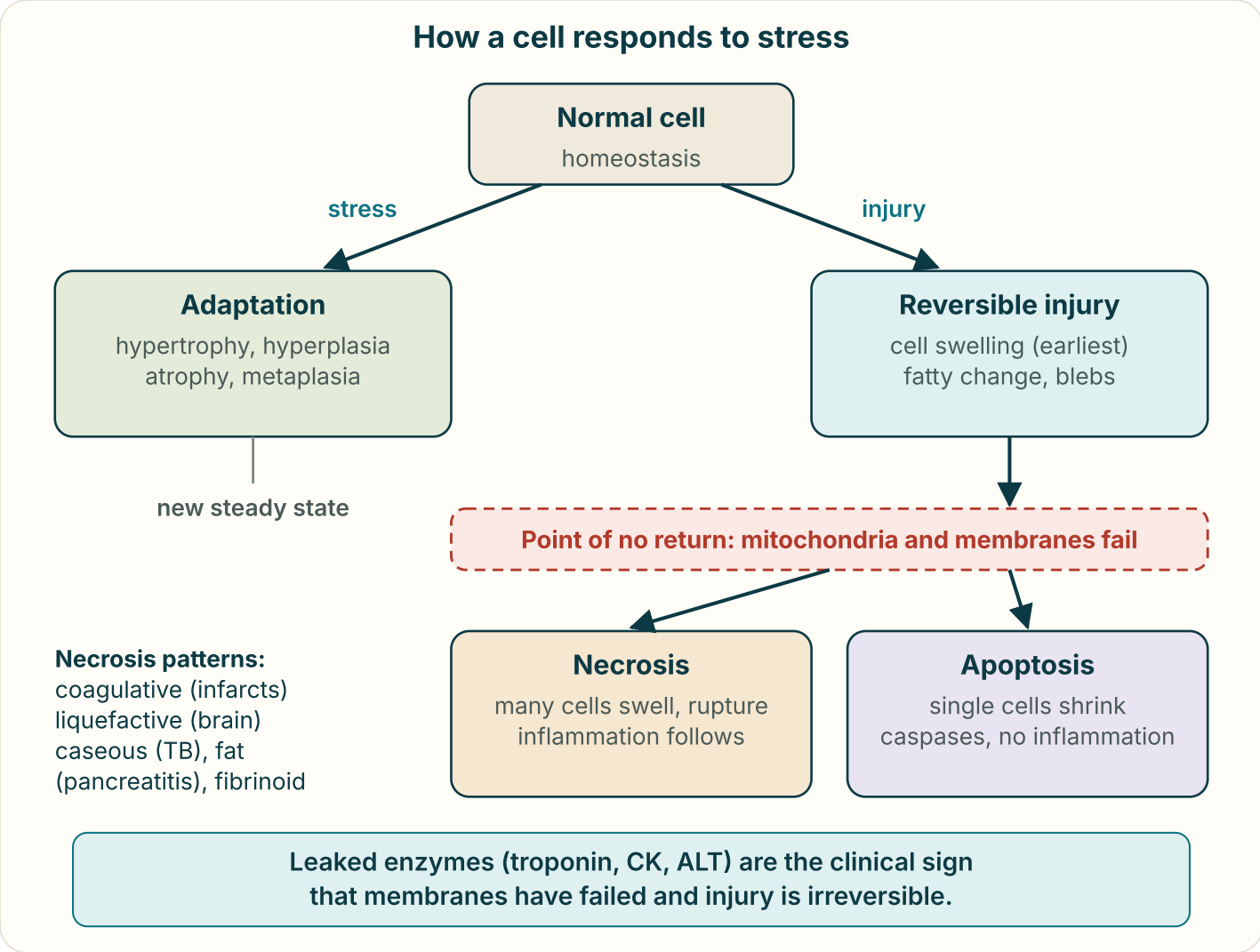

Adapt, injure, then die. Swelling is reversible; once mitochondria and membranes fail the cell dies by necrosis or apoptosis.

LOCK THESE IN

- Swelling reversible; mitochondrial and membrane failure not.
- Brain infarcts are liquefactive.
- Repair: type III then type I collagen.
- Metastasis is the surest sign of malignancy; stage beats grade.
- Vertebral metastasis destroys pedicles and spares discs.
- Type IV hypersensitivity: 48 to 72 hours, no antibody.

Hypersensitivity

Type	Mechanism	Example
I	IgE on mast cells	Anaphylaxis, asthma
II	Antibody on a cell	Hemolysis, Graves, myasthenia
III	Immune complexes	Lupus, poststreptococcal GN
IV	T cells, delayed	PPD, contact dermatitis

Worked case

CASE 12.1 · NIGHT PAIN WITH A MISSING PEDICLE

A 68-year-old treated for prostate cancer has night pain, weight loss, an absent pedicle at L2 and a dense L3 body with preserved discs.

STEP 1 · COUNT RED FLAGS

Age, cancer history, night pain, weight loss.

STEP 2 · READ THE FILM

A missing pedicle plus a dense body fits blastic prostate metastasis; preserved discs argue against infection.

STEP 3 · ACT

No manipulation of the involved segments; refer.

TRAPS PEOPLE FALL INTO

- **Dystrophic calcification.** It occurs with normal serum calcium.
- **Grade versus stage.** Stage predicts prognosis better.
- **X-linked spread.** Never father to son.

Chapter 12 self-test · six board-style items

1. The earliest light-microscopic sign of reversible injury is

A. karyorrhexis
B. cell swelling
C. pyknosis
D. membrane rupture

B. cell swelling Pump failure lets sodium and water in.

2. Infarcts of the brain show which necrosis?

A. Coagulative
B. Caseous
C. Liquefactive
D. Fibrinoid

C. Liquefactive Enzymatic digestion liquefies the tissue.

3. Calcification in a damaged tendon with normal serum calcium is

A. apoptotic
B. a sign of hyperparathyroidism
C. metastatic
D. dystrophic

D. dystrophic Damaged tissue calcifies without a metabolic cause.

4. A wound at one week has roughly

A. about 10 percent
B. its full strength
C. about 80 percent
D. about half of it

A. about 10 percent Strength plateaus at 70 to 80% by about three months.

5. Which metastasis is typically osteoblastic?

A. Lung
B. Prostate
C. Kidney
D. Thyroid

B. Prostate Prostate lesions lay down dense bone.

6. A tuberculin test read at 48 to 72 hours is hypersensitivity type

A. III
B. I
C. II
D. IV

D. IV It is delayed and T cell mediated with no antibody.

CHAPTER 13

Systemic Pathology

Read it in full: **Chapter 13 in the review book**. Practice it: **the practice exams** (Exam 7 covers this chapter) and **the flashcards**.

What to know

Bone labs sort the metabolic diseases: osteoporosis normal across the board, osteomalacia with low phosphate and high ALP and PTH, **Paget disease with a very high ALP alone**, hyperparathyroidism with high calcium and low phosphate. Pyogenic spine infection destroys the disc; tuberculosis and tumor spare it. In an older adult a destructive spinal lesion is metastasis or myeloma first.

Primary bone tumors by site and age: osteosarcoma metaphysis (Codman triangle), Ewing sarcoma diaphysis (onion skin), giant cell tumor epiphysis (soap bubble), osteoid osteoma with **night pain relieved by aspirin**. Myeloma gives CRAB and punched-out lytic lesions with a cold bone scan.

Arthritis: osteoarthritis builds bone unevenly and spares MCPs; **rheumatoid arthritis** erodes symmetric small joints, spares DIPs and threatens C1 to C2; HLA-B27 disease fuses the SI joints and spine; gout crystals are needles and CPPD rhomboids; DISH flows down the right thoracic spine with discs preserved. Myasthenia worsens with use and Lambert-Eaton improves.

Neurology and organs: stroke follows arterial territory, CSF separates bacterial (low glucose) from viral meningitis, MS and Guillain Barre demyelinate centrally and peripherally, and each cord syndrome removes a predictable set of tracts. **Cauda equina syndrome** is a surgical emergency. Troponin rises in 3 to 4 hours; an abdominal aortic aneurysm or dissection can masquerade as back pain; anemia sorts by MCV.

Where primary bone tumors live, and what metastasis looks like

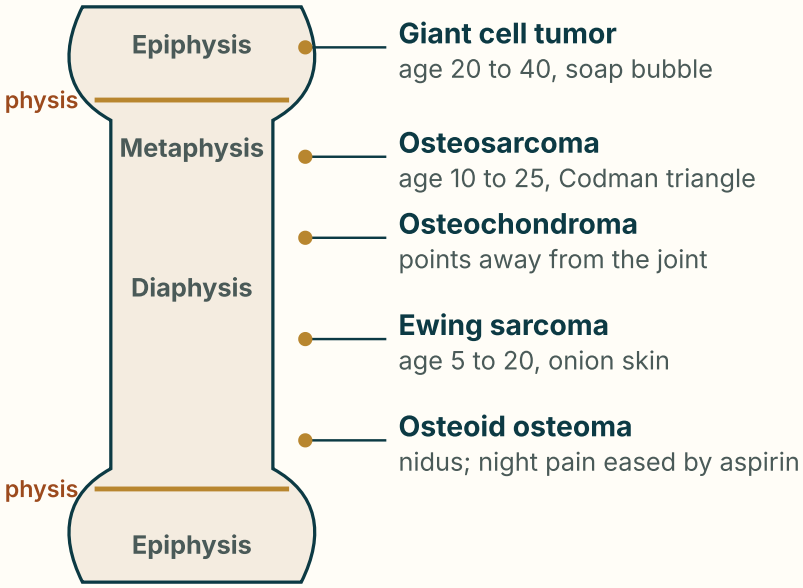

In an adult, a destructive spinal lesion is metastasis or myeloma first

Metastasis: destroys a pedicle (winking owl sign), spares the disc; prostate blastic, kidney and thyroid lytic and expansile. Infection destroys the disc early.

Red flags: age over 50, cancer history, weight loss, night pain, no improvement in a month.

Site plus age narrows the list. Epiphysis in an adult suggests giant cell tumor, metaphysis in a teenager osteosarcoma, diaphysis in a child Ewing sarcoma; in an older adult, think metastasis.

LOCK THESE IN

- Paget disease: ALP high, everything else normal.
- Infection destroys the disc; tumor spares it.
- Codman triangle, onion skin, soap bubble.
- RA spares the DIP and erodes margins.
- Unilateral sacroiliitis means infection until proven otherwise.
- Retention with overflow plus saddle anesthesia equals cauda equina.

Bone disease by labs

Condition	Calcium / phosphate	ALP
Osteoporosis	Normal / normal	Normal
Osteomalacia	Low / low	High
Paget disease	Normal / normal	Very high
Hyperparathyroidism	High / low	Normal or high
Myeloma	Often high / normal	Normal

Worked case

CASE 13.1 · BACK PAIN WITH FEVER

A week of worsening thoracolumbar pain with fever, after a urinary infection; MRI shows disc loss with erosion of both endplates.

STEP 1 · USE THE DISC

Early disc destruction points to infection rather than tumor.

STEP 2 · NAME IT

Pyogenic discitis and vertebral osteomyelitis, usually Staphylococcus aureus.

STEP 3 · ACT

Same-day medical referral; films lag 10 to 14 days.

TRAPS PEOPLE FALL INTO

- **Myeloma bone scan.** It can be cold because lesions are purely lytic.
- **Serum urate in a flare.** It may be normal; crystals decide.
- **Anemia with numb feet.** That is B12, not folate.

Chapter 13 self-test · six board-style items

1. Bone pain with ALP five times normal and normal calcium, phosphate and PTH is

A. osteoporosis
B. hyperparathyroidism
C. Paget disease
D. osteomalacia

C. Paget disease Only Paget disease raises ALP alone.

2. Which favors metastasis over infection on a spinal film?

A. A destroyed pedicle
B. Loss of the disc space
C. Erosion of both endplates
D. A paravertebral abscess

A. A destroyed pedicle Tumor enters the posterior body and pedicle and spares the disc.

3. A metaphyseal femoral lesion with a Codman triangle in a 15-year-old is

A. giant cell tumor
B. osteosarcoma
C. osteochondroma
D. Ewing sarcoma

B. osteosarcoma Osteosarcoma favors the metaphysis around the knee in adolescents.

4. Which pattern fits rheumatoid arthritis?

A. Chondrocalcinosis
B. Osteophytes and sclerosis
C. Flowing ossification
D. Marginal erosions

D. Marginal erosions Pannus erodes bare areas and narrows the joint uniformly.

5. Bacterial meningitis CSF shows

A. normal cells with high protein
B. lymphocytes with normal glucose
C. neutrophils with low glucose
D. lymphocytes with high glucose

C. neutrophils with low glucose Bacteria consume glucose and draw neutrophils.

6. Saddle anesthesia with urinary retention and bilateral sciatica requires

A. a trial of manipulation
B. repeat films in two weeks
C. a home exercise program
D. same-day surgical referral

D. same-day surgical referral This is cauda equina syndrome.

CHAPTER 14

Microbiology, Immunology and Public Health

Read it in full: **Chapter 14 in the review book**. Practice it: **the practice exams** (Exam 7 covers this chapter) and **the flashcards**.

What to know

IgM marks current infection, **IgG** is most abundant and crosses the placenta, IgA guards mucosa and IgE drives allergy. Complement gives C3b opsonin, C5a chemotaxis and the membrane attack complex (C5 to C9 deficiency means Neisseria infection). MHC I presents to CD8 and MHC II to CD4. Live vaccines are avoided in pregnancy and immunodeficiency; conjugate vaccines let infants respond to capsules.

Gram-positive cells keep crystal violet in thick peptidoglycan; gram-negative cells carry **LPS endotoxin** and stain pink. Mycoplasma has no wall. Exotoxins are specific proteins (tetanus spastic, botulinum flaccid, cholera locks Gs on, Shiga blocks the 60S ribosome); endotoxin triggers fever, hypotension and DIC. S. aureus is the commonest cause of osteomyelitis and septic arthritis; gonococcus is the commonest septic arthritis in young adults.

Viruses: envelopes are fragile, naked viruses survive on surfaces. Herpesviruses stay latent, so shingles can start as dermatomal pain days before the rash. Hepatitis B serology: HBsAg current, anti-HBs alone vaccinated, IgM anti-HBc in the window period. HIV destroys CD4 cells, and AIDS is a count under 200. **Prions** survive routine sterilization. Fungi are mold in the cold and yeast in the heat; antifungals target ergosterol.

Epidemiology: incidence is new cases, prevalence existing ones, and prevalence is about incidence times duration. Case-control studies give odds ratios, cohort studies relative risks, trials ARR and NNT. **Sensitive tests rule out; specific tests rule in**, and predictive values swing with prevalence. Infection control: sterilize critical items, high-level disinfect semicritical ones, wipe tables and cradles between patients, and remember that alcohol rub misses C. difficile spores.

A screening test in a low-prevalence population

1,000 people, prevalence 2%, sensitivity 95%, specificity 90%

	Disease present (20)	Disease absent (980)	
Test positive	TP = 19	FP = 98	117 positives
Test negative	FN = 1	TN = 882	883 negatives

Sensitivity	19 / 20 = 95%	how many sick people test positive
Specificity	882 / 980 = 90%	how many well people test negative
PPV	19 / 117 = about 16%	chance a positive is real
NPV	882 / 883 = about 99.9%	chance a negative is real

Sensitivity and specificity belong to the test; predictive values move with prevalence, which is why screening healthy people yields false positives.

Most positives can still be false. With a good test and low prevalence, only about one positive in six is real, while a negative is almost certainly true.

LOCK THESE IN

- IgM current, IgG placenta, IgA mucosa, IgE allergy.
- Rule of 8: MHC I with CD8, MHC II with CD4.
- Only gram-negative bacteria have endotoxin.
- Anti-HBs alone means vaccinated.
- Prevalence equals incidence times duration.
- Sterilize critical, high-level disinfect semicritical, wipe noncritical.

Epidemiology formulas

Measure	Formula	Design
Relative risk	[a/(a+b)] / [c/(c+d)]	Cohort
Odds ratio	ad / bc	Case-control
NNT	1 / ARR	Trial
Sensitivity	TP / (TP + FN)	Screening
PPV	TP / (TP + FP)	Moves with prevalence

Worked case

CASE 14.1 · READING A SEROLOGY PANEL

HBsAg negative, anti-HBs positive, anti-HBc negative.

STEP 1 · HBSAG

Negative: no current infection.

STEP 2 · ANTI-HBC

Negative: no past natural infection.

STEP 3 · CONCLUDE

Immune by vaccination.

TRAPS PEOPLE FALL INTO

- **Endotoxin.** Gram-negative only.
- **Prevalence.** It changes predictive values, not sensitivity or specificity.
- **Alcohol rub.** It does not kill C. difficile spores.

Chapter 14 self-test · six board-style items

1. Which class dominates the first days of a primary response?

A. IgD
B. IgA
C. IgG
D. IgM

D. IgM IgM appears first in a primary response.

2. MHC class I presents peptides to

A. CD8 cytotoxic T cells
B. Antibody-making B cells
C. Natural killer cells
D. CD4 helper T cells

A. CD8 cytotoxic T cells Rule of 8.

3. Which component belongs only to gram-negative bacteria?

A. Teichoic acid
B. Endospores
C. Lipopolysaccharide
D. Thick peptidoglycan

C. Lipopolysaccharide LPS sits in the outer membrane.

4. Tetanus toxin produces spastic paralysis by blocking release of

A. substance P
B. glycine and GABA
C. acetylcholine
D. norepinephrine

B. glycine and GABA It disables spinal inhibitory interneurons.

5. Anti-HBs positive with anti-HBc negative means

A. vaccinated
B. recovered
C. acute
D. chronic

A. vaccinated Core antibody appears only after natural infection.

6. A treatment that prolongs life without curing

A. raises both together
B. raises prevalence only
C. lowers incidence too
D. lowers prevalence

B. raises prevalence only Prevalence is about incidence times duration.

ONE PAGE

Cram sheet

The whole review on one sheet. Cover the right columns and rebuild each row from memory. If a row will not come back, go to that chapter's study guide.

Levels and landmarks

Structure	Level	Note
Hyoid, thyroid cartilage, cricoid	C3, C4, C6	Cricoid: larynx to trachea
Vertebra prominens	C7	First clearly palpable spinous process
Scapular spine, inferior angle	T3, T7	Thoracic counting
Sternal angle	T4 to T5	Rib 2, carina, aortic arch, azygos
Xiphisternum	T9	Lower border of the heart
IVC, esophagus, aorta through diaphragm	T8, T10, T12	I 8 10 Eggs At 12
Celiac, SMA, renal, gonadal, IMA	T12, L1, L1 to L2, L2, L3	Foregut, midgut, hindgut
Transpyloric plane	L1	Renal hila, pancreatic neck
Umbilicus	L3 to L4 disc	T10 dermatome
Aortic bifurcation, iliac crests	L4	Lumbar puncture level
IVC formation	L5	Common iliac veins
Conus medullaris; dural sac	L1 to L2; S2	PSIS dimples at S2

Roots, reflexes and nerve lesions

Root or nerve	Test	Lesion
C5 to C6	Biceps reflex	Erb palsy: waiter's tip
C6	Brachioradialis; thumb	C5 to C6 disc
C7	Triceps; middle finger	C6 to C7 disc, commonest cervical
C8, T1	Intrinsics; medial forearm	Klumpke palsy, Horner sign
L4	Patellar; medial leg	L3 to L4 disc
L5	EHL, heel walk; dorsum of foot	L4 to L5 posterolateral disc
S1	Achilles; lateral foot	L5 to S1 disc
Radial (spiral groove)	Wrist drop	Triceps spared
Median at wrist	Thenar atrophy	Thenar skin spared
Ulnar at wrist	Deep claw	Dorsal ulnar skin spared
Common fibular	Foot drop, weak eversion	Inversion and ankle reflex normal
Superior gluteal	Trendelenburg sign	Weakness on the stance side

Pathways and cord syndromes

Item	Crossing or lesion	Deficit
DCML	Lower medulla	Vibration, position, fine touch
Spinothalamic	Within 1 to 2 segments	Pain and temperature
Lateral corticospinal	Pyramidal decussation	Skilled distal movement
Spinocerebellar	Ends ipsilaterally	Unconscious proprioception
Brown Sequard	Hemisection	Ipsilateral motor and vibration; contralateral pain
Central cord	Hyperextension	Arms worse than legs
Anterior cord	Anterior spinal artery	Vibration and position spared
Syringomyelia	Anterior white commissure	Cape-like pain loss
Subacute combined degeneration	B12	Romberg positive, Babinski
Cauda equina	Roots below L2	Saddle anesthesia, retention: emergency

Lab patterns

Condition	Pattern	Hook
Osteoporosis	Ca, PO4, ALP, PTH all normal	T-score at or below -2.5
Osteomalacia	Ca low-normal, PO4 low, ALP high, PTH high	Looser zones
Paget disease	ALP very high, rest normal	Ivory enlarged vertebra
Primary hyperparathyroidism	Ca high, PO4 low, PTH high	Subperiosteal resorption
Renal osteodystrophy	Ca low, PO4 high, PTH high	Rugger jersey spine
Myeloma	Ca high, lytic, normal ALP	M spike, cold bone scan
Primary hypothyroidism	T4 low, TSH high	Opposite directions: the gland
Secondary hypothyroidism	T4 low, TSH low	Same direction: the pituitary
Addison disease	Cortisol low, ACTH high	Hyperpigmentation, high K+
Iron deficiency	Ferritin low, TIBC high	Chronic disease is the reverse
B12 deficiency	MMA and homocysteine high	Folate raises homocysteine only

Numbers and formulas

Measure	Formula or value	Use
Cardiac output	HR × SV; about 5 L/min	EF 55 to 70%
MAP	DBP + PP/3	Resistance varies with 1/r to the 4th
Alveolar gas	0.21(760-47) - PaCO2/0.8	About 100 mm Hg
O2 content	1.34 × Hb × SaO2 + 0.003 × PaO2	About 20 mL/dL
P50	About 27 mm Hg	Right shift unloads
GFR and clearance	UV/P; about 125 mL/min	Inulin, creatinine, PAH
Henderson Hasselbalch	pH = 6.1 + log(HCO3-/0.03 PCO2)	Ratio sets pH
Winters formula	PCO2 = 1.5 × HCO3- + 8 ± 2	Metabolic acidosis
Anion gap	Na+ - (Cl- + HCO3-)	8 to 12 mEq/L
ATP per glucose	About 30 to 32	2.5 per NADH, 1.5 per FADH2
Prevalence	About incidence × duration	Burden versus risk
NNT	1 / ARR	Trials

Tumors, toxins and organisms

Item	Signature	Note
Osteosarcoma	Metaphysis, Codman triangle	Age 10 to 25
Ewing sarcoma	Diaphysis, onion skin	t(11;22), mimics infection
Giant cell tumor	Epiphysis, soap bubble	Age 20 to 40
Osteoid osteoma	Nidus, night pain eased by aspirin	Painful scoliosis
Spinal metastasis	Pedicle destroyed, disc spared	Prostate blastic
Multiple myeloma	Punched out, cold scan	CRAB
Tetanus toxin	Blocks glycine and GABA	Spastic
Botulinum toxin	Blocks ACh release	Flaccid
Cholera toxin	Locks Gs on	Rice-water stool
Endotoxin	Lipid A on TLR4	Fever, shock, DIC
S. aureus	Osteomyelitis, septic arthritis	Salmonella in sickle cell
M. tuberculosis	Pott disease, spares the disc	Psoas abscess, gibbus

Red flags that stop treatment

Finding	Suspect	Action
Night pain, weight loss, cancer history over 50	Metastasis or myeloma	Image and refer
Fever with spinal pain, recent infection or IV drug use	Discitis or epidural abscess	Same-day referral
Saddle anesthesia, retention with overflow	Cauda equina syndrome	Surgical emergency
New unusual neck pain with dizziness, diplopia, dysarthria	Cervical artery dissection	No manipulation; emergency
Worst headache of life with neck stiffness	Subarachnoid hemorrhage	Emergency
Clumsy hands, Hoffmann sign, brisk reflexes	Cervical myelopathy	MRI, no cervical thrust
ADI over 3 mm adult (RA, Down syndrome)	Atlantoaxial instability	No upper cervical thrust
Deep boring back pain, pulsatile mass, smoker over 60	Abdominal aortic aneurysm	Vascular referral
Tearing chest pain to the back, unequal arm pulses	Aortic dissection	Emergency
Exertional chest or left arm pain relieved by rest	Angina	Emergency evaluation
Cola-colored urine after exertion	Rhabdomyolysis	Check CK and kidneys

An independent study aid, not affiliated with or endorsed by the National Board of Chiropractic Examiners.
Dr. Garg Learning · CC BY-SA 4.0