Study Guide 3

This guide covers chapters 5 and 6, the nervous system from the meninges to the special senses. The board asks these chapters in one shape over and over: here is a deficit, where is the lesion? Every fact you learn should answer that question, so keep asking where each pathway crosses and what sits next to what. Work one chapter at a time. Read the "what to know" paragraphs, study the diagram, copy the tables, then cover the steps of each worked case and localize the lesion yourself before reading on. Finish with the ten board-style items. The cram sheet at the end puts both chapters on one page.

WHAT THIS GUIDE COVERS

- Chapter 5 · the meninges and their spaces, hematomas, CSF production, flow and hydrocephalus, cord length and segment levels, Rexed laminae, the funiculi, the cord blood supply, the DCML, spinothalamic, spinocerebellar and descending tracts, UMN versus LMN signs, classic cord syndromes, the brainstem nuclei and vascular syndromes, cortical areas, the internal capsule, thalamus, hypothalamus, basal ganglia, cerebellum and the circle of Willis.
- Chapter 6 · spinal nerve formation, the IVF and its contents, rami and the recurrent meningeal nerve, dermatomes, myotomes and the radiculopathy grid, the twelve cranial nerves and their foramina, sympathetic and parasympathetic outflow, receptors, referred pain, the eye, visual field defects, the light reflex, the ear and hearing tests, the vestibular system, taste and smell.

CHAPTER 5

The Spinal Cord and Central Nervous System

Read it in full: **Chapter 5 in the review book**. Practice it: **the practice exams** (Exam 3 covers this chapter) and **the flashcards**.

What to know

From inside out the coverings are pia, arachnoid and dura. In the spine the **epidural space is real** (fat and the valveless Batson plexus, a metastatic route); in the skull it is only potential because the dura is fused to bone. An **epidural hematoma** is usually arterial (middle meningeal artery at

the pterion), biconvex, stops at sutures and often follows a lucid interval. A **subdural hematoma** comes from torn bridging veins, is crescent shaped, crosses sutures and is common in older adults and people with alcohol use disorder. A subarachnoid hemorrhage gives the worst headache of the patient's life with neck stiffness.

The choroid plexus makes about 500 mL of CSF a day (about 150 mL present at a time). The blood CSF barrier is the choroid epithelium with tight junctions. Flow: lateral ventricle, interventricular foramen (Monro), third ventricle, **cerebral aqueduct**, fourth ventricle, out the median (Magendie) and lateral (Luschka) apertures, around the subarachnoid space, and into the superior sagittal sinus through arachnoid granulations. A block inside the system (aqueduct most often) is noncommunicating hydrocephalus and only upstream ventricles dilate. Normal pressure hydrocephalus is wet, wobbly and wacky.

The adult cord ends as the **conus medullaris at L1 to L2** (L3 in the newborn); the dural sac ends at **S2**; the filum terminale anchors to the coccyx. The lumbar cistern (L2 to S2) holds the cauda equina, so lumbar puncture at L3 to L4 or L4 to L5 meets only floating roots. The needle passes supraspinous, interspinous and then the ligamentum flavum (the pop) into the epidural space. There are 31 segments; the cervical enlargement is C4 to T1 and the lumbosacral enlargement about L1 to S3. Segments lie above their vertebrae: cervical spine plus 1, upper thoracic plus 2, lower thoracic plus 3; the T10 vertebra overlies L1 and L2 segments.

Rexed laminae: **II is the substantia gelatinosa** (pain modulation), V is where visceral and somatic input converge (the basis of referred pain), **VII holds Clarke nucleus (C8 to L3)** and the intermediolateral column (T1 to L2), and IX holds the lower motor neurons (medial for the trunk, lateral for limbs, flexors dorsal to extensors). The lateral horn exists only from T1 to L2. Cervical cord: most white matter, both gracilis and cuneatus. Thoracic: small, round, visible lateral horn. Sacral: mostly gray.

The **anterior spinal artery** (from both vertebrals) feeds the front two thirds of the cord; the paired posterior spinal arteries feed the back third. The **artery of Adamkiewicz**, usually left between T9 and T12, reinforces the lower cord; injury during aortic surgery gives anterior spinal artery syndrome (bilateral paralysis and pain and temperature loss, with vibration and position spared). T1 to T4 is a watershed zone.

Three crossing points solve most lesion questions. The **DCML** (fine touch, vibration, position) ascends ipsilaterally and crosses in the **lower medulla** as the internal arcuate fibers; gracilis (legs, below T6) is medial and cuneatus lateral. The **spinothalamic tract** (pain and temperature) synapses in the dorsal horn and crosses within **one or two segments** in the anterior white commissure; sacral fibers are most lateral, so central lesions spare the sacrum. The **lateral corticospinal tract** crosses at the **pyramidal decussation** (85 to 90%); its leg fibers are lateral. Spinocerebellar tracts end ipsilaterally. A positive Romberg means sensory ataxia, not cerebellar disease.

UMN lesions give spastic weakness in a pyramidal pattern, hyperreflexia, clonus and a Babinski sign with little atrophy. LMN lesions give flaccid weakness of individual muscles, hyporeflexia, early marked atrophy and fasciculations. Cervical spondylotic myelopathy (clumsy hands, broad based gait, Hoffmann sign, hyperreflexia) is a UMN picture: no cervical high velocity manipulation, refer for MRI.

Brown Sequard (hemisection): ipsilateral spastic weakness and dorsal column loss below the lesion, contralateral pain and temperature loss starting one or two segments below, and an ipsilateral band of total anesthesia at the level. **Central cord**: hyperextension of a spondylotic neck, arms worse than legs, often sacral sparing. **Anterior cord**: everything but the dorsal columns. **Syringomyelia**: cape-like pain and temperature loss with touch kept, then hand wasting. **Subacute combined degeneration** (B12): dorsal columns plus corticospinal. Tabes dorsalis: dorsal roots and columns. ALS: UMN plus LMN with no sensory loss.

Conus medullaris syndrome (L1 to L2) gives early symmetric saddle anesthesia and early bladder and bowel dysfunction with mixed UMN and LMN signs. Cauda equina syndrome (a large central L4 to L5 or L5 to S1 disc) gives asymmetric radicular pain, LMN weakness, areflexia, then saddle anesthesia and retention. Both are surgical emergencies: urinary retention with overflow in a back pain patient means same-day referral.

Brainstem strokes give **crossed signs**: a cranial nerve deficit on the side of the lesion and a long tract deficit on the opposite body. The nerve tells the level: III midbrain (**Weber**: CN III palsy plus contralateral hemiplegia), VI and VII pons, IX, X and XII medulla. **Wallenberg** (lateral medulla, PICA or vertebral) gives ipsilateral facial pain and temperature loss, hoarseness and dysphagia,

Horner syndrome and ataxia with contralateral body pain and temperature loss and no weakness. Medial medullary: tongue toward the lesion plus contralateral hemiplegia. The tongue points to the lesion; the uvula points away.

Cortex: area 4 motor, area 6 premotor, area 8 frontal eye field, **Broca** (44, 45) expressive aphasia, 3, 1, 2 somatosensory, **Wernicke** (22) receptive aphasia, 41 and 42 auditory, 17 visual. The posterior limb of the internal capsule carries corticospinal and sensory fibers, so a small lacunar infarct can give pure motor hemiparesis of face, arm and leg. The thalamus relays everything but smell (VPL body, VPM face, LGN light, MGN music). Basal ganglia loops depend on nigral dopamine (Parkinson disease); subthalamic lesions give hemiballismus. The cerebellum controls the **ipsilateral** body; Purkinje cells are its only output and are GABAergic.

The vertebral arteries ascend through the transverse foramina of C6 to C1, loop behind the atlas in the suboccipital triangle, give PICA and the anterior spinal artery, and join to form the basilar artery (AICA, pontine, superior cerebellar, then the PCAs). The circle of Willis links them with the carotids; the anterior communicating artery is the commonest aneurysm site, and a posterior communicating aneurysm blows the CN III pupil. **MCA**: face and arm more than leg, aphasia or neglect. **ACA**: leg more than arm, incontinence. **PCA**: homonymous hemianopia with macular sparing. Before cervical manipulation, screen for the 5 D's and 3 N's of vertebrobasilar ischemia.

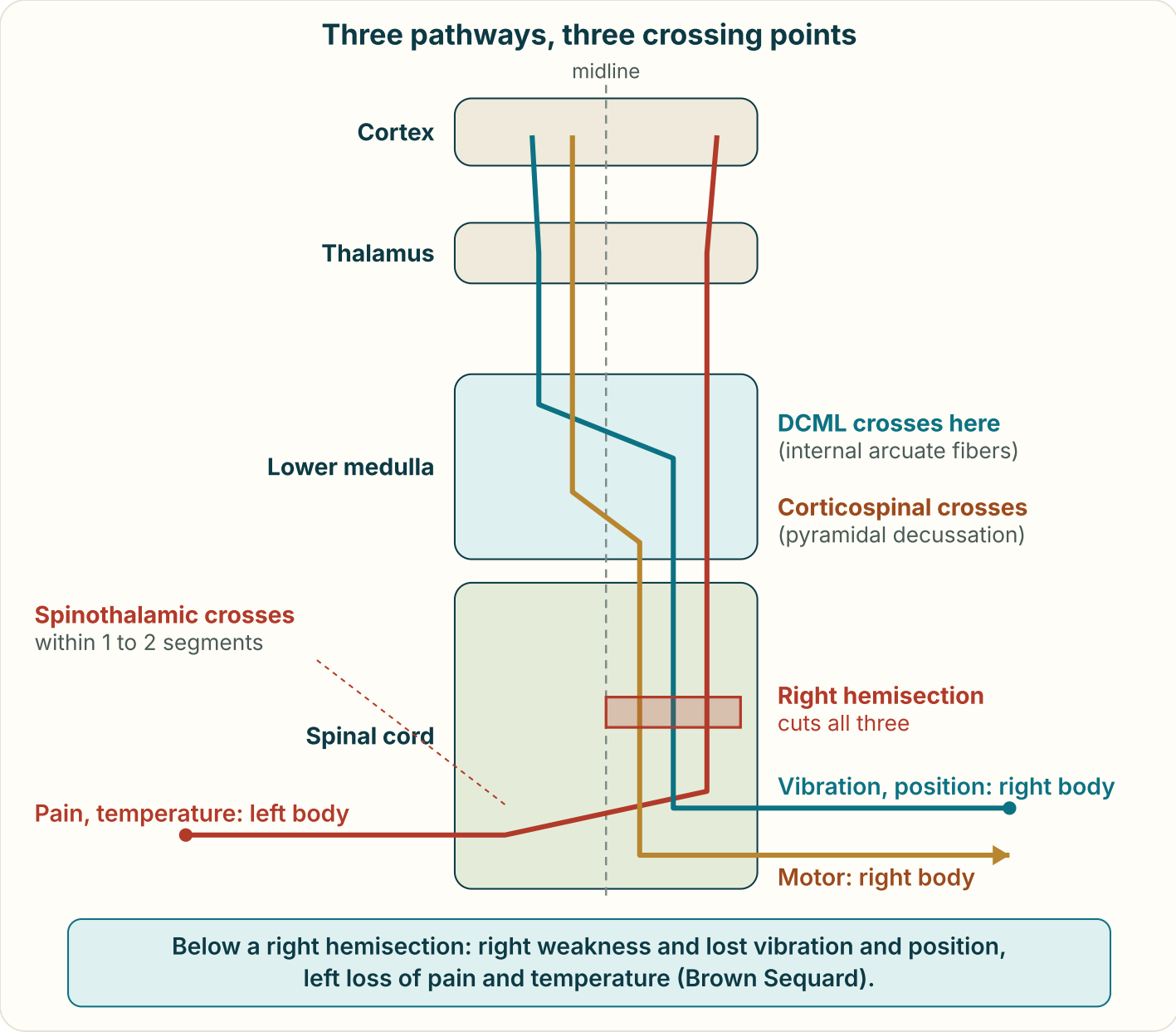

Crossing points decide the side. The DCML crosses in the medulla, the corticospinal tract at the pyramids and the spinothalamic tract within a segment or two, so a hemisection splits the deficits.

LOCK THESE IN

- Spinal epidural space is real (fat, Batson plexus); cranial epidural space is potential.
- CSF path: lateral ventricle, Monro, third ventricle, aqueduct, fourth ventricle, Magendie and Luschka, granulations.
- Cord ends at L1 to L2 (adult), dural sac at S2; lateral horn only T1 to L2; Clarke nucleus C8 to L3.
- DCML crosses in the lower medulla; spinothalamic crosses within one or two segments; corticospinal at the pyramids.
- Brown Sequard: ipsilateral motor and vibration loss, contralateral pain and temperature loss.
- Central cord: arms worse than legs after hyperextension. Anterior cord: dorsal columns spared.
- Brainstem lesions give crossed signs; Wallenberg has no weakness; the tongue points toward the lesion.
- MCA spares the leg; ACA hits the leg; PCA gives hemianopia with macular sparing.

Cord syndromes

Syndrome	What is damaged	What you find
Brown Sequard	Half the cord	Ipsilateral UMN weakness and dorsal column loss; contralateral pain and temperature loss
Central cord	Central gray, medial corticospinal fibers	Arms worse than legs, sacral sparing
Anterior cord	Anterior two thirds (anterior spinal artery)	Bilateral paralysis and pain loss; vibration and position kept
Syringomyelia	Anterior white commissure, then ventral horns	Cape-like pain and temperature loss, hand wasting
Subacute combined degeneration	Dorsal columns, lateral corticospinal (B12)	Paresthesias, lost vibration, spastic weakness, Babinski
Tabes dorsalis	Dorsal roots and columns	Sensory ataxia, Romberg positive, Argyll Robertson pupils
ALS	Corticospinal tracts and ventral horns	Mixed UMN and LMN signs, no sensory loss
Conus medullaris	Cord at L1 to L2	Early symmetric saddle anesthesia and bladder loss
Cauda equina	Roots below L2	Asymmetric radicular pain, LMN weakness, retention

Brainstem and stroke syndromes

Syndrome or artery	Same side	Opposite side or pattern
Weber (ventral midbrain)	CN III palsy	Hemiplegia
Medial pontine	CN VI (with or without VII)	Hemiplegia
Lateral pontine (AICA)	Facial palsy, hearing loss, ataxia, Horner	Body pain and temperature loss
Medial medullary	Tongue deviates toward lesion	Hemiplegia, lost vibration and position
Wallenberg (PICA)	Face pain loss, hoarseness, Horner, ataxia	Body pain and temperature loss
Locked in (basilar)	Quadriplegia, no speech	Consciousness and vertical gaze kept
MCA	Contralateral face and arm more than leg	Aphasia (dominant) or neglect
ACA	Contralateral leg more than arm	Incontinence, abulia
PCA	Contralateral homonymous hemianopia	Macular sparing

Worked cases

WORKED CASE 1 · A STAB WOUND AND SPLIT DEFICITS

After a stab wound to the back, Malik has weakness and lost vibration sense in the left leg and lost pinprick and temperature in the right leg from about T12 down.

STEP 1 · LIST THE DEFICITS BY SIDE

Left: motor and vibration. Right: pain and temperature.

STEP 2 · RECALL WHERE EACH CROSSES

Corticospinal and dorsal column fibers are still ipsilateral in the cord. Spinothalamic fibers have already crossed within one or two segments of entry.

STEP 3 · PUT THE LESION ON A SIDE

Motor and vibration loss mark the side of the lesion: the left half of the cord.

STEP 4 · SET THE LEVEL

The pain level starts one or two segments below the lesion, so the hemisection is around T10 to T11.

STEP 5 · NAME IT

Brown Sequard syndrome on the left.

WORKED CASE 2 · ARMS WORSE THAN LEGS

Harold, 74, trips and strikes his forehead, forcing his neck into extension. He has marked weakness and burning in both hands and arms but only mild leg weakness, and he can feel touch around the anus.

STEP 1 · NOTE THE MECHANISM

Hyperextension of a spondylotic cervical spine pinches the cord between osteophytes in front and a buckled ligamentum flavum behind.

STEP 2 · ASK WHAT LIES CENTRALLY

The central gray matter and the medially placed arm fibers of the lateral corticospinal tract.

STEP 3 · EXPLAIN THE PATTERN

Arm fibers suffer more than leg fibers, and the most lateral sacral fibers are spared.

STEP 4 · NAME AND ACT

Central cord syndrome, the most common incomplete cord injury. Immobilize and refer as an emergency.

WORKED CASE 3 · CROSSED SIGNS IN THE BRAINSTEM

A patient has a right eye that is down and out with a dilated pupil, plus weakness of the left arm and leg.

STEP 1 · FIND THE CRANIAL NERVE

Down and out with a dilated pupil is a CN III palsy on the right.

STEP 2 · FIND THE LEVEL

CN III nucleus and fascicles are in the midbrain.

STEP 3 · EXPLAIN THE OPPOSITE SIDE

The crus cerebri next to the CN III fascicles carries corticospinal fibers that have not yet crossed, so the hemiplegia is on the left.

STEP 4 · NAME IT

Weber syndrome, right ventral midbrain, usually from posterior cerebral branches.

TRAPS PEOPLE FALL INTO

- **Hydrocephalus level.** A normal fourth ventricle with big lateral and third ventricles places the block at the aqueduct.
- **Romberg.** A positive Romberg means proprioceptive loss (dorsal columns or large fiber neuropathy), not cerebellar disease.
- **Brown Sequard sides.** Motor and fine touch stay with you; pain and temperature go away from you.
- **Facial weakness.** Cortical lesions spare the forehead; Bell palsy takes the whole half of the face.
- **Cerebellar side.** Cerebellar hemisphere lesions give ipsilateral ataxia because the output crosses twice.
- **Wallenberg.** No hemiplegia, because the pyramids are medial and spared.

Chapter 5 self-test · ten board-style items

1. After a blow to the temple, a patient is briefly unconscious, then lucid, then declines. CT shows a biconvex clot that stops at the sutures. Which vessel bled?

A. A berry aneurysm at the ACoA
B. The superior sagittal sinus
C. Middle meningeal artery
D. Bridging cerebral veins

C. Middle meningeal artery An epidural hematoma is arterial, usually the middle meningeal artery torn at the pterion, and is lens shaped because the dura is fused at the sutures.

2. Imaging shows enlarged lateral and third ventricles with a normal fourth ventricle. Where is the block?

A. A foramen of Monro
B. The fourth ventricle
C. The granulations
D. The cerebral aqueduct

D. The cerebral aqueduct Only ventricles upstream of a block dilate, so the obstruction lies between the third and fourth ventricles.

3. In the adult, a lumbar puncture at L4 to L5 is safe mainly because

A. the cord ends at about L1 to L2
B. the filum terminale ends at L5
C. the dural sac ends at L3
D. the cauda equina ends at L4

A. the cord ends at about L1 to L2 The conus ends near the L1 to L2 disc, and the dural sac continues to S2, so the needle meets only floating roots.

4. A cross section shows a small round cord with slender horns and a visible lateral horn. Which region is it?

A. Lower cervical
B. Thoracic
C. Upper cervical
D. Sacral

B. Thoracic The lateral horn exists only from T1 to L2, and the thoracic cord is small and round with slender horns.

5. After repair of an aortic aneurysm, a patient has paralysis and loss of pain below T10, but vibration is intact. Which artery was injured?

A. Posterior inferior cerebellar artery
B. Vertebral artery
C. Posterior spinal artery
D. Artery of Adamkiewicz

D. Artery of Adamkiewicz The artery of Adamkiewicz reinforces the anterior spinal artery to the lower cord. Anterior cord loss spares the dorsal columns.

6. A man with cape-like loss of pain and temperature across both shoulders keeps normal touch. What is the likely cause?

A. Syringomyelia
B. Tabes dorsalis
C. B12 deficiency
D. Anterior cord stroke

A. Syringomyelia A central cavity first destroys spinothalamic fibers crossing in the anterior white commissure, sparing the dorsal columns.

7. Which finding points to an upper motor neuron lesion?

A. Flaccid tone in one myotome
B. Absent reflex at one root
C. Babinski sign with clonus
D. Fasciculations with early atrophy

C. Babinski sign with clonus UMN lesions give spasticity, hyperreflexia, clonus and an extensor plantar response. The others are LMN features.

8. A patient has left facial pain and temperature loss, right body pain and temperature loss, hoarseness, left Horner syndrome and left limb ataxia. Which artery is occluded?

A. Left anterior inferior cerebellar
B. Left PICA or left vertebral
C. Basilar artery
D. Right posterior cerebral

B. Left PICA or left vertebral This is the lateral medullary (Wallenberg) syndrome: spinal trigeminal nucleus, spinothalamic tract, nucleus ambiguus, sympathetics and inferior peduncle.

9. A stroke causes right leg weakness much greater than right arm weakness, plus urinary incontinence. Which artery?

A. Right anterior cerebral
B. Left posterior cerebral
C. Left anterior cerebral
D. Left middle cerebral

C. Left anterior cerebral The ACA supplies the medial frontal and parietal cortex, where the leg is represented, and the medial frontal micturition area.

10. A patient has past pointing and intention tremor in the right arm and falls to the right. Where is the lesion?

A. Right cerebellar hemisphere
B. Left cerebellar hemisphere
C. Right dorsal column tracts
D. Left internal capsule knee

A. Right cerebellar hemisphere Cerebellar output crosses to the opposite cortex and the corticospinal tract crosses back, so a hemisphere controls the same side of the body.

CHAPTER 6

Peripheral and Autonomic Nervous Systems and the Special Senses

Read it in full: **Chapter 6 in the review book**. Practice it: **the practice exams** (Exam 3 covers this chapter) and **the flashcards**.

What to know

The dorsal root carries sensory fibers from pseudounipolar cells in the **dorsal root ganglion**, which usually sits in the IVF under the pedicle and is very sensitive to compression and disc

inflammation. The ventral root carries motor and (T1 to L2, S2 to S4) preganglionic autonomic fibers. They join beyond the DRG to form a short mixed spinal nerve that splits at once into a dorsal ramus and a ventral ramus. The IVF also holds the recurrent meningeal nerve, the spinal branch of a segmental artery, veins, lymphatics and fat. Flexion opens the foramen; extension, same-side lateral flexion and rotation close it (Spurling).

The **dorsal ramus** supplies the deep back muscles, the facet joints and midline back skin; each facet gets medial branches from the level above and its own level. Named dorsal rami: suboccipital (C1, motor), greater occipital (C2), third occipital (C3, the C2 to C3 facet), and the cluneal nerves. The **ventral ramus** forms the plexuses and intercostal nerves; the phrenic nerve is C3 to C5. **White rami** (myelinated, preganglionic) exist only from **T1 to L2**; **gray rami** (unmyelinated, postganglionic) join all 31 nerves. The **recurrent meningeal (sinuvertebral) nerve** re-enters the canal to supply the PLL, anterior dura and outer posterior annulus and carries discogenic pain.

Dermatomes overlap, so one root lesion gives a small deficit and pinprick is the more sensitive screen. Most muscles have two or more roots, so a radiculopathy weakens but rarely paralyzes. Reflexes: **biceps C5 to C6, brachioradialis C6, triceps C7, patellar L4, Achilles S1**. C7 (from the C6 to C7 disc) is the commonest cervical radiculopathy. L5 weakens the EHL and heel walk with no reliable reflex; S1 weakens toe walk and the ankle jerk. Superficial reflexes: upper abdominal T8 to T10, lower T10 to T12, cremasteric L1 to L2, anal wink S2 to S4.

Cranial nerves I and II are CNS tracts, which is why the optic nerve is hit by multiple sclerosis. Exits: I cribriform plate, II optic canal, III, IV, V1 and VI superior orbital fissure, V2 foramen rotundum, V3 foramen ovale, VII and VIII internal acoustic meatus, **IX, X and XI jugular foramen**, XII hypoglossal canal. Eye muscles follow **LR6 SO4, all the rest 3**. Parasympathetics ride III, VII, IX and X. Sensory, motor or both: Some Say Marry Money, But My Brother Says Big Brains Matter More.

A compressive CN III lesion (posterior communicating aneurysm, uncal herniation) dilates the pupil early because the parasympathetic fibers are on the outside; a diabetic ischemic palsy often spares the pupil. CN IV palsy gives vertical diplopia looking down and in, and the head tilts away. CN VI has the longest course along the clivus and is a false localizing sign of raised pressure. The

spinal trigeminal tract descends to C2 to C3 and meets upper cervical input in the **trigeminocervical nucleus**, the basis of cervicogenic headache. **Bell palsy** takes the whole half of the face (forehead included); a cortical lesion spares the forehead. Hyperacusis means the stapedius is out.

The autonomic system uses two neurons. **Sympathetic**: thoracolumbar (T1 to L2 lateral horn), short preganglionic to the chain or prevertebral ganglia, long noradrenergic postganglionic, high divergence. **Parasympathetic**: craniosacral (III, VII, IX, X and S2 to S4), long preganglionic to ganglia near or in the organ, short cholinergic postganglionic. All ganglia use acetylcholine on **nicotinic NN** receptors. Exceptions: sweat glands get sympathetic acetylcholine (muscarinic), and the adrenal medulla receives preganglionic fibers directly and releases about 80% epinephrine.

In the chain a preganglionic fiber can synapse and return by a gray ramus, travel up or down (the cervical and sacral ganglia have no white rami), leave as a visceral branch (cardiac, pulmonary), or pass straight through as a **splanchnic nerve**: greater T5 to T9 to the celiac ganglion (foregut), lesser T10 to T11 to the aorticorenal and superior mesenteric ganglia, least T12 to the renal plexus, lumbar L1 to L2 to the inferior mesenteric plexus. The superior cervical ganglion supplies the head; the stellate ganglion is the fused inferior cervical and first thoracic. Interrupting the head supply gives **Horner syndrome** (ptosis, miosis, anhidrosis): Pancoast tumor, lateral medullary stroke, carotid dissection, T1 injury.

Cranial parasympathetic ganglia: III to the **ciliary** (pupil and lens), VII to the **pterygopalatine** (lacrimal) and **submandibular** (submandibular and sublingual glands), IX to the **otic** (parotid). The vagus reaches the gut to the splenic flexure; the pelvic splanchnics (S2 to S4) do the rest, the detrusor and erection. Receptors: M2 slows the heart, M3 contracts smooth muscle and drives glands, alpha 1 constricts vessels and dilates the pupil, beta 1 speeds the heart and releases renin, beta 2 dilates bronchi. Visceral pain returns along sympathetic routes to T1 to L2 and is felt in the matching dermatome.

The orbit's floor is weakest in a blowout fracture (inferior rectus trapped, upward gaze limited); the medial wall (lamina papyracea) is thinnest. The cornea provides about two thirds of refraction. Aqueous flows from the ciliary processes to the posterior chamber, through the pupil and out the canal of Schlemm. **Closed angle glaucoma** is an emergency (painful red eye, halos, mid-dilated

pupil). The fovea is all cones; the optic disc is the blind spot. The MLF links the abducens nucleus to the opposite medial rectus; an MLF lesion (multiple sclerosis) gives internuclear ophthalmoplegia.

Nasal retinal fibers cross at the chiasm. Optic nerve lesion: one blind eye. **Chiasm: bitemporal hemianopia** (pituitary). Optic tract: contralateral homonymous hemianopia. Meyer loop (temporal): contralateral upper quadrant, pie in the sky. Parietal radiations: pie on the floor. Visual cortex: homonymous hemianopia with macular sparing (PCA). The light reflex is **II in, III out** through the pretectum to both Edinger Westphal nuclei, so one eye lit constricts both. An afferent defect shows on the swinging flashlight test (Marcus Gunn); an efferent defect leaves that pupil dilated whichever eye is lit. Accommodation is convergence, constriction and lens rounding (ciliary muscle contracts, zonules relax).

The ossicles and the area ratio amplify sound about 20 times. Endolymph is potassium rich. The cochlear **base hears high pitch**, the apex low; noise and age damage the base first. The auditory pathway goes cochlear nuclei, superior olive, lateral lemniscus, inferior colliculus, MGN, Heschl gyri, and it is bilateral above the cochlear nuclei. **Weber** lateralizes to the bad ear in conductive loss and to the good ear in sensorineural loss; **Rinne** is negative (bone louder) only with conductive loss.

Otolith organs (utricle and saccule) sense linear acceleration and tilt; semicircular canals sense angular acceleration. **BPPV** is otoconia in the posterior canal: brief positional vertigo, torsional upbeating nystagmus on Dix Hallpike, treated with Epley. Peripheral vertigo has unidirectional nystagmus suppressed by fixation and an abnormal head impulse test; central vertigo may have vertical or direction-changing nystagmus, a normal head impulse test and other signs. Taste: VII anterior two thirds, IX posterior third, X epiglottis, all to the solitary nucleus, then VPM. Smell skips the obligatory thalamic relay; a cribriform fracture gives anosmia and CSF rhinorrhea.

The visual pathway and five classic lesions

Seen from above; lesions drawn on the left pathway

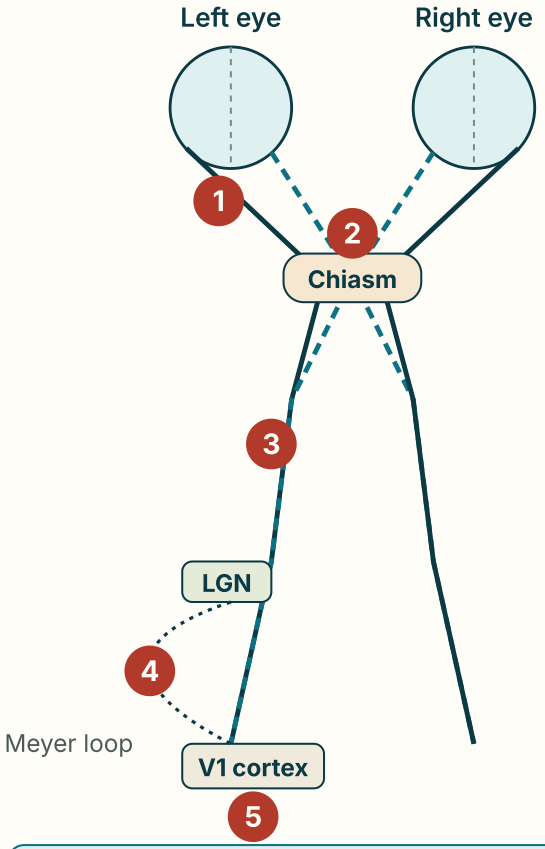

Lesion	L eye, R eye
1 **Left optic nerve** — Left eye blind	● ○
2 **Chiasm** — Bitemporal hemianopia	◐ ◐
3 **Left optic tract** — Right homonymous hemianopia	◑ ◑
4 **Left Meyer loop** — Right upper quadrant loss	◔ ◔
5 **Left visual cortex** — Right hemianopia, macula spared	◕ ◕

Dark = lost field

Nasal retinal fibers cross at the chiasm (temporal fields).
Temporal retinal fibers stay on their own side.

Crossing nasal fibers explain every defect. A chiasm lesion takes both temporal fields; any lesion behind the chiasm takes the opposite half field in both eyes.

LOCK THESE IN

- Roots join beyond the DRG in the IVF; the spinal nerve splits into dorsal and ventral rami.
- White rami T1 to L2 only; gray rami to all 31 nerves.
- Recurrent meningeal nerve: PLL, anterior dura, outer posterior annulus.
- Reflexes: biceps C5 to C6, brachioradialis C6, triceps C7, patellar L4, Achilles S1.
- LR6 SO4, rest 3; parasympathetics in III, VII, IX, X; IX, X, XI leave by the jugular foramen.
- All autonomic ganglia are nicotinic; sweat glands are sympathetic cholinergic; adrenal medulla is preganglionic.
- Chiasm lesion: bitemporal hemianopia. Behind the chiasm: contralateral homonymous defect.
- Weber goes to the bad ear in conductive loss; cochlear base hears high pitch.

The radiculopathy grid

Root (usual disc)	Weakness	Reflex and sensory area
C5 (C4 to C5)	Deltoid, biceps	Biceps; lateral arm
C6 (C5 to C6)	Wrist extensors, biceps	Brachioradialis; thumb and index
C7 (C6 to C7, most common)	Triceps, wrist flexors, finger extensors	Triceps; middle finger
C8 (C7 to T1)	Finger flexors	None reliable; little finger, medial forearm
T1 (T1 to T2)	Interossei	None; medial arm
L4 (L3 to L4)	Tibialis anterior, quadriceps	Patellar; medial leg and malleolus
L5 (L4 to L5)	EHL, gluteus medius, heel walk	None reliable; dorsum and great toe
S1 (L5 to S1)	Gastrocnemius, soleus, toe walk	Achilles; lateral foot and sole

Cranial nerves at a glance

Nerve	Exit	Key function and test
I	Cribriform plate	Smell, each nostril
II	Optic canal	Vision, fields; afferent light reflex
III	Superior orbital fissure	Most eye muscles, levator, pupil; down and out when lost
IV	Superior orbital fissure	Superior oblique; diplopia looking down and in
V	SOF (V1), rotundum (V2), ovale (V3)	Face sensation, chewing; afferent corneal reflex
VI	Superior orbital fissure	Lateral rectus
VII	Internal acoustic meatus, stylomastoid	Face muscles, taste front two thirds, tears, stapedius
VIII	Internal acoustic meatus	Hearing and balance; Weber, Rinne
IX	Jugular foramen	Posterior tongue taste, parotid; afferent gag
X	Jugular foramen	Palate, larynx, viscera; uvula away from lesion
XI	Jugular foramen	SCM and trapezius
XII	Hypoglossal canal	Tongue; deviates toward lesion

Worked cases

WORKED CASE 1 · LOCALIZING A CERVICAL RADICULOPATHY

Lena, 47, has neck pain into the right arm, weak elbow extension, numbness of the middle finger and a reduced triceps reflex.

STEP 1 · MATCH THE FINDINGS TO A ROOT

Triceps weakness, middle finger numbness and a reduced triceps reflex all point to C7.

STEP 2 · APPLY THE CERVICAL EXIT RULE

Cervical roots exit above their vertebra, so C7 leaves through the C6 to C7 foramen.

STEP 3 · NAME THE DISC

A posterolateral C6 to C7 disc, the commonest cervical radiculopathy.

STEP 4 · CONFIRM THE MECHANISM

Extension with rotation and lateral flexion toward the right narrows the foramen and should reproduce arm pain (Spurling).

WORKED CASE 2 · A DROOPY EYELID AND A SMALL PUPIL

Victor, 61, a smoker, has a droopy left eyelid, a small left pupil, a dry left side of the face and aching down the medial left arm with weak hand muscles.

STEP 1 · NAME THE TRIAD

Ptosis, miosis and anhidrosis are Horner syndrome: the sympathetic supply to the head is interrupted.

STEP 2 · TRACE THE CHAIN

Hypothalamus, down to T1 in the cord, out through the white ramus into the chain, up to the superior cervical ganglion, then along the carotid.

STEP 3 · USE THE ARM FINDINGS

Medial arm pain and weak intrinsics point to the lower trunk (C8, T1), which lies near the stellate ganglion at the lung apex.

STEP 4 · CONCLUDE

A left apical (Pancoast) tumor. Refer for chest imaging rather than treating it as a cervical problem.

WORKED CASE 3 · READING A FIELD DEFECT

A patient bumps into objects on both sides. Confrontation testing shows loss of the outer (temporal) half of the field in each eye.

STEP 1 · NAME THE DEFECT

Loss of both temporal fields is bitemporal heteronymous hemianopia.

STEP 2 · FIND THE FIBERS

Temporal fields fall on the nasal retina, and nasal retinal fibers are the ones that cross at the chiasm.

STEP 3 · LOCATE THE LESION

A lesion of the center of the chiasm cuts both crossing bundles.

STEP 4 · NAME THE USUAL CAUSE

A pituitary adenoma growing upward, or a craniopharyngioma. Refer for imaging.

TRAPS PEOPLE FALL INTO

- **Gray versus white rami.** White rami exist only at T1 to L2; gray rami reach every spinal nerve.
- **L5 reflex.** There is no reliable L5 reflex; diagnose L5 by the EHL, heel walk and the dorsum of the foot.
- **Parotid supply.** Parasympathetic to the parotid is CN IX through the otic ganglion, even though the gland sits on the face.
- **Uvula and tongue.** The uvula deviates away from a vagus lesion; the tongue deviates toward a hypoglossal lesion.
- **Weber in sensorineural loss.** It lateralizes to the good ear; in conductive loss it goes to the bad ear.
- **Pupil-sparing CN III.** Pupil sparing suggests ischemia (diabetes); a blown pupil suggests compression.

Chapter 6 self-test · ten board-style items

1. Which structure carries pain from the outer posterior annulus and the PLL?

A. Recurrent meningeal nerve
B. Lateral branch of the dorsal ramus
C. White ramus communicans
D. Medial branch of the dorsal ramus

A. Recurrent meningeal nerve The sinuvertebral nerve re-enters the canal through the IVF to supply the PLL, anterior dura and outer posterior annulus.

2. White rami communicantes are found at which levels?

A. S2 to S4 only
B. T1 to L2 only
C. All 31 spinal nerves
D. C1 to T1 only

B. T1 to L2 only Only T1 to L2 have the intermediolateral column, so only they send preganglionic fibers into the chain.

3. A patient has weak great toe extension, numbness on the dorsum of the foot and a normal Achilles reflex. Which root?

A. S1
B. L4
C. L5
D. S2

C. L5 EHL weakness and dorsal foot numbness are L5. A normal Achilles reflex argues against S1.

4. Which nerves leave the skull through the jugular foramen?

A. XII alone
B. III, IV and VI
C. VII and VIII
D. IX, X and XI

D. IX, X and XI IX, X and XI share the jugular foramen, so a tumor there causes a combined deficit.

5. A patient cannot wrinkle the right forehead, close the right eye or smile on the right, and has right hyperacusis. Where is the lesion?

A. The right facial nerve at the parotid
B. The left motor cortex face area
C. Right facial nerve above the stapedius
D. The right trigeminal motor root

C. Right facial nerve above the stapedius Forehead involvement means a peripheral lesion, and hyperacusis means the nerve to stapedius is involved, so the lesion is proximal to it.

6. Which ganglion relays parasympathetic fibers to the parotid gland?

A. Submandibular
B. Otic ganglion
C. Pterygopalatine
D. Ciliary ganglion

B. Otic ganglion Fibers from the inferior salivatory nucleus travel in CN IX and the lesser petrosal nerve to the otic ganglion, then ride the auriculotemporal nerve.

7. The greater thoracic splanchnic nerve arises from which levels and synapses where?

A. T5 to T9, celiac ganglion
B. T10 to T11, superior mesenteric
C. S2 to S4, intramural ganglia
D. L1 to L2, inferior mesenteric

A. T5 to T9, celiac ganglion The greater splanchnic carries preganglionic fibers from T5 to T9 to the celiac ganglion for the foregut.

8. A temporal lobe tumor produces which visual field defect?

A. Ipsilateral monocular blindness
B. Contralateral lower quadrantanopia
C. Bitemporal hemianopia only
D. Contralateral upper quadrantanopia

D. Contralateral upper quadrantanopia Meyer loop carries lower retinal fibers (upper field) through the temporal lobe: pie in the sky.

9. Light shone in the left eye causes no constriction of either pupil, but light in the right eye constricts both. Where is the lesion?

A. Left optic nerve
B. Left oculomotor nerve
C. Right optic nerve
D. Right oculomotor nerve

A. Left optic nerve An afferent (CN II) lesion stops both responses from the affected eye, while the efferent paths still work when the other eye is lit.

10. With a tuning fork, Weber lateralizes to the left and Rinne is negative on the left. What type of hearing loss is present?

A. Left sensorineural loss
B. Right conductive loss
C. Left conductive loss
D. Right sensorineural loss

C. Left conductive loss In conductive loss bone conduction beats air on that side and Weber lateralizes to the affected ear.

ONE PAGE

Cram sheet

Both chapters on one page. Cover the right columns and rebuild each row from memory. If a row will not come back, go back to that chapter.

Central nervous system

Topic	Rule	Board hook
Hematomas	Epidural arterial, biconvex; subdural venous, crescent	Lucid interval with epidural
CSF	500 mL a day; Monro, third, aqueduct, fourth, Magendie, Luschka	Aqueduct is the usual block
Cord	Conus L1 to L2; dural sac S2; LP at L3 to L5	Cervical plus 1, upper thoracic plus 2, lower plus 3
Laminae	II gelatinosa, V convergence, VII Clarke and IML, IX motor	Lateral horn T1 to L2
Blood supply	Anterior spinal front two thirds; Adamkiewicz T9 to T12 left	Anterior cord spares vibration
Crossings	DCML medulla; spinothalamic 1 to 2 segments; corticospinal pyramids	Spinocerebellar ipsilateral
Cord syndromes	Brown Sequard, central, anterior, syrinx, B12	Arms worse than legs: central cord
Brainstem	Crossed signs; nerve gives level	Wallenberg no weakness
Cortex	Broca 44, 45; Wernicke 22; vision 17	Internal capsule lacune: pure motor
Arteries	MCA face and arm; ACA leg; PCA vision	5 D's and 3 N's before manipulation

Peripheral nerves and senses

Topic	Rule	Board hook
Spinal nerve	Roots join beyond DRG; dorsal and ventral rami	Facet: two medial branches
Rami	White T1 to L2; gray all 31	Sinuvertebral: disc pain
Reflexes	C5 to C6 biceps, C7 triceps, L4 patellar, S1 Achilles	C7 commonest cervical root
Cranial nerves	LR6 SO4; 1973 parasympathetics	Tongue toward, uvula away
Autonomic	Sympathetic T1 to L2; parasympathetic III, VII, IX, X, S2 to S4	Ganglia nicotinic
Splanchnics	Greater T5 to T9 celiac; lesser T10 to T11; least T12	Pelvic splanchnics S2 to S4
Horner	Ptosis, miosis, anhidrosis	Pancoast, Wallenberg, carotid dissection
Vision	Chiasm bitemporal; behind chiasm homonymous	Meyer loop pie in the sky
Light reflex	II in, III out, both Edinger Westphal nuclei	Marcus Gunn afferent defect
Hearing	Base high pitch; Weber, Rinne	Conductive: Weber to bad ear
Balance	Otoliths linear; canals angular	BPPV: Dix Hallpike, Epley

An independent study aid, not affiliated with or endorsed by the National Board of Chiropractic Examiners.
Dr. Garg Learning · CC BY-SA 4.0