Study Guide 2

This guide covers chapters 3 and 4. Chapter 3 is the viscera, read the way a chiropractor needs them: where each organ sits, what supplies it, and how its pain can arrive dressed as back, shoulder or neck pain. Chapter 4 is home ground, the vertebral column, and spinal anatomy carries more Part I weight than any other domain. Work one chapter at a time. Read the "what to know" paragraphs, study the diagram, copy the tables by hand, then cover the steps of each worked case and reason it out before reading on. Finish with the ten board-style items. The cram sheet at the end puts both chapters on one page.

WHAT THIS GUIDE COVERS

- Chapter 3 · the mediastinum and sternal angle plane, chambers, valves, coronary arteries and dominance, conduction, the aorta and its branches by level, the great veins, azygos and vertebral venous plexus, lymph, the larynx and bronchial tree, lungs, pleura and diaphragm, the gut and peritoneum, the portal system, kidneys, ureters, bladder, reproductive organs, pelvic floor and the endocrine glands.
- Chapter 4 · the typical and atypical vertebrae, sacrum, ribs and skull base, the disc, facet orientation, uncovertebral joints, the intervertebral foramen and root levels, the upper cervical, costovertebral and sacroiliac joints, the spinal and craniovertebral ligaments, the back, suboccipital, prevertebral, scalene and abdominal muscles, the thoracolumbar fascia, and development and variants.

CHAPTER 3

Visceral Anatomy: Cardiovascular, Respiratory, Digestive, Urogenital and Endocrine Systems

Read it in full: **Chapter 3 in the review book**. Practice it: **the practice exams** (Exam 2 covers this chapter) and **the flashcards**.

What to know

The **sternal angle plane** (T4 to T5) splits the superior from the inferior mediastinum. The inferior part is anterior (fat, nodes, lower thymus in children), middle (the pericardial sac and heart) and

posterior (descending aorta, esophagus, thoracic duct, azygos system, sympathetic trunks). At the plane the aortic arch begins and ends, the trachea bifurcates, the azygos arches into the SVC, the thoracic duct crosses to the left and the left recurrent laryngeal nerve hooks under the arch. Anterior masses are the four T's; posterior masses in adults are usually neurogenic and can widen a foramen.

The fibrous and parietal pericardium are supplied by the **phrenic nerve** (C3 to C5), so pericarditis refers to the shoulder. Rapid effusion gives tamponade with Beck triad (hypotension, distended neck veins, muffled sounds). The apex sits in the left fifth intercostal space at the midclavicular line. The right ventricle forms most of the anterior surface, the **left atrium forms the base** and lies against the esophagus, and the left ventricle forms the apex and the left border.

The right coronary artery usually gives the SA nodal artery (about 60%), the AV nodal artery (about 80%) and, in right dominance, the posterior interventricular artery to the inferior wall. The **LAD** supplies the anterior wall, apex and anterior two thirds of the septum and is the vessel most often occluded. **Dominance** is set by which artery gives the posterior interventricular branch: about 70% right, 10% left, the rest codominant. Left ventricular flow is mainly diastolic, so tachycardia hurts the subendocardium. Cardiac pain travels with sympathetic afferents to T1 to T4 or T5, which is why ischemia can feel like upper thoracic or left arm pain.

Conduction runs SA node (upper crista terminalis near the SVC, 60 to 100 beats per minute), AV node (triangle of Koch, about a 0.1 second delay), bundle of His through the fibrous skeleton, bundle branches (the right one partly in the moderator band) and Purkinje fibers. The fibrous skeleton insulates atria from ventricles. Aortic arch branches run right to left: brachiocephalic, left common carotid, left subclavian. The abdominal aorta gives the **celiac trunk at T12, SMA at L1, renals at L1 to L2, gonadals at L2, IMA at L3** and bifurcates at L4.

The IVC forms at L5 and pierces the diaphragm at T8. The left gonadal and left suprarenal veins drain into the **left renal vein**, which crosses in front of the aorta below the SMA. The azygos system links IVC and SVC and connects with the valveless **vertebral venous plexus (Batson)**, the route by which prostate, breast, lung, kidney and thyroid cancers seed the spine. The thoracic duct begins at the cisterna chyli (L1 to L2), passes the aortic hiatus at T12, crosses left at T4 to T5

and drains into the left venous angle. A Virchow node in the left supraclavicular fossa suggests abdominal cancer.

The larynx spans C3 to C6. The **posterior cricoarytenoid** is the only abductor of the cords; the cricothyroid (external laryngeal nerve) tenses them; every other intrinsic muscle is recurrent laryngeal. The left recurrent nerve loops under the arch, the right under the subclavian; damage gives hoarseness. The right main bronchus is short, wide and vertical, so aspirated objects go right. The right lung has three lobes and two fissures; the left has two lobes, a lingula and only an oblique fissure. The pleura lies two ribs below the lung: lung 6, 8, 10 and pleura 8, 10, 12 at the midclavicular, midaxillary and paravertebral lines.

The diaphragm (phrenic, C3 to C5) passes the **IVC at T8, esophagus and vagal trunks at T10, aorta, thoracic duct and often the azygos at T12**. Quiet inspiration is diaphragm plus external intercostals (pump handle above, bucket handle below); quiet expiration is passive. Forced inspiration adds scalenes, SCM and pectorals; forced expiration uses the abdominal wall and quadratus lumborum. Diaphragmatic irritation refers to the C4 shoulder dermatome. A Pancoast tumor hits the lower plexus and sympathetic chain: shoulder and medial arm pain, hand weakness and Horner syndrome.

The gut follows embryology: foregut (celiac, epigastric pain), midgut (SMA, periumbilical pain), hindgut (IMA, suprapubic pain). The esophagus narrows at C6, at the arch and left bronchus (T4 to T5) and at the diaphragm (T10). The duodenum is mostly retroperitoneal; ulcers sit in the first part, and a posterior ulcer can erode the **gastroduodenal artery**. The ligament of Treitz divides upper from lower GI bleeding. Retroperitoneal organs: **SAD PUCKER** (suprarenals, aorta and IVC, duodenum 2 to 4, pancreas except the tail, ureters, ascending and descending colon, kidneys, esophagus, rectum).

The hepatoduodenal ligament carries the portal triad: portal vein behind, bile duct right front, hepatic artery left front, with the epiploic foramen behind. The liver takes about 75% of its blood from the portal vein. The portal vein forms behind the pancreatic neck from the superior mesenteric and splenic veins. In portal hypertension, four portocaval anastomoses open: **esophageal (varices), paraumbilical (caput medusae), anorectal and retroperitoneal**. The gallbladder fundus lies at the tip of the right ninth costal cartilage (Murphy sign); McBurney point

is a third of the way from ASIS to umbilicus. Pancreatic pain bores through to the back at T12 to L1.

The kidneys span T12 to L3, the right lower than the left, with the hilum at L1 holding vein, artery, pelvis front to back. Stones lodge at the **ureteropelvic junction, pelvic brim and ureterovesical junction**, and renal colic travels on T11 to L2 afferents from loin to groin. Clues that back pain is renal: colicky waves, restlessness, groin radiation, hematuria, fever and costovertebral angle tenderness not reproduced by spinal motion. The ureter passes under the uterine artery and under the ductus deferens.

S2 to S4 run the pelvis: pelvic splanchnics (parasympathetic) contract the detrusor and give erection; T11 to L2 sympathetics close the internal sphincter and give emission; the pudendal nerve controls the external sphincters. Cauda equina compression disturbs all three. The left testicular vein drains into the left renal vein, so varicoceles are commoner on the left, and a new one that does not empty lying down can mean a renal tumor. Testes drain to para-aortic nodes. The uterosacral ligaments explain cyclic sacral pain in gynecologic disease.

Endocrine anatomy: the pituitary sits in the sella under the optic chiasm (upward growth gives **bitemporal hemianopia**) between the cavernous sinuses. The thyroid isthmus crosses tracheal rings 2 to 4; the superior thyroid artery runs with the external laryngeal nerve and the inferior thyroid artery with the recurrent laryngeal nerve. Parathyroids sit on the back of the thyroid (removal gives hypocalcemic tetany). Each adrenal has three arteries and one vein (left to the left renal vein); the cortex is mesodermal (glomerulosa, fasciculata, reticularis) and the medulla neural crest.

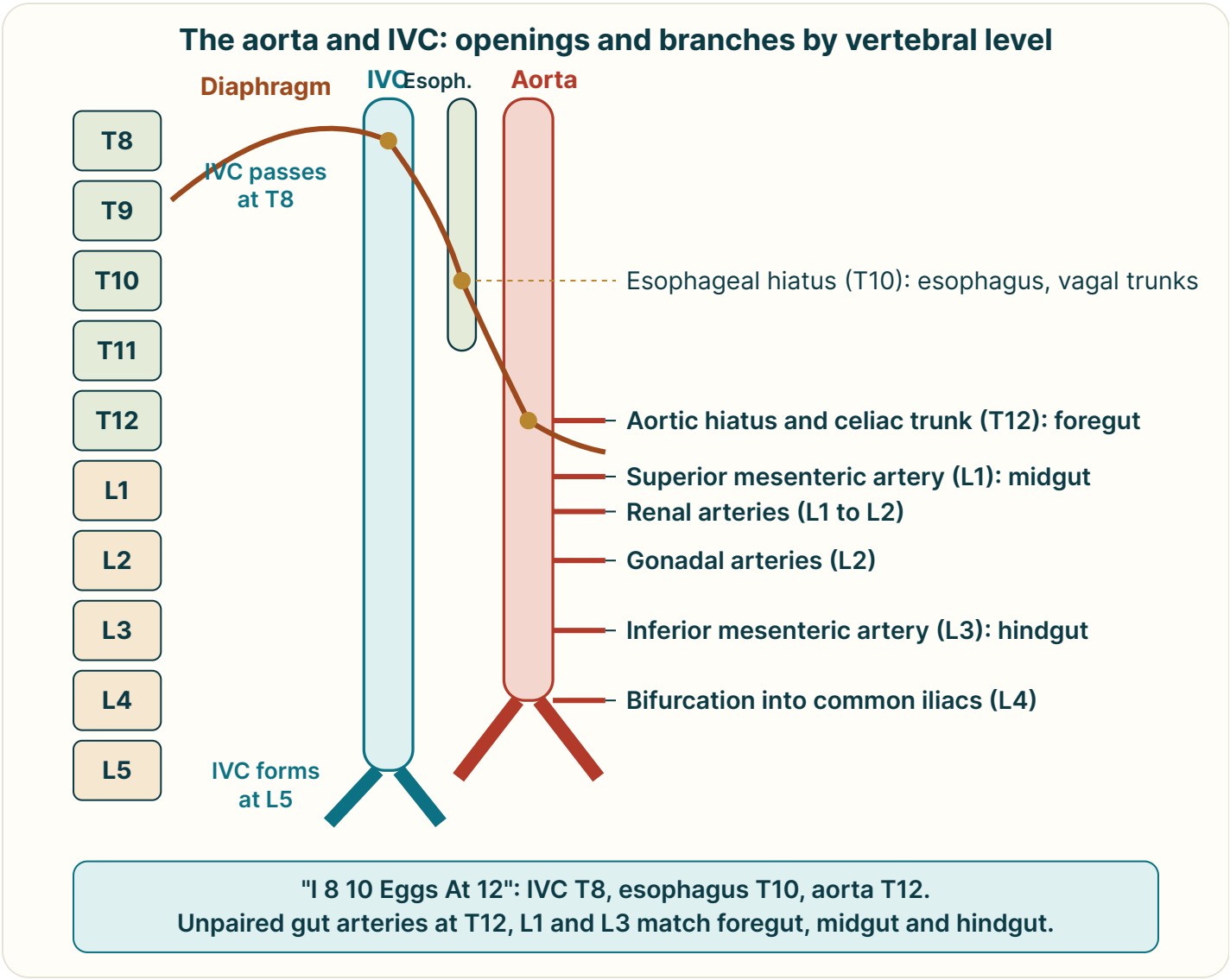

Levels organize the abdomen. The diaphragm openings and the unpaired gut arteries fall at fixed vertebral levels, which lets you find them on the surface and on film.

LOCK THESE IN

- Sternal angle (T4 to T5): arch begins and ends, carina, azygos into SVC, thoracic duct crosses left.
- RCA usually feeds the SA and AV nodes and the inferior wall; the LAD is most often occluded; dominance follows the posterior interventricular artery.
- Celiac T12, SMA L1, renals L1 to L2, gonadals L2, IMA L3, bifurcation L4.
- Diaphragm openings: IVC T8, esophagus T10, aorta T12 ("I 8 10 Eggs At 12").
- Lung borders 6, 8, 10; pleura 8, 10, 12 (midclavicular, midaxillary, paravertebral).
- Posterior cricoarytenoid is the only abductor of the vocal folds.
- Portocaval sites: esophageal, paraumbilical, anorectal, retroperitoneal.
- Ureteric stones: UPJ, pelvic brim, UVJ. Left gonadal and adrenal veins go to the left renal vein.

Levels of the great vessels and openings

Structure	Level	Note
Caval foramen	T8	IVC, right phrenic branches
Esophageal hiatus	T10	Esophagus, vagal trunks
Aortic hiatus	T12	Aorta, thoracic duct, often azygos
Celiac trunk	T12	Foregut: esophagus to second part of duodenum
Superior mesenteric artery	L1	Midgut: to proximal two thirds of transverse colon
Renal arteries	L1 to L2	Right renal passes behind the IVC
Gonadal arteries	L2	Testes and ovaries descended from here
Inferior mesenteric artery	L3	Hindgut: to upper rectum
Aortic bifurcation	L4	Level of the iliac crests
IVC formation	L5	From the common iliac veins
Cisterna chyli	L1 to L2	Start of the thoracic duct

Visceral pain and referral

Source	Afferent level or nerve	Where it is felt
Heart	T1 to T4 (T5) sympathetic afferents	Substernal, left arm, jaw, interscapular
Pericardium, central diaphragm	Phrenic nerve, C3 to C5	Shoulder and supraclavicular area (C4)
Foregut (stomach, gallbladder, pancreas)	Celiac territory	Epigastric; pancreas bores through to T12 to L1
Midgut (early appendicitis)	T10	Periumbilical, then right lower quadrant
Kidney and ureter	T11 to L2	Loin to groin, scrotum or labia, medial thigh
Spleen injury with blood under diaphragm	Phrenic	Left shoulder (Kehr sign)
Uterus and cervix	Uterosacral ligaments	Sacral and low back pain, often cyclic

Worked cases

WORKED CASE 1 · SHOULDER PAIN WITH NO SHOULDER FINDINGS

Pooja, 52, has right shoulder pain. Range of motion is full and painless, and orthopedic tests are negative. The pain is worse after fatty meals.

STEP 1 · NOTICE THE MISMATCH

A shoulder that moves freely and tests normal points away from the shoulder itself.

STEP 2 · RECALL THE REFERRAL

The diaphragm and its covering are supplied by the phrenic nerve (C3 to C5), so irritation refers to the C4 dermatome over the shoulder.

STEP 3 · FIND THE ORGAN

Meal-related right-sided pain plus diaphragmatic referral suggests the gallbladder, whose fundus lies at the tip of the right ninth costal cartilage.

STEP 4 · ACT

Examine the right upper quadrant (Murphy sign) and refer for medical evaluation rather than treating the shoulder.

WORKED CASE 2 · BACK PAIN AND A CALCIFIED LINE

Walter, 71, a long-time smoker, has new deep low back pain. A lateral lumbar film shows a curvilinear calcified bulge anterior to L3.

STEP 1 · LOCATE THE VESSEL

The abdominal aorta lies on the left front of the lumbar bodies and bifurcates at L4, so a calcified bulge in front of L2 to L4 is aortic.

STEP 2 · NAME THE PROBLEM

An abdominal aortic aneurysm, usually infrarenal, defined as a diameter of 3 cm or more.

STEP 3 · CHECK FOR DANGER

Feel for a pulsatile, expansile midline mass above the umbilicus. New pain in a known aneurysm suggests expansion.

STEP 4 · ACT

Avoid forceful lumbar manipulation and refer for vascular evaluation, urgently if symptomatic.

WORKED CASE 3 · CIRRHOSIS AND VOMITING BLOOD

A patient with long-standing alcohol-related cirrhosis vomits a large volume of blood.

STEP 1 · NAME THE PRESSURE PROBLEM

Scarring obstructs flow through the liver, raising portal pressure.

STEP 2 · LIST THE ESCAPE ROUTES

Blood diverts through the four portocaval anastomoses.

STEP 3 · MATCH THE SIGN

Vomiting blood points to the esophageal site: left gastric vein (portal) with esophageal veins to the azygos (systemic). Varices form and can bleed massively.

STEP 4 · CONTRAST THE OTHERS

Paraumbilical veins give caput medusae; superior with middle and inferior rectal veins give anorectal varices.

TRAPS PEOPLE FALL INTO

- **Base versus apex.** The base of the heart faces back and is mostly left atrium, not the top of the heart.

- **Dominance.** It is defined by the posterior interventricular artery, not by which coronary is larger.
- **Gonadal veins.** The left drains to the left renal vein; the right drains straight into the IVC.
- **Lung versus pleura.** The pleura reaches two ribs lower than the lung at every line, and dips below rib 12 medially.
- **Internal versus external hemorrhoids.** Above the pectinate line is visceral and painless; below is somatic (pudendal) and painful.
- **Cricothyroid.** It is the one intrinsic laryngeal muscle not supplied by the recurrent laryngeal nerve.

Chapter 3 self-test · ten board-style items

1. A patient with an inferior wall infarction develops bradycardia and heart block. Which artery is most likely occluded?

A. Left main coronary artery
B. Right coronary artery
C. Left anterior descending artery
D. Left circumflex artery

B. Right coronary artery In most people the RCA gives the posterior interventricular artery and the SA and AV nodal arteries, so inferior infarcts often come with conduction problems.

2. Which of these is a posterior mediastinal structure?

A. The pulmonary trunk
B. The ascending aorta
C. The thoracic duct
D. The thymic remnant

C. The thoracic duct The posterior mediastinum holds the descending aorta, esophagus, thoracic duct, azygos veins and sympathetic trunks. The ascending aorta and pulmonary trunk are middle mediastinum.

3. A child aspirates a peanut while sitting upright. Where does it most likely go?

A. Right main bronchus, lower lobe
B. Left main bronchus and lingula
C. Left lower lobe superior segment
D. Right upper lobe apical segment

A. Right main bronchus, lower lobe The right main bronchus is shorter, wider and more vertical, so aspirated material usually goes right and, upright, down into the lower lobe.

4. After a thyroidectomy, a patient has a weak, breathy voice and cannot fully open the glottis on one side. Which muscle has lost its nerve?

A. Thyroarytenoid (vocalis)
B. Lateral cricoarytenoid
C. Cricothyroid muscle
D. Posterior cricoarytenoid

D. Posterior cricoarytenoid The posterior cricoarytenoid is the only abductor of the vocal folds and is supplied by the recurrent laryngeal nerve, which runs near the inferior thyroid artery.

5. At which opening do the vagal trunks leave the thorax, and with what?

A. The T12 hiatus, with the aorta
B. The T10 hiatus, with the esophagus
C. The T8 foramen, with the IVC
D. The T12 hiatus, with the azygos

B. The T10 hiatus, with the esophagus IVC at T8, esophagus and vagal trunks at T10, aorta and thoracic duct at T12.

6. At the midaxillary line, the lower border of the parietal pleura lies at which rib?

A. Rib 10
B. Rib 8
C. Rib 12
D. Rib 6

A. Rib 10 Lung borders run 6, 8, 10 and pleural borders 8, 10, 12 at the midclavicular, midaxillary and paravertebral lines.

7. A posterior duodenal ulcer that perforates and bleeds heavily has most likely eroded which vessel?

A. Superior mesenteric artery
B. Splenic artery
C. Left gastric artery
D. Gastroduodenal artery

D. Gastroduodenal artery The gastroduodenal artery, from the common hepatic artery, runs behind the first part of the duodenum.

8. Which organ is intraperitoneal?

A. Descending colon
B. Head of the pancreas
C. Tail of the pancreas
D. Third part of the duodenum

C. Tail of the pancreas The pancreatic tail lies in the splenorenal ligament, the only intraperitoneal part. The rest of the list is retroperitoneal.

9. A man of 66 notices a new left scrotal swelling of veins that does not empty when he lies down. Which cause must be excluded?

A. Testicular torsion on the left
B. A right adrenal adenoma
C. An inguinal hernia on the left
D. A left renal tumor in the vein

D. A left renal tumor in the vein The left testicular vein drains into the left renal vein. A tumor obstructing that vein can produce a new varicocele that does not collapse when supine.

10. A pituitary adenoma grows upward. Which visual defect is expected?

A. Bitemporal hemianopia
B. Upper quadrantanopia
C. Homonymous hemianopia
D. Monocular blindness

A. Bitemporal hemianopia The chiasm sits above the pituitary, and its crossing nasal retinal fibers carry both temporal fields.

CHAPTER 4

The Vertebral Column: Bones, Joints, Ligaments and Muscles

Read it in full: **Chapter 4 in the review book**. Practice it: **the practice exams** (Exam 2 covers this chapter) and **the flashcards**.

What to know

The adult column has 33 vertebrae: 7 cervical, 12 thoracic, 5 lumbar, 5 fused sacral and about 4 coccygeal. A typical vertebra has a load-bearing **body** and a protective **arch** (two pedicles, two laminae) with seven processes: one spinous, two transverse and four articular. The **pars interarticularis** is the bone between the articular processes and the site of spondylolysis. To

identify a loose vertebra: a transverse foramen means cervical, costal facets on the body mean thoracic, neither with a large body and mammillary processes means lumbar.

Atypical vertebrae: **C1** has no body and no spinous process; its superior facets are concave and cradle the condyles, and a groove on the posterior arch carries the vertebral artery (sometimes bridged by a posterior ponticle). **C2** carries the dens and has a large bifid spinous process; its pars region is the site of the hangman fracture. **C7** has a long non-bifid spinous process, and its transverse foramina usually hold only veins because the vertebral artery enters at C6. T11 and T12 have a single full costal facet and no transverse costal facet; T12 is transitional. L5 is wedge shaped.

The sacrum transmits weight to the pelvis through its auricular surfaces (S1 to S3). The median crest is fused spinous processes, the intermediate crests are articular and the lateral crests transverse. The **sacral hiatus** comes from unfused S5 (often S4) laminae. True ribs are 1 to 7, false 8 to 10, floating 11 and 12. A typical rib head has two facets; rib 1 has one and a scalene tubercle. The costal groove holds vein, artery and nerve, top to bottom.

There are **23 discs**, from C2 to C3 down to L5 to S1; none between occiput and C1 or between C1 and C2. The nucleus pulposus (notochordal origin, about 80% water in youth, type II collagen and aggrecan) resists compression. The annulus fibrosus (15 to 25 lamellae at about 65 degrees, alternating) resists tension, shear and torsion and is thinnest **posterolaterally**. The adult disc is the largest avascular structure and is fed by diffusion through the endplates. Only the **outer third of the annulus** is innervated, posteriorly by the sinuvertebral (recurrent meningeal) nerve.

Facet orientation sets regional motion: cervical about 45 degrees to the horizontal (all motions fairly free; lateral flexion coupled with same-side rotation), thoracic about 60 degrees (rotation and lateral flexion; flexion and extension limited by ribs), lumbar about 90 degrees and near sagittal (flexion and extension free, rotation only a few degrees per level). Facet joints are synovial with meniscoid folds and are supplied by the **medial branch of the dorsal ramus** from the level above and the same level. Uncovertebral joints (C3 to C7) limit lateral translation and narrow the foramen when they hypertrophy.

The intervertebral foramen is bounded by pedicles above and below, the body and disc in front (plus the uncinate in the neck) and the facet capsule and ligamentum flavum behind. Cervical nerves C1 to C7 exit **above** their vertebra and C8 exits between C7 and T1; below that each nerve exits **below** its vertebra. A posterolateral **L4 to L5 herniation compresses the traversing L5 root**; a far lateral herniation at the same disc compresses the exiting L4 root. A C5 to C6 disc compresses C6. Extension and ipsilateral lateral flexion narrow the foramen (Spurling).

The **atlanto-occipital joints** are condyloid and nod (yes joint, about 15 to 25 degrees). The **atlantoaxial** complex is a median pivot plus two lateral joints and gives about 40 degrees of rotation each way, roughly half of cervical rotation. The transverse ligament holds the dens; an adult **atlantodental interval over 3 mm** (5 mm in a child) means it is incompetent (rheumatoid arthritis, Down syndrome, trauma), and upper cervical manipulation is contraindicated. The alar ligaments check rotation; the tectorial membrane continues the PLL to the clivus.

The **ALL** is broad, runs on the front of the bodies and discs and limits extension. The **PLL** runs inside the canal, attaches more firmly to discs, limits flexion, is richly innervated, and **narrows in the lumbar spine**, leaving the posterolateral annulus exposed. The **ligamentum flavum** (about 80% elastin) joins laminae from C2 to S1, is the only elastic one in the canal wall, and thickens and buckles in stenosis. The supraspinous ligament runs C7 to about L3 or L4 and becomes the nuchal ligament above. The iliolumbar ligament anchors L5 to the ilium; the interosseous ligament is the strongest SI bond.

The SI joint is synovial in front and below and a syndesmosis behind and above. Motion is small. **Nutation** (sacral base forward and down) is the stable, close-packed position and is resisted by the sacrotuberous, sacrospinous and interosseous ligaments; **counternutation** is resisted by the long dorsal SI ligament. Sacroiliitis is an early sign of ankylosing spondylitis and starts in the synovial lower part. The thoracic and sacral kyphoses are primary curves; the cervical and lumbar lordoses are secondary, formed mainly by wedge-shaped discs. The lumbosacral angle averages about 41 degrees.

All intrinsic back muscles are supplied by **dorsal rami**. The four suboccipitals (C1 dorsal ramus) are spindle-rich postural sensors; the suboccipital triangle (rectus capitis posterior major, obliquus capitis superior and inferior) holds the vertebral artery and suboccipital nerve, and the greater

occipital nerve (C2) emerges below obliquus capitis inferior. Erector spinae (iliocostalis, longissimus, spinalis) extends and laterally flexes. The transversospinalis group (semispinalis, multifidus, rotatores) **rotates to the opposite side**; multifidus is the key lumbar stabilizer and atrophies after back pain.

Rotation direction is the commonest muscle trap. **Same side**: splenius, obliquus capitis inferior, rectus capitis posterior major, internal oblique. **Opposite side**: SCM, semispinalis, multifidus, rotatores, external oblique. The scalenes frame the thoracic outlet (plexus and subclavian artery pass between anterior and middle scalene; the vein passes in front). Quadratus lumborum hikes the hip and fixes rib 12. Psoas houses the lumbar plexus; a psoas abscess gives flank pain, fever and a hip held flexed. The thoracolumbar fascia links latissimus to the opposite gluteus maximus across the SI joints.

Development: somites appear about day 20; each sclerotome splits, and by **resegmentation** the caudal half of one joins the cranial half of the next, so each vertebra is intersegmental, nerves pass between vertebrae, and there are 8 cervical nerves but 7 cervical vertebrae. The notochord survives as the nucleus pulposus. Ossification starts about week 8 from three primary centers; neurocentral fusion is at 3 to 6 years and secondary centers fuse by about 25. Variants: block vertebra (C2 to C3, wasp waist), hemivertebra (congenital scoliosis), butterfly vertebra, spina bifida occulta (L5, S1), transitional segments and spondylolysis (L5 in about 85 to 90%).

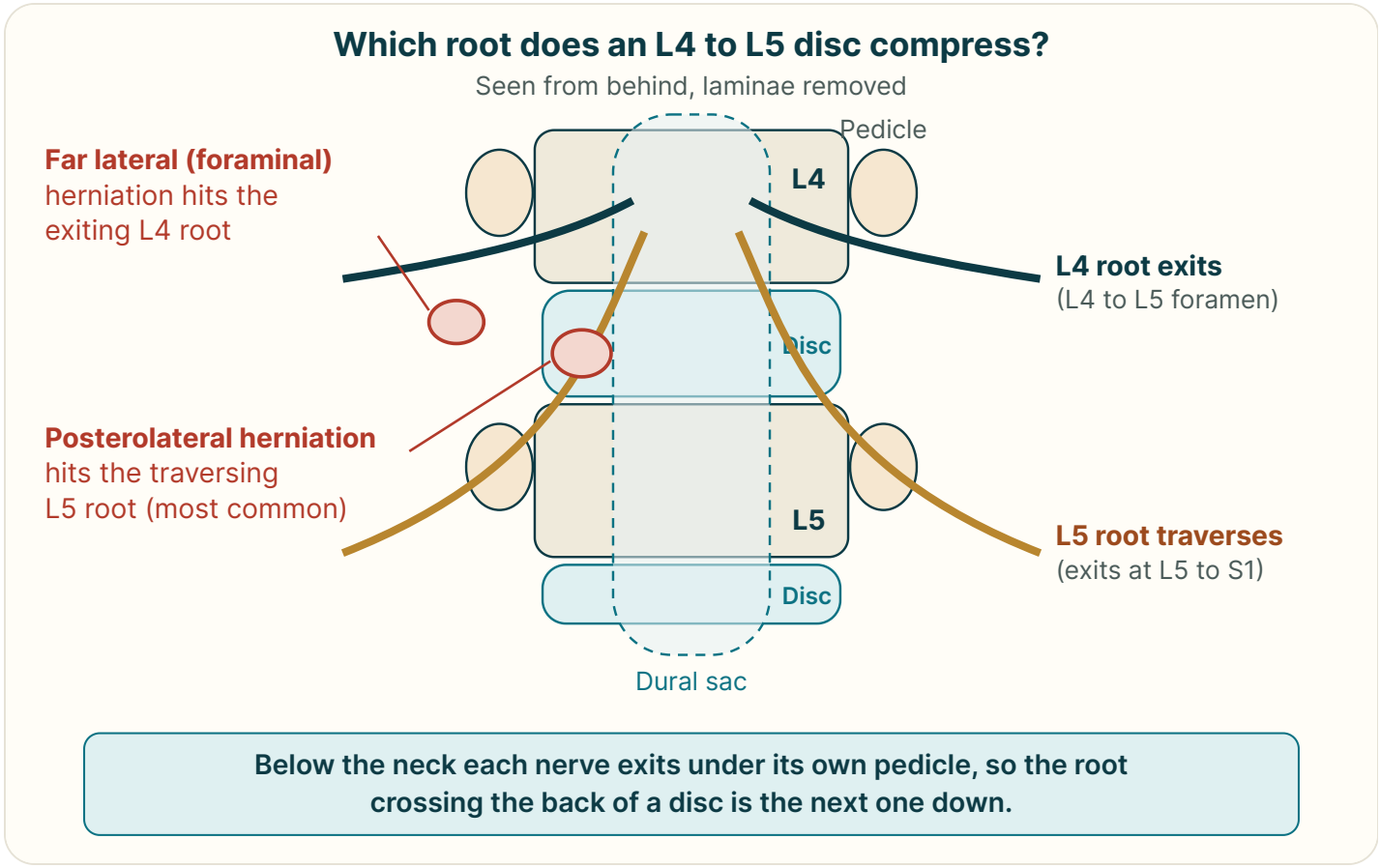

The traversing root takes the hit. A posterolateral L4 to L5 herniation compresses L5; only a far lateral herniation reaches the exiting L4 root.

LOCK THESE IN

- Transverse foramen = cervical; costal facets = thoracic; big body plus mammillary processes = lumbar.
- 23 discs; only the outer third of the annulus is innervated (sinuvertebral nerve posteriorly).
- Facet planes: cervical 45, thoracic 60, lumbar 90 degrees to the horizontal.
- Posterolateral L4 to L5 herniation hits the traversing L5 root; far lateral hits the exiting L4 root.
- Adult ADI over 3 mm (child 5 mm) means transverse ligament failure; no upper cervical manipulation.
- ALL limits extension; PLL narrows in the lumbar spine; ligamentum flavum is elastic and buckles in stenosis.
- Transversospinalis and the external oblique rotate to the opposite side; splenius and internal oblique to the same side.
- Resegmentation explains intersegmental vertebrae and 8 cervical nerves with 7 cervical vertebrae.

Regional features of the vertebrae

Feature	Cervical / Thoracic	Lumbar
Body	Small with uncinates / heart shaped with costal demifacets	Large, kidney shaped, no costal facets
Vertebral foramen	Large triangular / small circular	Medium triangular
Transverse process	Foramen with tubercles / costal facets T1 to T10	Long, thin, accessory process
Spinous process	Short bifid / long, steep downward	Short, broad, hatchet shaped
Facet plane	About 45 degrees / about 60 degrees, coronal	About 90 degrees, near sagittal
Freest motion	All fairly free / rotation and lateral flexion	Flexion and extension
Most restricted	Little / flexion and extension	Axial rotation

Ligaments and what they limit

Ligament	Attachments	Limits or does
Anterior longitudinal	Front of bodies and discs, basiocciput to sacrum	Extension
Posterior longitudinal	Back of bodies and discs, C2 to sacrum	Flexion; narrow in the lumbar spine
Ligamentum flavum	Lamina to lamina, C2 to S1	Flexion; elastic, buckles in stenosis
Supraspinous and interspinous	Spinous processes	Flexion; supraspinous often absent at L5 to S1
Transverse ligament of atlas	Between the lateral masses behind the dens	Anterior translation of C1 on C2
Alar ligaments	Dens to occipital condyles	Rotation and lateral flexion of the head
Tectorial membrane	C2 body to clivus	Flexion; continuation of the PLL
Iliolumbar	L5 transverse process to iliac crest	Forward slip and rotation of L5 on S1
Sacrotuberous and sacrospinous	Sacrum to ischial tuberosity and spine	Nutation; form the sciatic foramina

Worked cases

WORKED CASE 1 · WHICH ROOT IS IT?

Dana, 41, has back pain radiating to the dorsum of the left foot and great toe. MRI shows a left posterolateral disc herniation at L4 to L5.

STEP 1 · RECALL THE EXIT RULE

Below the neck, each nerve exits below its numbered vertebra. The L4 root leaves through the L4 to L5 foramen, passing under the L4 pedicle above the level of the disc.

STEP 2 · FOLLOW THE TRAVERSING ROOT

The L5 root crosses the back of the L4 to L5 disc on its way down to the L5 to S1 foramen.

STEP 3 · APPLY THE HERNIATION TYPE

A posterolateral herniation sits where the PLL is narrow and the annulus is thin, right in the path of the traversing L5 root.

STEP 4 · MATCH THE FINDINGS

Dorsum of the foot and great toe is the L5 dermatome, so the picture fits an L5 radiculopathy.

CONTRAST

A far lateral (foraminal) herniation at L4 to L5 would compress the exiting L4 root instead: medial leg numbness and a weak patellar reflex.

WORKED CASE 2 · A WIDENED GAP IN FRONT OF THE DENS

Ruth, 63, has long-standing rheumatoid arthritis and neck pain. A flexion lateral cervical film shows a 6 mm gap between the anterior arch of C1 and the dens.

STEP 1 · NAME THE MEASURE

The atlantodental interval (ADI). Normal is up to 3 mm in an adult and 5 mm in a child.

STEP 2 · NAME THE FAILED STRUCTURE

The transverse ligament of the atlas, which holds the dens against the anterior arch.

STEP 3 · EXPLAIN WHY

Rheumatoid synovitis around the median atlantoaxial joint weakens the ligament.

STEP 4 · ACT

Upper cervical manipulation is contraindicated. Refer for evaluation of instability.

WORKED CASE 3 · COUNTING LEVELS ON A FILM

A lumbar series shows only four mobile lumbar-type segments above a large sacrum, and the lowest one has a broad transverse process that meets the sacral ala on one side.

STEP 1 · NAME THE VARIANT

A lumbosacral transitional vertebra, here a sacralized L5 with a unilateral pseudarthrosis.

STEP 2 · RECOGNIZE THE RISK

Transitional segments are the most common cause of naming the wrong level.

STEP 3 · COUNT RELIABLY

Count down from C2 on a full spine view, or up from the last rib-bearing vertebra, and state the method in the report.

STEP 4 · NOTE THE CLINICAL LINK

A unilateral pseudarthrosis can be painful (Bertolotti syndrome), and the level above degenerates faster.

TRAPS PEOPLE FALL INTO

- **Disc count.** There are 23 discs. None between occiput and C1 or between C1 and C2.
- **Cervical exits.** C nerves exit above their vertebra, and C8 exits between C7 and T1. Everything below exits below.
- **Same-side versus opposite-side rotation.** Multifidus and the external oblique rotate to the opposite side; splenius and the internal oblique to the same side.
- **Nutation.** Sacral base forward and down; it is the stable position, resisted by the sacrotuberous and sacrospinous ligaments.
- **The vertebral artery.** It usually enters the transverse foramen of C6, not C7.
- **Spondylolysis.** It is a fatigue fracture of the pars, not a true congenital anomaly, most often at L5.

Chapter 4 self-test · ten board-style items

1. An isolated vertebra has costal facets on the body but no transverse costal facets, and a single full facet on each side. Which levels fit?

A. T1 or T2
B. T5 or T6
C. T11 or T12
D. L1 or L2

C. T11 or T12 T11 and T12 carry floating ribs that articulate with the body or pedicle only, so they have a single full facet and no transverse costal facet.

2. Which part of the disc is innervated?

A. The whole of the nucleus pulposus
B. The outer third of the annulus
C. The inner annular lamellae
D. The center of the endplates

B. The outer third of the annulus Only the outer annulus receives nerves, posteriorly from the sinuvertebral nerve. The disc is otherwise avascular and aneural.

3. A posterolateral herniation of the C5 to C6 disc most likely compresses which root?

A. C7
B. C8
C. C5
D. C6

D. C6 Cervical roots exit above their numbered vertebra, so the C6 root leaves through the C5 to C6 foramen.

4. Which region's facet orientation most limits axial rotation?

A. Lumbar, near the sagittal plane
B. Cervical, at about 45 degrees
C. Upper cervical, condyloid joints
D. Thoracic, near the coronal plane

A. Lumbar, near the sagittal plane Lumbar facets are nearly sagittal, about 90 degrees to the horizontal, so they lock in rotation while allowing flexion and extension.

5. A patient with rheumatoid arthritis has an atlantodental interval of 5 mm on a flexion film. What is the best next step?

A. Call it normal for her age
B. Hold manipulation and refer
C. Adjust C1 with a light thrust
D. Repeat the film in a year

B. Hold manipulation and refer An adult ADI over 3 mm means the transverse ligament is incompetent. Manipulation is contraindicated until the instability is evaluated.

6. Why do most lumbar disc herniations go posterolaterally?

A. The PLL is narrow and the annulus thin
B. The facets push the disc backward
C. The nucleus sits far anterior
D. The ALL is weakest posterolaterally

A. The PLL is narrow and the annulus thin The lumbar PLL reinforces only the midline, and the annulus is thinnest posterolaterally.

7. Which ligament is about 80% elastin and lies in the posterior wall of the canal?

A. Supraspinous ligament
B. The posterior ligament
C. The ligamentum flavum
D. Interspinous ligament

C. The ligamentum flavum The ligamentum flavum joins adjacent laminae, stays under tension in neutral and buckles inward with age and disc narrowing.

8. Acting on one side, which muscle rotates the trunk to the opposite side?

A. Longissimus
B. Internal oblique
C. Splenius
D. Multifidus

D. Multifidus The transversospinalis group, including multifidus, and the external oblique rotate to the opposite side. The others listed rotate to the same side.

9. What runs inside the suboccipital triangle itself?

A. Spinal accessory nerve and C2 root
B. Greater occipital nerve and occipital artery
C. Internal carotid artery and vagus nerve
D. Vertebral artery and suboccipital nerve

D. Vertebral artery and suboccipital nerve The triangle holds the third part of the vertebral artery on the atlas and the suboccipital nerve (C1). The greater occipital nerve emerges below obliquus capitis inferior.

10. Why are there eight cervical nerves but only seven cervical vertebrae?

A. The first sclerotome joins the skull
B. The dens is a separate vertebra
C. C8 branches from the T1 nerve
D. C1 has two nerve roots per side

A. The first sclerotome joins the skull In resegmentation the cranial half of the first cervical sclerotome fuses with the occiput, so the first nerve exits above C1 and the eighth between C7 and T1.

Cram sheet

Both chapters on one page. Cover the right columns and rebuild each row from memory. If a row will not come back, go back to that chapter.

Viscera

Topic	Rule	Board hook
Mediastinum	Sternal angle T4 to T5 splits superior from inferior	Four T's in front; neurogenic tumors behind
Heart surfaces	RV anterior, LA base, LV apex	Apex beat left 5th ICS, MCL
Coronaries	RCA nodes and inferior wall; LAD anterior and septum	Dominance by posterior interventricular
Conduction	SA, AV (0.1 s), His, bundle branches, Purkinje	Moderator band carries the right bundle
Aorta levels	Celiac T12, SMA L1, renal L1 to L2, IMA L3, split L4	IVC forms L5
Diaphragm	IVC T8, esophagus T10, aorta T12	Phrenic C3 to C5
Lungs	Right 3 lobes, left 2 plus lingula	Lung 6, 8, 10; pleura 8, 10, 12
Gut	Foregut celiac, midgut SMA, hindgut IMA	SAD PUCKER retroperitoneal
Portal	SMV plus splenic behind pancreatic neck	Esophageal, umbilical, rectal, retroperitoneal
Kidney	T12 to L3, right lower, hilum L1	Stones at UPJ, brim, UVJ
Pelvis	S2 to S4 bladder, bowel, sex	Cauda equina affects all three
Endocrine	Pituitary under chiasm; adrenal 3 arteries, 1 vein	Superior thyroid with external laryngeal nerve

Vertebral column

Topic	Rule	Board hook
Count	7 C, 12 T, 5 L, 5 S, about 4 Co; 23 discs	No disc at C0 to C1 or C1 to C2
Identify	Transverse foramen C; costal facets T; mammillary L	C7 non-bifid; T11, T12 single facet
Disc	Nucleus compression; annulus tension and torsion	Outer third innervated
Facets	45, 60, 90 degrees	Lumbar limits rotation
Roots	C exits above; others below	L4 to L5 posterolateral hits L5
Upper cervical	C0 to C1 nods; C1 to C2 rotates about 40 degrees each way	ADI over 3 mm adult unstable
Ligaments	ALL extension; PLL, flavum, interspinous flexion	Lumbar PLL narrow
SI joint	Nutation stable; sacrotuberous resists it	Sacroiliitis early in AS
Muscles	Intrinsic back muscles by dorsal rami	Transversospinalis rotates opposite
Development	Resegmentation; notochord to nucleus	Block C2 to C3; spondylolysis L5

An independent study aid, not affiliated with or endorsed by the National Board of Chiropractic Examiners.
Dr. Garg Learning · CC BY-SA 4.0