Study Guide 1

This guide covers the first two chapters of the review book, the appendicular half of general anatomy. Chapter 1 builds the map: planes, landmarks, skin, bones and joints. Chapter 2 hangs the muscles, nerves and vessels on that map, and it is where the board asks its most precise questions (one muscle, one nerve, one root, one lesion). Work one chapter at a time. Read the "what to know" paragraphs, study the diagram, copy the tables out by hand, then cover the steps of each worked case and reason it out yourself before you read on. Finish each chapter with its ten board-style items. The cram sheet at the end puts both chapters on one page.

WHAT THIS GUIDE COVERS

- Chapter 1 · anatomical position, planes and axes, surface landmarks with their vertebral levels, the epidermis, dermis, appendages and receptors, dermatomes, the bones of both limbs, the pelvis and femoral angles, joint classification, close-packed positions, capsular patterns and the ligaments and classic injuries of each limb joint.
- Chapter 2 · the scapular stabilizers and rotator cuff, the arm, forearm and hand muscles, the carpal tunnel and Guyon canal, the brachial plexus and its lesions, the upper limb arteries, veins and nodes, the hip, thigh, leg and foot muscles, the lumbar and sacral plexuses, gait from nerve lesions, and the lower limb vessels.

CHAPTER 1

Topographical Anatomy and the Appendicular Skeleton

Read it in full: **Chapter 1 in the review book**. Practice it: **the practice exams** (Exam 1 covers this chapter) and **the flashcards**.

What to know

All description assumes the **anatomical position**: standing, facing forward, arms at the sides, palms forward, feet forward. Terms are read as if the patient stood this way, so the radius and thumb are lateral even when the forearm is pronated. A **sagittal** plane divides right from left (the

midline one is the median plane), a **frontal (coronal)** plane divides front from back, and a **transverse** plane divides top from bottom. Axial CT and MRI slices are viewed from the feet, so the patient's right is on the viewer's left.

Movement happens in a plane and about the axis perpendicular to it. Flexion and extension: sagittal plane, coronal axis. Abduction and adduction: frontal plane, anteroposterior axis. Rotation: transverse plane, vertical axis. The thumb is the exception people miss: it sits rotated 90 degrees, so it flexes in the frontal plane. Finger abduction is measured from the middle finger, toe abduction from the second toe.

Surface landmarks become powerful when you tie them to a **vertebral level**. In the neck: hyoid C3, upper thyroid cartilage C4 (carotid bifurcation), cricoid C6 (larynx becomes trachea, pharynx becomes esophagus, carotid tubercle deep to it). The **sternal angle** is the single most tested trunk landmark: rib 2 joins here and a plane through it reaches the T4 to T5 disc, the tracheal bifurcation, both ends of the aortic arch, the azygos entering the SVC and the line between superior and inferior mediastinum.

Lower down: xiphisternal junction T9, **transpyloric plane** L1 (pylorus, renal hila, SMA origin, pancreatic neck, near the conus), subcostal plane L3, umbilicus at the L3 to L4 disc in the T10 dermatome, aortic bifurcation L4, iliac crests at L4 or L4 to L5 (the lumbar puncture landmark), and the PSIS dimples at S2 (end of the dural sac, middle of the SI joints). Behind: C7 is the vertebra prominens and glides forward under your finger with extension while T1 stays put; the scapular spine root is T3, the inferior angle T7.

The **epidermis** is avascular keratinized stratified squamous epithelium. Deep to superficial: basale (stem cells, melanocytes, Merkel cells), spinosum (desmosomes, Langerhans cells), granulosum (keratohyalin and the lipid barrier), lucidum (thick skin of palms and soles only) and corneum. The **dermis** is papillary (loose, capillary loops, Meissner corpuscles) over reticular (dense irregular, type I collagen, cleavage lines). The hypodermis holds the deep Pacinian corpuscles.

Appendages are favorite one-liners. Sebaceous glands are **holocrine** and androgen sensitive. Eccrine sweat glands are merocrine and supplied by **sympathetic fibers that release acetylcholine** on muscarinic receptors. Apocrine glands open into follicles in the axilla, areola and

anogenital skin and wake at puberty. The arrector pili is smooth muscle driven by sympathetic alpha-1 receptors. Among receptors, Meissner (superficial) and Pacinian (deep, vibration) adapt rapidly; Merkel (sustained pressure) and Ruffini (stretch) adapt slowly.

A **dermatome** is the skin of one root, which is not the same as the territory of a peripheral nerve. Test points: C5 lateral arm, C6 thumb, C7 middle finger, C8 little finger, T4 nipple, T10 umbilicus, L1 groin, L4 medial leg and malleolus, L5 dorsum of foot and great toe, S1 lateral foot and sole. Herpes zoster follows one dermatome and stops at the midline. Burns use the rule of nines: 9% head, 9% each arm, 18% each side of the trunk, 18% each leg, 1% perineum.

Each upper limb has 32 bones and joins the trunk only at the SC joint, so it trades stability for reach. Nerve to bone pairs drive many items: **axillary nerve at the surgical neck**, **radial nerve in the spiral groove** at midshaft, **ulnar nerve behind the medial epicondyle**, median nerve and brachial artery at the supracondylar region. The suprascapular artery passes above the transverse scapular ligament and the nerve below it. The clavicle ossifies first, fuses last and is the most often fractured bone.

At the wrist the **scaphoid** is the most often fractured carpal (snuffbox tenderness, normal first film possible, proximal pole at risk of avascular necrosis because blood enters distally), the **lunate** is the most often dislocated, and the pisiform and hook of hamate frame Guyon canal. Colles fracture displaces the distal radius dorsally (dinner fork); Smith displaces it volarly. Boxer's fracture is the fifth metacarpal neck; Bennett is an intra-articular first metacarpal base fracture.

In the lower limb, the hip bone is ilium, ischium and pubis fused at the acetabulum. The femoral neck meets the shaft at about **125 degrees** (smaller is coxa vara, larger is coxa valga), with 10 to 15 degrees of anteversion. The head depends on the **medial circumflex femoral artery**, so a displaced intracapsular neck fracture risks avascular necrosis. The common fibular nerve winds around the fibular neck, the talus has no muscle attachments, and the Q angle is about 13 degrees in men and 18 in women.

Joints are fibrous (suture, syndesmosis, gomphosis), cartilaginous (synchondrosis of hyaline cartilage, symphysis of fibrocartilage) or synovial. The six synovial shapes are plane, hinge, pivot, condyloid, saddle and ball and socket. The **close-packed** position is the most congruent and stable

(knee full extension, ankle dorsiflexion, hip extension with medial rotation and abduction, shoulder abduction with lateral rotation). The **capsular pattern** is the proportional loss of motion when the whole capsule is involved (shoulder: lateral rotation, then abduction, then medial rotation; hip: medial rotation, flexion, abduction).

Joint injuries follow anatomy. Over 95% of shoulder dislocations are anterior (axillary nerve, Bankart lesion, Hill-Sachs impaction); hips usually dislocate posteriorly (dashboard injury, sciatic nerve at risk, limb shortened, flexed, adducted and medially rotated). The cruciates are named for their tibial ends; the ACL stops anterior tibial translation (Lachman most sensitive), the PCL posterior. The medial meniscus is bound to the MCL and tears more often. The ankle is stable in dorsiflexion, so inversion in plantarflexion tears the ATFL first, then the calcaneofibular ligament.

Surface landmarks and their vertebral levels

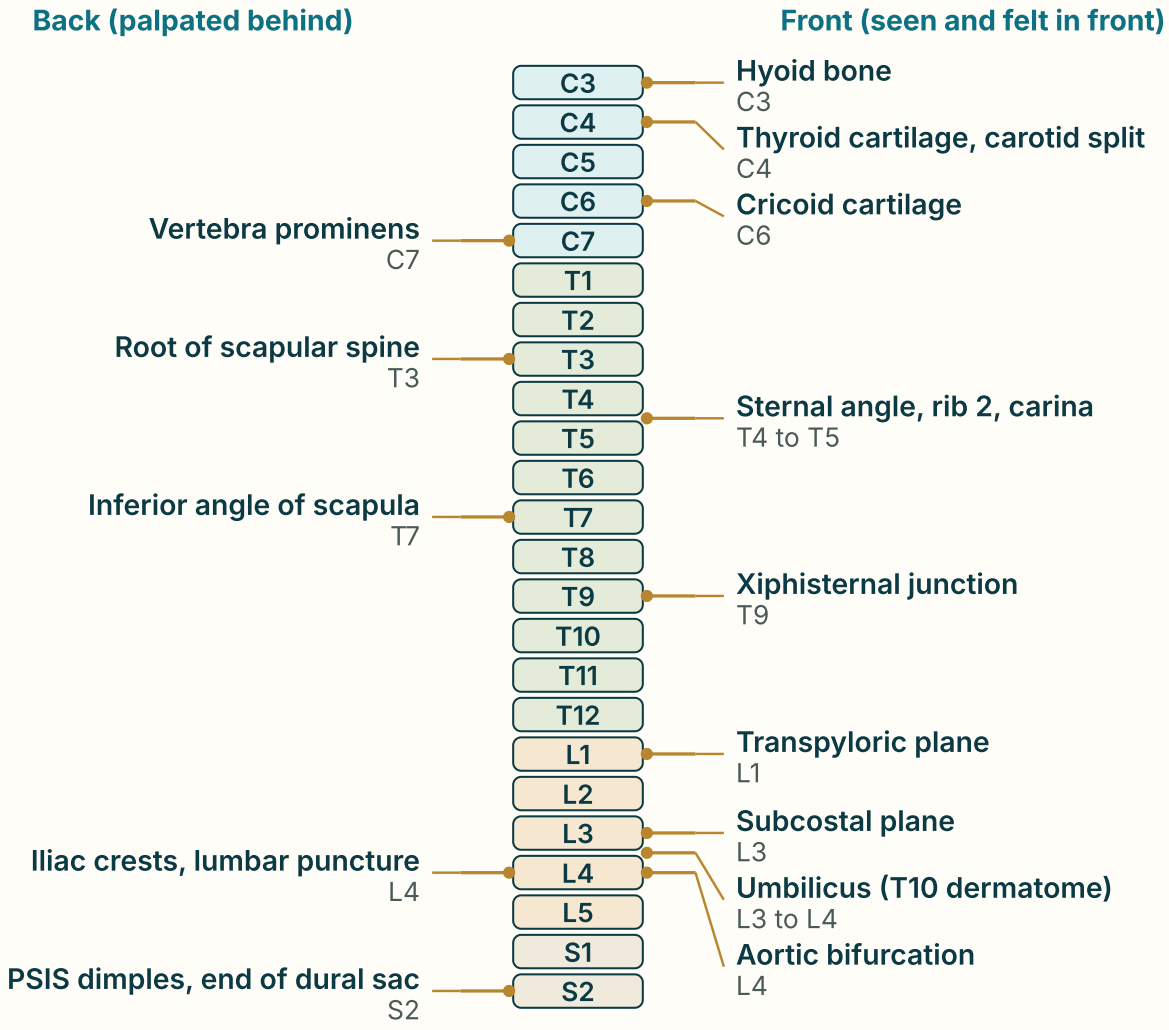

Board favorite: the sternal angle plane (T4 to T5) marks rib 2, the tracheal bifurcation, both ends of the aortic arch and the azygos entering the SVC.

Landmarks become levels. Tie every surface landmark to a vertebra and you can locate viscera, vessels and spinal segments from the outside.

LOCK THESE IN

- Movement occurs in a plane about the perpendicular axis: abduction is frontal plane, anteroposterior axis.
- Hyoid C3, thyroid cartilage C4, cricoid C6, sternal angle T4 to T5, xiphisternum T9, transpyloric L1, umbilicus L3 to L4 and T10, iliac crests L4, PSIS S2.
- Stratum lucidum only in thick skin; eccrine glands are sympathetic cholinergic; sebaceous glands are holocrine.
- C6 thumb, C7 middle finger, C8 little finger, L4 medial malleolus, L5 great toe and dorsum, S1 lateral foot.
- Axillary nerve at the surgical neck, radial in the spiral groove, ulnar behind the medial epicondyle.
- Scaphoid fractures (AVN of the proximal pole); lunate dislocates; Colles is dorsal, Smith is volar.
- Femoral neck angle about 125 degrees; the head relies on the medial circumflex femoral artery.
- Shoulders dislocate anteriorly, hips posteriorly; ATFL is the first ankle ligament to tear.

Surface landmarks and vertebral levels

Landmark	Level	What else is there
Hyoid bone	C3	Root of the tongue
Upper border of thyroid cartilage	C4	Common carotid bifurcation
Cricoid cartilage	C6	Larynx to trachea, pharynx to esophagus, carotid tubercle
Vertebra prominens	C7	First clearly palpable spinous process
Root of scapular spine; inferior angle	T3; T7	Counting thoracic spinous processes
Sternal angle	T4 to T5 disc	Rib 2, tracheal bifurcation, aortic arch, azygos into SVC
Xiphisternal junction	T9	Lower border of the heart
Transpyloric plane	L1	Pylorus, renal hila, SMA origin, pancreatic neck
Umbilicus	L3 to L4 disc	T10 dermatome
Iliac crests	L4 or L4 to L5	Aortic bifurcation at L4; lumbar puncture
PSIS dimples	S2	End of the dural sac; middle of the SI joints

Synovial joints, close-packed positions and capsular patterns

Item	Fact	Example or note
Plane	Nonaxial gliding	AC, intercarpal, proximal tibiofibular
Hinge	Uniaxial flexion and extension	Humeroulnar, interphalangeal, talocrural
Pivot	Uniaxial rotation	Proximal and distal radioulnar, median atlantoaxial
Condyloid	Biaxial	Radiocarpal, MCP, MTP
Saddle	Biaxial with conjunct rotation	First CMC, SC, calcaneocuboid
Ball and socket	Multiaxial	Glenohumeral, hip
Close-packed	Most congruent, ligaments taut	Knee full extension; ankle dorsiflexion; hip extension, medial rotation, abduction
Capsular pattern, shoulder	Lateral rotation > abduction > medial rotation	Adhesive capsulitis
Capsular pattern, hip	Medial rotation, flexion, abduction	Hip osteoarthritis
Capsular pattern, knee and elbow	Flexion > extension	Effusion, arthritis

Worked cases

WORKED CASE 1 · COUNTING THE SPINE FROM THE SURFACE

A new patient lies prone. You need to mark the L4 spinous process before a lumbar exam and confirm your thoracic count on the way.

STEP 1 · FIND C7

Have the patient flex and extend the neck. The spinous process that glides forward under your finger with extension is C7; T1 stays fixed.

STEP 2 · CHECK THE THORACIC COUNT

With the arms at the sides, the root of the scapular spine lies at T3 and the inferior angle at T7. Your count from C7 should agree.

STEP 3 · USE THE ILIAC CRESTS

The line joining the highest points of the crests (the supracristal line) crosses the L4 spinous process or the L4 to L5 interspace.

STEP 4 · CROSS-CHECK WITH THE PSIS

The skin dimples over the PSIS mark S2. Count up from S2 and you should land on L4 again.

STEP 5 · IF THE COUNTS DISAGREE

Think of a transitional segment, or a short or extra rib, before blaming your hands, and let the film settle it.

WORKED CASE 2 · A FALL ON THE OUTSTRETCHED HAND

Rowan, 24, falls skateboarding onto an outstretched hand. The wrist is tender in the anatomical snuffbox. The first radiograph is read as normal.

STEP 1 · NAME THE FLOOR OF THE SNUFFBOX

The scaphoid (with the trapezium) lies in the floor, between the APL and EPB tendons laterally and the EPL tendon medially.

STEP 2 · RECALL THE PATTERN

The scaphoid is the most often fractured carpal, and first films are often normal.

STEP 3 · RECALL THE BLOOD SUPPLY

Blood enters the scaphoid distally, so a waist fracture can leave the proximal pole avascular: nonunion and avascular necrosis.

STEP 4 · DECIDE

Treat it as an occult scaphoid fracture: immobilize and repeat imaging or obtain MRI. Do not manipulate the wrist.

WORKED CASE 3 · THE TWISTING KNEE

Jada, 19, plants her foot and twists while cutting in soccer. She hears a pop and the knee swells within an hour. With the knee flexed about 20 degrees, the tibia slides forward on the femur.

STEP 1 · NAME THE TEST

Anterior translation at 20 to 30 degrees of flexion is a positive Lachman test, the most sensitive sign for the ACL.

STEP 2 · NAME THE LIGAMENT AND ITS ENDS

The ACL runs from the anterior intercondylar area of the tibia to the medial side of the lateral femoral condyle. It is named for its tibial end.

STEP 3 · LOOK FOR COMPANY

A lateral blow to a planted knee adds the MCL and the medial meniscus (the unhappy triad). The medial meniscus is bound to the capsule and MCL, so it tears more often than the lateral.

STEP 4 · RAPID SWELLING

Swelling within hours suggests hemarthrosis, which fits a cruciate tear. Refer for imaging and orthopedic assessment.

TRAPS PEOPLE FALL INTO

- **Thumb movements.** The thumb flexes in the frontal plane and abducts in the sagittal plane because it is rotated 90 degrees from the fingers.
- **Dermatome versus nerve territory.** The median nerve carries C6 to C8 fibers. A median lesion gives a nerve pattern, not a dermatomal band.
- **Eccrine glands.** They are sympathetic but cholinergic. If an item asks for the transmitter, the answer is acetylcholine, not norepinephrine.
- **Anatomical versus surgical neck.** The capsule attaches at the anatomical neck; fractures and the axillary nerve are at the surgical neck.
- **Coxa vara and valga.** Vara is a smaller angle than 125 degrees, valga a larger one. Do not mix them up with genu varum and valgum at the knee.
- **Naming the cruciates.** They are named for the tibial attachment, not the femoral one.

Chapter 1 self-test · ten board-style items

1. A patient moves the arm away from the side of the body. In which plane and about which axis does this occur?

A. Frontal plane, vertical axis
B. Sagittal plane, mediolateral axis
C. Frontal plane, anteroposterior axis
D. Transverse plane, vertical axis

C. Frontal plane, anteroposterior axis Abduction moves the limb sideways in the frontal plane, so it turns about an axis running front to back.

2. A plane through the second costal cartilage at the sternum also passes through which of the following?

A. The pylorus of the stomach
B. The tracheal bifurcation
C. The carotid bifurcation
D. The origin of the SMA

B. The tracheal bifurcation The sternal angle plane reaches the T4 to T5 disc, where the trachea bifurcates and the aortic arch begins and ends. The SMA and pylorus are at L1; the carotid bifurcation is at C4.

3. Which landmark marks the level where the larynx becomes the trachea?

A. Cricoid cartilage at C6
B. Hyoid bone at C3
C. Thyroid cartilage at C4
D. Jugular notch at T2

A. Cricoid cartilage at C6 At the cricoid (C6) the larynx becomes the trachea and the pharynx becomes the esophagus.

4. Postganglionic fibers to eccrine sweat glands release which transmitter onto which receptor?

A. Norepinephrine onto alpha-1 receptors
B. Norepinephrine onto beta-2 receptors
C. Acetylcholine onto nicotinic receptors
D. Acetylcholine onto muscarinic receptors

D. Acetylcholine onto muscarinic receptors Eccrine glands are the classic sympathetic cholinergic exception: the fibers are sympathetic but release acetylcholine on muscarinic receptors.

5. A deep, onion-layered, rapidly adapting receptor that signals high frequency vibration is the

A. Ruffini ending
B. Meissner corpuscle
C. Pacinian corpuscle
D. Merkel disc

C. Pacinian corpuscle Pacinian corpuscles lie deep in the dermis and hypodermis and adapt rapidly. Meissner corpuscles also adapt rapidly but sit high in the dermal papillae.

6. A patient has numbness of the middle finger only. Which root is the best fit?

A. C7
B. C6
C. C8
D. T1

A. C7 The middle finger is the classic C7 test area. C6 is the thumb and index, C8 the little finger, T1 the medial forearm.

7. After a midshaft humeral fracture, Nora cannot extend her wrist, but her triceps is strong. Which nerve is injured?

A. Ulnar nerve behind the epicondyle
B. Radial nerve in the spiral groove
C. Median nerve above the condyles
D. Axillary nerve at the surgical neck

B. Radial nerve in the spiral groove The radial nerve winds around the back of the shaft in the spiral groove. Triceps is spared because its branches leave the nerve higher up.

8. An older woman falls and her leg is shortened and laterally rotated. A displaced intracapsular neck fracture most threatens which artery?

A. First perforating artery
B. Lateral circumflex femoral artery
C. Artery of the ligament of the head
D. Medial circumflex femoral artery

D. Medial circumflex femoral artery Retinacular branches of the medial circumflex femoral artery run up the neck inside the capsule and are torn by displaced intracapsular fractures, risking avascular necrosis.

9. Which joint is a secondary cartilaginous joint (symphysis)?

A. The pubic symphysis
B. The epiphyseal plate
C. The sagittal suture
D. A tooth socket

A. The pubic symphysis Symphyses are fibrocartilage joints in the midline. The growth plate and first sternocostal joint are synchondroses; the distal tibiofibular joint is a syndesmosis.

10. A runner rolls the ankle while the foot is plantarflexed and inverted. Which ligament fails first?

A. Posterior talofibular ligament
B. Calcaneofibular ligament
C. Deltoid ligament
D. Anterior talofibular ligament

D. Anterior talofibular ligament The talus is narrower behind, so plantarflexion is loose, and the ATFL is the weakest lateral ligament. The calcaneofibular ligament fails next.

CHAPTER 2

Appendicular Muscles, Nerves and Vessels

Read it in full: **Chapter 2 in the review book**. Practice it: **the practice exams** (Exam 1 covers this chapter) and **the flashcards**.

What to know

The scapula has no ligament tying it to the chest wall, so muscle holds it. **Trapezius** (spinal accessory nerve, CN XI) and **serratus anterior** (long thoracic nerve, C5 to C7) form a force couple that upwardly rotates the scapula. Serratus palsy gives **medial winging** on a wall push; trapezius palsy (often after posterior triangle surgery) gives a drooping shoulder, weak shrug and milder lateral winging. Levator scapulae, the rhomboids (dorsal scapular nerve, C5) and pectoralis minor rotate it downward.

The **rotator cuff** (SITS) centers the humeral head against the upward shear of the deltoid. Supraspinatus initiates abduction and is the tendon most often impinged and torn because it runs under the coracoacromial arch. Infraspinatus and teres minor rotate laterally; subscapularis is the only medial rotator. Nerves: suprascapular for supraspinatus and infraspinatus, axillary for teres minor (and deltoid), upper and lower subscapular for subscapularis. A painful arc from about 60 to 120 degrees suggests impingement; a positive drop arm suggests a full thickness tear.

In the arm, the **musculocutaneous nerve** supplies the flexors (biceps, brachialis, coracobrachialis) and ends as the lateral cutaneous nerve of the forearm. The **radial nerve** supplies triceps and anconeus. Biceps is the strongest supinator with the elbow flexed; brachialis is the prime elbow flexor in every forearm position. Reflexes test roots: biceps C5 (and C6), brachioradialis C6, triceps C7. The quadrangular space carries the axillary nerve and posterior circumflex humeral artery; the triangular interval carries the radial nerve and profunda brachii.

The forearm flexor-pronator group arises from the medial epicondyle and belongs to the **median nerve**, except one and a half muscles: flexor carpi ulnaris and the medial half of flexor digitorum profundus (ulnar). The **anterior interosseous nerve** is purely motor to FPL, lateral FDP and pronator quadratus, so its palsy blocks the round OK sign without numbness. The whole extensor-supinator compartment belongs to the **radial nerve**, mostly the posterior interosseous branch, which passes through supinator under the arcade of Frohse. Brachioradialis is radial but flexes the elbow.

Tennis elbow is a tendinopathy of the extensor carpi radialis brevis origin (Cozen test). Golfer's elbow is the common flexor origin. The first dorsal compartment (APL and EPB) is the site of **de Quervain tenosynovitis** (Finkelstein test). The snuffbox lies between APL and EPB laterally and EPL medially, with the scaphoid in its floor and the radial artery crossing it.

In the hand the median nerve supplies **LOAF**: the lateral two lumbricals, opponens pollicis, abductor pollicis brevis and flexor pollicis brevis. The ulnar nerve supplies every other intrinsic, including adductor pollicis and all interossei (palmar adduct, dorsal abduct). Lumbricals and interossei flex the MCP and extend the IP joints, so their loss produces a claw. Froment sign: the patient flexes the thumb IP joint with FPL to make up for a weak adductor pollicis.

The **carpal tunnel** holds the median nerve and nine tendons (four FDS, four FDP, FPL); FCR runs in its own groove and palmaris longus is outside. Carpal tunnel syndrome gives night paresthesia of the lateral three and a half digits and thenar weakness, but **thenar skin is spared** because the palmar cutaneous branch leaves above the wrist. **Guyon canal** lies between the pisiform and hook of hamate and holds the ulnar nerve and artery; a lesion here spares FCU, medial FDP and dorsal ulnar hand sensation.

The **brachial plexus** comes from the ventral rami of C5 to T1: roots between the anterior and middle scalenes, trunks in the posterior triangle, divisions behind the clavicle, cords around the second part of the axillary artery. Upper trunk is C5 and C6, middle C7, lower C8 and T1. All posterior divisions form the posterior cord (axillary and radial nerves, the extensor side). The lateral cord gives the musculocutaneous nerve, the medial cord the ulnar nerve, and both send a root to the median nerve. From the roots come the dorsal scapular and long thoracic nerves; from the upper trunk the suprascapular nerve.

Classic lesions: **Erb palsy** (C5, C6) gives the waiter's tip and loses the biceps reflex; **Klumpke palsy** (C8, T1) gives a claw hand, sometimes with Horner syndrome. Axillary nerve injury weakens abduction beyond 15 degrees and numbs the regimental badge. Radial nerve at midshaft: wrist drop with triceps largely spared; in the axilla (crutch palsy) triceps goes too. Median at the elbow: hand of benediction on a fist attempt; at the wrist: ape hand. The **ulnar paradox**: a proximal ulnar lesion claws less than a distal one because medial FDP is also paralyzed.

Upper limb arteries: subclavian, then **axillary** at the first rib (pectoralis minor splits it into parts with one, two and three branches), then brachial at the lower border of teres major. The brachial artery divides at the radial neck into radial and ulnar. The ulnar forms most of the superficial palmar arch, the radial most of the deep arch. The cubital fossa holds, lateral to medial, the biceps tendon, brachial artery and median nerve. The cephalic vein runs laterally to the deltopectoral groove, the basilic medially, and the median cubital vein links them.

In the hip, the **superior gluteal nerve** (gluteus medius, minimus and TFL) keeps the pelvis level in single-leg stance; its loss gives a positive **Trendelenburg sign** (the opposite hip drops when standing on the weak side). The **inferior gluteal nerve** supplies gluteus maximus, which is used to rise from a chair and climb stairs. Piriformis is the landmark of the greater sciatic foramen: the superior gluteal nerve exits above it and the sciatic nerve below. Iliopsoas is the strongest hip flexor.

Thigh: anterior compartment by the **femoral nerve** (L2 to L4, posterior divisions; quadriceps, patellar reflex L4), medial by the **obturator nerve** (L2 to L4, anterior divisions), posterior by the **sciatic nerve** (tibial division for the hamstrings, common fibular for the short head of biceps). Leg: anterior compartment by the deep fibular nerve (dorsiflexion), lateral by the superficial

fibular nerve (eversion), both posterior compartments by the tibial nerve (plantarflexion, inversion, toe flexion; ankle reflex S1). The tarsal tunnel holds, front to back, tibialis posterior, FDL, artery and veins, tibial nerve, FHL.

Foot drop needs sorting. A common fibular lesion at the fibular neck (tight cast, crossed legs, fracture) gives foot drop, weak eversion, numb dorsum and lateral leg, but **normal inversion and a normal ankle reflex**. An L5 root lesion also weakens inversion (tibialis posterior) and hip abduction (gluteus medius) and may bring back pain and a positive straight leg raise. Lower limb arteries run external iliac, femoral (mid-inguinal point), popliteal (adductor hiatus), then anterior tibial to dorsalis pedis and posterior tibial behind the medial malleolus. The femoral triangle reads **NAVEL**, lateral to medial.

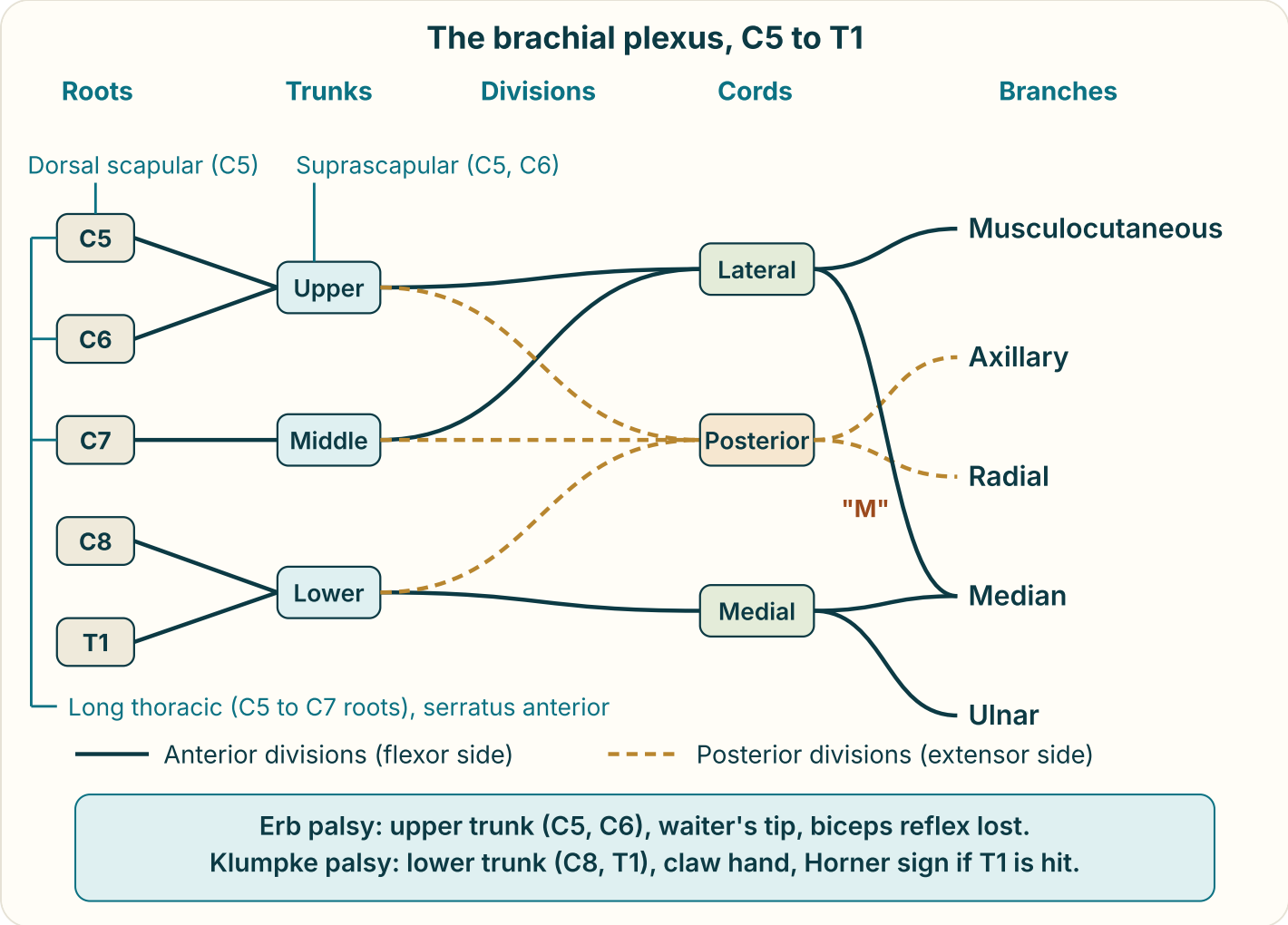

Posterior divisions make the extensor nerves. Every posterior division feeds the posterior cord, so the axillary and radial nerves supply the extensor side; the median nerve takes a root from both the lateral and medial cords.

LOCK THESE IN

- Serratus anterior (long thoracic) palsy gives medial winging; trapezius (CN XI) palsy gives lateral winging and a weak shrug.
- Supraspinatus initiates abduction and is torn most often; subscapularis is the only medial rotator in the cuff.
- Forearm flexors are median except FCU and medial FDP; all extensors are radial; brachioradialis is radial yet flexes the elbow.
- Median nerve in the hand: LOAF. Ulnar nerve: every other intrinsic, including adductor pollicis and all interossei.
- Carpal tunnel: median nerve plus nine tendons, thenar skin spared. Guyon canal: ulnar nerve and artery, dorsal ulnar skin spared.
- Erb (C5, C6) waiter's tip; Klumpke (C8, T1) claw hand, possibly with Horner syndrome.
- Trendelenburg sign means weak abductors on the stance side (superior gluteal nerve).
- Fibular neck lesion: foot drop with intact inversion and ankle reflex. L5 root: inversion and hip abduction weak too.

Nerve lesions of the upper limb

Lesion	Typical cause	Findings
Long thoracic	Mastectomy, heavy pack	Medial winging of the scapula
Spinal accessory	Posterior triangle surgery	Drooping shoulder, weak shrug, lateral winging
Axillary	Anterior dislocation, surgical neck fracture	Weak abduction past 15 degrees, numb regimental badge
Musculocutaneous	Rare; coracobrachialis entrapment	Weak elbow flexion and supination, numb lateral forearm
Radial, spiral groove	Midshaft fracture, Saturday night palsy	Wrist drop, numb dorsal first web space, triceps spared
Posterior interosseous	Supinator, arcade of Frohse	Finger drop, wrist extends with radial deviation, no numbness
Anterior interosseous	Forearm compression	Cannot make a round OK sign, no numbness
Median at wrist	Carpal tunnel syndrome	Thenar atrophy, weak opposition, thenar skin spared
Ulnar at elbow	Cubital tunnel, epicondyle fracture	Clawing of ring and little fingers, Froment sign, dorsal and palmar numbness
Ulnar at wrist	Guyon canal, hook of hamate	Deeper claw; dorsal ulnar sensation spared

Lower limb nerves, compartments and gait

Nerve (roots)	Supplies	Lesion gives
Femoral (L2 to L4)	Quadriceps, sartorius; saphenous to medial leg	Knee buckles, lost patellar reflex
Obturator (L2 to L4)	Adductors, gracilis	Weak adduction, circumduction
Lateral femoral cutaneous (L2, L3)	Skin of anterolateral thigh	Meralgia paresthetica, no motor loss
Superior gluteal (L4 to S1)	Gluteus medius, minimus, TFL	Trendelenburg sign, abductor lurch
Inferior gluteal (L5 to S2)	Gluteus maximus	Trouble rising and climbing
Deep fibular	Anterior compartment, EDB	Foot drop, numb first web space
Superficial fibular	Fibularis longus and brevis	Weak eversion, numb dorsum of foot
Tibial (L4 to S3)	Posterior compartments, sole	Cannot rise on toes, weak inversion, lost ankle reflex
Pudendal (S2 to S4)	Perineum, external sphincters	Perineal numbness, sphincter weakness

Worked cases

WORKED CASE 1 · WHERE IS THE MEDIAN NERVE LESION?

Marcus, 46, a data entry clerk, has night numbness of the thumb, index and middle fingers and drops cups. Sensation over the thenar eminence is normal. The OK sign is round.

STEP 1 · MAP THE SENSORY LOSS

Numb lateral three and a half digits is median nerve territory, not a single dermatome (C6 would be the thumb and index, C7 the middle finger).

STEP 2 · USE THE SPARED SKIN

Thenar skin comes from the palmar cutaneous branch, which leaves the median nerve above the wrist and passes over the retinaculum. Sparing puts the lesion at the wrist.

STEP 3 · USE THE OK SIGN

A round OK sign means FPL and lateral FDP work, so the anterior interosseous nerve is fine. That again argues against a lesion at the elbow.

STEP 4 · CONCLUDE

Carpal tunnel syndrome. Confirm with Phalen, Tinel and nerve conduction studies, and still screen the neck, since a double crush is possible.

WORKED CASE 2 · SORTING A FOOT DROP

Elena, 58, wore a tight below-knee cast for six weeks. Now she drags her toes and lifts the knee high to clear the foot.

STEP 1 · NAME THE GAIT

A high-stepping gait to clear a dropped foot is a steppage gait. Something has weakened the dorsiflexors (deep fibular nerve territory).

STEP 2 · TEST INVERSION

Inversion is strong. Tibialis posterior (tibial nerve, L5 heavy) works, which argues against an L5 root lesion.

STEP 3 · TEST EVERSION AND THE REFLEX

Eversion is weak (superficial fibular nerve) and the ankle reflex is normal (S1 through the tibial nerve).

STEP 4 · FIND THE COMMON POINT

Both fibular branches share the common fibular nerve as it winds around the fibular neck, exactly where the cast edge pressed.

STEP 5 · CONCLUDE

Common fibular nerve compression at the fibular neck. If inversion and hip abduction were weak too, think L5.

WORKED CASE 3 · READING A TRENDELENBURG SIGN

Standing on his right leg, Theo's left hip drops. Standing on his left leg, the pelvis stays level.

STEP 1 · ASK WHICH SIDE HOLDS THE PELVIS

In single-leg stance the abductors on the stance side hold the pelvis level.

STEP 2 · NAME THE WEAK MUSCLES

The right side is standing when the left hip drops, so the right gluteus medius and minimus are weak.

STEP 3 · NAME THE NERVE

The right superior gluteal nerve (L4 to S1), which exits the greater sciatic foramen above piriformis.

STEP 4 · THINK OF CAUSES

A misplaced gluteal injection, hip surgery, or an L5 radiculopathy weakening the abductors.

TRAPS PEOPLE FALL INTO

- **Which side is weak in Trendelenburg.** The weak muscle is on the stance side, not on the side that drops.
- **Brachioradialis.** It is supplied by the radial nerve and lies with the extensors, yet it flexes the elbow.
- **The ulnar paradox.** A proximal ulnar lesion claws less, because medial FDP is also paralyzed and cannot curl the fingers.
- **Thenar sensation.** Spared in carpal tunnel syndrome. Lost when the median nerve is hurt higher up, such as at the elbow.
- **Foot drop is not always L5.** Normal inversion and a normal ankle reflex point to the common fibular nerve at the fibular neck.
- **Superior versus inferior gluteal.** Superior gluteal nerve is the pelvic stabilizers and Trendelenburg; inferior gluteal is gluteus maximus and stairs.

Chapter 2 self-test · ten board-style items

1. After a lymph node biopsy in the posterior triangle, a patient cannot shrug and the scapula flares laterally on abduction. Which nerve was injured?

A. Suprascapular nerve

B. Long thoracic nerve

C. Spinal accessory nerve

D. Dorsal scapular nerve

C. Spinal accessory nerve CN XI crosses the posterior triangle superficially and supplies trapezius. Trapezius palsy gives a droop and lateral winging; long thoracic palsy gives medial winging.

2. A pitcher has weak lateral rotation and wasting in the infraspinous fossa only; supraspinatus is strong. Where is the nerve most likely compressed?

A. Arcade of Frohse
B. Spinoglenoid notch
C. Suprascapular notch
D. Quadrangular space

B. Spinoglenoid notch At the spinoglenoid notch only the branch to infraspinatus remains. Compression at the suprascapular notch would weaken supraspinatus as well.

3. A worker cannot pinch a pen tip to tip because the thumb and index tips will not bend, yet sensation is normal. Which nerve is affected?

A. Median nerve at the wrist
B. Posterior interosseous nerve
C. Ulnar nerve at the wrist
D. Anterior interosseous nerve

D. Anterior interosseous nerve The anterior interosseous nerve is purely motor to FPL, lateral FDP and pronator quadratus, so the OK sign collapses without numbness.

4. Which structure passes through the carpal tunnel?

A. The flexor pollicis longus tendon
B. The ulnar nerve and artery
C. The palmaris longus tendon
D. The flexor carpi radialis tendon

A. The flexor pollicis longus tendon The tunnel holds the median nerve, FPL and the four FDS and four FDP tendons. Palmaris longus and the ulnar nerve pass superficial; FCR runs in its own groove.

5. A newborn after shoulder dystocia holds the arm adducted, medially rotated and pronated with the elbow extended. Which reflex is lost?

A. Finger reflex
B. Ankle reflex
C. Biceps reflex
D. Triceps reflex

C. Biceps reflex This is Erb palsy (C5 and C6, upper trunk). The biceps reflex tests C5 and C6.

6. A cyclist has weak finger abduction and numbness of the palmar little finger, but dorsal ulnar hand sensation and FCU strength are normal. Where is the lesion?

A. Lower trunk of the plexus
B. Ulnar nerve at the cubital tunnel
C. C8 nerve root at the foramen
D. Ulnar nerve in Guyon canal

D. Ulnar nerve in Guyon canal FCU, medial FDP and the dorsal cutaneous branch all leave the ulnar nerve in the forearm, so sparing them puts the lesion at the wrist.

7. A patient on crutches develops wrist drop and also weak elbow extension. Where is the radial nerve compressed?

A. High in the axilla
B. At the arcade
C. At the epicondyle
D. In the groove

A. High in the axilla Triceps branches leave the radial nerve high, so triceps is lost only when the nerve is hit in the axilla, as in crutch palsy.

8. Standing on the left leg, a patient's right hip drops. Which nerve is weak?

A. Right obturator nerve
B. Left superior gluteal nerve
C. Right superior gluteal nerve
D. Left inferior gluteal nerve

B. Left superior gluteal nerve The stance-side abductors hold the pelvis level, so the left gluteus medius and minimus are weak, supplied by the left superior gluteal nerve.

9. Which set lists the tarsal tunnel contents from anterior to posterior?

A. FDL, TP, tibial nerve, artery and veins, FHL
B. FHL, FDL, TP, artery and veins, tibial nerve
C. TP, FHL, tibial nerve, artery and veins, FDL
D. TP, FDL, artery and veins, tibial nerve, FHL

D. TP, FDL, artery and veins, tibial nerve, FHL "Tom, Dick And Very Nervous Harry": tibialis posterior, flexor digitorum longus, artery and veins, nerve, flexor hallucis longus.

10. A man who crosses his legs for hours has foot drop, weak eversion and a numb dorsum of the foot. Inversion and the ankle reflex are normal. What is the lesion?

A. Sciatic nerve at the piriformis
B. Tibial nerve in the popliteal fossa
C. Common fibular nerve at the neck
D. L5 radiculopathy at the foramen

C. Common fibular nerve at the neck Preserved inversion (tibialis posterior) and a normal S1 reflex exclude L5 and sciatic lesions. Both fibular branches are involved, so the common nerve is hit at the neck.

Cram sheet

Both chapters on one page. Cover the right columns and rebuild each row from memory. If a row will not come back, go back to that chapter.

Landmarks, skin and bones

Topic	Rule	Board hook
Planes and axes	Flexion sagittal; abduction frontal; rotation transverse	Axis is perpendicular to the plane
Neck levels	Hyoid C3, thyroid C4, cricoid C6	Carotid bifurcation C4
Trunk levels	Sternal angle T4 to T5, transpyloric L1, umbilicus L3 to L4	Iliac crests L4, PSIS S2
Epidermis	Basale, spinosum, granulosum, lucidum, corneum	Lucidum only in thick skin
Glands	Eccrine sympathetic cholinergic; sebaceous holocrine	Apocrine axilla and anogenital
Dermatomes	C6 thumb, C7 middle, C8 little, L4 medial leg, L5 dorsum, S1 lateral foot	T4 nipple, T10 umbilicus
Humerus nerves	Axillary surgical neck, radial spiral groove, ulnar medial epicondyle	Median with brachial artery above condyles
Wrist	Scaphoid fractures, lunate dislocates	Colles dorsal, Smith volar
Femur	Neck angle 125 degrees, anteversion 10 to 15	Medial circumflex femoral supplies the head

Joints, ligaments and injuries

Joint	Key structure	Classic injury
Shoulder	Labrum, cuff, coracoclavicular ligament	Anterior dislocation, axillary nerve, Bankart, Hill-Sachs
Elbow	UCL resists valgus; annular ligament	Nursemaid's elbow; thrower UCL
Hip	Iliofemoral (Y) ligament limits extension	Posterior dislocation, sciatic nerve
Knee	ACL stops anterior tibia, PCL posterior	Unhappy triad: ACL, MCL, medial meniscus
Ankle	ATFL weakest; deltoid strongest	Inversion in plantarflexion; Ottawa rules

Muscles, nerves and vessels

Item	Fact	Hook
Plexus	C5 to T1: roots, trunks, divisions, cords, branches	Posterior cord gives axillary and radial
Erb versus Klumpke	C5, C6 waiter's tip; C8, T1 claw hand	Horner sign with T1
Hand	Median LOAF; ulnar the rest	Froment sign tests adductor pollicis
Tunnels	Carpal: median plus 9 tendons; Guyon: ulnar nerve and artery	Spared skin localizes the lesion
Reflexes	Biceps C5, brachioradialis C6, triceps C7, patellar L4, ankle S1	Root testing
Thigh	Femoral anterior, obturator medial, sciatic posterior	Pes anserinus: three nerves
Leg	Deep fibular anterior, superficial fibular lateral, tibial posterior	Anterior compartment syndrome most common
Arteries	Femoral, popliteal, anterior tibial to dorsalis pedis	NAVEL in the femoral triangle
Veins	Great saphenous in front of medial malleolus; small behind lateral	Swollen calf after surgery: refer for duplex

An independent study aid, not affiliated with or endorsed by the National Board of Chiropractic Examiners.
Dr. Garg Learning · CC BY-SA 4.0