MEDICAL TERMINOLOGY · STUDY GUIDE

Exam 5 Study Guide

This guide covers chapters 9 and 10. Both systems are tubes, and both chapters teach their roots in the order air or food travels. The respiratory chapter adds the -pnea family, the gas words, the breath sounds and the four airway operations. The digestive chapter adds the bile duct roots, the bleeding words, the scopes and the stomas. Work one chapter at a time. Read the "what to know" paragraphs, copy the tables out by hand, then try each worked case with the steps covered. Finish each chapter with its ten self-test items. The cram sheet at the end puts both tubes and their look-alikes in one place.

WHAT THIS GUIDE COVERS

- Chapter 9 · nose to alveolus roots; pulmon/o, pneumon/o and pneum/o; pleura, thorax and diaphragm; -pnea family; -capnia, -oxia, -thorax, -ectasis, -ptysis; plurals; upper and lower airway disease; breath sounds; spirometry, oximetry, ABG; scopes; -tomy, -stomy, -ectomy, -centesis; respiratory abbreviations.
- Chapter 10 · mouth to anus roots; digestion suffixes; liver, gallbladder, pancreas and the chol- roots; -ase and -ose; bleeding words; GERD, PUD, IBD, diverticular disease, obstruction; -scopy, -graphy, -gram; EGD, colonoscopy, ERCP; surgical suffixes and feeding tubes; eponyms; GI abbreviations.

CHAPTER 9

The Respiratory System

Read it in full: **Chapter 9 in the textbook**. Practice it in the lab: **Walk the Airway** and **The Breath Term Forge**.

What to know

Respiratory terms follow the path of air: nose, pharynx, larynx, trachea, bronchi, bronchioles, alveoli. The nose has **nas/o** (Latin, anatomy: nasal, nasogastric) and **rhin/o** (Greek, disease and surgery: rhinitis, rhinorrhea, rhinoplasty). Sinus/o is the paranasal sinuses and sept/o the septum. **Epistaxis** is a nosebleed and does not decode. The pharynx (pharyng/o) is a shared corridor for food and air. The larynx (laryng/o) holds the vocal cords: dysphonia is a hoarse voice, aphonia is

no voice. The epiglottis covers the larynx during a swallow; epiglottitis is an airway emergency in a child. Osm/o is smell: anosmia is loss of smell.

The trachea (trache/o) divides at the carina into the bronchi (bronch/o, bronchi/o). Branches too small for cartilage are bronchioles (bronchiol/o); bronchiolitis is a disease of infants. Gas exchange happens in the alveoli (alveol/o). The lung has three roots: **pulmon/o** (Latin, adjectives: pulmonary, pulmonologist), **pneumon/o** (Greek, lung: pneumonia, pneumonectomy) and **pneum/o**, which can mean lung or **air**. Pneumothorax is air in the chest, not an infection. The right lung has three lobes and the left has two. The hilum is where vessels and bronchi enter.

The lungs sit in the thorax (thorac/o) wrapped in the **pleura** (pleur/o): visceral on the lung, parietal on the chest wall, with the pleural space between. **-thorax** names what fills that space: pneumothorax (air), hemothorax (blood), pyothorax or empyema (pus), hydrothorax (watery fluid); a pleural effusion is fluid there. The diaphragm is phren/o or diaphragmat/o; phren/o also once meant mind. Spir/o is to breathe, ox/i is oxygen and capn/o is carbon dioxide.

-pnea means breathing. The p is silent only at the start of a word. Eupnea is normal, dyspnea is difficult, apnea is absent, tachypnea fast, bradypnea slow. **Orthopnea** is breathlessness unless sitting upright, a classic heart failure sign charted by pillows. Hyperpnea is deep breathing; hypopnea is shallow. Hyperventilation is breathing beyond need and causes **hypocapnia**. Hypoxemia is low oxygen in the blood; **hypoxia** is low oxygen in the tissue; **hypercapnia** is high carbon dioxide in the blood.

-ectasis is dilation: bronchiectasis is permanently widened bronchi; **atelectasis** (atel/o, incomplete) is collapse, common after surgery. **-ptysis** is spitting (hemoptysis, coughing up blood); **-ptosis** is drooping. Hemoptysis is not hematemesis, which is vomited blood. Laryngotracheobronchitis is croup. Plurals: alveolus to alveoli, bronchus to bronchi, pleura to pleurae, larynx to larynges, pharynx to pharynges, apex to apices. Laryngeal and pharyngeal keep a g; mucus is the noun and mucous the adjective.

Upper airway: rhinitis, sinusitis (rhinosinusitis), pharyngitis, laryngitis, epiglottitis. Croup gives a barking cough and inspiratory **stridor**. Pertussis is whooping cough. Obstructive sleep apnea is repeated collapse of the pharyngeal airway in sleep. Lower airway: **asthma** is reversible

narrowing with bronchospasm and wheezing. **COPD** is airflow limitation that does not fully reverse: chronic bronchitis (productive cough over time) and emphysema (destroyed alveolar walls, air trapping). Cystic fibrosis makes secretions thick. **Pneumoconiosis** is dust disease: anthracosis (coal), silicosis, asbestosis. Pulmonary fibrosis is restrictive.

Pneumonia is infection filling the alveoli; pneumonitis is lung inflammation that may not be infectious. Pulmonary edema is fluid in the alveoli, often from left heart failure; a pleural effusion is fluid outside the lung. Pleurisy (pleuritis) gives sharp pain on breathing in. ARDS is diffuse alveolar injury with hypoxemia that oxygen does not easily correct. A PE blocks pulmonary blood flow. A tension pneumothorax pushes the mediastinum sideways. Bronchogenic carcinoma starts in the bronchial lining; mesothelioma is a pleural cancer linked to asbestos.

Assessment runs inspection, palpation, percussion, auscultation. Look for cyanosis, clubbing, retractions and accessory muscle use. Percussion: resonant is normal, hyperresonant is too much air, dull is fluid or consolidation. Normal breath sounds are vesicular. Adventitious sounds: **crackles** (rales; popping from fluid or opening alveoli), **wheezes** (musical, narrowed small airways), **rhonchi** (low, snoring, secretions in large airways), **stridor** (harsh, high, upper airway, heard without a stethoscope; a red flag) and a pleural friction rub.

Spirometry is the core of pulmonary function testing (PFT). FEV1 is the volume forced out in one second; FVC is forced vital capacity. A low FEV1/FVC ratio means **obstruction** (asthma, COPD); a preserved ratio with small volumes means **restriction** (fibrosis). Pulse oximetry gives SpO2, a saturation percentage, and cannot see carbon dioxide. An **ABG** reports pH, PaO2, PaCO2 and bicarbonate and is the standard test for hypercapnia. SpO2 and PaO2 are different numbers on different scales. Capnography records exhaled CO2. Polysomnography is the sleep study. Bronchoscopy, laryngoscopy, mediastinoscopy and thoracoscopy look inside; a V/Q scan compares air flow and blood flow; thoracentesis drains pleural fluid.

Four suffixes decide what was done. A **tracheotomy** is the incision; a **tracheostomy** is the opening that stays. A thoracotomy opens the chest; a thoracostomy makes an opening for a chest tube; a thoracentesis drains once with a needle. Removal scales up: wedge resection, segmentectomy, **lobectomy**, **pneumonectomy**. A laryngectomy leaves a permanent neck stoma.

Pleurodesis scars the pleural layers together. VATS is keyhole chest surgery. T&A is tonsillectomy and adenoidectomy.

Airway support: an endotracheal tube (ETT) is placed by intubation. FiO2 is the fraction of inspired oxygen (room air is 0.21, or 21 percent). PEEP holds alveoli open. CPAP gives one pressure and treats OSA; BiPAP gives two. Oxygen devices: nasal cannula, simple mask, non-rebreather, high-flow nasal cannula; ECMO oxygenates outside the body. Inhaled drugs: nebulizer, MDI (often with a spacer), DPI. Bronchodilators widen airways, mucolytics thin secretions and antitussives suppress cough. Incentive spirometry prevents postoperative atelectasis. Lobe abbreviations: RUL, RML, RLL, LUL, LLL; there is no left middle lobe.

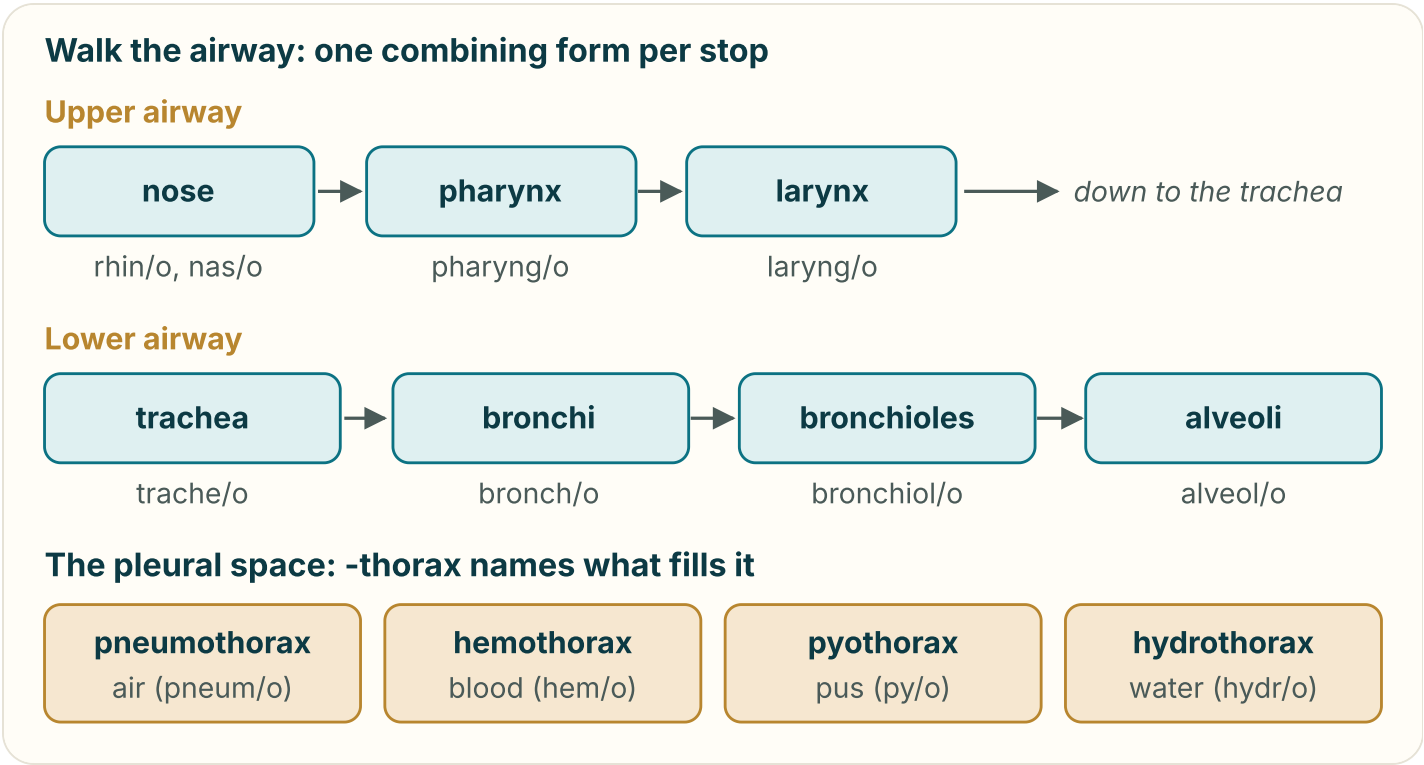

Learn the roots in the order air travels. That is also the order a bronchoscope travels and the order a disease spreads down the tract.

LOCK THESE IN

- Air path: rhin/o, nas/o; pharyng/o; laryng/o; trache/o; bronch/o; bronchiol/o; alveol/o.
- Pulmon/o and pneumon/o mean lung; pneum/o often means air.
- -thorax names what fills the pleural space: air, blood, pus, water.
- Eupnea, dyspnea, apnea, tachypnea, bradypnea, orthopnea, hyperpnea, hypopnea.
- Hypoxemia is blood; hypoxia is tissue; hypercapnia is high CO2.
- Bronchiectasis widened; atelectasis collapsed. -ptysis spitting; -ptosis drooping.
- Low FEV1/FVC is obstruction; preserved ratio with small volumes is restriction.
- Tracheotomy cuts; tracheostomy stays open; lobectomy removes; thoracentesis drains.

Word parts for the respiratory system

Word part	Meaning	Example term	What it means
nas/o, rhin/o	nose	nasopharyngeal, rhinorrhea	nose and throat; runny nose
sinus/o, sept/o	sinus, septum	sinusitis, septoplasty	inflamed sinus; septum repair
pharyng/o, laryng/o	throat, voice box	pharyngitis, laryngoscopy	sore throat; voice box exam
epiglott/o, uvul/o, palat/o	epiglottis, uvula, palate	epiglottitis, palatoplasty	airway emergency; palate repair
trache/o, bronch/o, bronchiol/o	windpipe, bronchus, bronchiole	tracheal, bronchoscopy, bronchiolitis	airway terms
alveol/o, lob/o, hil/o	air sac, lobe, hilum	alveolar, lobectomy, hilar	gas exchange; lobe removal; lung root
pulmon/o, pneumon/o, pneum/o	lung; lung or air	pulmonologist, pneumonectomy, pneumothorax	specialist; lung removed; air in chest
pleur/o, thorac/o, steth/o	pleura, chest	pleuritis, thoracic, stethoscope	pleura inflamed; chest; listening tool
phren/o, diaphragmat/o	diaphragm (phren/o also mind)	phrenic nerve	nerve to the diaphragm
spir/o, ox/i, capn/o	breathe, oxygen, carbon dioxide	spirometer, oximetry, capnography	breath meter; O2 saturation; CO2 tracing
phon/o, osm/o, coni/o	voice, smell, dust	dysphonia, anosmia, pneumoconiosis	hoarse; no smell; dust lung

Word part	Meaning	Example term	What it means
cili/o, muc/o	cilia, mucus	ciliary, mucopurulent	hairlike sweepers; mucus and pus
atel/o	incomplete	atelectasis	incomplete expansion, collapse
-pnea	breathing	orthopnea	breathless unless upright
-capnia, -oxia	carbon dioxide, oxygen	hypercapnia, hypoxia	high CO2; low tissue O2
-thorax	pleural cavity	hemothorax	blood in the pleural space
-ectasis, -ptysis, -phonia, -osmia	dilation, spitting, voice, smell	bronchiectasis, hemoptysis, aphonia, hyposmia	widened airways; coughing blood; no voice; weak smell
-spasm, -stenosis, -desis	contraction, narrowing, binding	bronchospasm, tracheostenosis, pleurodesis	airway clamps; trachea narrowed; pleura fused

Respiratory abbreviations

Abbreviation	Meaning	Note
ABG; SpO2 / PaO2	arterial blood gas; saturation / partial pressure	only the ABG measures PaCO2
COPD, ARDS, OSA	chronic obstructive pulmonary disease; acute respiratory distress syndrome; obstructive sleep apnea	chronic, acute, sleep
CPAP / BiPAP, PEEP	continuous / bilevel positive airway pressure; positive end-expiratory pressure	pressure support
FEV1 / FVC, PFT	forced expiratory volume in 1 s / forced vital capacity; pulmonary function test	obstruction vs restriction
FiO2	fraction of inspired oxygen	room air 0.21 (21 percent)
ETT, HFNC, MDI, ECMO	endotracheal tube; high-flow nasal cannula; metered-dose inhaler; extracorporeal membrane oxygenation	devices
SOB, DOE, PND	shortness of breath; dyspnea on exertion; paroxysmal nocturnal dyspnea	breathlessness types
CXR, V/Q, VATS	chest x-ray; ventilation-perfusion scan; video-assisted thoracoscopic surgery	imaging and surgery
RUL, RML, RLL, LUL, LLL	lung lobes	no left middle lobe
PE, TB, PPD, RSV	pulmonary embolism; tuberculosis; tuberculin skin test; respiratory syncytial virus	PE can also mean physical exam
URI / LRTI, T&A	upper / lower respiratory infection; tonsillectomy and adenoidectomy	split at the larynx

Worked cases

WORKED CASE 1 · DECODING A LONG AIRWAY TERM

A child, Mateo, is admitted with laryngotracheobronchitis. Decode it.

STEP 1 · SUFFIX

-itis, inflammation.

STEP 2 · ROOTS IN AIRWAY ORDER

laryng/o (voice box), trache/o (windpipe), bronch/o (bronchi). The o stays between roots and drops before -itis.

ANSWER

Inflammation of the larynx, trachea and bronchi: croup, with a barking cough and stridor.

WORKED CASE 2 · NAMING WHAT FILLS THE PLEURAL SPACE

After chest trauma, Mr. Adeyemi has air in one pleural space and blood in the other. Name both.

STEP 1 · FIND THE SUFFIX

-thorax names the pleural cavity. The root in front names the contents.

STEP 2 · AIR

pneum/o here means air: **pneumothorax**.

STEP 3 · BLOOD

hem/o is blood: **hemothorax**. Pus would be pyothorax (empyema); watery fluid hydrothorax.

WORKED CASE 3 · READING SPIROMETRY

Two patients: one has a low FEV1/FVC ratio; the other has a normal ratio but small lung volumes. Name each pattern and an example.

STEP 1 · LOW RATIO

Air cannot get out fast: an **obstructive** pattern, as in asthma or COPD.

STEP 2 · PRESERVED RATIO, SMALL VOLUMES

The lung cannot expand: a **restrictive** pattern, as in pulmonary fibrosis.

WORKED CASE 4 · FOUR SUFFIXES, ONE CHEST

Match each order: open the chest for lung surgery; place a chest tube; drain fluid once with a needle; remove one lobe.

STEP 1 · OPEN FOR SURGERY

-tomy: **thoracotomy**.

STEP 2 · CHEST TUBE OPENING

-stomy: **thoracostomy**.

STEP 3 · NEEDLE DRAIN

-centesis: **thoracentesis**.

STEP 4 · REMOVE A LOBE

lob/o + -ectomy: **lobectomy**.

TRAPS PEOPLE FALL INTO

- **Reading pneumothorax as infection.** Pneum/o here means air.
- **Mixing hypoxemia and hypoxia.** Blood vs tissue. A patient in shock can have a good SpO2 and still be hypoxic.
- **Confusing atelectasis and bronchiectasis.** Collapse vs widening. The atel/o at the front flips the meaning.
- **Writing hemoptysis for hematemesis.** Coughed-up blood from the airway vs vomited blood from the stomach.
- **Mixing -ptysis and -ptosis.** Spitting vs drooping.
- **Treating SpO2 and PaO2 as the same.** A saturation percentage vs a partial pressure.
- **Calling stridor a wheeze.** Stridor is harsh, high and upper airway, often heard without a stethoscope.
- **Charting LML.** There is no left middle lobe.
- **Using tracheotomy for the lasting opening.** The opening that stays is a tracheostomy.

Chapter 9 self-test · ten items

1. Which root in a term can mean air rather than lung?

A. pulmon/o

B. pneum/o

C. pneumon/o

D. alveol/o

B. pneum/o Pneum/o can mean lung or air, as in pneumothorax. Pulmon/o and pneumon/o reliably mean lung.

2. Pus in the pleural space is called:

A. Hemothorax
B. Hydrothorax
C. Pneumothorax
D. Pyothorax

D. Pyothorax Py/o is pus; it is also called empyema. Blood is hemothorax, watery fluid hydrothorax and air pneumothorax.

3. A patient sleeps on three pillows because lying flat makes him breathless. Which term fits?

A. Bradypnea
B. Eupnea
C. Orthopnea
D. Hypopnea

C. Orthopnea Orth/o (upright) + -pnea. It is a classic sign of heart failure.

4. Which term means too much carbon dioxide in the blood?

A. Hypercapnia
B. Hypocapnia
C. Hypoxemia
D. Hyperpnea

A. Hypercapnia -capnia is carbon dioxide. Hyperventilation causes hypocapnia; hyperpnea is deep breathing.

5. After surgery, Ms. Kaur has a section of collapsed alveoli. Which term fits?

A. Bronchiectasis
B. Atelectasis
C. Emphysema
D. Pneumoconiosis

B. Atelectasis Atel/o (incomplete) + -ectasis (expansion). Incentive spirometry helps prevent it.

6. A harsh, high-pitched sound on inspiration, heard without a stethoscope, is:

A. Stridor
B. Rhonchi
C. Crackles
D. A friction rub

A. Stridor Stridor signals upper airway obstruction and is a red flag. Rhonchi are low and snoring.

7. A low FEV1/FVC ratio points to which pattern?

A. Obstructive, as in asthma or COPD
B. Restrictive, as in pulmonary fibrosis
C. Normal lung function at rest
D. Upper airway infection such as croup

A. Obstructive, as in asthma or COPD Air cannot be forced out quickly, so the first-second volume is low compared with the total.

8. Which test measures PaCO2 directly?

A. Pulse oximetry
B. Peak flow meter
C. Arterial blood gas
D. Polysomnography

C. Arterial blood gas The ABG reports pH, PaO2, PaCO2 and bicarbonate. Pulse oximetry cannot see carbon dioxide.

9. Which procedure creates an opening for a chest tube?

A. Thoracotomy
B. Thoracostomy
C. Thoracentesis
D. Thoracoscopy

B. Thoracostomy -stomy creates an opening that stays. -tomy is an incision and -centesis a one-time needle drain.

10. What is the plural of larynx?

A. Larynxes
B. Laryngi
C. Larynxae
D. Larynges

D. Larynges -nx becomes -nges: larynx to larynges, said lah-RIN-jeez.

CHAPTER 10

The Digestive System

Read it in full: **Chapter 10 in the textbook**. Practice it in the lab: **Walk the Tube: The Alimentary Term Builder** and **The Chol: Root Router**.

What to know

The alimentary canal is one tube, and each stop has its own root, in order: or/o or stomat/o (mouth), pharyng/o, esophag/o, gastr/o, pylor/o, duoden/o, jejun/o, ile/o, cec/o, col/o, sigmoid/o, rect/o, an/o (proct/o is anus and rectum). These roots rarely wander into other systems, so a jejunostomy must involve the jejunum. Mouth and tongue have Latin forms for normal anatomy (oral, lingual) and Greek forms for disease and surgery (stomatitis, glossectomy). The lumen is the open space inside a tube.

Mouth roots: gingiv/o gums, dent/i and odont/o tooth, gloss/o and lingu/o tongue, cheil/o and labi/o lip, bucc/o cheek, palat/o palate, sial/o saliva (sialolithiasis is a salivary stone). The lower esophageal sphincter (LES) fails in reflux. **Esophagogastroduodenoscopy** (EGD) lists the scope's route: esophagus, stomach, duodenum, then viewing.

Enter/o is the small intestine in general: gastroenteritis is the "stomach flu." Its three parts are duodenum, jejunum and ileum. The large intestine starts at the cecum, where the appendix hangs, then ascending, transverse, descending and sigmoid colon, rectum and anus. Appendectomy drops the ic, but appendicitis keeps it. Abdomin/o is descriptive, **lapar/o** is surgical (laparoscopy, laparotomy) and celi/o survives in celiac. **Ile/o** is the ileum (e for intestine); **ili/o** is the hip bone.

Digestion suffixes: **-pepsia** digestion (dyspepsia, indigestion), **-phagia** swallowing or eating (dysphagia, polyphagia), **-emesis** vomiting (hematemesis, antiemetic), **-chezia** defecation (hematochezia), **-orexia** appetite, **-prandial** meal (postprandial glucose), **-lithiasis** stones, -stalsis contraction (peristalsis). Anorexia as a symptom means only lack of appetite; it is not anorexia nervosa.

The liver makes bile, the gallbladder stores it and the pancreas makes enzymes and the hormones insulin and glucagon. The chol- roots mark points along one path: **chol/e** is bile itself, **cholecyst/o** is the gallbladder (bile sac), **cholangi/o** is any bile duct and **choledoch/o** is the common bile duct. Cholecystectomy is chol/e + cyst + -ectomy. Cholelithiasis is gallstones; choledocholithiasis is a stone in the common bile duct; cholangitis is infection in the ducts, and ascending cholangitis is an emergency. Cyst/o means any sac; before chol/e it is the gallbladder.

Liver failure words: **jaundice** (icterus) is yellow skin and sclerae from bilirubin; **ascites** is fluid in the peritoneal cavity; hepatic encephalopathy is confusion from toxins the liver cannot clear. **Cirrhosis** comes from Greek for tawny and names scarring with nodules; it does not decode into anatomy. Hepatitis A, B and C are three different viruses. Steatohepatitis is inflammation of a fatty liver, now called MASH (formerly NASH). Any term ending in **-ase** is an enzyme (amylase, lipase, protease); **-ose** is a sugar (glucose, lactose). Pancreatitis is diagnosed with amylase and lipase. The bile and pancreatic ducts share an exit, which is why ERCP images both.

Symptoms: regurgitation, eructation (belching), borborygmus (bowel noise; plural borborygmi), flatus. Bleeding words point to a source. **Hematemesis** is vomited blood from an upper source. **Melena** is black tarry stool from digested blood, also upper. **Hematochezia** (BRBPR) is bright red blood per rectum, usually lower. Odynophagia is painful swallowing. Steatorrhea is fatty stool from malabsorption. Dysphagia (swallowing), dysphasia (speech) and dysplasia (disordered cell growth) are one letter apart.

GERD is backward flow of stomach contents when the LES fails; long exposure can cause Barrett esophagus, a precursor to adenocarcinoma. **PUD** (peptic ulcer disease) is mostly from H. pylori and NSAIDs; an ulcer through the wall is a perforation. Achalasia is an LES that will not relax. Gastroparesis is a slow stomach, often from diabetes. **IBD** is Crohn disease (any segment, skip lesions, full thickness, often terminal ileum) and ulcerative colitis (colon and rectum, mucosa only, continuous). IBS is a functional disorder with no inflammation.

Diverticulosis is having outpouchings, often silent; **diverticulitis** is one inflamed or infected. Intussusception is telescoping bowel, common in young children; volvulus is twisting; **ileus** is no peristalsis without a mechanical block, common after surgery. A hernia is protrusion through a wall; herniorrhaphy repairs it. Plurals: diverticulum to diverticula, villus to villi, ruga to rugae, anastomosis to anastomoses, varix to varices (esophageal varices bleed fast in liver failure).

Diagnostics: -scope is the tool, -scopy the look, -graphy the recording, -gram the image, -metry measuring (esophageal manometry). **Colonoscopy** sees to the cecum and can remove polyps (polypectomy); sigmoidoscopy sees only the sigmoid and rectum. **ERCP** is endoscopic retrograde cholangiopancreatography; MRCP makes the same map without a scope but cannot treat. Capsule endoscopy reaches the small intestine. A barium swallow (esophagram) outlines the esophagus; a

modified barium swallow study is a separate swallow test with a speech-language pathologist. Labs: ALT and AST (liver cell injury), alkaline phosphatase and bilirubin (bile flow), albumin and PT/INR (liver synthetic function), amylase and lipase (pancreas), FOBT or FIT (occult, meaning hidden, blood). Paracentesis drains ascites.

Surgery: **-ectomy** removes, **-otomy** cuts in and closes, **-ostomy** makes a mouth (stoma), -plasty repairs (pyloroplasty), -pexy fixes (proctopexy), -rrhaphy sutures (herniorrhaphy), -tripsy crushes (cholelithotripsy). An anastomosis joins two structures. Laparoscopy views through small incisions; laparotomy opens the abdomen. Hemicolectomy removes half the colon. Feeding routes: **PEG** (percutaneous endoscopic gastrostomy), J-tube (jejunostomy) and NG (nasogastric, not surgical). **TPN** (parenteral: beside the intestine) feeds by vein; it does not by itself make a patient NPO. Bariatric is bar/o (weight) + -iatric. **Col/o** is colon; **colp/o** is vagina.

Eponyms drop the possessive: Crohn disease, Barrett esophagus. Mallory-Weiss tear, McBurney point, Murphy sign, sphincter of Oddi and Meckel diverticulum are still standard. Whipple procedure is better written pancreaticoduodenectomy, and ampulla of Vater is often written hepatopancreatic ampulla. Chart terms: NPO (nothing by mouth), PO (by mouth), N/V, BM, LFT, CBD, HAV, HBV, HCV. BS can mean bowel sounds or blood sugar, so write it out.

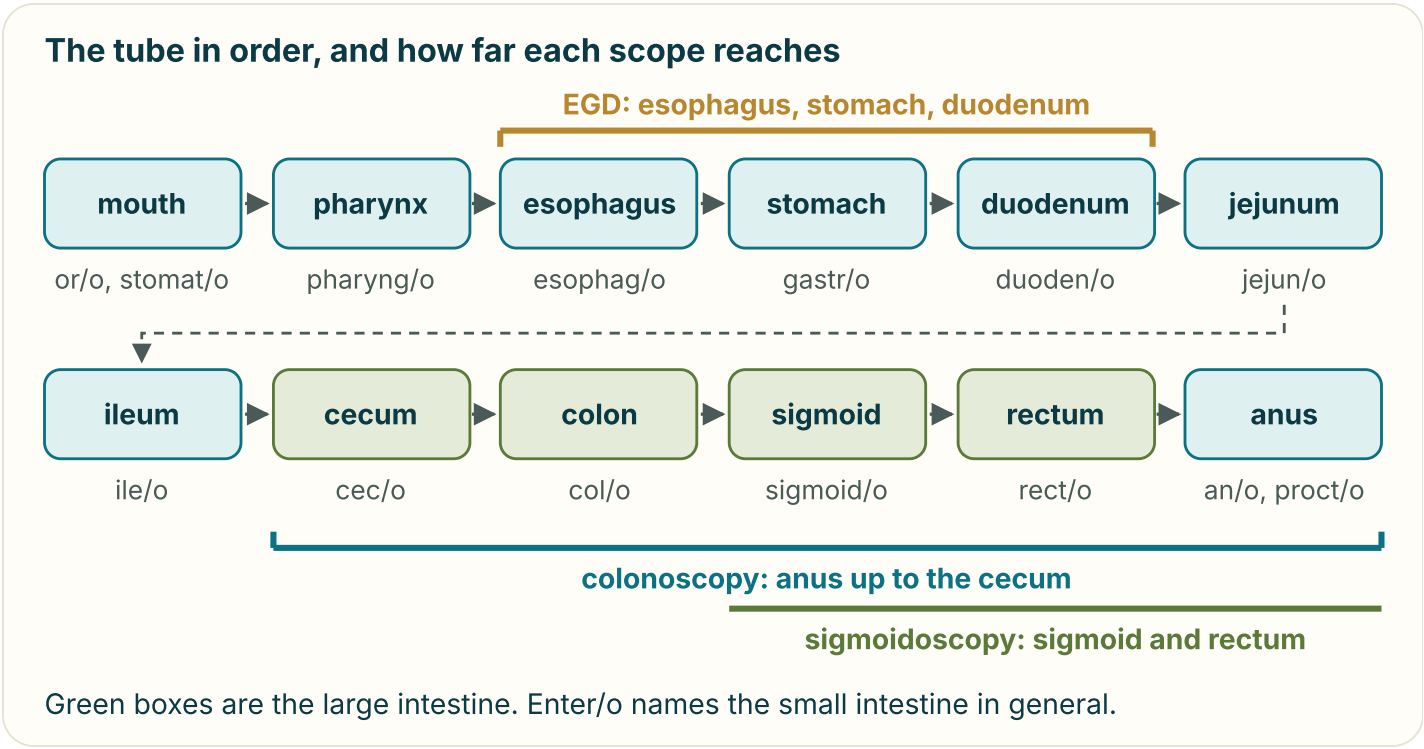

The scope name is the scope route. Esophagogastroduodenoscopy lists its stops in order; colonoscopy reaches the cecum; sigmoidoscopy sees only the end of the colon.

LOCK THESE IN

- Tube order: or/o, pharyng/o, esophag/o, gastr/o, duoden/o, jejun/o, ile/o, cec/o, col/o, sigmoid/o, rect/o, an/o.
- Ile/o is the ileum (bowel); ili/o is the ilium (hip). Col/o is colon; colp/o is vagina.
- Chol/e bile; cholecyst/o gallbladder; cholangi/o any bile duct; choledoch/o common bile duct.
- -ase is an enzyme; -ose is a sugar.
- Hematemesis and melena: upper source. Hematochezia (BRBPR): usually lower.
- Diverticulosis is the quiet state; diverticulitis is the inflamed one.
- IBD (Crohn, UC) has inflammation; IBS does not.
- -ectomy removes, -otomy opens and closes, -ostomy makes a stoma. PEG is a gastrostomy; NG is not surgical.

Word parts for the digestive system

Word part	Meaning	Example term	What it means
or/o, stomat/o	mouth	oral, stomatitis	of the mouth; mouth inflammation
gingiv/o, dent/i, odont/o	gums, tooth	gingivectomy, periodontal	gum removal; around a tooth
gloss/o, lingu/o; cheil/o, labi/o	tongue; lip	hypoglossal; cheilitis	under the tongue; lip inflammation
bucc/o, palat/o, sial/o	cheek, palate, saliva	buccal, palatoplasty, sialadenitis	cheek; palate repair; salivary gland inflamed
esophag/o, gastr/o, pylor/o	esophagus, stomach, pylorus	esophagoscopy, gastralgia, pyloromyotomy	scope; stomach pain; cut in pyloric muscle
enter/o, duoden/o, jejun/o, ile/o	small intestine and its parts	enteropathy, jejunostomy, ileitis	small bowel terms
cec/o, appendic/o, col/o, sigmoid/o	cecum, appendix, colon, sigmoid	cecopexy, appendicitis, colonoscopy	large bowel terms
rect/o, an/o, proct/o	rectum, anus, anus and rectum	rectocele, perianal, proctologist	lower end terms
lapar/o, abdomin/o, celi/o	abdomen	laparoscopy, abdominocentesis, celiac	abdominal terms
hepat/o, pancreat/o	liver, pancreas	hepatomegaly, pancreatitis	enlarged liver; inflamed pancreas
chol/e, bil/i	bile	cholestasis, biliary	bile flow stopped; of bile

Word part	Meaning	Example term	What it means
cholecyst/o, cholangi/o, choledoch/o	gallbladder, bile duct, common bile duct	cholecystectomy, cholangitis, choledocholithiasis	biliary path
lith/o, steat/o	stone, fat	lithotripsy, steatorrhea	stone crushing; fatty stool
amyl/o, lip/o, prote/o + -ase	starch, fat, protein + enzyme	amylase, lipase, protease	digestive enzymes
diverticul/o, polyp/o, herni/o	pouch, polyp, hernia	diverticulectomy, polypectomy, hernioplasty	removal and repair
-pepsia, -phagia, -emesis	digestion, swallowing, vomiting	dyspepsia, odynophagia, hematemesis	symptoms
-chezia, -orexia, -prandial	defecation, appetite, meal	hematochezia, anorexia, postprandial	symptoms and timing
-lithiasis, -stalsis, -paresis	stones, contraction, weakness	cholelithiasis, peristalsis, gastroparesis	conditions

GI abbreviations

Abbreviation	Meaning	What it tells you
NPO; PO	nil per os; per os	nothing by mouth; by mouth
GERD, PUD, LES	reflux disease; peptic ulcer disease; lower esophageal sphincter	upper tract
EGD, ERCP, MRCP	upper endoscopy; scope plus duct imaging; MRI duct map	diagnostics
IBD / IBS; UC / CD	inflammatory bowel disease / irritable bowel syndrome; ulcerative colitis / Crohn disease	structure vs function
NG, PEG, TPN	nasogastric; percutaneous endoscopic gastrostomy; total parenteral nutrition	feeding routes
LFT, CBD	liver function tests; common bile duct	liver and ducts
BRBPR, FOBT / FIT	bright red blood per rectum; fecal occult blood / immunochemical test	bleeding
N/V, BM, GI	nausea and vomiting; bowel movement; gastrointestinal	daily charting
HAV, HBV, HCV	hepatitis A, B, C viruses	which virus
RUQ, LUQ, RLQ, LLQ	abdominal quadrants	RUQ suggests gallbladder

Worked cases

WORKED CASE 1 · DECODING A BILIARY OPERATION

Ms. Petrova is scheduled for laparoscopic cholecystectomy. Decode it.

STEP 1 · SUFFIX

-ectomy, removal.

STEP 2 · ROOTS

chol/e (bile) + cyst (sac): the bile sac, the gallbladder.

STEP 3 · THE FIRST WORD

lapar/o (abdominal wall) + -scopic: done through the abdominal wall with a scope.

ANSWER

Removal of the gallbladder through small incisions using a scope.

WORKED CASE 2 · LOCATING A BLEED FROM THE WORDS

One patient vomits blood; a second passes black tarry stool; a third passes bright red blood per rectum. Where is each source likely?

STEP 1 · HEMATEMESIS

Vomited blood: an upper source (esophagus, stomach, duodenum).

STEP 2 · MELENA

Black tarry stool is digested blood: also an upper source.

STEP 3 · HEMATOCHEZIA

Bright red blood per rectum (BRBPR): usually a lower source, colon or anorectum.

WORKED CASE 3 · -OSIS OR -ITIS

A screening colonoscopy shows many silent outpouchings. Months later one becomes infected with pain and fever. Name each stage and the plural.

STEP 1 · SILENT STATE

-osis, abnormal condition: **diverticulosis**.

STEP 2 · INFLAMED STATE

-itis, inflammation: **diverticulitis**.

STEP 3 · PLURAL

One diverticulum, several **diverticula**.

WORKED CASE 4 · CHOOSING THE FEEDING ROUTE TERM

Mr. Chen needs long-term feeding. A tube is placed through the skin into the stomach using a scope. Name it and contrast an NG tube.

STEP 1 · BUILD THE TERM

percutaneous (through the skin) + endoscopic (with a scope) + gastr/o + -stomy (opening).

ANSWER

PEG, percutaneous endoscopic gastrostomy. An NG tube goes through the nose to the stomach (nas/o + gastr/o + -ic) and is not surgical.

TRAPS PEOPLE FALL INTO

- **Writing ilium for ileum.** Ileum is bowel (e for intestine); ilium is hip bone.
- **Reading cyst/o as always urinary.** It means any sac. Chol/e + cyst/o is the gallbladder.
- **Blurring the chol- roots.** Bile, gallbladder, any duct, common duct.
- **Reading melena as a lower bleed.** Black tarry stool is digested blood from an upper source.
- **Mixing IBD and IBS.** Inflammation and damage vs a functional disorder.
- **Charting anorexia as the eating disorder.** As a symptom it means only loss of appetite.
- **Mixing col/o and colp/o.** Colonoscopy is bowel; colposcopy examines the cervix and vagina.
- **Spelling appendicitis or appendicectomy.** Appendicitis keeps the ic; appendectomy drops it.
- **Assuming TPN means NPO.** They are separate orders.

Chapter 10 self-test · ten items

1. Which root names the middle segment of the small intestine?

A. duoden/o
B. ile/o
C. cec/o
D. jejun/o

D. jejun/o The order is duodenum, jejunum, ileum. The cecum starts the large intestine.

2. Which term means difficulty swallowing?

A. Dyspepsia
B. Dysphasia
C. Dysplasia
D. Dysphagia

D. Dysphagia -phagia is swallowing. Dyspepsia is indigestion, dysphasia is speech and dysplasia is disordered growth.

3. A stone lodged in the common bile duct is:

A. Cholelithiasis
B. Cholecystolithiasis
C. Choledocholithiasis
D. Cholangitis

C. Choledocholithiasis Choledoch/o is the common bile duct. Cholelithiasis is gallstones in general.

4. Which term names an enzyme?

A. Lipase
B. Lactose
C. Glucose
D. Glycogen

A. Lipase -ase marks an enzyme; lip/o is fat. -ose marks a sugar, and glycogen is stored glucose.

5. Black, tarry, foul-smelling stool is called:

A. Hematochezia
B. Steatorrhea
C. Hematemesis
D. Melena

D. Melena Melena is digested blood from an upper source. Hematochezia is bright red blood per rectum.

6. Which condition involves only the colon and rectum, with continuous mucosal inflammation?

A. Crohn disease
B. Ulcerative colitis
C. Irritable bowel syndrome
D. Diverticulosis

B. Ulcerative colitis UC is limited to colon and rectum. Crohn disease can affect any segment with skip lesions.

7. After abdominal surgery, the bowel stops moving with no mechanical block. This is:

A. Ileus
B. Volvulus
C. Intussusception
D. Ileitis

A. Ileus Ileus is absent peristalsis without a block. Volvulus is twisting and intussusception is telescoping.

8. What does ERCP image?

A. The esophagus, stomach and duodenum
B. The entire large intestine to cecum
C. The bile ducts and the pancreas
D. The small intestine using a capsule

C. The bile ducts and the pancreas Cholangi/o (bile duct) + pancreat/o + -graphy, with contrast injected backward through a scope.

9. Which operation brings the colon to the abdominal wall as a stoma?

A. Colectomy
B. Colostomy
C. Colotomy
D. Colporrhaphy

B. Colostomy -ostomy makes a mouth. Colectomy removes colon; colporrhaphy repairs the vagina.

10. What is the plural of diverticulum?

A. Diverticuli
B. Diverticulums
C. Diverticula
D. Diverticulae

C. Diverticula -um becomes -a: diverticulum to diverticula.

Cram sheet

Everything from chapters 9 and 10 in one place. Cover the right column and see if you can rebuild each row.

Word parts to know

Group	Parts and meanings
Upper airway	nas/o, rhin/o nose; sinus/o; sept/o; pharyng/o; laryng/o; epiglott/o; osm/o smell; phon/o voice
Lower airway	trache/o; bronch/o; bronchiol/o; alveol/o; lob/o; hil/o; pulmon/o, pneumon/o lung; pneum/o lung or air
Chest and gases	pleur/o; thorac/o; phren/o; spir/o breathe; ox/i oxygen; capn/o CO2; coni/o dust; atel/o incomplete
Breathing suffixes	-pnea; -capnia; -oxia; -thorax; -ectasis; -ptysis; -phonia; -osmia; -spasm
Upper GI	or/o, stomat/o; gingiv/o; gloss/o, lingu/o; cheil/o; sial/o; esophag/o; gastr/o; pylor/o
Lower GI	enter/o; duoden/o; jejun/o; ile/o; cec/o; appendic/o; col/o; sigmoid/o; rect/o; an/o; proct/o; lapar/o
Accessory	hepat/o; chol/e; cholecyst/o; cholangi/o; choledoch/o; pancreat/o; lith/o; -ase enzyme; -ose sugar
GI suffixes	-pepsia; -phagia; -emesis; -chezia; -orexia; -prandial; -lithiasis; -stalsis

Key terms and comparisons

Pair or set	The difference
hypoxemia vs hypoxia	low O2 in blood vs in tissue
atelectasis vs bronchiectasis	collapsed vs widened
hemoptysis vs hematemesis	coughed-up blood vs vomited blood
obstruction vs restriction	low FEV1/FVC vs normal ratio, small volumes
crackles, wheezes, rhonchi, stridor	popping; musical; snoring; harsh upper airway
tracheotomy vs tracheostomy	the cut vs the lasting opening
thoracotomy, thoracostomy, thoracentesis	open chest; tube opening; needle drain
hematemesis, melena, hematochezia	upper, upper, usually lower
diverticulosis vs diverticulitis	silent pouches vs inflamed pouch
IBD vs IBS	inflammation vs functional disorder
ileum vs ilium; col/o vs colp/o	bowel vs hip; colon vs vagina
laparoscopy vs laparotomy	scope through small cuts vs open incision

Abbreviations

Abbreviation	Meaning
ABG, SpO2, PaO2, PaCO2, FiO2	blood gas; saturation; partial pressures; inspired oxygen fraction
COPD, ARDS, OSA, PE, TB	respiratory diagnoses
CPAP, BiPAP, PEEP, ETT, HFNC	airway support
PFT, FEV1, FVC, V/Q, CXR, VATS	tests and surgery
SOB, DOE, PND; RUL to LLL	breathlessness; lobes (no LML)
NPO, PO, NG, PEG, TPN	mouth and feeding routes
GERD, PUD, IBD, IBS, UC, CD	GI diagnoses
EGD, ERCP, MRCP, LFT, FOBT, FIT	GI tests
BRBPR, CBD, HAV, HBV, HCV	bleeding; bile duct; hepatitis viruses

---

Dr. Garg Learning · CC BY-SA 4.0