MEDICAL TERMINOLOGY · STUDY GUIDE

Exam 3 Study Guide

This guide covers chapters 5 and 6, the first two body systems. The skin chapter teaches the roots for skin, hair, nails and glands, the color and lesion words used to describe a rash, and the words on a wound note. The musculoskeletal chapter gives you a root for every bone, joint and muscle part, then the fractures, arthritis types, operations and abbreviations of an orthopedic chart. Work one chapter at a time. Read the "what to know" paragraphs, copy the tables out by hand, then try each worked case with the steps covered. Finish each chapter with its ten self-test items. The cram sheet at the end puts the roots, look-alikes and abbreviations in one place.

WHAT THIS GUIDE COVERS

- Chapter 5 · derm/o, dermat/o, cutane/o; layers and appendages; hidr/o vs hydr/o; color roots; primary and secondary lesions; infections, inflammatory conditions, growths and cancers; biopsy and surgery; graft prefixes; plurals and wound note abbreviations.
- Chapter 6 · oste/o, chondr/o, myel/o; long bone parts and -physis; a root for each bone; joint, tendon and muscle roots; motion terms; fractures and treatment; spinal curves; arthritides; muscle and bone disease; imaging, surgery and orthopedic abbreviations.

CHAPTER 5

The Integumentary System

Read it in full: **Chapter 5 in the textbook**. Practice it in the lab: **The Lesion Description Desk** and **The Skin Term Forge**.

What to know

Skin has three roots. Greek gives **derm/o** and **dermat/o**; Latin gives **cutane/o**. Greek roots take Greek suffixes (dermatitis) and the Latin root takes the Latin ending -ous (subcutaneous). Derm/o tends to name a layer or quality (epidermis, xeroderma, pyoderma). Dermat/o tends to name a

specialty, disease or procedure (dermatology, dermatosis, dermatoplasty). The suffix **-derma** names a skin condition (scleroderma) and **-dermis** names a layer (epidermis, hypodermis).

The **epidermis** is avascular and made of stacked squamous cells that fill with keratin as they move up. That is why its cancer is squamous cell carcinoma, a thickened callus is a keratosis and fish-like scaling is ichthyosis. The deepest epidermal layer holds the **melanocytes** (melan/o + -cyte, black cell) that make melanin. The **dermis** holds collagen, vessels, nerves and the roots of hair and glands. The **hypodermis** (subcutaneous layer) is mostly fat, and fat has three roots: adip/o, lip/o and steat/o.

Glands and appendages come in Greek and Latin pairs. Sebaceous glands make sebum (seb/o): seborrhea is a flow of sebum. Sudoriferous glands make sweat: hidr/o (Greek) and sudor/i (Latin). Hyperhidrosis is too much sweating, anhidrosis is no sweating, and diaphoresis is profuse sweating. Hair is trich/o and pil/o; a pilonidal cyst is literally a hair nest. Nail is onych/o and ungu/o: onychomycosis is a fungal nail infection, periungual is around the nail and paronychia is infection beside the nail. **Hidr/o** (sweat) is not **hydr/o** (water). Kerat/o means horny tissue in skin but cornea in the eye.

Color roots do diagnostic work: cyan/o blue, erythr/o red, leuk/o white, melan/o black, xanth/o yellow, alb/o and albin/o white, poli/o gray, chrom/o color. Cyanosis is a blue condition; perioral cyanosis is blueness around the mouth. Erythema is redness and erythematous is the adjective. Leukoplakia is white patches on a mucous membrane that can be premalignant. Jaundice and its Greek twin icterus describe yellow skin and sclerae from bilirubin, and are not built from xanth/o. Xer/o (dry) and xanth/o (yellow) both start with a z sound.

Primary lesions appear on normal skin. Flat: a **macule** is under 1 cm and a **patch** is over 1 cm. Solid and raised: a **papule** is under 1 cm, a **plaque** is a raised flat-topped area over 1 cm (psoriasis), and a **nodule** extends deeper. Fluid-filled: a **vesicle** is under 1 cm and a **bulla** is over 1 cm (plural bullae). A pustule holds pus. A **wheal** is a short-lived raised swelling, a hive, and many wheals are urticaria. A cyst is an encapsulated sac.

Secondary lesions develop from primary ones. Crust is dried serum, blood or pus. Scale is flaking. An **erosion** loses epidermis only and heals without a scar; an **ulcer** goes through the

dermis and scars. A fissure is a linear crack. Excoriation is a scratch mark. Lichenification is thick, leathery skin from rubbing. A scar is a cicatrix, and a scar that spreads beyond the wound edge is a keloid. **Pruritus** is itching; it ends in -us because it is not an inflammation. Purpura is bleeding into skin that does not blanch; small spots are petechiae and a bruise is an ecchymosis.

Infections: cellulitis is a spreading bacterial infection of the dermis and subcutaneous tissue. Folliculitis inflames hair follicles; a furuncle (boil) is a deep infection of one follicle and a carbuncle is several joined together. An abscess is walled-off pus, treated by I&D. Staphyl/o means cluster and strept/o means twisted chain, so the shape is in the name. Impetigo is a honey-crusted superficial infection. Fungal terms use myc/o; tinea is the clinical word, with a location (tinea pedis, capitis, corporis, cruris, unguium). Verruca is a wart; herpes zoster is shingles. **Myc/o** (fungus), **my/o** (muscle) and **myel/o** (marrow or spinal cord) are three different roots.

Inflammatory conditions: atopic dermatitis is eczema; seborrheic dermatitis flakes oily areas; psoriasis makes well-demarcated silvery plaques; acne lesions include comedones (singular comedo). Vitiligo is patchy loss of melanocytes; alopecia is hair loss; hirsutism is male-pattern hair growth in a female patient; hypertrichosis is general excess hair. A nevus is a mole (plural nevi). The three skin cancers are **basal cell carcinoma** (most common, rarely spreads), **squamous cell carcinoma** (from keratinocytes) and **malignant melanoma** (least common, most deaths). ABCDE: asymmetry, border, color, diameter over 6 mm, evolution. An actinic keratosis is a sun-induced precancerous lesion. Melena is black stool from upper GI bleeding, not a skin finding.

A **biopsy** (bi/o + -opsy, viewing living tissue) can be shave, punch, incisional (part of a lesion) or excisional (all of it). Dermatoscopy uses a dermatoscope. A KOH prep shows fungus; a C&S grows the organism and tests antibiotics. Curettage scrapes; with electrodesiccation it is ED&C. Cryosurgery freezes. Mohs surgery removes a tumor layer by layer and keeps its eponym. Debridement removes dead tissue. An **escharotomy** cuts into burn eschar to relieve pressure; it does not remove it. Rhytidectomy is a face lift; blepharoplasty repairs an eyelid.

Graft prefixes: an **autograft** is the patient's own skin, an **allograft** (homograft) comes from another human and a **xenograft** (heterograft) comes from another species, classically pig. A split-thickness graft (STSG) takes epidermis and part of the dermis; a full-thickness graft (FTSG) takes

the whole dermis. A flap keeps its own blood supply. Burns are graded by depth and by TBSA, total body surface area, using the rule of nines.

Plurals: bulla to bullae, petechia to petechiae, nevus to nevi, stratum to strata, keratosis to keratoses, ecchymosis to ecchymoses, cicatrix to cicatrices, comedo to comedones. Write subcut, not SC or SQ, which are error-prone. Pressure ulcer is now **pressure injury** (PI), with deep tissue pressure injury (DTPI) and unstageable categories, staged 1 through 4 in Arabic numerals.

Primary lesions: what kind, then how big

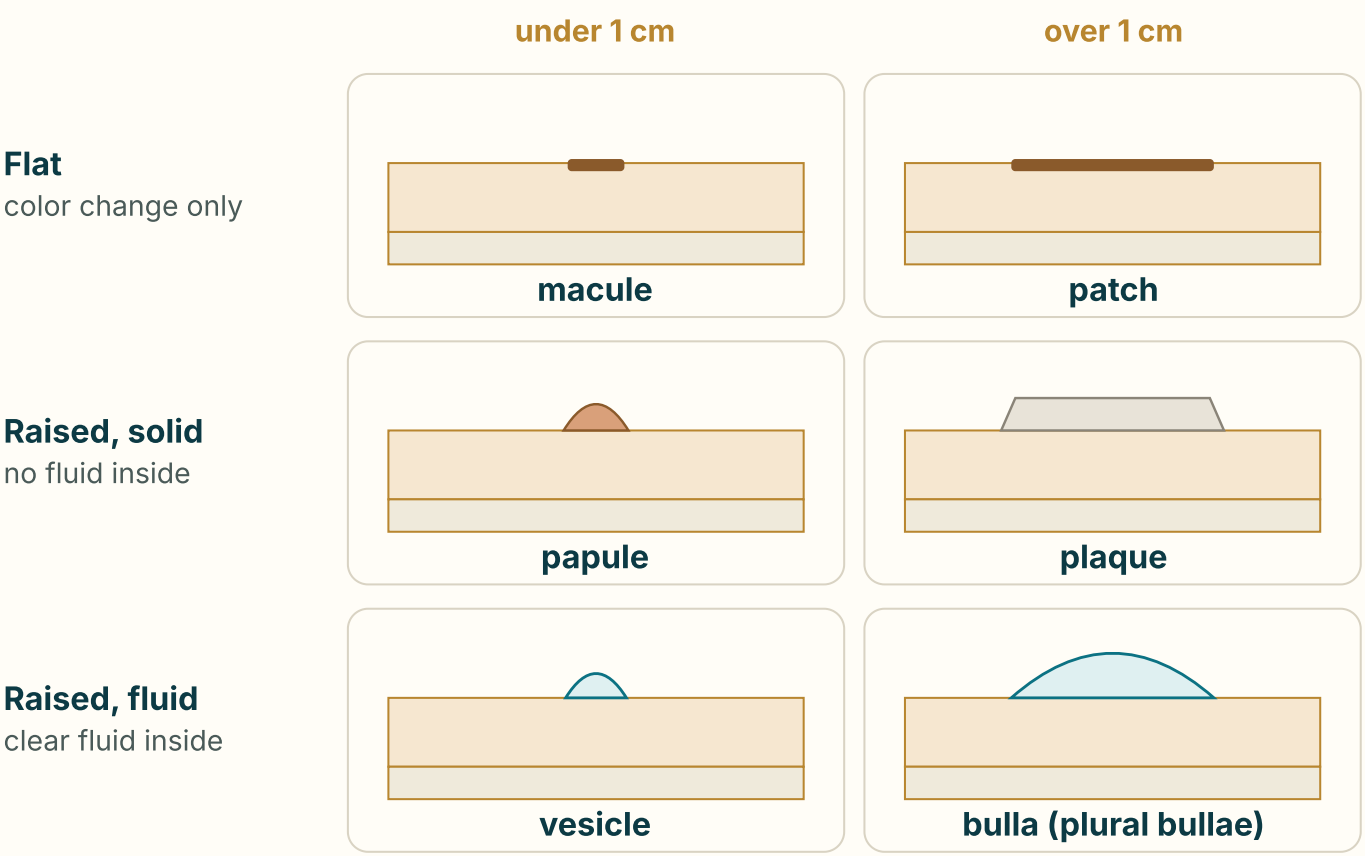

Also primary: nodule (solid, deeper), pustule (pus), wheal (short-lived hive), cyst (enclosed sac).

Two questions name most lesions. Is it flat, solid or fluid-filled, and is it under or over 1 cm across?

LOCK THESE IN

- Skin: derm/o, dermat/o (Greek), cutane/o (Latin). -derma is a condition; -dermis is a layer.
- Hidr/o is sweat; hydr/o is water. Onych/o and ungu/o are nail; trich/o and pil/o are hair.
- Macule under 1 cm, patch over; papule under 1 cm, plaque over; vesicle under 1 cm, bulla over.
- Erosion heals without a scar; an ulcer goes through the dermis and scars.
- Pruritus (itching) is spelled -us. Petechiae is already plural.
- BCC is most common; SCC comes from keratinocytes; melanoma causes most skin-cancer deaths. ABCDE.
- Autograft self, allograft another human, xenograft another species.
- Escharotomy cuts into eschar; it does not remove it.

Word parts for the skin

Word part	Meaning	Example term	What it means
derm/o, dermat/o, cutane/o	skin	dermatitis, subcutaneous	skin inflammation; under the skin
kerat/o	horny tissue (eye: cornea)	keratosis	thickened horny tissue
squam/o; ichthy/o	scale; fish, scaly	squamous; ichthyosis	scale-like cells; fish-like scaling
seb/o	sebum, oil	seborrhea	excess flow of sebum
hidr/o, sudor/i	sweat	anhidrosis, sudoriferous	no sweating; carrying sweat
trich/o, pil/o	hair	trichomycosis, pilonidal	fungal hair condition; hair nest
onych/o, ungu/o	nail	onycholysis, subungual	nail loosening; under the nail
adip/o, lip/o, steat/o	fat	adipose, lipoma, steatorrhea	fatty; fatty mass; fatty stool
myc/o	fungus	onychomycosis	fungal nail infection
rhytid/o	wrinkle	rhytidectomy	face lift
cyan/o, erythr/o, leuk/o	blue, red, white	cyanosis, erythroderma, leukoplakia	blue skin; widespread redness; white patch
melan/o, xanth/o, alb/o	black, yellow, white	melanocyte, xanthoma, albinism	pigment cell; yellow fatty plaque; absent pigment
xer/o, py/o, necr/o, scler/o	dry, pus, death, hard	xeroderma, pyogenic, necrosis, scleroderma	dry skin; pus-forming; dead tissue; hard skin
staphyl/o, strept/o	cluster, twisted chain	staphylococcus, streptococcus	round bacteria in clusters; in chains

Word part	Meaning	Example term	What it means
cellul/o, follicul/o	little cell, follicle	cellulitis, folliculitis	dermis infection; follicle inflammation
cry/o, electr/o	cold, electricity	cryosurgery, electrodesiccation	freezing tissue; drying it with current
auto-, allo-, xen/o	self, other, foreign species	autograft, allograft, xenograft	graft sources

Abbreviations on a skin or wound note

Abbreviation	Stands for	In practice
BCC; SCC; MM	basal cell; squamous cell carcinoma; malignant melanoma	the three skin cancers
AK	actinic keratosis	sun-induced precancerous scaly lesion
Bx	biopsy	tissue sampled for diagnosis
I&D	incision and drainage	abscess opened and drained
ED&C	electrodesiccation and curettage	scrape, then burn the base
TBSA	total body surface area	burn extent by the rule of nines
STSG / FTSG	split / full-thickness skin graft	graft depth
NPWT	negative pressure wound therapy	vacuum dressing
PI / DTPI	pressure injury / deep tissue pressure injury	replaces pressure ulcer
C&S; KOH	culture and sensitivity; potassium hydroxide prep	organism and antibiotics; fungal hyphae
HSV / VZV; MRSA	herpes simplex / varicella-zoster; methicillin-resistant Staph aureus	viruses; resistant organism
subcut	subcutaneous	write this, not SC or SQ

Worked cases

WORKED CASE 1 · DESCRIBING A LESION BEFORE NAMING A DISEASE

Ms. Arroyo has a raised, flat-topped, silvery lesion 3 cm across on her elbow. Name the lesion type.

STEP 1 · FLAT OR RAISED?

Raised and solid, not fluid-filled.

STEP 2 · SIZE

Over 1 cm, so it is not a papule.

STEP 3 · SHAPE

Broad and flat-topped.

ANSWER

A **plaque**, the classic finding in psoriasis. Under 1 cm it would have been a papule.

WORKED CASE 2 · DECODING A PATHOLOGY TERM

Break down onychomycosis, then build the same pattern for hair and skin.

STEP 1 · SUFFIX

-osis, abnormal condition.

STEP 2 · MIDDLE

myc/o is fungus. onych/o is nail.

STEP 3 · PLAIN ENGLISH

A fungal infection of the nail.

STEP 4 · REUSE THE PATTERN

Swap the structure root: **trichomycosis** (hair) and **dermatomycosis** (skin). One pattern, three locations.

WORKED CASE 3 · CHOOSING THE GRAFT TERM

A burn patient receives pig skin as a temporary cover, then later his own skin from the thigh, taking epidermis and part of the dermis. Name both.

STEP 1 · SOURCE OF THE FIRST GRAFT

Another species, so xen/o: a **xenograft** (heterograft).

STEP 2 · SOURCE OF THE SECOND

The patient's own skin: an **autograft**.

STEP 3 · THICKNESS

Epidermis plus part of the dermis is a split-thickness skin graft, **STSG**.

WORKED CASE 4 · READING A REAL NOTE

Decode: "erythematous plaque, 3 cm, left pretibial, warmth and edema, no fluctuance, C&S sent, presumed cellulitis."

STEP 1 · COLOR AND LESION

Erythematous is red. A plaque is raised, flat-topped and over 1 cm.

STEP 2 · PLACE

Pretibial is in front of the tibia.

STEP 3 · FINDINGS

No fluctuance means no fluid pocket, so no I&D is planned. C&S grows the organism.

ANSWER

A red raised patch on the front of the left shin from a **spreading infection of the dermis and subcutaneous tissue**.

TRAPS PEOPLE FALL INTO

- **Spelling pruritis.** It is pruritus. Itching is not an inflammation.
- **Mixing hidr/o and hydr/o.** Anhidrosis is no sweat; hydrocephalus is water on the brain.
- **Mixing myc/o, my/o and myel/o.** Fungus, muscle, and marrow or spinal cord.
- **Calling a bulla a vesicle.** Size decides: under 1 cm is a vesicle, over 1 cm is a bulla.
- **Reading escharotomy as removal.** -tomy cuts in to relieve pressure. Removal would be -ectomy.
- **Reading melena as a skin finding.** Melan/o means black anywhere: melena is black, tarry stool.
- **Writing SC or SQ.** Both are error-prone. Write subcut.
- **Charting "several petechia."** Petechia is singular; the plural is petechiae.
- **Assuming kerat/o is always skin.** In an eye note it means cornea: keratitis, keratoplasty.

Chapter 5 self-test · ten items

1. Which suffix names a skin layer rather than a skin condition?

A. -derma, as in scleroderma

B. -dermis, as in epidermis

C. -derma, as in pyoderma

D. -osis, as in dermatosis

B. -dermis, as in epidermis -dermis names a layer. -derma names a condition such as hardening (scleroderma) or pus (pyoderma).

2. A patient does not sweat at all. Which term fits?

A. Anhydrosis
B. Anhidrosis
C. Hyperhidrosis
D. Diaphoresis

B. Anhidrosis Hidr/o means sweat and an- means without. Hydr/o means water. Diaphoresis is profuse sweating.

3. A fluid-filled blister measures 2 cm. What is it called?

A. Vesicle
B. Pustule
C. Papule
D. Bulla

D. Bulla Over 1 cm, a fluid-filled blister is a bulla. Under 1 cm it is a vesicle.

4. Which lesion goes through the dermis and heals with a scar?

A. Erosion
B. Excoriation
C. Ulcer
D. Macule

C. Ulcer An erosion loses only epidermis and heals without a scar. An ulcer goes deeper.

5. What is the correct spelling for itching?

A. Pruritus
B. Pruritis
C. Pruretus
D. Prurititis

A. Pruritus Pruritus is a Latin noun ending in -us. The adjective is pruritic.

6. Which skin cancer is the most common and least likely to spread?

A. Basal cell carcinoma
B. Squamous cell carcinoma
C. Malignant melanoma
D. Actinic keratosis

A. Basal cell carcinoma BCC is most common and rarely metastasizes. Melanoma causes most deaths, and actinic keratosis is precancerous.

7. A graft taken from a deceased human donor is a:

A. Autograft
B. Allograft
C. Xenograft
D. Heterograft

B. Allograft Allo- means other, here another human. Xenograft and heterograft come from another species.

8. Which term names inflammation of a hair follicle?

A. Cellulitis
B. Paronychia
C. Hidradenitis
D. Folliculitis

D. Folliculitis Follicul/o is follicle. Cellulitis involves dermis and subcutis, and hidradenitis is a sweat gland.

9. What is the plural of nevus?

A. Nevi
B. Nevae
C. Nevuses
D. Neva

A. Nevi Words ending in -us take -i: nevus to nevi, said NEE-vye.

10. In "I&D of the abscess," what was done?

A. It was frozen with nitrogen
B. It was scraped, then burned
C. It was cut open and drained
D. A sample was cut for testing

C. It was cut open and drained I&D is incision and drainage. Freezing is cryosurgery and scraping plus burning is ED&C.

CHAPTER 6

The Musculoskeletal System

Read it in full: **Chapter 6 in the textbook**. Practice it in the lab: **The Bone Word Forge** and **The Fracture and Disease Lab**.

What to know

Bone has a Greek root, **oste/o**, used in diagnoses and procedures, and Latin roots, **oss/e** and **oss/i**, used in anatomy (osseous, ossification). Osteomyelitis is oste/o + myel + -itis, infection of bone and marrow. **Osteomalacia** is softening from poor mineralization. **Osteoporosis** is porous bone: normally mineralized but less of it. **Osteopenia** is density below normal but not yet osteoporosis. Sarcopenia (sarc/o, flesh) is age-related loss of muscle mass.

Long bone parts use **-physis**, growth. The **diaphysis** (through) is the shaft. The **epiphysis** (upon) is the widened end. The **metaphysis** (beyond, change) is the transition zone with the growth plate in children. A symphysis (together) is a joint joined by fibrocartilage, like the pubic symphysis. The **periosteum** wraps the outside and the **endosteum** lines the medullary cavity. Bone cells: an osteoblast builds bone, an osteoclast breaks it down and an osteocyte is the mature cell. Blast builds, clast crushes.

Chondr/o is cartilage: chondromalacia patellae is soft cartilage behind the kneecap, and costochondritis is rib cartilage inflammation that can mimic cardiac pain. -sarcoma is a malignant connective tissue tumor (chondrosarcoma, osteosarcoma); -oma alone is usually benign. **Myel/o** means marrow (osteomyelitis, myelosuppression, multiple myeloma) or spinal cord (myelogram, myelopathy); neighbors in the term or note decide. **My/o** is muscle: myositis vs myelitis, myopathy vs myelopathy.

The axial skeleton is the skull, spine, ribs and sternum. A **craniotomy** opens the skull and replaces the bone flap; a **craniectomy** removes a piece and does not replace it. Cost/o is rib (intercostal); stern/o is breastbone (sternotomy). The spine has three roots: vertebr/o for adjectives (intervertebral), **spondyl/o** for diagnoses (spondylosis, spondylitis) and rachi/o (rachischisis). Levels are C1 to C7, T1 to T12, L1 to L5, then sacrum and coccyx. Chondr/o (cartilage) is not condyl/o (condyle); epicondylitis is tennis elbow.

Each appendicular bone gives a combining form: clavicul/o, scapul/o, acromi/o, humer/o, radi/o, uln/o, carp/o, metacarp/o, phalang/o, femor/o, patell/o, tibi/o, fibul/o (perone/o), tars/o, calcane/o. The pelvis is ilium (ili/o), ischium (ischi/o) and pubis (pub/o), meeting at the acetabulum, the hip

socket. **Ili/o** is the hip bone; **ile/o** is the ileum of the bowel. Plurals: vertebrae, bursae, menisci, radii, acetabula, epiphyses, phalanges, cortices.

Joints are arthr/o (Greek, clinical) and articul/o (Latin, descriptive). Synovi/o is the joint lining; burs/o is the fluid sac; ligament/o connects bone to bone; ten/o and tendin/o name tendon, which connects muscle to bone. The correct spelling is **tendinitis**. Tenorrhaphy sutures a tendon; tenosynovitis inflames a tendon and its sheath. Fasci/o is fascia; menisc/o is meniscus; ankyl/o is stiff or fused.

Muscle is my/o, myos/o and muscul/o. **Rhabdomy/o** is skeletal (striated) muscle and **leiomy/o** is smooth muscle: a leiomyoma is a benign uterine fibroid, a rhabdomyosarcoma is a malignancy. **Rhabdomyolysis** is breakdown of skeletal muscle that dumps myoglobin and can harm the kidneys, with CK in the thousands and tea-colored urine. -trophy is development (atrophy, hypertrophy, dystrophy), -asthenia is weakness, -plegia is paralysis, -paresis is weakness, -tonia is tone.

Motion: abduction away and adduction toward the midline; flexion decreases a joint angle and extension increases it; supination turns the palm up and pronation down; dorsiflexion lifts the toes and plantar flexion points them; inversion turns the sole in and eversion out; circumduction is a cone-shaped motion. A contracture is permanent shortening that fixes a joint. Crepitus is grating. A **sprain** injures a ligament; a **strain** injures a muscle or tendon (t for tendon). A subluxation is a partial dislocation.

Fractures (Fx): closed leaves skin intact; open (compound) breaks the skin and risks infection. By line: transverse, oblique, spiral (from rotation), comminuted (three or more pieces), impacted, compression (a collapsed vertebra, often the first sign of osteoporosis). By cause: greenstick (incomplete, in children), pathologic (through diseased bone), stress (repetitive loading). Colles fracture is a distal radius fracture; Pott fracture involves the distal fibula. Reduction restores alignment, closed or open; fixation is internal or external. **ORIF** is open reduction with internal fixation.

Spinal curves: **kyphosis** is exaggerated rounding of the upper back, **lordosis** is exaggerated inward sway of the lower back and **scoliosis** is a sideways curve. Spondylolisthesis is a vertebra

slipping forward, often at L5-S1. **OA** (DJD) is wear of cartilage: asymmetric, weight-bearing joints, morning stiffness under about 30 minutes. **RA** is autoimmune synovitis: symmetric, small joints of the hands, stiffness an hour or more. Gout comes from urate crystals; in the great toe it is podagra. Ankylosing spondylitis can fuse the spine. Carpal tunnel syndrome compresses the median nerve. HNP is a herniated disc.

Myasthenia gravis is an autoimmune attack at the neuromuscular junction, with weakness that worsens with use. Duchenne muscular dystrophy is X-linked. Fibromyalgia is widespread pain with fatigue. Osteogenesis imperfecta is imperfect bone formation. Paget disease raises alkaline phosphatase. Multiple myeloma causes lytic lesions and pathologic fractures.

Testing: arthroscopy looks inside a joint; arthrography images it with contrast. **DXA** reports a T-score: -1.0 to -2.5 is osteopenia; -2.5 or lower is osteoporosis. EMG records muscle electrical activity; goniometry measures joint angles. CK rises with muscle damage; uric acid supports gout, but crystals from arthrocentesis confirm it. Surgery: osteotomy cuts bone, meniscectomy removes a meniscus, arthroplasty rebuilds or replaces a joint (THA, TKA), arthrodesis fuses it, osteoclasis breaks a bone on purpose, tenorrhaphy sutures a tendon, laminectomy removes part of the vertebral arch, fasciotomy relieves compartment syndrome. Weight-bearing orders: NWB, PWB, WBAT. MD, PT, DC and OS can each mean two things, so write them out.

A long bone, decoded: most part names end in -physis (growth)

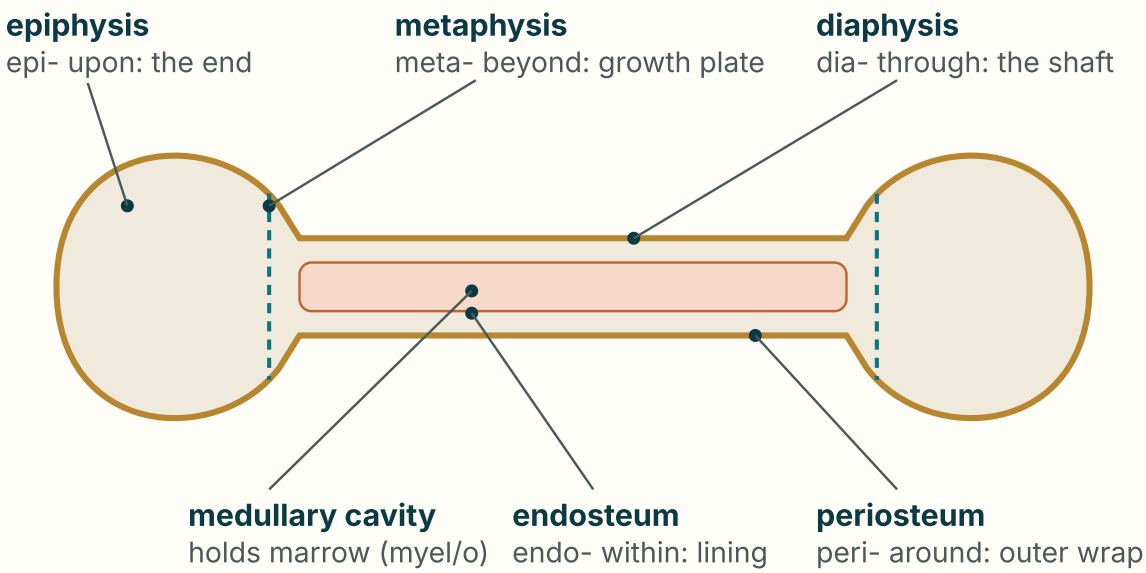

Prefix plus -physis. The same prefixes (epi-, meta-, dia-, peri-, endo-) appear all over medicine, so one decoded bone teaches a dozen terms.

LOCK THESE IN

- Oste/o in diagnoses, oss/e in anatomy. Osteomalacia is soft; osteoporosis is porous; osteopenia is low but not yet porosis.
- Diaphysis shaft, epiphysis end, metaphysis growth zone; periosteum outside, endosteum inside.
- Osteoblast builds, osteoclast breaks down, osteocyte is mature.
- Myel/o is marrow or spinal cord; my/o is muscle. Ili/o is hip bone; ile/o is bowel.
- Spondyl/o for diagnoses, vertebr/o for adjectives. Craniotomy replaces the flap; craniectomy does not.
- Sprain is ligament; strain is muscle or tendon. Spell it tendinitis.
- Kyphosis upper back hump, lordosis lower back sway, scoliosis sideways.
- DXA T-score: -1.0 to -2.5 osteopenia; -2.5 or lower osteoporosis. ORIF is open reduction, internal fixation.

Word parts for bones, joints and muscles

Word part	Meaning	Example term	What it means
oste/o; oss/e, oss/i	bone	osteotomy; osseous	cutting bone; bony
chondr/o	cartilage	costochondritis	rib cartilage inflammation
myel/o	marrow; spinal cord	osteomyelitis; myelogram	bone and marrow infection; cord image
-physis	growth	epiphysis, diaphysis	bone end; shaft
-blast, -clast, -cyte	builder, breaker, cell	osteoblast, osteoclast, osteocyte	bone cells
-porosis, -penia, -malacia	porous, deficiency, softening	osteoporosis, osteopenia, osteomalacia	bone conditions
crani/o, cost/o, stern/o	skull, rib, breastbone	craniectomy, intercostal, sternotomy	skull piece removed; between ribs; cut through sternum
vertebr/o, spondyl/o, rachi/o	vertebra, spine	intervertebral, spondylosis, rachischisis	between vertebrae; spine degeneration; split spine
lamin/o	lamina	laminectomy	removing part of the vertebral arch
ili/o, ischi/o, pub/o, acetabul/o	hip bones, socket	iliac crest, ischial, suprapubic, acetabular	pelvis parts
carp/o, metacarp/o, phalang/o	wrist, hand, digit bones	carpal tunnel, metacarpophalangeal	wrist passage; knuckle joint
femor/o, patell/o, tibi/o, fibul/o	thigh, kneecap, shin, fibula	patellofemoral, peroneal	kneecap and femur; near the fibula

Word part	Meaning	Example term	What it means
tars/o, calcane/o	ankle, heel	metatarsal, calcaneal spur	foot bones; heel spur
arthr/o, articul/o	joint	arthralgia, articular	joint pain; joint surface
synovi/o, burs/o	joint lining, fluid sac	synovitis, bursitis	inflamed lining; inflamed bursa
ten/o, tendin/o, ligament/o	tendon, ligament	tenorrhaphy, tendinitis	tendon suture; tendon inflammation
fasci/o, menisc/o, ankyl/o	fascia, meniscus, stiff	fasciotomy, meniscectomy, ankylosis	fascia cut; meniscus removed; fused joint
rhabdomy/o, leiomy/o	skeletal, smooth muscle	rhabdomyolysis, leiomyoma	muscle breakdown; fibroid
-trophy, -asthenia, -tonia	development, weakness, tone	atrophy, myasthenia, hypotonia	wasting; muscle weakness; floppiness
kyph/o, lord/o, scoli/o	hump, swayback, crooked	kyphosis, lordosis, scoliosis	spinal curves
-listhesis, -schisis	slipping, splitting	spondylolisthesis	vertebra slips forward
-desis, -clasis	fusion, breaking	arthrodesis, osteoclasis	joint fused; bone broken on purpose

Orthopedic abbreviations

Abbreviation	Meaning	Where you see it
Fx	fracture	triage, radiology
ROM, AROM, PROM	range of motion, active, passive	therapy and nursing notes
ORIF	open reduction, internal fixation	operative reports
THA / TKA	total hip / knee arthroplasty	post-op orders
OA, DJD, RA	osteoarthritis, degenerative joint disease, rheumatoid arthritis	problem lists
HNP, CTS	herniated nucleus pulposus, carpal tunnel syndrome	spine and hand clinics
DXA (DEXA), EMG	bone density scan, electromyography	osteoporosis and nerve work-ups
ACL, PCL, MCL, LCL	cruciate and collateral ligaments of the knee	sports injuries
TMJ	temporomandibular joint	jaw pain
NWB, PWB, WBAT	non, partial, as-tolerated weight-bearing	mobility orders
AKA / BKA	above / below knee amputation	surgery
NSAID, IM	nonsteroidal anti-inflammatory drug, intramuscular	medication records

Worked cases

WORKED CASE 1 · DECODING A LONG ORTHOPEDIC TERM

Decode spondylolisthesis and say where it most often occurs.

STEP 1 · SUFFIX

-listhesis, slipping.

STEP 2 · ROOT

spondyl/o, vertebra (the Greek root used in diagnoses). The o is kept before a consonant.

ANSWER

A **vertebra slipping forward on the one below**, most often at L5-S1.

WORKED CASE 2 · CRANIOTOMY OR CRANIECTOMY

After surgery for brain swelling, Mr. Ito's note says a piece of skull was removed and not put back. Which term fits?

STEP 1 · WHAT HAPPENED TO THE BONE?

It was removed and kept out.

STEP 2 · MATCH THE SUFFIX

-tomy cuts in and the flap is replaced. -ectomy removes.

ANSWER

Craniectomy. A craniotomy replaces the bone flap.

WORKED CASE 3 · SPRAIN OR STRAIN

A runner hurts the back of her thigh; a soccer player rolls his ankle and tears a lateral ligament. Name each injury.

STEP 1 · FIND THE TISSUE

The hamstring is a muscle with tendons. The ankle injury is a ligament.

STEP 2 · APPLY THE RULE

Strain is muscle or tendon (t for tendon). Sprain is ligament.

ANSWER

Hamstring **strain**; ankle **sprain** (an inversion injury). "Sprained hamstring" gets the anatomy backward.

WORKED CASE 4 · READING A DXA RESULT

Mrs. Novak, 68, has a T-score of -2.8. Her friend has -1.6. Name each result.

STEP 1 · RECALL THE CUTOFFS

-1.0 to -2.5 is osteopenia; -2.5 or lower is osteoporosis.

STEP 2 · PLACE EACH SCORE

-2.8 is below -2.5. -1.6 falls between -1.0 and -2.5.

ANSWER

Mrs. Novak: **osteoporosis**. Her friend: **osteopenia**.

TRAPS PEOPLE FALL INTO

- **Reading osteomyelitis as a muscle problem.** Myel/o here is marrow. My/o would be muscle.
- **Treating osteomalacia and osteoporosis as the same.** Soft, poorly mineralized bone vs normal bone with less of it.
- **Spelling tendonitis in formal writing.** The correct build is tendinitis, from the stem tendin-.
- **Swapping sprain and strain.** Ligament is a sprain; muscle or tendon is a strain.
- **Confusing kyphosis and lordosis.** Kyphosis is the upper back hump; lordosis is the lower back sway.
- **Mixing chondr/o and condyl/o.** Cartilage vs the rounded knob on a bone.
- **Mixing arthr/o, arteri/o and ather/o.** Joint, artery, fatty plaque.
- **Assuming -oma means cancer.** Chondroma is benign; chondrosarcoma is malignant.
- **Trusting PT, MD, DC or OS.** Each has two meanings. Write the term out.

Chapter 6 self-test · ten items

1. Which term names bone that is soft from poor mineralization?

A. Osteoporosis
B. Osteopenia
C. Osteosclerosis
D. Osteomalacia

D. Osteomalacia -malacia is softening. Osteoporosis is porous bone with normal mineral, just less of it.

2. Which part of a long bone is the shaft?

A. Diaphysis
B. Epiphysis
C. Metaphysis
D. Symphysis

A. Diaphysis Dia- (through) + -physis (growth) is the shaft. The epiphysis is the end, upon the shaft.

3. Which cell breaks down bone?

A. Osteoblast
B. Osteocyte
C. Chondrocyte
D. Osteoclast

D. Osteoclast -clast means to break. The osteoblast builds bone and the osteocyte is the mature cell.

4. A note reads "cervical myelopathy." What is affected?

A. The muscles of the neck
B. The marrow of neck bones
C. The spinal cord in the neck
D. The cervix of the uterus

C. The spinal cord in the neck With a spinal or neurologic partner, myel/o means spinal cord. Muscle disease would be myopathy.

5. Which root is used in a diagnosis of degenerative vertebrae?

A. vertebr/o
B. rachi/o
C. spondyl/o
D. lamin/o

C. spondyl/o Spondyl/o takes the suffix in diagnoses (spondylosis). Vertebr/o forms adjectives such as intervertebral.

6. A fracture breaks the bone into three or more pieces. What type is it?

A. Greenstick
B. Spiral
C. Comminuted
D. Impacted

C. Comminuted Comminuted means shattered into three or more fragments. A spiral fracture comes from a twisting force.

7. Which statement fits rheumatoid arthritis rather than osteoarthritis?

A. Symmetric small joints, stiffness over an hour
B. Weight-bearing joints, stiffness under 30 minutes
C. Mechanical wear of articular cartilage
D. Also charted as degenerative joint disease

A. Symmetric small joints, stiffness over an hour RA is autoimmune synovitis: symmetric, small hand joints, long morning stiffness. The others describe OA (DJD).

8. What does arthrodesis do to a joint?

A. Rebuilds it with a prosthesis
B. Fuses it so it no longer moves
C. Drains fluid from inside it
D. Views it through a small scope

B. Fuses it so it no longer moves -desis is fusion. Arthroplasty rebuilds, arthrocentesis drains and arthroscopy views.

9. Which abbreviation means the patient may put as much weight on the leg as is comfortable?

A. NWB
B. PWB
C. ROM
D. WBAT

D. WBAT WBAT is weight-bearing as tolerated. NWB is none and PWB is partial.

10. What is the plural of meniscus?

A. Meniscuses
B. Menisci
C. Meniscae
D. Menisca

B. Menisci -us becomes -i: meniscus to menisci, said men-ISS-kye.

ONE PAGE

Cram sheet

Everything from chapters 5 and 6 in one place. Cover the right column and see if you can rebuild each row.

Word parts to know

Group	Parts and meanings
Skin	derm/o, dermat/o, cutane/o skin; -derma condition; -dermis layer; kerat/o horny tissue; squam/o scale
Appendages	seb/o oil; hidr/o, sudor/i sweat; trich/o, pil/o hair; onych/o, ungu/o nail; adip/o, lip/o, steat/o fat
Color	cyan/o blue; erythr/o red; leuk/o, alb/o white; melan/o black; xanth/o yellow; poli/o gray; chrom/o color
Skin pathology	myc/o fungus; staphyl/o cluster; strept/o chain; py/o pus; necr/o death; xer/o dry; rhytid/o wrinkle
Bone	oste/o, oss/e; chondr/o; myel/o; -physis; -blast; -clast; -porosis; -malacia; -penia
Skeleton	crani/o, cost/o, stern/o; vertebr/o, spondyl/o, rachi/o; ili/o, ischi/o, pub/o; carp/o, phalang/o; femor/o, patell/o, tibi/o, fibul/o; tars/o, calcane/o
Joint and muscle	arthr/o, articul/o; synovi/o; burs/o; ten/o, tendin/o; ligament/o; fasci/o; my/o; rhabdomy/o; leiomy/o; ankyl/o
Function suffixes	-trophy development; -asthenia weakness; -plegia paralysis; -paresis weakness; -listhesis slipping; -desis fusion; -clasis breaking

Key terms and comparisons

Pair or set	The difference
macule / patch; papule / plaque; vesicle / bulla	under 1 cm / over 1 cm
erosion vs ulcer	epidermis only, no scar vs through dermis, scars
furuncle vs carbuncle	one infected follicle vs several joined
autograft / allograft / xenograft	self / another human / another species
STSG vs FTSG	part of the dermis vs all of it
osteomalacia / osteoporosis / osteopenia	soft / porous / low but not yet porous
craniotomy vs craniectomy	flap replaced vs bone left out
sprain vs strain	ligament vs muscle or tendon
kyphosis / lordosis / scoliosis	upper hump / lower sway / sideways
OA vs RA	wear, asymmetric, short stiffness vs autoimmune, symmetric, long stiffness
DXA T-score	-1.0 to -2.5 osteopenia; -2.5 or lower osteoporosis

Abbreviations

Abbreviation	Meaning
BCC, SCC, MM, AK	basal cell, squamous cell carcinoma; malignant melanoma; actinic keratosis
I&D, ED&C, Bx	incision and drainage; electrodesiccation and curettage; biopsy
TBSA, STSG, FTSG, NPWT	burn area; graft depths; vacuum dressing
PI, DTPI, C&S, KOH	pressure injury; deep tissue PI; culture and sensitivity; fungal prep
Fx, ORIF, THA, TKA	fracture; open reduction internal fixation; hip and knee replacement
OA, DJD, RA, HNP, CTS	arthritis types; herniated disc; carpal tunnel
NWB, PWB, WBAT, AKA, BKA	weight-bearing orders; amputation levels
Write out	subcut (not SC, SQ); unit (not U); MD, PT, DC, OS when ambiguous

Dr. Garg Learning · CC BY-SA 4.0