MEDICAL TERMINOLOGY · STUDY GUIDE

Exam 2 Study Guide

This guide covers chapters 3 and 4. First you will learn the prefixes, the small set of word parts at the front of a term that say where, how many, when and how well. Then you will put words onto a real body: levels of organization, the anatomical position, directional pairs, planes, patient positions, cavities and the abdominal map. Work one chapter at a time. Read the "what to know" paragraphs, copy the tables out by hand, then try each worked case with the steps covered. Finish each chapter with its ten self-test items. The cram sheet at the end puts every pair and every map in one place.

WHAT THIS GUIDE COVERS

- Chapter 3 · what a prefix does and why it takes no combining vowel; assimilation (an-, sym-, im-); prefixes of position and direction; number and quantity; time, speed and sequence; negation, opposition and quality; the confusable pairs.
- Chapter 4 · levels of organization and tissue roots; anatomical position; directional pairs and -ad; AP and PA; planes and the tom/o family; patient positions; dorsal and ventral cavities; parietal and visceral; quadrants and nine regions; regional roots and plurals.

CHAPTER 3

Prefixes: Position, Number, Time and Negation

Read it in full: **Chapter 3 in the textbook**. Practice it in the lab: **Where the Prefix Puts It** and **The Quantity Dial**.

What to know

A prefix sits at the front of a term and qualifies it. It is never the subject. The root says what the term is about, the suffix gives the verdict, and the prefix narrows it. Tension is pressure. Hypertension is pressure above normal. Hypotension is pressure below normal. Not every term has a prefix: gastritis is complete with a root and a suffix.

A prefix attaches straight to what follows, with no combining vowel: pericarditis, sublingual. What can change is the prefix itself, for ease of saying it. This is **assimilation**. A- becomes an- before a vowel or h (apnea, but anemia and anesthesia). Syn- becomes sym- before b, m or p (syndrome, but symphysis). In- (not) becomes im- before b, m or p (impermeable). In a glossary a prefix is written with a hyphen after it (peri-), but the hyphen is never typed in the finished word. A prefix also never changes how the word forms its plural: metastasis to metastases, diverticulum to diverticula.

Hyper- means above normal and **hypo-** means below normal or under. They differ by one letter and mean opposite things. Hyperkalemia (potassium too high) and hypokalemia (potassium too low) need opposite treatment. Say the whole word aloud and read it fully. Hypodermic, the needle that goes under the skin, anchors hypo- as the low one.

Position prefixes answer "where." Endo- is within, epi- is upon, peri- is around. On the heart, the endocardium lines the chambers, the epicardium lies on the surface and the pericardium is the sac around it. The same prefixes move to other organs: endometrium, epidermis, periosteum. Sub- and infra- are under, supra- is above, extra- and ecto- are outside, retro- is behind, meso- is middle, juxta- is near. **Inter-** is between (intercostal, between the ribs) and **intra-** is within (intramuscular, inside the muscle).

Direction prefixes describe movement. Trans- and per- mean through: a transdermal patch, a percutaneous procedure. Per- (through) is not peri- (around). **Ab-** is away from and **ad-** is toward: abduction moves a limb away from the midline and adduction brings it back. Dia- is through or complete (dialysis), ana- is up (anabolism) and cata- is down (catabolism). Ipsi- is same side and contra- is opposite side. Afferent nerves carry signals toward the central nervous system and efferent nerves carry them out.

Three prefixes have more than one sense. **Para-** means beside (parathyroid), abnormal (paresthesia, pins and needles) or assisting (paramedic). **Retro-** means behind or backward: the kidneys are retroperitoneal, and retrosternal chest pain sits behind the breastbone. **Meta-** means beyond, after or change: metastasis is spread beyond the first site, metacarpals lie beyond the carpals, and metabolism is chemical change.

Number prefixes come from both Latin and Greek, and both are correct. One is uni- or mono-. Two is bi- or di-. Three is tri-. Four is quadri- or tetra- (quadriplegia and tetraplegia are the same thing). Many is multi- or poly-. Primi- is first, nulli- is none and pan- is all (pancytopenia, too few of every blood cell). **Hemi-** (Greek) is a true half, usually one side of the body: hemiplegia. **Semi-** (Latin) is partial: semiconscious, semi-Fowler. Trisomy 21 is the descriptive term for Down syndrome: three copies of chromosome 21.

Quantity prefixes build graded scales. Put hyper- or hypo- in front of a substance root and add -emia: hyperkalemia (kal- from kalium, potassium), hyponatremia (natr- from natrium, sodium), hypercalcemia, hyperglycemia. Urine output has three steps: **polyuria** (too much), **oliguria** (scanty, in adults about under 400 mL in 24 hours) and **anuria** (essentially none). Macro- and micro- are large and small; iso- is equal, normo- is normal, homeo- is unchanging, hetero- is different.

Time prefixes organize the chart. Pre-, intra- and post- give preoperative, intraoperative and postoperative. Ante-, intra- and post- with partum give the phases of childbirth. Peri- covers the whole window around an event: perioperative, perinatal. Pro- means before or forward: a prognosis is a forecast and a prodrome is the early symptom set before an illness. Post- also gives postprandial (after a meal) and postictal (after a seizure). **Ante-** (before) and **anti-** (against) sound alike and are unrelated.

Speed prefixes: **tachy-** is fast and **brady-** is slow. In an adult, tachycardia is a heart rate above about 100 and bradycardia is below about 60. Tachypnea is fast breathing and bradykinesia is slow movement. **Neo-** is new: a neonate is an infant in the first 28 days, and a neoplasm is a new growth. Neoplastic does not mean cancer; a neoplasm can be benign or malignant. Re- is again (relapse). Syn- or sym- is together (syndrome, syndactyly).

Negation, opposition and quality are three different jobs. **A-** and **an-** mean absent, not reduced: apnea is no breathing, anuria is no urine. Aphasia, agnosia, apraxia and ataxia are loss of speech, recognition, learned movement and coordination. In-, im-, ir-, non- and un- mean not, but in- can also mean into (incision, intubation). Opposition prefixes act against: anti- (antipyretic, anticoagulant), contra- (contraindication) and de- (removal, as in dehydration and debridement). Quality prefixes judge: **dys-** is painful, difficult or abnormal (dyspnea, dysplasia), **eu-** is normal

(eupnea, euthyroid), **mal-** is bad or poor (malabsorption, malunion) and **pseudo-** is false (pseudoaneurysm). Ortho- is straight or upright: orthopnea is breathlessness unless sitting up.

Prefixes name the layers

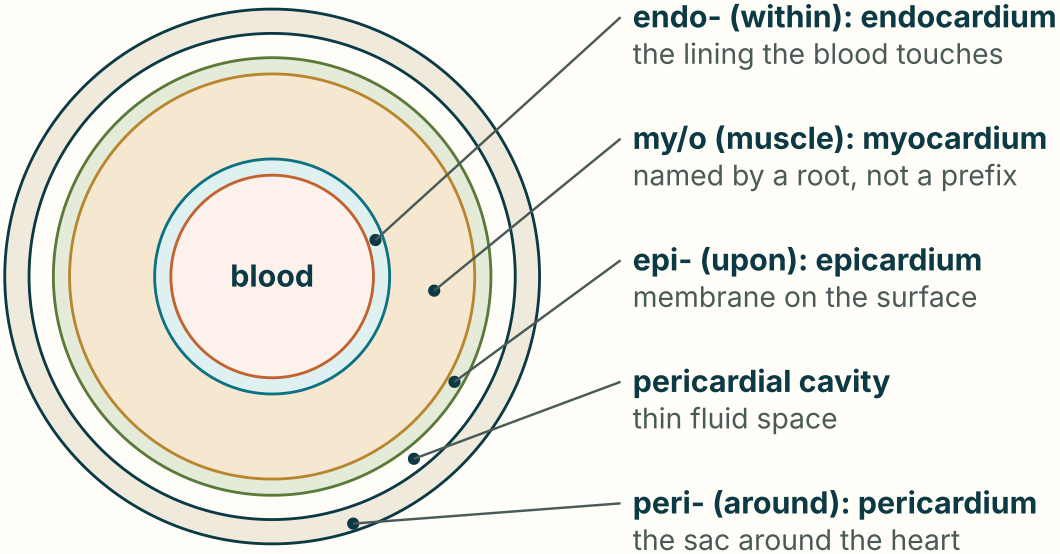

Add -itis: endocarditis, myocarditis, pericarditis.

One root, four positions. Endo-, epi- and peri- move to other organs unchanged: endometrium, epidermis, periosteum.

LOCK THESE IN

- Prefixes take no combining vowel and never change the plural.
- Assimilation: a- to an- before a vowel or h; syn- to sym- and in- to im- before b, m or p.
- Hyper- above normal, hypo- below normal or under. Read the whole word every time.
- Inter- between, intra- within; ab- away, ad- toward; per- through, peri- around.
- Hemi- is a true half (hemiplegia); semi- is partial (semi-Fowler).
- Urine scale: polyuria, oliguria (under about 400 mL/24 h in adults), anuria.
- Ante- before, anti- against. Tachy- fast (over about 100 bpm), brady- slow (under about 60 bpm).
- A- means absent; dys- means difficult or abnormal; eu- means normal; mal- means poor; pseudo- means false.

Prefixes of position and direction

Prefix	Meaning	Example term	What it means
endo-	within	endocardium	inner lining of the heart
epi-	upon, above	epidural	upon or outside the dura
peri-	around	periosteum	membrane around a bone
inter-	between	intercostal	between the ribs
intra-	within	intramuscular	within a muscle
sub-, infra-	under, below	subcutaneous, infraorbital	under the skin; below the eye socket
supra-	above	suprapubic	above the pubic bone
extra-, ecto-	outside	extracellular, ectopic	outside the cell; out of place
retro-	behind, backward	retroperitoneal	behind the peritoneum
para-	beside; abnormal	parathyroid, paresthesia	beside the thyroid; abnormal sensation
meta-	beyond, after, change	metastasis	spread beyond the first site
trans-, per-	across, through	transdermal, percutaneous	through the skin
ab-, ad-	away from, toward	abduction, adduction	away from, toward the midline
dia-	through, complete	dialysis	separating through a membrane
ana-, cata-	up, down	anabolism, catabolism	building up, breaking down
ipsi-, contra-	same, opposite	ipsilateral, contralateral	same side, opposite side

Prefixes of number, quantity, time and quality

Prefix	Meaning	Example term	What it means
mono-, uni-	one	mononucleosis, unilateral	single-nucleus cells increased; one side
bi-, di-, dipl/o-	two, double	bilateral, diplopia	both sides; double vision
tri-; quadri-, tetra-	three; four	trisomy 21; tetraplegia	three copies; paralysis of four limbs
multi-, poly-	many, excessive	multipara, polydipsia	has given birth more than once; excessive thirst
primi-, nulli-, pan-	first, none, all	primigravida, nullipara, pancytopenia	first pregnancy; never given birth; all cells low
hemi-, semi-	half; partial	hemiparesis, semilunar	one-sided weakness; half-moon shaped
hyper-, hypo-	above, below normal	hyperkalemia, hypothermia	high potassium; low temperature
olig/o-	scanty	oliguria	low urine output
macro-, micro-	large, small	macrocytic, microcephaly	large cells; small head
iso-, homeo-, hetero-	equal, unchanging, different	isotonic, homeostasis, heterogeneous	same strength; steady state; unlike parts
pre-, pro-, ante-	before	prenatal, prodrome, antepartum	before birth; early symptoms; before delivery
post-, peri-, intra-	after, around, during	postprandial, perioperative, intrapartum	after a meal; around surgery; during labor
neo-, re-, syn-	new, again, together	neonate, relapse, syndactyly	newborn; return of disease; joined digits

Prefix	Meaning	Example term	What it means
tachy-, brady-	fast, slow	tachypnea, bradykinesia	fast breathing; slow movement
a-, an-	without	apnea, anesthesia	no breathing; no sensation
anti-, contra-, de-	against; removal	antipyretic, contraindication, debridement	against fever; reason not to treat; removing dead tissue
dys-, eu-, mal-, pseudo-	abnormal, normal, poor, false	dysplasia, eupnea, malunion, pseudoaneurysm	disordered cells; normal breathing; bad healing; false aneurysm
ortho-, auto-, allo-, xen/o-	upright, self, other, foreign	orthopnea, autoimmune, allograft, xenograft	breathless lying flat; self attack; same-species graft; other-species graft

Worked cases

WORKED CASE 1 · SWAPPING THE PREFIX ON ONE ROOT

Hold -cardia still and swap the front: build the terms for a fast heart rate, a slow heart rate and a heart on the right side of the chest.

STEP 1 · PICK THE PREFIXES

Fast is tachy-, slow is brady-, right is dextro-.

STEP 2 · ATTACH WITH NO VOWEL

Prefixes join directly to what follows.

STEP 3 · WRITE THE TERMS

Tachycardia, bradycardia, dextrocardia.

ADD THE NUMBERS

In an adult, tachycardia is above about 100 beats per minute and bradycardia is below about 60.

WORKED CASE 2 · BUILDING THE URINE OUTPUT SCALE

Mr. Okafor's urine output is charted three days in a row as too much, then scanty, then none. Name each day.

STEP 1 · THE SUFFIX

-uria is a urine condition. It stays the same on all three days.

STEP 2 · THE PREFIXES

Too much is poly-. Scanty is olig-. None is a- or an-.

STEP 3 · APPLY ASSIMILATION

-uria begins with a vowel, so the negative prefix takes the an- form.

ANSWER

Polyuria, oliguria, anuria. Oliguria in an adult is roughly under 400 mL in 24 hours.

WORKED CASE 3 · DECODING A LAB TERM

A potassium level is reported as high. Build the term and its opposite.

STEP 1 · THE SUBSTANCE ROOT

kal- comes from kalium, the Latin name behind the symbol K.

STEP 2 · THE SUFFIX

-emia is a blood condition.

STEP 3 · THE PREFIX

Above normal is hyper-; below normal is hypo-.

ANSWER

Hyperkalemia; the opposite is hypokalemia. They need opposite treatments, so never write "hyperK" or "hypoK" in a note.

WORKED CASE 4 · CHOOSING BETWEEN LOOK-ALIKE PREFIXES

A note on a stroke patient, Mrs. Lindqvist, reads "dysphasia; keep NPO until swallow study." Is the term right?

STEP 1 · SPLIT THE TERM

dys- (difficult) + -phasia (speech).

STEP 2 · MATCH THE FINDING

Keeping a patient NPO for a swallow study is about swallowing, not speech.

STEP 3 · CORRECT IT

Swallowing is phag/o, so the right term is **dysphagia** (the g is for gulping).

WHY IT MATTERS

Charting the wrong one can feed a patient who will aspirate, or withhold food from one who can eat.

TRAPS PEOPLE FALL INTO

- **Adding a vowel after a prefix.** It is pericarditis, never "periocarditis."
- **Glancing at hyper- and hypo-.** One letter, opposite meanings. Read the whole word aloud.
- **Mixing inter- and intra-.** Inter- is between two things; intra- is inside one thing.
- **Reversing abduction and adduction.** Abduction takes the limb away; adduction adds it back.
- **Using semi- for one side of the body.** A stroke patient is hemiplegic, never semiplegic.
- **Reading neoplastic as cancer.** Neo- only says the growth is new. It can be benign or malignant.
- **Treating a- as "reduced."** Apnea is no breathing, not slow breathing.
- **Mixing ante- and anti-.** Antepartum is before birth; an antiemetic works against vomiting.
- **Reading every in- as "not."** Incision and intubation use in- meaning into.

Chapter 3 self-test · ten items

1. Why is it anemia but apnea?

A. an- is the Greek form of the prefix
B. anemia has two roots in it
C. apnea drops a combining vowel
D. a- becomes an- before a vowel

D. a- becomes an- before a vowel Assimilation turns a- into an- before a vowel or h, so an- goes before -emia and a- before the consonant in -pnea.

2. An injection goes inside the muscle. Which prefix fits?

A. inter-
B. intra-
C. infra-
D. epi-

B. intra- Intra- means within, so intramuscular is within the muscle. Inter- means between two things.

3. A shoulder exercise moves the arm away from the midline. What is it called?

A. Adduction
B. Abduction
C. Circumduction
D. Retraction

B. Abduction Ab- means away from. Adduction, with ad- meaning toward, brings the arm back to the body.

4. Which term means a deficiency of all blood cell types?

A. Polycythemia
B. Leukopenia
C. Pancytopenia
D. Hemicytopenia

C. Pancytopenia Pan- (all) + cyt/o (cell) + -penia (deficiency): red cells, white cells and platelets are all low.

5. A patient's urine output is scanty. Which term fits?

A. Oliguria
B. Anuria
C. Polyuria
D. Dysuria

A. Oliguria Olig- means scanty. Anuria is essentially no output, polyuria is too much and dysuria is painful urination.

6. Which term names the period after a meal?

A. Preprandial
B. Postictal
C. Postprandial
D. Perinatal

C. Postprandial Post- means after and prandial refers to a meal. Postictal is after a seizure.

7. Which statement about a neoplasm is correct?

A. It is always a malignant tumor
B. It is a new growth, benign or malignant
C. It is a tumor found only in newborns
D. It is a growth that has spread away

B. It is a new growth, benign or malignant Neo- means new. A neoplasm can be benign or malignant; malignancy is signaled by other word parts.

8. A patient can breathe only when sitting upright. Which term fits?

A. Orthopnea
B. Eupnea
C. Apnea
D. Tachypnea

A. Orthopnea Ortho- means straight or upright, so orthopnea is breathlessness unless sitting up. Eupnea is normal breathing.

9. Which prefix in these terms means "against"?

A. ante- in antecubital
B. ante- in antepartum
C. pro- in prodrome
D. anti- in antiemetic

D. anti- in antiemetic Anti- means against. Ante- means before or in front of, and pro- means before or forward.

10. Which word names a false aneurysm that lacks all three vessel layers?

A. Pseudoaneurysm
B. Microaneurysm
C. Varicocele
D. Hemangioma

A. Pseudoaneurysm Pseudo- means false. The wall rupture is contained, but it is not a true aneurysm.

CHAPTER 4

Body Structure, Directional Terms and Planes

Read it in full: **Chapter 4 in the textbook**. Practice it in the lab: **The Anatomical Compass** and **Cavities, Quadrants and Regions**.

What to know

Anatomy is ana- (up, apart) + -tomy (cutting): the parts list. Physiology is physi/o (nature, function) + -logy: how the parts work. Pathology is path/o (disease) + -logy. The body is built in levels: chemical, cell, tissue, organ, organ system, organism. Cyt/o (or -cyte) means cell, so cytology is the study of cells, as in a Pap test. Hist/o means tissue, so histology is the study of tissue under a microscope, where a biopsy goes.

Other level roots: kary/o and nucle/o (nucleus; a karyotype is a picture of the chromosomes), somat/o (body), viscer/o (internal organs) and organ/o (organ). -plasm means formation or substance: cytoplasm, neoplasm. With -plasia: hyperplasia is too many cells, aplasia is absent formation and dysplasia is disordered formation, not yet cancer. Blast/o is an immature cell (osteoblast), morph/o is shape and -genesis is origin.

The four tissue types are epithelial (covering and lining), connective (bone, cartilage, fat, blood), muscle and nervous. Their roots: epitheli/o, my/o and muscul/o (muscle), myel/o (marrow or spinal cord), neur/o (nerve), oste/o (bone), chondr/o (cartilage), adip/o, lip/o and steat/o (fat), fibr/o (fiber), hem/o and hemat/o (blood), angi/o and vas/o (vessel). Osteomyelitis is infection of bone and marrow, not muscle.

Local means confined to one area and **systemic** means affecting the whole body. **Somatic** pain comes from skin, muscle or bone and is easy to point to. **Visceral** pain comes from internal organs and is dull and hard to place.

Every directional term assumes the **anatomical position**: standing, facing forward, arms at the sides, palms forward, feet slightly apart. The terms describe the body, not how it lies right now. Right and left always mean the patient's right and left. Palms forward is why the thumb and the radius are lateral.

Directional terms come in pairs. Superior is toward the head and inferior toward the feet. Anterior (ventral) is front and posterior (dorsal) is back. Medial is toward the midline and lateral is away from it. **Proximal** is nearer the trunk and **distal** is farther: the elbow is proximal to the wrist. Superficial is near the surface and deep is away from it. Cephalad is toward the head and caudal toward the tail. The suffix -ad means toward: cephalic is "of the head," cephalad is "toward the

head." In the hand and foot, dorsum keeps its animal sense: the dorsum of the foot is its top, the sole is plantar and the palm is palmar or volar.

Directional roots stack with a combining vowel. **Anteroposterior (AP)** is front to back and **posteroanterior (PA)** is back to front. The order names the path of the x-ray beam. A standard chest film is PA, which keeps the heart near the plate and true to size. A portable AP film magnifies the heart, so an AP film alone should not be used to call the heart enlarged. A stroke in the right hemisphere causes weakness on the **contralateral** (left) side, because motor tracts cross. On a standard film the patient's right appears on your left.

A plane is an imaginary flat surface; a section is the cut along it. The **sagittal** plane divides right from left. A midsagittal (median) cut makes equal halves; a parasagittal cut is off center. The **frontal (coronal)** plane divides front from back. The **transverse** (horizontal or axial) plane divides upper from lower and is the plane of a standard CT slice. An oblique plane is any slanted cut.

Tom/o means to cut. A **-tome** is an instrument that cuts (osteotome, dermatome). A **-tomy** is an incision and the structure stays. An **-ectomy** removes it. An **-ostomy** makes an opening. Gastrotomy cuts into the stomach, gastrectomy removes it and gastrostomy opens it for a feeding tube. Tomography records the body in slices.

Positions are orders. **Supine** is on the back, face up (you lie on your spine). **Prone** is face down. Lateral recumbent is on one side. **Fowler** raises the head of the bed about 45 to 60 degrees, semi-Fowler about 30 to 45 and high Fowler about 60 to 90. **Trendelenburg** tilts the whole bed head-down; reverse Trendelenburg tilts it head-up. **Lithotomy** is on the back with hips and knees flexed and feet in stirrups. **Sims** is left side-lying with the right knee drawn up, used for rectal exams and enemas. Orthopneic is sitting up and leaning forward. Fowler, Trendelenburg and Sims are eponyms, now usually written without the possessive.

The **dorsal cavity** holds the brain (cranial cavity) and spinal cord (spinal cavity). The **ventral cavity** is split by the diaphragm into the thoracic cavity and the abdominopelvic cavity. The thoracic cavity holds two pleural cavities and the **mediastinum**, the central space with the heart in its pericardial cavity, the esophagus, trachea, thymus and great vessels. **Retroperitoneal** organs sit

behind the peritoneum: kidneys, adrenal glands, ureters, most of the pancreas and duodenum, the abdominal aorta and the inferior vena cava. That is why kidney pain is felt in the flank and back.

Serous membranes have two layers. **Parietal** lines the cavity wall and **visceral** covers the organ, with a thin film of fluid between. The **peritoneum** lines the abdominal cavity; the **perineum** is the external area between the thighs. The abdomen is charted in four quadrants (RUQ, LUQ, RLQ, LLQ) for speed, or nine regions for precision: right and left hypochondriac (under the rib cartilage), epigastric (above the stomach), right and left lumbar, umbilical, right and left iliac or inguinal, and hypogastric (pubic). Pain that starts periumbilical and moves to the RLQ is the classic pattern of appendicitis.

Regional roots: cephal/o head, cervic/o neck or cervix, acr/o extremities, thorac/o chest, brachi/o arm, axill/o armpit, lumb/o lower back, glute/o buttock, inguin/o groin, umbilic/o and omphal/o navel, femor/o thigh, ped/o and pod/o foot, dactyl/o finger or toe. Ped/o also means child (pediatrics), so pod/o is the clear root for foot. Never pluralize a plural: there is no "diagnosises." Viscus is the singular of viscera, so a "perforated viscus" is one hollow organ.

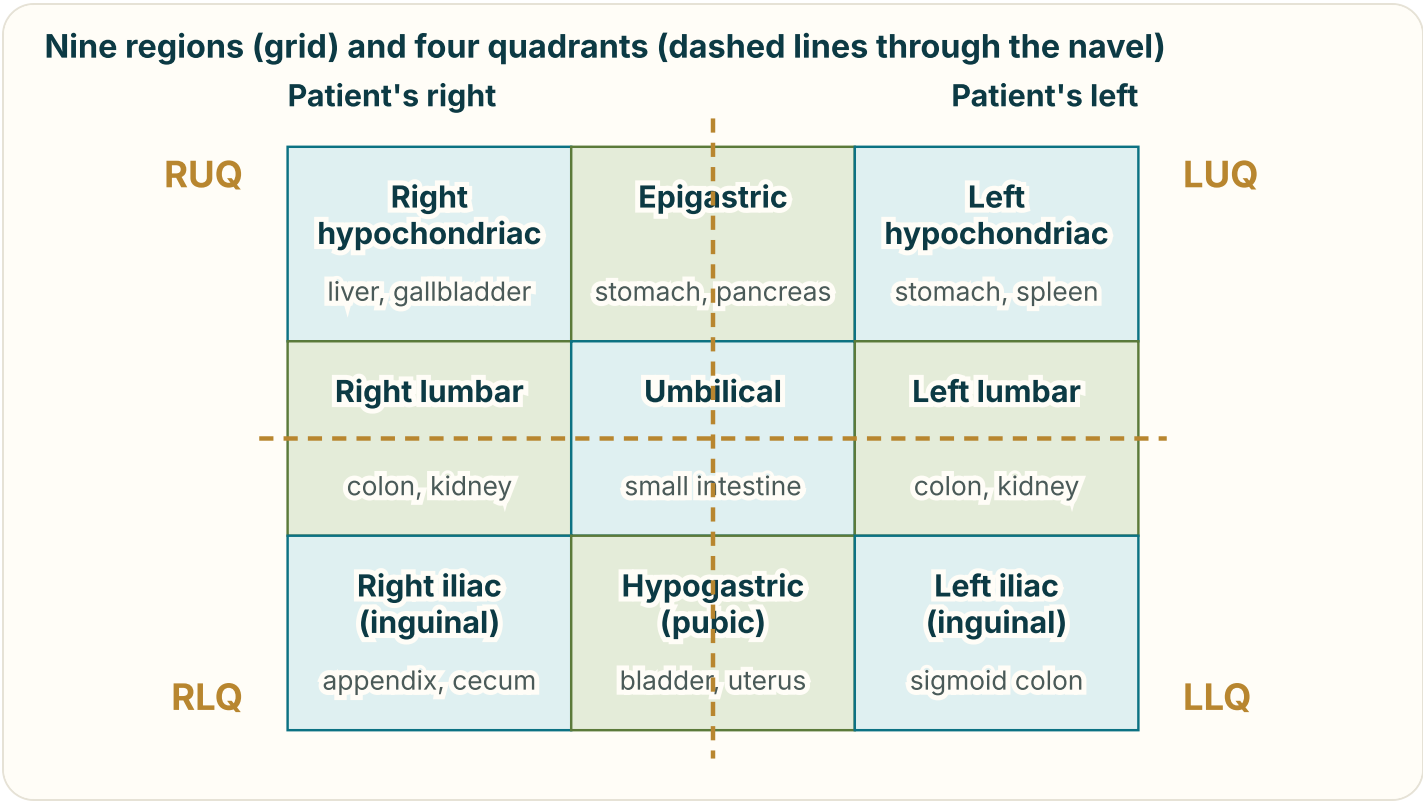

Facing the patient, their right is on your left. Quadrants are quick for charting; the nine regions are more precise, and every region name can be decoded.

LOCK THESE IN

- Levels: cell (cyt/o), tissue (hist/o), organ, system, organism. Cytology studies cells; histology studies tissue.
- Anatomical position: standing, facing forward, arms at sides, palms forward. Right and left are the patient's.
- Pairs: superior and inferior, anterior and posterior, medial and lateral, proximal and distal, superficial and deep.
- AP is front to back; PA is back to front. A standard chest film is PA.
- Sagittal splits right and left; frontal (coronal) splits front and back; transverse (axial) splits upper and lower.
- -tome is the tool, -tomy the cut, -ectomy the removal, -ostomy the opening.
- Supine is face up, prone face down; Fowler head up 45 to 60 degrees; Trendelenburg head down.
- Retroperitoneal: kidneys, adrenals, ureters, most of pancreas and duodenum, aorta, IVC. Peritoneum is not perineum.

Word parts for structure, direction and regions

Word part	Meaning	Example term	What it means
cyt/o, -cyte	cell	cytoplasm	substance inside a cell, outside the nucleus
hist/o	tissue	histology	study of tissue
kary/o, nucle/o	nucleus	karyotype	picture of sorted chromosomes
somat/o; viscer/o	body; internal organs	somatic; visceral	of the body wall; of the organs
-plasia, -plasm	formation	dysplasia; neoplasm	disordered cells; new growth
blast/o	immature cell	osteoblast	immature bone-forming cell
chondr/o	cartilage	chondromalacia	softening of cartilage
adip/o, lip/o, steat/o	fat	adipose	fatty
super/o, infer/o	above, below	superior, inferior	toward the head, toward the feet
anter/o, poster/o	front, back	anteroposterior	front to back
medi/o, later/o	middle, side	medial, lateral	toward, away from the midline
proxim/o, dist/o	near, far	proximal, distal	nearer, farther from the trunk
cephal/o, caud/o	head, tail	cephalad, caudal	toward the head; toward the tail
-ad	toward	mediad	toward the midline
tom/o	to cut, slice	tomography	imaging in slices
crani/o, thorac/o	skull, chest	craniotomy, thoracotomy	incision into skull; into chest
pleur/o, mediastin/o	pleura, mediastinum	pleuritis, mediastinitis	inflammation of each

Word part	Meaning	Example term	What it means
periton/o, peritone/o	peritoneum	peritonitis	inflammation of the peritoneum
hypo- + chondr/o	under + cartilage	hypochondriac region	upper side region, under the rib cartilage
brachi/o, axill/o	arm, armpit	brachial, axillary	arm pulse; armpit nodes
inguin/o, umbilic/o	groin, navel	inguinal, periumbilical	of the groin; around the navel
ped/o, pod/o; dactyl/o	foot; finger or toe	pedal; polydactyly	of the foot; extra digits

Key terms and comparisons

Term	Meaning	Use or contrast
Midsagittal (median)	equal right and left halves	Parasagittal is off center
Frontal (coronal)	front and back portions	Follows the coronal suture
Transverse (axial)	upper and lower portions	Plane of a CT slice
Supine / prone	face up / face down	Proning helps severe hypoxemia
Fowler; semi-Fowler; high Fowler	head up about 45 to 60; 30 to 45; 60 to 90 degrees	Breathing, eating, aspiration risk
Trendelenburg / reverse	bed tilted head-down / head-up	Some pelvic surgery / reflux precautions
Lithotomy	on back, hips and knees flexed, feet in stirrups	Pelvic exams, childbirth
Sims	left side-lying, right knee drawn up	Rectal exam, enema
Parietal / visceral	lines the wall / covers the organ	Pleura, pericardium, peritoneum
Peritoneum / perineum	abdominal lining / area between the thighs	Peritonitis vs perineal care
RUQ, LUQ	liver, gallbladder; stomach, spleen	Cholecystitis; splenic injury
RLQ, LLQ	appendix, cecum; sigmoid colon	Appendicitis; diverticulitis
Epigastric; umbilical; hypogastric	upper, middle, lower center regions	Stomach; small bowel; bladder

Worked cases

WORKED CASE 1 · DECODING A CHART LINE PART BY PART

A note on Mr. Haddad reads "anterolateral thoracotomy." Decode it.

STEP 1 · FIND THE SUFFIX

-tomy is an incision. This is an operation that cuts in.

STEP 2 · FIND THE ROOTS IN ORDER

anter/o is front, later/o is side, thorac/o is chest.

STEP 3 · CHECK THE VOWELS

The o stays between roots (rule three) and before -tomy (a consonant).

ANSWER

An incision into the chest made at the front and to the side.

WORKED CASE 2 · IPSILATERAL OR CONTRALATERAL

Ms. Brandt has a stroke in the right cerebral hemisphere and weakness of the left arm and leg. How should the weakness be described?

STEP 1 · COMPARE THE SIDES

Lesion on the right; weakness on the left. They are on opposite sides.

STEP 2 · PICK THE PREFIX

Contra- means opposite; ipsi- means same.

ANSWER

Contralateral weakness, because the motor tracts cross. Charting ipsilateral would point the next reader at the wrong hemisphere.

WORKED CASE 3 · MAPPING PAIN TO A REGION

Pain begins around the navel and moves to the right lower quadrant. Name both locations and the classic concern.

STEP 1 · DECODE THE FIRST TERM

Periumbilical: peri- (around) + umbilic/o (navel) + -al.

STEP 2 · PLACE THE SECOND

RLQ is the right lower quadrant: appendix and cecum.

ANSWER

Periumbilical pain moving to the RLQ is the **classic pattern of appendicitis**.

WORKED CASE 4 · BUILDING AND PLURALIZING

Build the term for a puncture of the chest to withdraw fluid, then give the plurals of vertebra, bronchus and phalanx.

STEP 1 · BUILD THE TERM

thorac/o (chest) + -centesis (puncture to withdraw fluid). The book contracts it to **thoracentesis**.

STEP 2 · APPLY THE PLURAL RULES

-a to -ae, -us to -i, -nx to -nges.

ANSWER

Vertebrae, bronchi, phalanges. Never add an English -s on top.

TRAPS PEOPLE FALL INTO

- **Describing from your own side.** Right and left are always the patient's, as if standing in anatomical position.
- **Mixing proximal and distal.** They compare two points on a limb: the elbow is proximal to the wrist.
- **Calling a heart enlarged on an AP film alone.** AP magnifies the heart. The standard chest film is PA.
- **Confusing coronal and sagittal.** Sagittal splits right from left; coronal splits front from back.
- **Reversing supine and prone.** You lie on your spine when supine. Prone is face down.
- **Writing peritoneum for perineum.** Peritoneum lines the abdomen. Perineum is the external area between the thighs.
- **Reading hypochondriac as a personality.** In anatomy it is a place: under the rib cartilage.
- **Mixing -tomy, -ectomy and -ostomy.** Cut in, take out, make an opening.
- **Pluralizing a plural.** Bacteria, viscera and meninges are already plural.

Chapter 4 self-test · ten items

1. Which study looks at tissue under a microscope, as with a biopsy?

A. Cytology
B. Karyology
C. Morphology
D. Histology

D. Histology Hist/o means tissue. Cytology studies cells, as in a Pap test.

2. In anatomical position, which way do the palms face?

A. Toward the thighs
B. Backward
C. Toward each other
D. Forward

D. Forward Palms face forward. That is why the thumb and radius are described as lateral.

3. Fill the blank: the wrist is ___ to the elbow.

A. Proximal
B. Medial
C. Superior
D. Distal

D. Distal Distal means farther from the trunk. The wrist is farther from the trunk than the elbow.

4. Which plane divides the body into front and back portions?

A. Sagittal
B. Coronal
C. Transverse
D. Midsagittal

B. Coronal The frontal or coronal plane divides anterior from posterior. Sagittal planes divide right from left.

5. A standard upright chest film is usually taken in which direction?

A. AP, front to back
B. Lateral, side to side
C. PA, back to front
D. Oblique, at a slant

C. PA, back to front A PA film keeps the heart close to the plate and true to size. A portable AP film magnifies it.

6. The head of the bed is raised to about 45 to 60 degrees. What is this position?

A. Trendelenburg
B. Fowler
C. Sims
D. Lithotomy

B. Fowler Fowler raises the head about 45 to 60 degrees. Trendelenburg tilts the whole bed head-down.

7. Which organ is retroperitoneal?

A. Stomach
B. Spleen
C. Kidney
D. Liver

C. Kidney Retro- means behind. The kidneys, adrenals, ureters and most of the pancreas sit behind the peritoneum.

8. Which membrane layer covers the surface of an organ?

A. Parietal
B. Peritoneal
C. Visceral
D. Mediastinal

C. Visceral Visceral covers the organ. Parietal lines the cavity wall.

9. Which abdominal region lies upper center, above the stomach?

A. Epigastric
B. Hypogastric
C. Umbilical
D. Hypochondriac

A. Epigastric Epi- (above) + gastr/o (stomach). Hypochondriac regions are the upper sides, under the rib cartilage.

10. What is the singular of viscera?

A. Viscus
B. Viscerum
C. Viscera
D. Viscerus

A. Viscus Viscera is plural. A "perforated viscus" means one hollow organ has ruptured.

Cram sheet

Everything from chapters 3 and 4 in one place. Cover the right column and see if you can rebuild each row.

Prefix rules

Rule	What it says	Example
No vowel	Prefixes attach directly	sublingual, pericarditis
Assimilation	a- to an- before a vowel or h; syn- to sym- and in- to im- before b, m, p	anemia; symphysis; impermeable
Plurals	A prefix never changes the plural	metastases, diverticula
Hyphen	peri- in a list, never in the finished word	pericardium

Word parts to know

Group	Parts and meanings
Position	endo- within; epi- upon; peri- around; sub-, infra- under; supra- above; inter- between; intra- within; retro- behind; extra-, ecto- outside; juxta- near; meso- middle
Direction	trans-, per- through; ab- away; ad- toward; dia- through; ana- up; cata- down; ipsi- same side; contra- opposite
Many senses	para- beside, abnormal, assisting; meta- beyond, after, change; in- not or into
Number	mono-, uni- one; bi-, di- two; tri- three; quadri-, tetra- four; multi-, poly- many; primi- first; nulli- none; pan- all; hemi- half; semi- partial
Quantity	hyper- above; hypo- below; olig/o- scanty; macro- large; micro- small; iso- equal; normo- normal
Time and speed	pre-, pro-, ante- before; post- after; peri- around; intra- during; neo- new; re- again; syn- together; tachy- fast; brady- slow
Negation and quality	a-, an- without; anti-, contra- against; de- removal; dys- difficult; eu- normal; mal- poor; pseudo- false; ortho- upright
Structure	cyt/o cell; hist/o tissue; kary/o nucleus; somat/o body; viscer/o organs; blast/o immature cell; chondr/o cartilage
Regions	cephal/o head; cervic/o neck; brachi/o arm; axill/o armpit; lumb/o lower back; inguin/o groin; umbilic/o navel; femor/o thigh; pod/o foot; dactyl/o digit

Key terms and comparisons

Item	The fact
Rates	Tachycardia above about 100 bpm; bradycardia below about 60 bpm (adult)
Urine scale	Polyuria; oliguria under about 400 mL/24 h; anuria
Childbirth timeline	antepartum, intrapartum, postpartum; perinatal spans all
Planes	sagittal right/left; frontal (coronal) front/back; transverse (axial) upper/lower
X-ray path	AP front to back; PA back to front; standard chest is PA
Positions	supine up; prone down; Fowler 45 to 60; semi 30 to 45; high 60 to 90; Trendelenburg head-down
Cavities	dorsal: cranial, spinal; ventral: thoracic, abdominopelvic, split by the diaphragm
Retroperitoneal	kidneys, adrenals, ureters, most of pancreas and duodenum, aorta, IVC
Quadrants	RUQ liver, gallbladder; LUQ stomach, spleen; RLQ appendix; LLQ sigmoid colon
Nine regions	hypochondriac, epigastric; lumbar, umbilical; iliac (inguinal), hypogastric

Confusable pairs

Pair	The difference
hyper- vs hypo-	above vs below normal
inter- vs intra-	between vs within
ab- vs ad-	away vs toward
ante- vs anti-	before vs against
per- vs peri-	through vs around
hemi- vs semi-	true half vs partial
ipsilateral vs contralateral	same side vs opposite side
peritoneum vs perineum	abdominal lining vs area between the thighs
cephalic vs cephalad	of the head vs toward the head

Dr. Garg Learning · CC BY-SA 4.0