MEDICAL-SURGICAL NURSING II · STUDY GUIDE

Exam 4 Study Guide

This guide covers chapters 7 and 8. You will learn to name a wound and a burn by depth, stage a pressure injury, sort leg ulcers by cause, and do the Parkland math from the time of injury, titrating to urine output. Then you will learn the plumbing of the eye and the two halves of the ear, so you can sort a painful red eye from a painless blackout and conductive from sensorineural hearing loss. Work one chapter at a time. Read the "what to know" paragraphs, study the tables, then try each worked case with the steps covered. Finish each chapter with its ten self-test items. The cram sheet at the end puts the numbers and first actions in one place.

WHAT THIS GUIDE COVERS

- Chapter 7 · skin layers and appendages, lesion vocabulary and darker skin tones, wound healing phases and documentation, cellulitis, necrotizing fasciitis, zoster, scabies, psoriasis, SJS and TEN, pressure injury staging, Braden scale, venous, arterial and neuropathic ulcers and the ABI, skin cancer, burn shock, depth and extent, inhalation injury, carbon monoxide and cyanide, Parkland resuscitation, topical agents, nutrition, grafting and contracture prevention.
- Chapter 8 · aqueous humor, visual acuity, pupils and fields, whisper, Weber and Rinne tests, open-angle and acute angle-closure glaucoma, eye drug classes and drop technique, cataract surgery, sudden vision loss, diabetic retinopathy, macular degeneration and AREDS2, the red eye, chemical splash, trauma, otitis, hearing loss and ototoxic drugs, vertigo and Meniere disease.

CHAPTER 7

Integumentary Disorders and Burns

Read it in full: **Chapter 7 in the textbook**. Practice it in the lab: **The First 24 Hours: Map It, Calculate It, Titrate It** and **Stage It, Score It, Offload It**.

What to know

The epidermis has no blood vessels; an injury limited to it cannot scar. The dermis holds vessels, nerves, glands and hair follicles, and those **appendages** carry the epithelial cells that let a partial-

thickness wound close on its own. Destroy the deep dermis and the wound needs a graft. Wound healing runs through hemostasis, inflammation (days 0 to 4, red and warm is normal), proliferation (days 4 to 21, beefy red granulation) and maturation (up to 2 years; scar reaches about 80% of original strength). Document length (head to toe) x width x depth in centimeters, with tunneling and undermining by clock position, 12 o'clock toward the head. In darker skin, erythema may look violaceous; use good light and your hands.

Cellulitis has warm, tender redness with indistinct borders; mark the edge with the date and time and elevate the limb. **Necrotizing fasciitis** has pain out of proportion to what you see, rapid spread, dusky skin, hemorrhagic bullae, crepitus and later numbness: it needs emergent surgery plus broad antibiotics with clindamycin, and imaging must not delay the operating room. **Stevens-Johnson syndrome and TEN** (under 10% versus over 30% detachment) follow drugs such as allopurinol, sulfonamides and lamotrigine, with mucosal erosions and a positive Nikolsky sign. The single most important step is to **stop the drug**, then treat it like a burn.

Pressure injury stages: **stage 1** non-blanchable redness on intact skin; **stage 2** partial thickness, shallow pink bed or blister; **stage 3** full thickness, fat may show; **stage 4** bone, tendon or muscle exposed; **unstageable** when slough or eschar hides the base (leave stable dry heel eschar alone); **deep tissue injury** is persistent maroon or purple discoloration. Never reverse-stage. The **Braden Scale** runs 6 to 23; lower is worse (18 or below at risk, 9 or below severe). Prevention: reposition, 30-degree tilt, head of bed 30 degrees or lower, float the heels, no massage, no donut cushions. Leg ulcers: venous at the medial malleolus (compress), arterial punched out on the lateral side or toes (never compress), neuropathic on the sole (offload). Check the **ABI** first: 0.91 to 1.30 normal, 0.90 or below arterial disease; full compression only above 0.8.

A large burn (above about 20 to 25% TBSA) makes capillaries leak everywhere: **burn shock**. In the emergent phase hematocrit and potassium rise and sodium falls; at 48 to 72 hours fluid returns to the vessels, the patient diureses and potassium falls. Depth: superficial (epidermis, not counted), superficial partial (moist, blisters, very painful), deep partial (mottled, waxy, slow blanching), full thickness (dry leathery eschar, insensate). Extent by the **Rule of Nines** (head 9, each arm 9, front trunk 18, back trunk 18, each leg 18, perineum 1) or the palm rule (about 1%).

Airway before fluid: hoarseness, stridor, drooling or a brassy cough mean intubate now. Pulse oximetry reads carbon monoxide as normal; send a carboxyhemoglobin and give 100% oxygen.

Parkland: 4 mL x kg x %TBSA of lactated Ringer's in 24 hours, half in the first 8 hours from the **time of injury**, half over the next 16. The ABA consensus starts at 2 mL. Then titrate to urine output 0.5 mL/kg/h in adults (75 to 100 mL/h with pigmented urine after electrical injury). Give IV opioids only, an NG tube for burns over 20%, warm the room, watch circumferential burns for escharotomy. After 48 to 72 hours the enemy is **infection** (sepsis may show as hypothermia, confusion or feeding intolerance) and **hypermetabolism** (protein 1.5 to 2 g/kg/day, early enteral feeding). The position of comfort is the position of contracture: neck slightly extended without a pillow, axillae abducted 90 to 110 degrees.

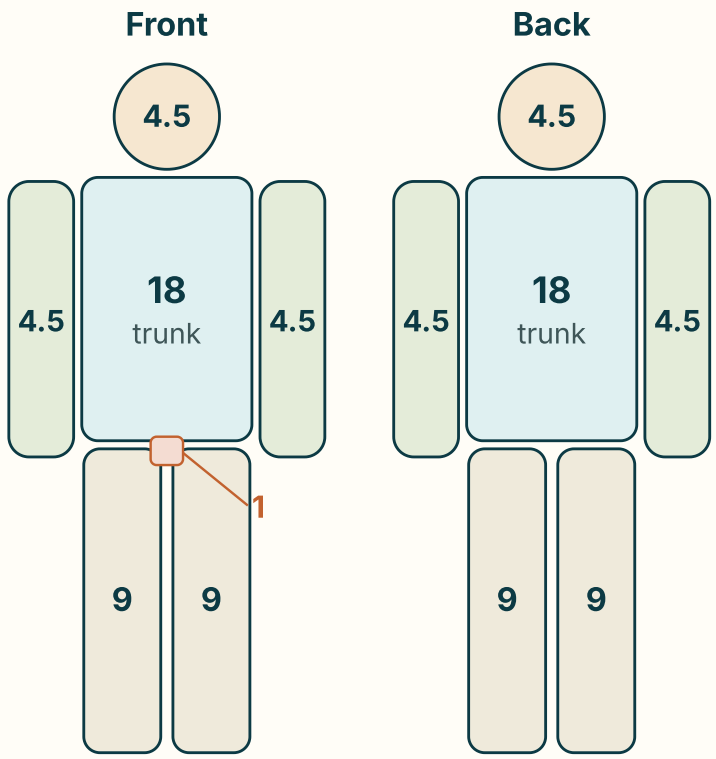

Totals
Head 9, each arm 9, trunk 18 + 18, each leg 18, perineum 1

Palm rule
Palm with fingers is about 1%

Small child
Head about 18%, each leg about 13.5%

Parkland
4 mL x kg x %TBSA lactated Ringer's; half in 8 h from injury

Count only partial and full thickness. Each region is a multiple of 9 split front and back. Sunburn (superficial) is never counted, and the Parkland clock starts at the time of injury.

LOCK THESE IN

- Necrotizing fasciitis: pain out of proportion; surgery now, imaging never delays it.
- SJS or TEN: mucosa plus positive Nikolsky; stop the drug first.
- Stage only what you can see: slough or eschar means unstageable. Never reverse-stage.
- Braden 6 to 23; 18 or below at risk; 9 or below severe. Float heels; 30-degree tilt.
- ABI before compression: full compression only above 0.8. Never compress an arterial ulcer.
- Parkland 4 mL x kg x %TBSA; half in first 8 h from injury. Titrate to 0.5 mL/kg/h urine.
- Inhalation injury: hoarseness, stridor, drooling mean intubate now. SpO2 lies with CO.
- After 72 h: infection and catabolism. Burn sepsis can show as hypothermia and tube-feed intolerance.

Key terms and comparisons: burn depth

Depth	Tissue	Looks and feels	Heals
Superficial	Epidermis	Dry, red, blanches, painful; no blisters	3 to 7 days; not counted in TBSA
Superficial partial	Epidermis and papillary dermis	Moist, blisters, brisk blanching, very painful	7 to 21 days, little scar
Deep partial	Into reticular dermis	Mottled red and waxy white, slow blanching, pressure painful	Over 21 days; usually grafted
Full thickness	Whole dermis	Dry leathery eschar, no blanching, insensate center	Needs grafting
Fourth degree	Fat, fascia, muscle, bone	Charred, deep structures exposed	Debridement, flaps, often amputation

Key terms and comparisons: leg ulcers

Feature	Venous	Arterial	Neuropathic
Where	Medial malleolus, gaiter area	Lateral malleolus, toes	Sole, metatarsal heads, heel
Looks	Shallow, irregular, ruddy, heavy exudate	Punched out, pale or dry base	Round with callused rim
Pain	Aching, better elevated	Severe, worse elevated	Absent
Skin	Brown staining, edema	Thin, shiny, hairless, cool	Dry, cracked, callused
ABI	Usually normal	0.90 or below	May be falsely high above 1.30
Core care	Compression, elevation	Revascularize; never compress	Offload, debride callus, glucose control

Worked cases

WORKED CASE 1 · PARKLAND FROM THE TIME OF INJURY

Mr. Abernethy, 80 kg, has 45% TBSA partial and full thickness flame burns from 20:00. He arrives at 22:00. Worked calculation example only.

STEP 1 · TOTAL VOLUME

4 x 80 x 45 = 14,400 mL lactated Ringer's in 24 hours.

STEP 2 · FIRST HALF

7,200 mL is due within 8 hours of the injury, by 04:00.

STEP 3 · ADJUST FOR LOST TIME

Two hours are gone, so 7,200 mL runs over the remaining 6 hours: 7,200 / 6 = 1,200 mL/h.

STEP 4 · SECOND HALF

7,200 mL over the next 16 hours (04:00 to 20:00): 7,200 / 16 = 450 mL/h.

STEP 5 · COMPARE THE ABA START

2 x 80 x 45 = 7,200 mL total; 3,600 mL in 8 hours = 450 mL/h, then 225 mL/h.

STEP 6 · TITRATE

Target urine 0.5 x 80 = 40 mL/h. Low output with tachycardia: increase. Output far above target with swelling: back off.

WORKED CASE 2 · COUNTING THE BURN

Ms. Delmar, 70 kg, has partial thickness burns of the whole right arm, the front of her trunk and the front of her right leg, plus sunburn on her face. She was burned at 09:00 and arrives at 10:30.

STEP 1 · APPLY THE RULE OF NINES

Whole arm 9 + front trunk 18 + front of one leg 9 = 36%. Sunburn is superficial and not counted.

STEP 2 · TOTAL PARKLAND VOLUME

4 x 70 x 36 = 10,080 mL in 24 hours; first half 5,040 mL by 17:00.

STEP 3 · RATE NOW

1.5 hours have passed, so 5,040 mL over 6.5 hours = about 775 mL/h. (Worked calculation example only.)

STEP 4 · TARGET URINE

0.5 x 70 = 35 mL/h.

RULE

The formula is a start. Hourly urine output decides the rate.

WORKED CASE 3 · THE AIRWAY THAT LOOKS FINE

Mr. Pruett, 34, came from a basement fire 40 minutes ago with facial burns, singed nasal hairs and black sputum. SpO2 reads 99% on a non-rebreather. In the last 10 minutes his voice has become hoarse.

STEP 1 · SEPARATE EXPOSURE FROM DANGER

Facial burns, singed hair and soot are exposure findings: they call for close watching and a carboxyhemoglobin.

STEP 2 · SPOT THE DYNAMIC SIGN

New hoarseness is a dynamic sign. Airway edema peaks at 24 to 48 hours and fluids will worsen it.

STEP 3 · ACT

Call anesthesia now for early intubation; difficult-airway cart outside the room.

STEP 4 · DO NOT TRUST THE OXIMETER

Pulse oximetry reads carboxyhemoglobin as oxygen. Continue 100% oxygen until co-oximetry returns.

TRAPS PEOPLE FALL INTO

- **Withholding analgesia because "third-degree burns do not hurt."** The center is numb, but the partial-thickness rim hurts badly.
- **Starting the Parkland clock at arrival.** The clock starts at the time of injury.
- **Putting ice on a burn.** Ice deepens the zone of stasis. Cool small burns briefly with room-temperature water only.
- **Compressing a venous-looking ulcer without an ABI.** An ABI of 0.55 means arterial disease; compression can cause necrosis.
- **Debriding dry, stable heel eschar.** Stable eschar on an ischemic heel is left alone as a natural cover.

Chapter 7 self-test · ten items

1. A cellulitic leg now has pain of 10 out of 10, dusky skin, bullae and numbness. What is the priority?

A. Switching from IV cefazolin to oral cephalexin
B. A CT scan to confirm gas before any surgery
C. Warm compresses and elevation of the leg
D. Urgent surgical debridement with broad antibiotics

D. Urgent surgical debridement with broad antibiotics This is necrotizing fasciitis. Imaging must not delay the operating room.

2. Which finding most suggests Stevens-Johnson syndrome rather than a simple drug rash?

A. Dry scaling plaques on the elbows and knees
B. Mouth and eye erosions with skin that shears off
C. Itchy hives that fade within a few hours
D. A flat red rash on the trunk without pain

B. Mouth and eye erosions with skin that shears off Mucosal involvement with a positive Nikolsky sign marks SJS or TEN. Stop the drug.

3. A sacral wound is 80% covered with yellow slough. How is it staged?

A. Unstageable until the base can be seen
B. Stage 3 because slough is visible
C. Stage 2 because it is shallow and moist
D. Stage 4 because the depth is unknown

A. Unstageable until the base can be seen If slough or eschar hides the base, the wound cannot be staged.

4. Which pressure injury prevention step is correct?

A. Using a donut cushion when the patient sits
B. Turning to a full 90-degree side-lying position
C. Floating the heels with a pillow under the calves
D. Massaging reddened skin over the sacrum

C. Floating the heels with a pillow under the calves Float the heels and use a 30-degree tilt. Never massage or use ring cushions.

5. An ulcer looks venous, but the ABI is 0.55. What should the nurse do?

A. Apply compression only during the daytime
B. Elevate the leg and apply light compression
C. Hold compression and notify for vascular review
D. Apply a multilayer compression wrap today

C. Hold compression and notify for vascular review An ABI of 0.55 shows arterial disease. Compression can cause tissue necrosis.

6. A 70 kg adult has 40% TBSA burns. What is the total Parkland volume for 24 hours?

A. 5,600 mL of lactated Ringer's
B. 22,400 mL of lactated Ringer's
C. 2,800 mL of lactated Ringer's
D. 11,200 mL of lactated Ringer's

D. 11,200 mL of lactated Ringer's 4 x 70 x 40 = 11,200 mL; half in the first 8 hours from injury.

7. During resuscitation, what is the urine output target for a 90 kg adult with thermal burns?

A. About 45 mL per hour
B. About 20 mL per hour
C. About 150 mL per hour
D. About 90 mL per hour

A. About 45 mL per hour 0.5 mL/kg/h x 90 kg = 45 mL/h.

8. A fire victim is alert with SpO2 100% on oxygen. Why might this reading mislead?

A. The probe reads poorly on burned fingers only
B. The probe reads carboxyhemoglobin as oxygenated
C. Cyanide makes the probe read too low at first
D. Oxygen therapy always raises readings falsely

B. The probe reads carboxyhemoglobin as oxygenated Pulse oximetry cannot tell carboxyhemoglobin from oxyhemoglobin. Send co-oximetry.

9. On day 6 after a large burn, a patient is confused, 35.4 C and not tolerating tube feeds. What is likely?

A. Pain reaction
B. Expected recovery
C. Fluid overload
D. Burn sepsis

D. Burn sepsis Burn sepsis often shows as hypothermia, confusion, feeding intolerance and rising glucose.

10. A patient with anterior neck burns asks for a pillow. What is the best response?

A. Explain that no pillow keeps the neck from tightening
B. Give two pillows to keep his neck well flexed forward
C. Let him choose whatever position feels best to him
D. Give one soft pillow for comfort during the night

A. Explain that no pillow keeps the neck from tightening The position of comfort is the position of contracture. Keep the neck slightly extended.

CHAPTER 8

Sensory Disorders: Eye and Ear

Read it in full: **Chapter 8 in the textbook**. Practice it in the lab: **The Angle Bench: What Slams It Shut and What Opens It** and **The Bedside Sensory Bench: Acuity, Weber and Rinne**.

What to know

The ciliary body makes **aqueous humor** all the time behind the iris; it drains in front through the trabecular meshwork. Normal pressure is about 10 to 21 mm Hg. Pressure damages the optic nerve. The retina has no collateral supply, so retinal ischemia behaves like a stroke. Check **visual acuity first** for every eye complaint (20/40 means the patient sees at 20 feet what a normal eye

sees at 40), except a chemical splash, where irrigation comes first. A relative afferent pupillary defect means optic nerve or large retinal disease on that side.

Open-angle glaucoma is a clogged filter: silent, peripheral loss over years, permanent. Adherence to drops is the main nursing job. **Acute angle-closure glaucoma** is a slammed door: sudden severe eye pain, headache, halos, nausea and vomiting, a red eye with a hazy cornea, a mid-dilated fixed pupil and a rock-hard globe. Anticholinergics (diphenhydramine, promethazine, scopolamine, ipratropium) can trigger it. Call ophthalmology now, keep the patient supine with lights on (darkness dilates the pupil), hold anticholinergics, treat pain and vomiting. Timolol drops can cause bradycardia and bronchospasm; teach **punctal occlusion** for 1 to 2 minutes.

Sudden painless vision loss: instant blackout with a pale retina and cherry-red spot is **central retinal artery occlusion** (treat as a stroke). Flashes, new floaters and a curtain are **retinal detachment** (urgent; rest, NPO, position as directed). Vision loss with temporal headache and jaw claudication over 50 is **giant cell arteritis**: steroids before biopsy. In **macular degeneration**, wavy lines on the Amsler grid mean call today; AREDS2 has no beta-carotene, which raised lung cancer risk in smokers. Diabetic eye exams: type 2 at diagnosis then yearly; type 1 within 5 years, then yearly.

A red eye with **pain, reduced acuity, photophobia or a ciliary flush** is seen the same day. Bacterial conjunctivitis has thick discharge; viral is watery and very contagious; allergic itches. Never patch an eye that may be infected or a contact lens wearer's eye. For a **chemical splash**, irrigate at once for at least 15 to 30 minutes, then check pH (target 7.0 to 7.4); alkali is worse than acid. For a suspected globe rupture: shield, do not press, do not remove an impaled object, NPO. After cataract surgery, increasing pain plus worse vision plus discharge means endophthalmitis today. One eye drop is a full dose; wait 5 minutes between drops; drops before ointment.

The ear has a mechanical half (canal, drum, ossicles: **conductive** loss) and a neural half (cochlea, nerve: **sensorineural** loss). Weber lateralizes toward a conductive ear and away from a sensorineural ear; Rinne shows bone louder than air on the conductive side. **Sudden sensorineural hearing loss** (30 dB or more in 72 hours) is an emergency: steroids work best within 72 hours. Ototoxic drugs include aminoglycosides, loop diuretics (furosemide no faster than about 4 mg/min IV), cisplatin and high-dose salicylates. Vertigo is sorted by duration:

seconds with position change is BPPV (Epley maneuver); 20 minutes to 12 hours with fluctuating hearing and fullness is **Meniere disease** (sodium 1500 to 2000 mg, diuretic); days without hearing loss is vestibular neuritis.

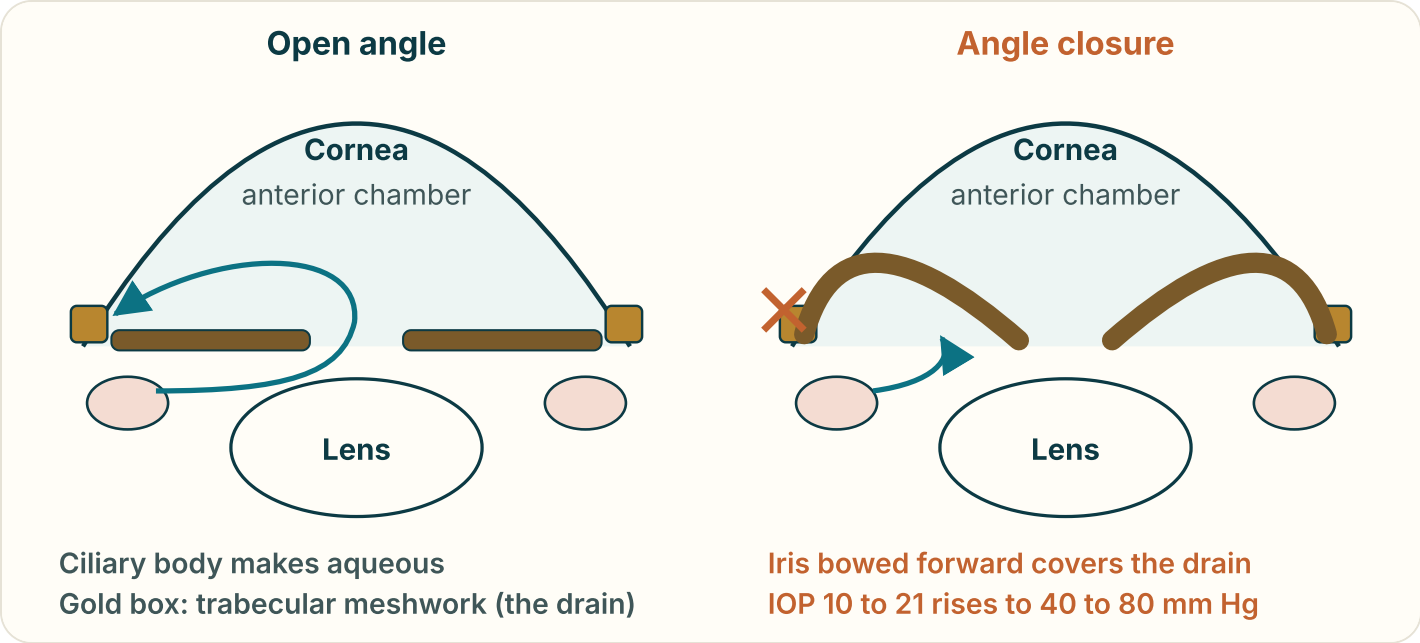

Production never stops; drainage can. In open-angle glaucoma the meshwork clogs slowly over years. In angle closure the iris slams the drain shut in hours, which is why anticholinergics and darkness are dangerous in a narrow-angle eye.

LOCK THESE IN

- Acuity is the vital sign of the eye. Chemical splash: irrigate first, then everything else.
- Angle closure: painful red eye, halos, vomiting, fixed mid-dilated pupil, hard globe. Supine, lights on, hold anticholinergics, call now.
- Punctal occlusion 1 to 2 minutes after drops; one drop is a dose; 5 minutes between drops; drops before ointment.
- Curtain = detachment; instant blackout = artery occlusion (stroke pathway); over 50 with headache = GCA, steroids first.
- Amsler grid daily for macular degeneration; AREDS2 has no beta-carotene.
- Pain plus worse vision plus discharge after eye surgery: endophthalmitis, today.
- Weber toward the bad ear = conductive; away = sensorineural. Sudden SNHL: steroids within 72 h.
- BPPV seconds; Meniere hours with hearing change; neuritis days without hearing change.

Key terms and comparisons: eye drops by mechanism

Class (example)	Mechanism	Watch and teach
Prostaglandin (latanoprost)	More uveoscleral outflow	Bedtime; iris darkening, longer lashes
Beta blocker (timolol)	Less aqueous made	Bradycardia, bronchospasm; check apical pulse; punctal occlusion
Alpha-2 agonist (brimonidine)	Less made, more outflow	Dry mouth, fatigue; not for infants or with MAOIs
Carbonic anhydrase inhibitor (dorzolamide; acetazolamide oral)	Less aqueous made	Sulfa allergy; oral form: potassium, acidosis, paresthesia
Miotic (pilocarpine)	Constricts pupil, opens angle	Brow ache, dim night vision; no night driving

Key terms and comparisons: Weber and Rinne

Test	Normal	Conductive loss, left	Sensorineural loss, left
Weber	Heard in the middle	Lateralizes to the left (bad) ear	Lateralizes to the right (good) ear
Rinne	Air louder than bone	Bone louder than air on the left	Air still louder than bone, both reduced
Causes	None	Wax, effusion, perforation, otosclerosis	Age, noise, ototoxic drugs, Meniere, schwannoma
Audiometry	0 to 25 dB	Mild 26 to 40; moderate 41 to 55	Severe 71 to 90; profound above 90

Worked cases

WORKED CASE 1 · THE VOMITING PATIENT WITH A RED EYE

Mrs. Halvorsen, 68, is on the medical floor for gastroenteritis. Four hours ago she received promethazine. She now has severe right eye pain, headache, halos and vomiting. The right eye is red, the cornea hazy, the pupil mid-dilated and nonreactive.

STEP 1 · NAME IT

Acute angle-closure glaucoma. The anticholinergic drug mid-dilated the pupil and blocked the angle.

STEP 2 · CALL

Ophthalmology now; this is a same-hour emergency, not a migraine.

STEP 3 · POSITION AND ROOM

Supine, quiet room, lights on. Darkness would dilate the pupil further.

STEP 4 · DRUGS

Hold all anticholinergics; give ordered analgesia and a non-anticholinergic antiemetic, since vomiting raises pressure. NPO for possible IV mannitol or laser.

STEP 5 · EXPECT

Pressure-lowering drops (beta blocker, alpha-2 agonist, carbonic anhydrase inhibitor), mannitol, then pilocarpine once pressure starts to fall; laser iridotomy, both eyes.

WORKED CASE 2 · DRAIN CLEANER IN THE EYES

Mr. Kovalenko splashed drain cleaner into both eyes. He is in the department with his eyes clamped shut. Ophthalmology is five minutes away.

STEP 1 · IRRIGATE NOW

Before acuity, before history: normal saline or lactated Ringer's, lids held open, contacts out, fornices swept, at least 15 to 30 minutes, inner canthus outward.

STEP 2 · CHECK PH AFTER

Litmus in the lower fornix, target 7.0 to 7.4. Keep irrigating and recheck every 20 to 30 minutes if abnormal.

STEP 3 · NEVER NEUTRALIZE

Adding acid to a base causes heat and a thermal burn.

STEP 4 · READ THE WHITE EYE

Alkali penetrates deeply. A white, quiet eye afterward may mean limbal ischemia, not healing.

WORKED CASE 3 · READING THE TUNING FORKS

Two patients. Ms. Ochoa: Weber lateralizes to the left; left Rinne shows bone louder than air. Mr. Lind, 46, woke deaf in the right ear with fullness and ringing: Weber lateralizes to the left; right Rinne shows air louder than bone.

STEP 1 · SORT MS. OCHOA

Weber toward the bad ear and reversed Rinne: left conductive loss. Look in the canal; wax is the commonest cause in older adults.

STEP 2 · SORT MR. LIND

Weber away from the bad ear and normal Rinne pattern: right sensorineural loss.

STEP 3 · SET THE URGENCY

Sudden sensorineural loss within 72 hours is an emergency. Same-day ENT and audiometry; high-dose steroids work best within 72 hours.

RULE

It cannot be wax if the pattern is sensorineural.

TRAPS PEOPLE FALL INTO

- **Dimming the lights for a patient with angle closure.** Darkness dilates the pupil and worsens the block. Leave the lights on.
- **Checking acuity before irrigating a chemical splash.** Irrigation comes first in a chemical injury.
- **Patching a contact lens wearer's painful red eye.** A patch incubates Pseudomonas. Shield, do not patch.

- **Giving a smoker an old AREDS formula with beta-carotene.** Beta-carotene raised lung cancer risk in smokers. AREDS2 removed it.
- **Telling a patient with sudden one-sided deafness to wait a week.** Steroid benefit falls after 72 hours. Same-day evaluation.

Chapter 8 self-test · ten items

1. A patient has eye pain, halos, vomiting and a fixed mid-dilated pupil after a dose of diphenhydramine. What position and room are best?

A. Prone in a dark room to rest the eye fully
B. Side-lying in a dark room with cool packs
C. Sitting up in a dim room with an eye patch
D. Supine in a quiet room with the lights left on

D. Supine in a quiet room with the lights left on Supine deepens the anterior chamber; darkness dilates the pupil and worsens angle closure.

2. Why should the nurse check the apical pulse before giving timolol eye drops?

A. Systemic absorption can cause bradycardia
B. A fast pulse means the drop was missed
C. Timolol raises the heart rate sharply
D. The drug lowers pressure only if HR is high

A. Systemic absorption can cause bradycardia Timolol is a beta blocker absorbed through the nasal mucosa; punctal occlusion reduces this.

3. A patient reports flashes, new floaters and a curtain over part of one eye. What is likely?

A. Retinal artery occlusion
B. Detachment of the retina
C. Bacterial conjunctivitis
D. Acute angle closure

B. Detachment of the retina Photopsia, floaters and an advancing curtain, painless, describe detachment.

4. A 74-year-old has vision loss, temporal headache and jaw pain with chewing. What should happen first?

A. Pilocarpine drops to open the angle
B. A temporal artery biopsy before steroids
C. High-dose steroids before the biopsy
D. An eye patch and recheck in the morning

C. High-dose steroids before the biopsy Giant cell arteritis threatens the other eye. Steroids are not delayed for biopsy.

5. A worker has alkali splashed in one eye. What is the first action?

A. Apply a pressure patch and call the doctor
B. Measure visual acuity in each eye
C. Test the pH of the tears with litmus
D. Begin irrigation right away with saline

D. Begin irrigation right away with saline Irrigation comes before any assessment in a chemical injury.

6. Three days after cataract surgery, which report needs same-day evaluation?

A. Mild itching and a scratchy, gritty feeling
B. A slightly bloodshot white of the operated eye
C. More pain, worse vision and thick discharge
D. Glare and squinting when going out in the sun

C. More pain, worse vision and thick discharge Rising pain, falling vision and discharge suggest endophthalmitis.

7. Which teaching is correct for a patient with macular degeneration?

A. Check an Amsler grid daily and call if lines bend
B. Stop eating leafy greens and fish to slow the disease
C. Expect the side vision to fail long before the center
D. Take any beta-carotene supplement every single day

A. Check an Amsler grid daily and call if lines bend Wavy lines can signal wet disease, which is treatable early with anti-VEGF.

8. Weber lateralizes to the left ear and Rinne shows bone louder than air on the left. What is this?

A. Sensorineural hearing loss in the right ear
B. Conductive hearing loss in the left ear
C. Sensorineural hearing loss in the left ear
D. Normal hearing in both of the two ears

B. Conductive hearing loss in the left ear Weber toward the bad ear plus reversed Rinne equals conductive loss.

9. A patient woke today with one-sided hearing loss and fullness. What is the best advice?

A. Book a routine hearing test sometime next month
B. Be seen today, since steroids work best within 72 hours
C. Use ear drops at home and wait about one more week
D. Try cleaning the ear canal gently with a cotton swab

B. Be seen today, since steroids work best within 72 hours Sudden sensorineural hearing loss is an emergency.

10. A patient has brief spinning when rolling over in bed, with normal hearing. What is likely?

A. A Meniere disease attack
B. Acute viral labyrinthitis
C. Acute vestibular neuritis
D. Benign positional vertigo

D. Benign positional vertigo Seconds-long positional vertigo with normal hearing is BPPV; the Epley maneuver treats it.

ONE PAGE

Cram sheet

One page of numbers, stages and first actions for both chapters. Cover the right column and say each rule out loud.

Skin, wounds and burns

Item	Rule or value
Wound note	L x W x D in cm; tunneling by clock, 12 toward the head; % granulation, slough, eschar
Necrotizing fasciitis	Pain out of proportion, bullae, numbness; surgery plus clindamycin-containing regimen
SJS / TEN	Under 10% / over 30% detachment; stop the drug; burn-unit care; eye consult
Stages	1 non-blanchable; 2 partial; 3 full, fat; 4 bone or tendon; unstageable; DTI
Braden	6 to 23; 18 or below at risk; 13 to 14 moderate; 10 to 12 high; 9 or below severe
ABI	0.91 to 1.30 normal; 0.90 or below arterial; 0.40 or below severe; above 1.30 unreliable
Rule of Nines	Head 9, arm 9, front 18, back 18, leg 18, perineum 1; palm about 1%
Parkland	4 x kg x %TBSA LR; half in 8 h from injury; ABA starts at 2 mL
Urine target	0.5 mL/kg/h adult; 1 mL/kg/h child under 30 kg; 75 to 100 mL/h with pigment
CO	SpO2 falsely normal; COHb by co-oximetry; 100% oxygen
Acute phase	Infection and hypermetabolism; protein 1.5 to 2 g/kg/day; contracture positioning

Eye and ear

Item	Rule or value
IOP	Normal 10 to 21 mm Hg; angle closure can reach 40 to 80
Acuity	Snellen 20 ft; legal blindness 20/200 or worse in the better eye
Angle closure	Supine, lights on, hold anticholinergics, drops, mannitol, then pilocarpine, laser
Sudden vision loss	CRAO: stroke path; detachment: rest, NPO; GCA: steroids first
AREDS2	Vit C 500 mg, vit E 400 IU, zinc 80 mg, copper 2 mg, lutein 10 mg, zeaxanthin 2 mg
Chemical splash	Irrigate 15 to 30 min or more; pH 7.0 to 7.4; no neutralizing
Globe rupture	Shield, no pressure, no drops, no removal, NPO, head up
Hearing	Normal 0 to 25 dB; sudden SNHL 30 dB in 72 h, steroids
Ototoxic	Aminoglycosides, loop diuretics (furosemide about 4 mg/min IV), cisplatin, salicylates
Vertigo	BPPV seconds (Epley); Meniere 20 min to 12 h (Na 1500 to 2000 mg); neuritis days

Dr. Garg Learning · CC BY-SA 4.0