HEALTH ASSESSMENT · STUDY GUIDE

Exam 6 Study Guide

This guide covers chapters 11 and 12. First you will examine the heart and vessels: where to listen, how to tell a jugular from a carotid pulse, when to use the bell, how to grade a murmur, a pulse and an edema, and which limb findings start a six hour clock. Then you will examine the abdomen in its own order, screen nutrition with numbers rather than impressions, keep feeding safe, and read elimination for the findings that mean call now. Work one chapter at a time. Read the "what to know" paragraphs, study the tables, then try each worked case with the steps covered. Finish each chapter with its ten self-test items. The cram sheet at the end puts the numbers and rules in one place.

WHAT THIS GUIDE COVERS

- Chapter 11 · flow through the heart, S1 and S2, physiologic splitting, atrial kick, the five auscultatory areas, apical pulse and pulse deficit, heart rate and blood pressure by age, pulse pressure and orthostatics, the PMI, thrills and heaves, carotids and bruits, JVP and hepatojugular reflux, S3, S4 and other extra sounds, the Levine scale and murmur patterns, pulse grading, capillary refill, ABI, Allen test, edema grading and daily weight, arterial versus venous insufficiency, the six Ps, compartment syndrome, DVT, red flags, lifespan, charting and SBAR.
- Chapter 12 · quadrants and regions, positioning and the inspect, auscultate, percuss, palpate order, the focused history and pain types, inspection signs, bowel sounds and the five minute rule, bruits, percussion and liver span, spleen, bladder and ascites, light and deep palpation and contraindications, focused maneuvers, lifespan findings, nutrition screening, BMI, weight loss, albumin, refeeding, dysphagia and aspiration precautions, feeding tube verification, Bristol scale, stool and stoma findings, urine output, bladder scanning and post-void residual, red flags, SBAR and delegation.

CHAPTER 11

Assessing the Heart and Peripheral Vascular System

Read it in full: **Chapter 11 in the textbook**. Practice it in the lab: **Name the Sound, Choose the Endpiece, Grade the Murmur** and **Arterial or Venous, and the Numbers of Perfusion**.

What to know

Blood returns through the venae cavae to the right atrium, through the tricuspid valve to the right ventricle, through the pulmonic valve to the lungs, back through the pulmonary veins to the left atrium, through the mitral valve to the left ventricle, and out the aortic valve. The left ventricle is the thickest chamber. Coronary arteries fill during diastole, so a fast rate that shortens diastole worsens ischemia.

Closing valves make the sounds. **S1** (mitral and tricuspid closing) starts systole and is loudest at the apex. **S2** (aortic and pulmonic closing) ends systole and is loudest at the base. Diastole is about two thirds of the cycle at rest. If you cannot tell S1 from S2, feel the carotid: its upstroke matches S1. S2 normally splits on inspiration at the pulmonic area. The atrial kick adds about 20 to 30% of filling; it disappears in atrial fibrillation.

Listening areas: **aortic** second ICS right sternal border; **pulmonic** second ICS left sternal border; **Erb point** third ICS left sternal border; **tricuspid** fourth to fifth ICS left sternal border; **mitral** (apex) fifth ICS left midclavicular line. "All People Enjoy Time Magazine." Count the apical pulse for a full minute when the rhythm is irregular, in infants and children, and before rate-controlling drugs such as digoxin (hold if under 60 in an adult, under 70 in a child, under 90 in an infant, or per the order). A pulse deficit is apical minus radial; the apical rate is the true rate.

The precordium is examined inspect, palpate, percuss, auscultate. The **PMI** sits at the fifth ICS at or just medial to the left midclavicular line, 1 to 2 cm, a brief early systolic tap. Displaced down and out and diffuse (over 3 cm) means a dilated ventricle; sustained and forceful in place means hypertrophy. A **thrill** is a palpable murmur and makes it at least grade IV/VI. A **heave** at the left lower sternal border suggests right ventricular hypertrophy. Cardiac percussion is now rarely done; never chart one you skipped.

Palpate one carotid at a time, low in the neck. Listen with the bell for a bruit in patients over about 50 or with vascular risk. **JVP**: head of bed 30 to 45 degrees, find the top of the internal jugular pulsation and measure vertically above the sternal angle. 3 cm or less is normal (CVP about 8 cm H_2O or less). The jugular is visible but not palpable, has two peaks, falls when the patient sits up

and is obliterated by light pressure; the carotid is palpable with one brisk stroke. A hepatojugular rise over 3 cm that persists suggests the right ventricle cannot take more volume.

Use the diaphragm firmly for high sounds and the bell lightly for low ones. Listen at all five areas with each, then roll the patient left (apex, bell) for S3, S4 and mitral stenosis, and sit them forward, exhaled (left sternal border, diaphragm) for aortic regurgitation and a friction rub. **S3** is early diastolic ("Ken-tuc-KY"); normal in children, young adults to about 35 to 40, and pregnancy, but over 40 it means heart failure until proven otherwise. **S4** is late diastolic ("TEN-nes-see"), a stiff ventricle, often benign in older adults, and impossible in atrial fibrillation. Beck triad (hypotension, JVD, muffled sounds) is tamponade.

Grade murmurs on the Levine scale as a fraction: I/VI very faint; II/VI quiet but heard at once; III/VI loud, no thrill; IV/VI with a thrill; V/VI heard with the stethoscope partly off; VI/VI heard with it lifted off. Describe timing, location, radiation, pitch, quality and what changes it. **Aortic stenosis**: harsh midsystolic crescendo-decrescendo at the second right ICS to the carotids. **Mitral regurgitation**: holosystolic blowing at the apex to the axilla. **Aortic regurgitation**: soft early diastolic at the third to fourth left ICS, sitting forward. **Mitral stenosis**: low diastolic rumble at the apex with the bell. A diastolic murmur is never innocent.

Pulses: 0 absent (confirm and chart Doppler separately), 1+ weak, 2+ normal, 3+ full, 4+ bounding; state the scale. The dorsalis pedis is absent in about 2 to 10% of healthy people; both pedal pulses absent is abnormal. Capillary refill is under 2 seconds. **ABI** = ankle systolic ÷ the higher brachial systolic: 1.00 to 1.40 normal, 0.91 to 0.99 borderline, 0.90 or less PAD, under 0.40 severe, over 1.40 non-compressible (calcified). A modified Allen test is abnormal if color takes more than 15 seconds to return.

Edema: 1+ about 2 mm, immediate rebound; 2+ about 4 mm, 10 to 15 seconds; 3+ about 6 mm, over a minute; 4+ about 8 mm, 2 to 5 minutes. Chart depth, level and side. Measure calves 10 cm below the tibial tuberosity; a difference over 3 cm counts in DVT scoring. A gain of 1 kg (2 lb) in 24 hours or 2.3 kg (5 lb) in a week is reportable in heart failure. **Arterial** disease: claudication, cool, pale on elevation, dependent rubor, hairless shiny skin, weak pulses, painful punched-out ulcers on toes, heels or lateral malleolus; never elevate or compress without an ABI. **Venous** disease: warm, edematous, brown staining, ulcers at the medial malleolus; elevate and compress.

The **six Ps** of acute arterial occlusion: pain, pallor, pulselessness, paresthesia, paralysis, poikilothermia. About six hours to save the limb: do not elevate, heat, cool or massage it; keep it at or slightly below heart level and call now. Compartment syndrome shows pain out of proportion and pain on passive stretch long before pulses vanish. For suspected DVT, do not do the Homans sign; measure, escalate and watch for pulmonary embolism. Other red flags: chest pain or atypical symptoms (women, older adults, diabetes), new irregular rhythm, HR under 50 with symptoms or over 150, new S3 with weight gain, BP 180/120 with symptoms, 140/90 after 20 weeks of pregnancy. A beta blocker can hide tachycardia in shock.

LOCK THESE IN

- S1 at the apex starts systole; S2 at the base ends it.
- Aortic 2R, pulmonic 2L, Erb 3L, tricuspid 4 to 5L, mitral 5th ICS MCL.
- PMI 1 to 2 cm at the 5th ICS MCL; down, out and diffuse means dilation.
- JVP over 3 cm above the sternal angle at 30 to 45 degrees is elevated.
- S3 after S2 (over 40 means heart failure); S4 before S1, never in AF.
- A thrill means at least IV/VI; a diastolic murmur is never innocent.
- ABI 0.90 or less is PAD; over 1.40 is a falsely high calcified reading.
- Six Ps: do not elevate, call now. Venous: elevate and compress.

Where the sounds fall in one cardiac cycle (heart rate 75)

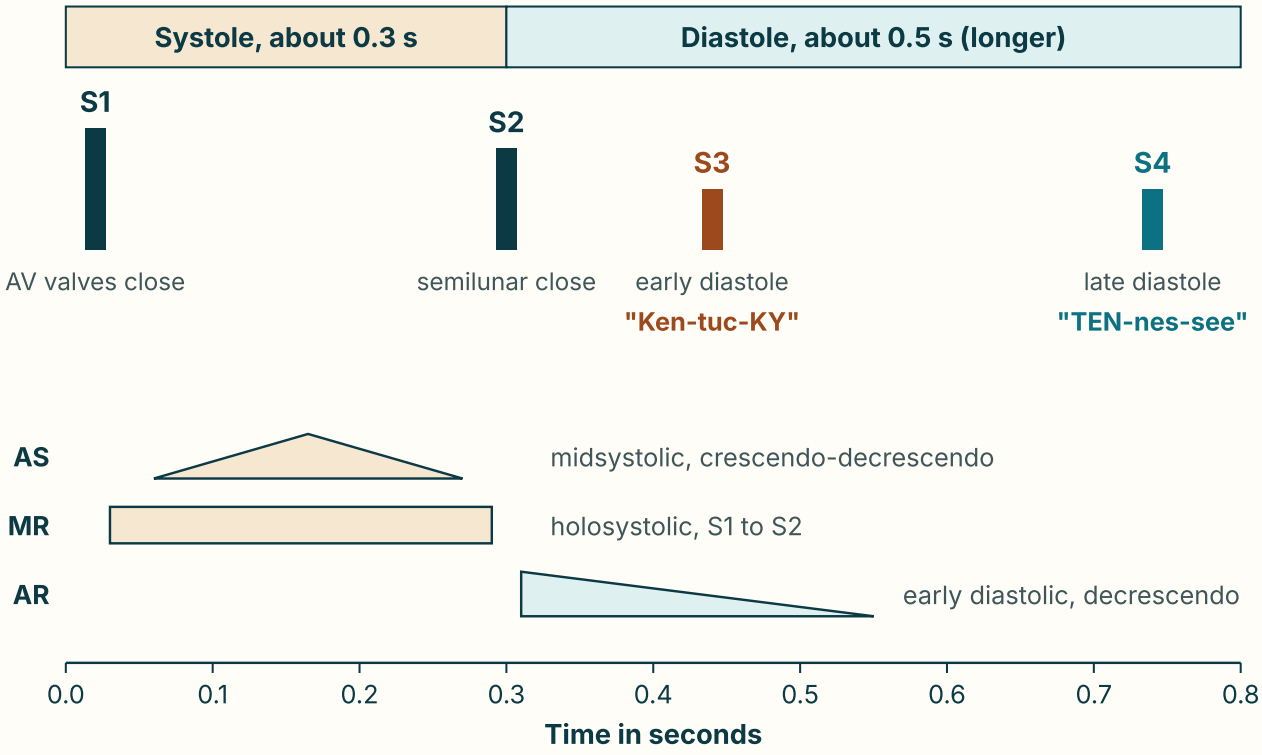

S3: after S2
Bell, apex, left side lying. Normal in children, young adults, pregnancy; over 40 think heart failure.

S4: before S1
Bell, apex. Stiff ventricle. Cannot occur in atrial fibrillation (no atrial kick).

Timing places every extra sound. Diastole is the longer phase. S3 follows S2 and S4 comes just before S1; murmurs are named by where they sit between S1 and S2 or after S2. Times are drawn to scale for a rate of 75.

Murmurs and extra sounds

Finding	Timing and quality	Where and how
Aortic stenosis	Midsystolic, crescendo-decrescendo, harsh	2nd right ICS, to the carotids; slow carotid upstroke
Mitral regurgitation	Holosystolic, blowing, high	Apex, to the left axilla
Tricuspid regurgitation	Holosystolic, blowing	Left lower sternal border; louder on inspiration
Mitral valve prolapse	Midsystolic click, late systolic murmur	Apex
Aortic regurgitation	Early diastolic, decrescendo, soft	3rd to 4th left ICS; sitting forward, exhaled
Mitral stenosis	Mid to late diastolic rumble after an opening snap	Apex, bell, left lateral
S3	Early diastole, after S2	Bell, apex, left lateral
S4	Late diastole, before S1	Bell, apex, left lateral
Pericardial rub	Scratchy, up to three parts; persists with breath held	Left lower sternal border, sitting forward
Innocent murmur	Early to midsystolic, soft, I to II/VI, changes with position	No thrill, normal S1 and S2, no symptoms

Arterial versus venous insufficiency

Feature	Arterial	Venous
Pain	Claudication; rest pain worse elevated	Aching, heavy; better elevated
Pulses	Weak or absent	Present
Temperature	Cool	Warm
Color	Pale on elevation, dependent rubor	Brown hemosiderin staining
Skin	Thin, shiny, hairless; thick nails	Thickened, may weep
Edema	Minimal	Often marked
Ulcer	Toes, heels, lateral malleolus; punched out; very painful	Medial malleolus; irregular; mildly painful
Key action	Never elevate or compress without an ABI and order	Elevate; compress once arterial disease is excluded

Worked cases

WORKED CASE 1 · COMPUTING AN ANKLE-BRACHIAL INDEX

Mr. Hale's brachial systolic pressures are 120 (right) and 128 (left). His right ankle systolic pressure is 72.

STEP 1 · PICK THE BRACHIAL VALUE

Use the higher of the two arms: 128.

STEP 2 · DIVIDE

72 ÷ 128 = 0.5625, about 0.56.

STEP 3 · INTERPRET

0.90 or less is peripheral arterial disease. 0.56 is not yet below 0.40, the severe band.

STEP 4 · APPLY IT

Do not elevate this leg or apply compression without an order, and report the result.

WORKED CASE 2 · READING A PULSE DEFICIT AND A DIGOXIN HOLD

Before digoxin, you and a second nurse count Mrs. Lin together for one minute: apical 58, radial 50. She is 70.

STEP 1 · FIND THE DEFICIT

58 − 50 = 8.

STEP 2 · KNOW THE TRUE RATE

The apical count, 58, is the heart rate.

STEP 3 · CHECK THE PARAMETER

For an adult, hold digoxin and notify if the apical rate is under 60, unless the order says otherwise.

STEP 4 · ACT

Hold the dose, notify the provider and chart all three numbers.

WORKED CASE 3 · A NEW S3 IN HEART FAILURE

Mr. Whitfield, 71, has a heart failure exacerbation. Weight 84.2 kg today, 82.8 kg on admission and up 1.4 kg since yesterday. New S3 at the apex, JVP 5 cm, crackles at both bases, three pillows last night, urine 20 mL/hour for four hours.

STEP 1 · CONFIRM THE SOUND

Bell, light pressure, apex, left lateral: an early diastolic sound after S2.

STEP 2 · READ THE NUMBERS

1.4 kg in 24 hours exceeds 1 kg. JVP 5 cm exceeds 3 cm. Urine 20 mL/hour is under 30.

STEP 3 · INTERPRET

Over age 40, a new S3 with these findings is decompensating heart failure.

STEP 4 · SBAR

End with the ask: extra diuretic, BMP and BNP, chest x-ray, oxygen order, strict I&O, come to the bedside.

WORKED CASE 4 · A COLD FOOT

At 2120 Ms. Ortiz reports sudden severe right foot pain, 9/10, and numb toes. The right foot is pale and cool to mid-calf; no pulses by palpation or Doppler; refill over 5 seconds. The left foot is normal.

STEP 1 · NAME IT

Pain, pallor, pulselessness, paresthesia, and a cold limb: acute arterial occlusion.

STEP 2 · START THE CLOCK

About six hours to save the limb.

STEP 3 · DO AND DO NOT

Keep the foot level, no heat, no cold, no massage, no elevation; mark the pulse sites; keep her NPO pending orders.

STEP 4 · ESCALATE

Rapid response and vascular surgery now, then chart the time and every finding.

TRAPS PEOPLE FALL INTO

- **Pressing the bell firmly.** Firm pressure turns it into a diaphragm and erases S3 and S4.
- **Skipping the left lateral and sitting forward positions.** That is how S3, mitral stenosis and aortic regurgitation are missed.
- **Palpating both carotids together.** It can drop cerebral perfusion and trigger bradycardia.
- **Calling an S4 in atrial fibrillation.** With no organized atrial contraction there is no S4.
- **Writing "grade 2 murmur."** Write II/VI so the scale is clear.
- **Elevating a cold, pulseless leg.** Elevation removes what little perfusion the foot had.
- **Doing a Homans sign.** It is unreliable; measure and escalate instead.
- **Trusting a normal heart rate on a beta blocker.** The drug can mask the tachycardia of shock.

Chapter 11 self-test · ten items

1. Where is the mitral (apical) area?

A. 2nd ICS, right sternal border

B. 5th ICS, left midclavicular line

C. 3rd ICS, left sternal border

D. 4th ICS, left sternal border

B. 5th ICS, left midclavicular line The apex sits at the fifth intercostal space at the left midclavicular line.

2. The PMI is found at the 6th ICS, anterior axillary line, spanning two interspaces. What does this suggest?

A. A normal apical impulse
B. Right ventricular hypertrophy
C. A normal finding in emphysema
D. Left ventricular dilation

D. Left ventricular dilation Displacement down and out with a diffuse impulse points to a dilated left ventricle, as in heart failure.

3. A neck pulsation has two soft peaks, falls when the patient sits up, and cannot be felt. What is it?

A. The carotid artery
B. The thyroid gland
C. The internal jugular
D. The subclavian artery

C. The internal jugular Jugular pulsations are visible, not palpable, biphasic and change with position.

4. A 68 year old with heart failure has a new low sound just after S2 at the apex. What is it?

A. An S3 gallop
B. An S4 gallop
C. A split S1
D. An opening snap

A. An S3 gallop An early diastolic sound after S2 is an S3. Over age 40 it suggests a volume overloaded ventricle.

5. Why can a patient in atrial fibrillation not have an S4?

A. There is no organized atrial contraction
B. The ventricles are too stiff to fill at all
C. The mitral valve stays open all the time
D. The heart rate is too slow to hear it

A. There is no organized atrial contraction S4 comes from the atrium contracting against a stiff ventricle. In AF the atria quiver instead.

6. A murmur is loud and the nurse can feel a vibration over the same spot. What is the lowest possible grade?

A. II/VI
B. III/VI
C. IV/VI
D. V/VI

C. IV/VI A palpable thrill means at least grade IV/VI.

7. Which murmur is never innocent and always needs evaluation?

A. A soft systolic murmur in a child
B. A systolic murmur in pregnancy
C. A systolic murmur with fever
D. Any murmur heard in diastole

D. Any murmur heard in diastole Many systolic murmurs are physiologic, but diastolic murmurs always need evaluation.

8. A patient's ankle systolic is 90 and the higher brachial systolic is 150. How is the ABI read?

A. 0.60, normal for adults
B. 0.60, arterial disease
C. 1.67, normal leg flow
D. 0.60, a calcified value

B. 0.60, arterial disease 90 ÷ 150 = 0.60, which is 0.90 or less, so PAD is present.

9. A leg is warm and swollen with brown staining and an ulcer at the medial malleolus. Pulses are present. What is the key action?

A. Keep the leg flat, below the heart, no compression
B. Elevate the leg and use compression if ordered
C. Apply heat to the ulcer to speed healing
D. Massage the calf to move the fluid upward

B. Elevate the leg and use compression if ordered These are venous findings. Elevation and compression help venous disease once arterial disease is excluded.

10. A post-op patient with a new cast reports pain far worse than expected that rises when the toes are moved. The pulses are present. What is most likely?

A. Compartment syndrome
B. Normal surgical pain
C. Deep vein thrombosis
D. Venous insufficiency

A. Compartment syndrome Pain out of proportion and pain on passive stretch are early signs; pulses persist until late.

Assessing the Abdomen, Nutrition and Elimination

Read it in full: **Chapter 12 in the textbook**. Practice it in the lab: **Inspection and Auscultation of the Abdomen** and **Nutrition Screening and Feeding Safety**.

What to know

Map findings to quadrants. RUQ: liver, gallbladder, duodenum, head of pancreas, right kidney. LUQ: stomach, spleen, body and tail of pancreas, left kidney. RLQ: cecum, appendix, right ovary and tube, right ureter. LLQ: sigmoid and descending colon, left ovary and tube, left ureter. Midline: aorta, bladder, uterus. Pain refers: gallbladder to the right scapula, spleen to the left shoulder (Kehr), pancreas to the back, ureter to the groin. The adult aorta should be under 3 cm and pulsate forward, not sideways.

Have the patient void first, lie supine with a pillow under the knees and the arms at the sides (not behind the head). Warm your hands. Examine in this order: **inspect, auscultate, percuss, palpate**. Pressing first changes bowel motility, so listening moves up to second. Examine the painful quadrant last, and save any rebound test for the very end. Ask the patient to point with one finger, and watch the face.

The focused history: OLDCARTS plus appetite, nausea and vomiting, last oral intake, last bowel movement and its form, flatus, urinary symptoms, weight change, alcohol, NSAIDs, anticoagulants, prior surgery, and the last menstrual period and pregnancy possibility. **Visceral** pain is crampy, poorly localized and makes the patient restless. **Parietal** pain is sharp, localized, worse with movement, and the patient lies still. Pain out of proportion to a soft abdomen in a patient with atrial fibrillation suggests mesenteric ischemia.

Inspect from the side at abdomen level for contour (flat, rounded, scaphoid, protuberant), symmetry, scars (risk for adhesive obstruction), striae (purple and wide suggests hypercortisolism), caput medusae, and Cullen (periumbilical) or Grey Turner (flank) bruising, which signals retroperitoneal bleeding. In deeply pigmented skin these look darker or duller rather than blue; compare sides and palpate. Visible peristaltic waves suggest obstruction. A wide, expansile, side to side epigastric pulsation is a suspected aneurysm: stop, no deep palpation, escalate.

Auscultate with the warm diaphragm starting in the RLQ, then clockwise, 15 to 30 seconds per quadrant. Normal is about 5 to 30 irregular gurgles a minute. Listen a full **5 minutes** in one spot before charting "absent." Hypoactive sounds follow surgery, opioids, immobility and hypokalemia, but also ileus and peritonitis. Hyperactive sounds come with diarrhea, laxatives, GI bleeding and early obstruction. Loud, high, tinkling sounds that later go silent in a distended, vomiting patient mean obstruction getting worse. Then use the bell for bruits over the aorta, renal, iliac and femoral arteries.

Percussion: tympany is the main note; dullness over liver, full bladder, stool or a mass. **Liver span** at the right midclavicular line is 6 to 12 cm (4 to 8 cm midsternal); over 12 cm is hepatomegaly. A bladder of about 300 mL or more becomes percussible; confirm with a scanner. Ascites: shifting dullness or a fluid wave; the exam finds about 1,500 mL, ultrasound about 100 mL, so measure girth at a marked spot.

Palpate light (1 to 2 cm) in all quadrants, then deep (4 to 6 cm). Describe any mass by location, size, shape, consistency, mobility and tenderness. **No deep palpation** over a pulsatile mass, a suspected tumor in a child, a transplanted or polycystic kidney, a fresh surgical site, or a rigid abdomen. **Voluntary** guarding relaxes with distraction and exhalation; **involuntary** rigidity does not and means peritonitis. Signs: Murphy (cholecystitis), McBurney point, Rovsing, psoas and obturator (appendicitis), CVA tenderness (pyelonephritis, stones). Prefer a cough or heel jar over rebound testing.

Lifespan: infants and toddlers have a round, protuberant abdomen, a liver edge 1 to 2 cm below the costal margin and often a reducible umbilical hernia that closes by about 2. In pregnancy, fundal height in cm approximates weeks from about 20 to 36, bowel sounds are diminished, and third trimester appendicitis may hurt in the RUQ; use a wedge under the right hip after about 20 weeks. Older adults may have peritonitis with no rigidity or rebound; confusion, poor appetite or a fall may be the only sign.

Screen nutrition within 24 hours (MST, MUST, MNA-SF). Weight change % = (usual − current) ÷ usual × 100; significant is over 5% in 1 month, over 7.5% in 3 months, over 10% in 6 months. BMI 18.5 to 24.9 is the reference; over 65, 23 to 30 is often healthier. Protein 0.8 g/kg/day (1.2 to 2.0 with wounds, sepsis, burns); fluid about 30 mL/kg/day. **Albumin and prealbumin are**

inflammation markers, not nutrition markers. Refeeding syndrome drops phosphate, potassium and magnesium within 12 to 72 hours; check them daily. Ask about diet practices and food insecurity.

Keep a patient NPO until a swallow screen is passed after stroke, a new deficit, extubation or choking; silent aspiration shows no signs. Aspiration precautions: upright at 90 degrees for meals, head of bed 30 to 45 degrees for 30 to 60 minutes after, small bites, no straws unless approved, oral care twice a day. A blind-placed feeding tube is confirmed by x-ray before use; then check external length and aspirate pH (5.0 or less supports gastric) every 4 hours and before feeds. Never use the air bolus method. Flush 30 mL before and after meds and every 4 hours. Elimination: Bristol 1 to 2 constipation, 3 to 4 ideal, 6 to 7 diarrhea; melena is an escalation; urine output at least 0.5 mL/kg/hour; post-void residual under 50 mL normal, over 100 repeated incomplete; scan before you catheterize; a dusky stoma is ischemic.

LOCK THESE IN

- Abdomen: inspect, auscultate, percuss, palpate; painful quadrant last.
- Start listening in the RLQ; 5 full minutes before "absent."
- Liver span 6 to 12 cm at the right MCL.
- No deep palpation over a pulsatile mass, a child's tumor or a rigid abdomen.
- Weight loss over 5% in 1 month, 7.5% in 3, 10% in 6 is significant.
- Albumin and prealbumin track inflammation, not nutrition.
- Feeding tube: x-ray first; never the air bolus test; pH 5.0 or less supports gastric.
- Urine at least 0.5 mL/kg/hour; PVR under 50 mL normal; scan before catheterizing.

The abdomen: four quadrants, and the order you examine them

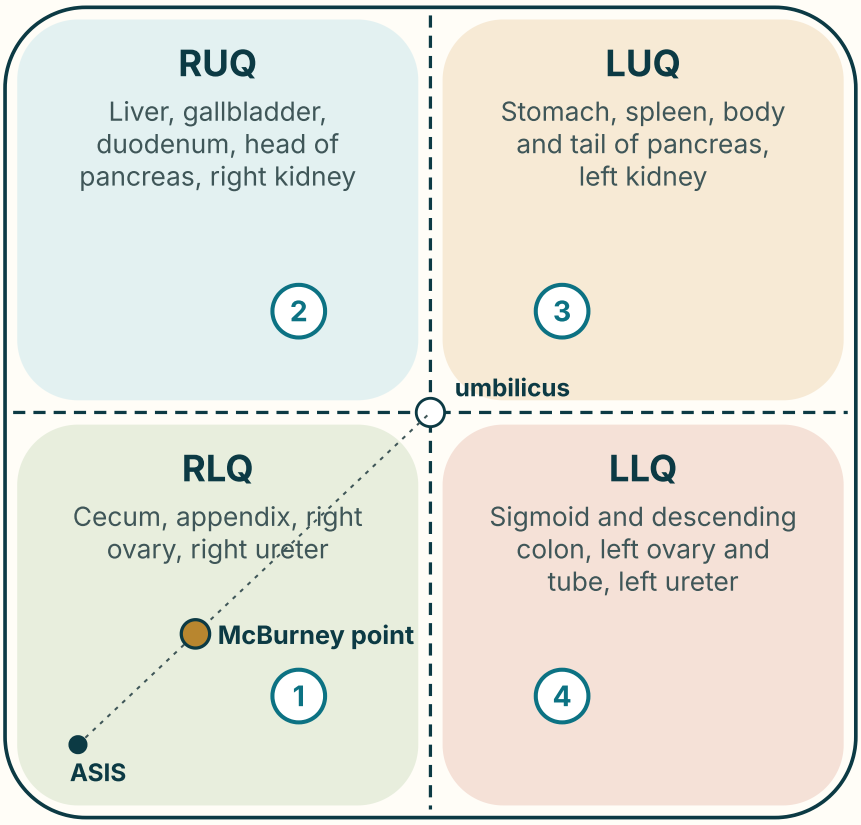

Patient's right is on the image left. Numbered circles: auscultation route.

Abdomen only

1. Inspect
contour, skin, movement

2. Auscultate
start RLQ, then clockwise; 5 min before "absent"

3. Percuss
tympany; liver span 6 to 12 cm

4. Palpate
light 1 to 2 cm, then deep; tender area last

Pressing first changes the bowel sounds, so listening moves up to second.

Listen before you touch. The abdomen is the one region examined inspect, auscultate, percuss, palpate. Start listening in the right lower quadrant and move clockwise, and map every finding to a quadrant.

Abdominal signs and maneuvers

Sign	How	Positive suggests
Murphy	Fingers under right costal margin, deep breath	Inspiration stops from pain: cholecystitis
McBurney point	One third from right ASIS to umbilicus	Localized tenderness: appendicitis
Rovsing	Press deep in the LLQ	Pain in the RLQ: appendicitis
Psoas	Extend right hip, or raise right leg against resistance	RLQ pain: retrocecal appendicitis
Obturator	Flex right hip and knee 90 degrees, rotate internally	RLQ or hypogastric pain: pelvic appendicitis
CVA tenderness	Fist strike over the costovertebral angle	Sharp flank pain: pyelonephritis, stone
Shifting dullness	Percuss flanks supine, then on the side	Dullness shifts: ascites
Castell sign	Percuss lowest left interspace, AAL, deep breath	Turns dull on inspiration: splenomegaly
Cullen / Grey Turner	Periumbilical / flank discoloration	Retroperitoneal or intraperitoneal bleeding

Elimination numbers

Measure	Expected	Abnormal
Adult urine output	At least 0.5 mL/kg/hour (about 30 mL/hour)	Oliguria under 400 mL/day; anuria under 100 mL/day
Children / infants	About 1 / about 2 mL/kg/hour	Below these
Daily adult output	About 1,200 to 1,500 mL	Falling output: hypoperfusion
Bladder capacity	400 to 600 mL; first urge 150 to 300 mL	Percussible at about 300 mL
Post-void residual	Under 50 mL	Over 100 repeated; over 300 to 400 mL retention
Bristol scale	Types 3 to 4	1 to 2 constipation; 6 to 7 diarrhea
Ileostomy output	500 to 1,000 mL/day once adapted	Over about 1,200 mL/day: report
Pouch emptying	At one third to one half full	No output 24 to 48 h after surgery beyond that: report

Worked cases

WORKED CASE 1 · PERCENTAGE WEIGHT LOSS

Mr. Vega usually weighs 70 kg. Today he weighs 64 kg, and the loss happened over three months without trying.

STEP 1 · SUBTRACT

70 − 64 = 6 kg.

STEP 2 · DIVIDE AND MULTIPLY

6 ÷ 70 × 100 = 8.6%.

STEP 3 · COMPARE

More than 7.5% in three months is significant.

STEP 4 · ACT

Refer to the dietitian, chart intake as percentages of each meal, and do not rely on albumin to judge it.

WORKED CASE 2 · HOURLY URINE OUTPUT

Mrs. Bell weighs 80 kg. Over the last 4 hours she made 96 mL of urine.

STEP 1 · FIND HER MINIMUM

0.5 mL/kg/hour × 80 kg = 40 mL/hour.

STEP 2 · FIND HER ACTUAL RATE

96 ÷ 4 = 24 mL/hour.

STEP 3 · COMPARE

24 is below 40, and below the 30 mL/hour bedside floor.

STEP 4 · ACT

Assess volume status and bladder (scan), then report: falling output is an early sign of hypoperfusion.

WORKED CASE 3 · MEASURING LIVER SPAN

At the right midclavicular line, the upper border of dullness is at the 6th ICS and the lower border is 10.5 cm below it, at the costal margin.

STEP 1 · READ THE SPAN

The distance between the marks is 10.5 cm.

STEP 2 · COMPARE

6 to 12 cm is expected; 10.5 cm is normal.

STEP 3 · WATCH THE TRAPS

A right pleural effusion can falsely raise the upper border; COPD can push a normal liver down so its edge is palpable.

WORKED CASE 4 · PERITONITIS AFTER SURGERY

Mr. Okafor, day 2 after colectomy: rigid abdomen, involuntary guarding, no bowel sounds after 5 minutes, one coffee-ground emesis, 20 mL urine in 2 hours, T 38.6 °C, HR 122, BP 92/68 (was 138/78), RR 26.

STEP 1 · RECOGNIZE IT

Board-like abdomen, involuntary guarding and silence: peritonitis until proven otherwise.

STEP 2 · READ THE PATTERN

Rising heart rate, falling pressure and output: shock is developing.

STEP 3 · SBAR

Situation and concern, background, the numbers, then the ask: come now, NPO, NG tube to low intermittent suction, lactate, CBC, BMP and a saline bolus.

STEP 4 · CLOSE THE LOOP

Read back orders and use the chain of command if no one comes.

TRAPS PEOPLE FALL INTO

- **Palpating before listening.** You would chart sounds your hands made.
- **Charting "absent" after 10 seconds.** Listen a full 5 minutes in one spot.
- **Putting the patient's arms behind the head.** It tightens the rectus and mimics guarding.
- **Reading silence after loud bowel sounds as better.** In obstruction, silence means the bowel is fatiguing.
- **Using albumin to judge nutrition.** It falls with inflammation regardless of intake.
- **Checking feeding tube placement with an air bolus.** It is unreliable; use x-ray first, then length and pH.
- **Catheterizing before scanning.** Scan first and try noninvasive measures.
- **Using alcohol rub after C. difficile.** Wash with soap and water; alcohol does not kill spores.

Chapter 12 self-test · ten items

1. A nurse is about to assess a new patient's abdomen. What comes right after inspection?

A. Light palpation

B. Percussion

C. Auscultation

D. Deep palpation

C. Auscultation In the abdomen, auscultation moves to second so that touch does not change the bowel sounds.

2. A nurse hears no bowel sounds in the LLQ after 15 seconds. What should the nurse do?

A. Chart bowel sounds as absent in the LLQ
B. Palpate the LLQ to stimulate the bowel
C. Move to the next quadrant and come back
D. Keep listening there for 5 full minutes

D. Keep listening there for 5 full minutes Absent bowel sounds may only be charted after 5 continuous minutes in one spot.

3. A 72 year old has a wide, side to side pulsating mass in the epigastrium. What should the nurse do?

A. Palpate deeply to measure its full width
B. Percuss over it to judge its size
C. Ask the patient to bear down and recheck
D. Stop, avoid deep palpation and escalate

D. Stop, avoid deep palpation and escalate This suggests an aortic aneurysm. Deep palpation risks rupture.

4. During palpation, the patient stops inhaling suddenly when fingers press under the right costal margin. What is this?

A. A positive Murphy sign
B. A positive Rovsing sign
C. A positive psoas sign
D. A positive Castell sign

A. A positive Murphy sign Murphy sign suggests acute cholecystitis.

5. Which finding suggests involuntary guarding?

A. Tension that relaxes as the patient exhales
B. Rigidity that does not ease with distraction
C. Tightness that eases with warm hands
D. Tensing that stops when the patient chats

B. Rigidity that does not ease with distraction Involuntary rigidity is constant and signals peritoneal inflammation.

6. A patient's usual weight is 90 kg and it is now 81 kg after 6 months of illness. How is this read?

A. A 9% loss: not yet significant
B. An 11% loss: significant in 1 month
C. A 10% loss: significant in 6 months
D. A 10% loss: expected with illness

C. A 10% loss: significant in 6 months (90 − 81) ÷ 90 × 100 = 10%, which meets the 6 month threshold for significance.

7. A septic patient has an albumin of 2.6 g/dL. What does this value mainly reflect?

A. Poor protein intake over the past week
B. Recent intake of too much fluid by mouth
C. An exact measure of muscle protein stores
D. Inflammation and severity of illness

D. Inflammation and severity of illness Albumin is a negative acute phase reactant and falls with inflammation regardless of intake.

8. How should the nurse confirm placement of a newly inserted, blindly placed feeding tube?

A. Listening over the stomach while injecting air
B. An abdominal x-ray before anything is given
C. Checking that the patient can still speak clearly
D. Observing for coughing during a small water flush

B. An abdominal x-ray before anything is given X-ray confirms initial placement. The air bolus method is unreliable and must not be used.

9. A 70 kg adult made 100 mL of urine in the last 4 hours. How should the nurse read this?

A. Normal, since some urine is being made
B. Above the minimum of 25 mL/hour for 70 kg
C. Too low: 25 mL/hour against a 35 minimum
D. Normal, since 100 mL is well over 30 mL

C. Too low: 25 mL/hour against a 35 minimum 0.5 × 70 = 35 mL/hour; 100 ÷ 4 = 25 mL/hour, which is too low.

10. An ileostomy stoma that was beefy red yesterday is now dusky purple. What is the priority?

A. Report it now; the stoma is ischemic
B. Apply a tighter pouch to protect it
C. Recheck it at the next pouch change
D. Clean it and document a normal finding

A. Report it now; the stoma is ischemic A pale, dusky, purple or black stoma is ischemic and must be reported immediately.

ONE PAGE

Cram sheet

Everything from chapters 11 and 12 in one place. Cover the right column and see if you can rebuild each row.

Numbers to know

Item	Value	Note
Listening areas	2R aortic, 2L pulmonic, 3L Erb, 4 to 5L tricuspid, 5th ICS MCL mitral	Base to apex
Digoxin hold	Apical under 60 adult, 70 child, 90 infant	Or per the written parameters
PMI	5th ICS at or medial to left MCL, 1 to 2 cm	Over 3 cm: dilation
JVP	3 cm or less above the sternal angle at 30 to 45 degrees	CVP about 8 cm H_2O or less
Pulse pressure	30 to 40, up to about 50	Narrow: low stroke volume
ABI	1.00 to 1.40 normal; 0.91 to 0.99 borderline	0.90 or less PAD; under 0.40 severe; over 1.40 calcified
Capillary refill	Under 2 s	Up to 3 s in neonates or a cold room
Allen test	Color back in 5 to 7 s	Over 15 s: do not use that radial
Calf difference	Over 3 cm	Measured 10 cm below the tibial tuberosity
HF weight gain	1 kg in 24 h or 2.3 kg in a week	1 kg is about 1 L
Bowel sounds	5 to 30 per minute	5 min before "absent"
Liver span	6 to 12 cm right MCL; 4 to 8 cm midsternal	Over 12 cm hepatomegaly
Palpation	Light 1 to 2 cm; deep 4 to 6 cm	Tender area last
Weight loss	Over 5% / 1 mo; 7.5% / 3 mo; 10% / 6 mo	Dietitian referral
Needs	Protein 0.8 g/kg (1.2 to 2.0 if stressed); fluid about 30 mL/kg	Fiber 25 g women, 38 g men
Urine and PVR	At least 0.5 mL/kg/h; PVR under 50 mL	Over 100 repeated; over 300 to 400 retention

Formulas

Name	Formula	Use
Pulse deficit	Apical − radial, counted together	Apical is the true rate
ABI	Ankle systolic ÷ higher brachial systolic	PAD screen
Weight change %	(usual − current) ÷ usual × 100	Malnutrition screen
Minimum urine output	0.5 mL × kg × hours	Hypoperfusion check
BMI	kg ÷ m^2	Screen, not diagnosis

Rules that are not numbers

Topic	The rule
Heart sounds	Diaphragm firm for high sounds; bell light for S3, S4, MS; left lateral and sitting forward every time.
Neck	If you can feel it, it is the carotid; one carotid at a time.
Limbs	Cold, pale, pulseless: do not elevate, call now. Warm, swollen, brown: elevate and compress.
Abdomen	Inspect, auscultate, percuss, palpate; no deep palpation over a pulsatile mass or rigid belly.
Feeding	NPO until the swallow screen; x-ray before first use; never the air bolus.
Delegation	UAP may record I&O, weigh, empty an established pouch; the RN assesses, screens swallowing, places and verifies tubes, teaches.

Dr. Garg Learning · CC BY-SA 4.0