HEALTH ASSESSMENT · STUDY GUIDE

Exam 5 Study Guide

This guide covers chapters 9 and 10. First you will examine everything above the clavicles: nodes, thyroid and trachea, eyes measured and not guessed, ears with the right pinna pull, and a mouth and throat exam that knows when to stop. Then you will examine the chest as a symmetry test: landmarks and lobes, a counted respiratory rate, fremitus, percussion and the sounds that mean consolidation, air or fluid. Work one chapter at a time. Read the "what to know" paragraphs, study the tables, then try each worked case with the steps covered. Finish each chapter with its ten self-test items. The cram sheet at the end puts the numbers and rules in one place.

WHAT THIS GUIDE COVERS

- Chapter 9 · exam order and bilateral comparison, skull, face and CN V and VII, central versus peripheral facial droop, the TMJ, ten cervical node chains and the malignant pattern, the supraclavicular node, trachea, thyroid and the swallow test, Snellen and Jaeger, confrontation fields, pupils and PERRLA, cardinal gaze, the red reflex, eye emergencies, otoscopy and tympanic membrane findings, whisper, Weber and Rinne, nose and sinuses, epistaxis, the oral cancer check, candidiasis versus leukoplakia, tonsil grading, Centor criteria, the airway stop rule, fontanels, charting and SBAR.
- Chapter 10 · the sternal angle and vertebra prominens, reference lines, lobes and fissures, respiratory rates by age, SpO_2 targets, chest shape and AP ratio, work of breathing, breathing patterns, tracheal position, expansion, fremitus and crepitus, percussion technique and tones, diaphragmatic excursion, breath sounds, adventitious sounds, voice-transmitted sounds, respiratory red flags, lifespan and skin tone, charting, delegation and SBAR.

CHAPTER 9

Assessing Head, Neck, Eyes, Ears, Nose and Throat

Read it in full: **Chapter 9 in the textbook**. Practice it in the lab: **Acuity, Pupils and Eye Emergencies** and **Otoscopy, the Drum and Weber-Rinne**.

What to know

Above the clavicles you use inspection and palpation most, percussion almost never, and auscultation only over the carotids and an enlarged thyroid. Sit the patient upright at your eye level and compare both sides at once; almost every abnormality here first shows as asymmetry. The abdomen remains the only region examined inspect, auscultate, percuss, palpate.

The skull should be normocephalic and atraumatic. Test CN VII by having the patient raise the brows, close the eyes tightly, smile and puff the cheeks. A droop with the **forehead spared** points to a central lesion such as stroke; a droop that **includes the forehead** points to a peripheral palsy such as Bell palsy. The mouth should open 3 to 6 cm; trismus with a sore throat suggests a deep neck infection.

Palpate the ten node chains with light pressure in a fixed order: preauricular, posterior auricular, occipital, tonsillar, submandibular, submental, superficial cervical, deep cervical, posterior cervical and supraclavicular. Describe location, size in cm, shape, consistency, mobility and tenderness. Tender, warm, soft, mobile and bilateral suggests inflammation. **Hard, fixed, matted, painless and unilateral** suggests malignancy at any size. A palpable supraclavicular node is always abnormal; the left (Virchow) node can signal gastric, pancreatic, esophageal or lung cancer.

Check that the trachea is midline. It is pushed **away** by tension pneumothorax or a large effusion and pulled **toward** atelectasis, fibrosis or pneumonectomy. The thyroid rises with a swallow; nodes do not. If the thyroid is enlarged, listen with the bell for a bruit (increased vascularity, as in Graves disease). Never palpate both carotids at once.

Visual acuity is a measured vital sign: Snellen at 20 feet, each eye covered with an occluder or palm, glasses on if worn. 20/40 means the patient sees at 20 feet what normal eyes see at 40. Legal blindness is 20/200 or worse in the better eye with best correction. Near vision uses a Jaeger card at 14 inches. Confrontation compares the patient's fields with yours. Normal pupils are 3 to 5 mm in room light, round, equal and reactive; chart the size in mm. Up to 1 mm of stable difference is physiologic anisocoria. A new unilateral dilated, fixed pupil with falling consciousness is uncal herniation: call now.

The six cardinal fields test CN III, IV and VI. A few beats of nystagmus at extreme lateral gaze are normal. Arcus senilis is normal over 60 but warrants a lipid check under 40. The red reflex is checked at every newborn and well-child visit; a white reflex (leukocoria) is an urgent referral. A chemical splash is irrigated first, for at least 15 to 20 minutes or to a pH of 7.0 to 7.4, inner to outer canthus, before acuity. Never remove an impaled object; shield both eyes. Sudden painless vision loss is a same-hour emergency.

Pain on moving the pinna or pressing the tragus points to **otitis externa**; ear pain without that tenderness points to otitis media. Mastoid tenderness suggests mastoiditis. For otoscopy, brace your hand on the head and pull the pinna **up and back** for adults and children 3 and older, **down and back** under 3. The normal drum is pearly gray with a cone of light at 5 o'clock on the right and 7 o'clock on the left. Red and bulging is acute otitis media; amber with bubbles is effusion; blood behind the drum after trauma suggests a basilar skull fracture.

The whispered voice test is the simplest screen. With a 512 Hz fork, **Weber** lateralizes to the bad ear in conductive loss and to the good ear in sensorineural loss. **Rinne** is normally air greater than bone (about 2 to 1); bone equal to or greater than air is a negative Rinne and means conductive loss on that side. Sudden one-sided sensorineural loss is urgent; steroids work best early, ideally within about 72 hours. New tinnitus or hearing loss on an ototoxic drug must be reported before the next dose. For presbycusis, speak lower, not louder.

Pale, boggy turbinates suggest allergy. Unilateral foul drainage in a toddler is a foreign body until proven otherwise. Clear drainage after head trauma may be CSF: no packing, no NG tube. For a nosebleed, sit upright leaning forward and pinch the soft nose for 10 to 15 minutes. In the mouth, pull the tongue aside to inspect the lateral borders and floor, the commonest oral cancer sites. White plaques that **scrape off** with a red base are candidiasis; a white patch that **does not** scrape off is leukoplakia and needs biopsy. Any oral lesion over two weeks is referred.

Grade tonsils: 1+ just visible, 2+ halfway to the uvula, 3+ touching the uvula, 4+ touching each other. The uvula should be midline and rise symmetrically (CN IX and X); the tongue should protrude midline (CN XII). Centor criteria for strep: fever over 38 °C, exudate, tender anterior nodes and no cough. **The stop rule:** fever, drooling, muffled voice, tripod posture or stridor means no tongue blade, no lying down, no IV and an airway team now. Infant fontanels: anterior

2.5 to 4 cm, closes at 12 to 18 months; posterior closes by 1 to 2 months. A bulging fontanel at rest suggests raised ICP; a sunken one suggests dehydration.

LOCK THESE IN

- Compare both sides at once; asymmetry is the first sign.
- Forehead spared: think stroke. Forehead involved: peripheral CN VII palsy.
- Hard, fixed, matted, painless node at any size, or any supraclavicular node, gets reported.
- Thyroid rises with a swallow; trachea pushed away by tension pneumothorax.
- Acuity as a fraction per eye; pupils charted in mm.
- Pinna up and back at 3 and older; down and back under 3.
- Weber to the bad ear and negative Rinne: conductive. Weber to the good ear: sensorineural.
- Drooling, stridor, tripod: no tongue blade, keep upright, airway team now.

Weber and Rinne: sorting a hearing loss in the right ear

Normal hearing

Weber: fork on the midline

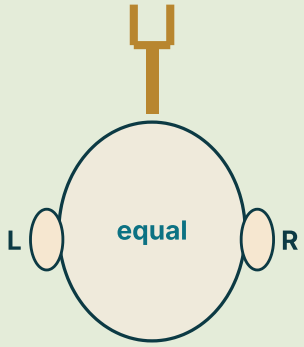

Heard equally in both ears

Rinne: mastoid, then ear

Rinne both ears: AC > BC (positive)

Normal Rinne ratio about 2 to 1

Conductive loss, right

Weber: fork on the midline

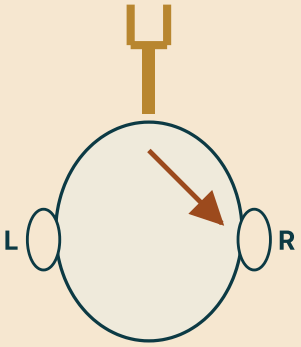

Lateralizes to the BAD (right) ear

Rinne: mastoid, then ear

Rinne right: BC ≥ AC (negative)

Causes: cerumen, effusion, perforation, otosclerosis

Sensorineural loss, right

Weber: fork on the midline

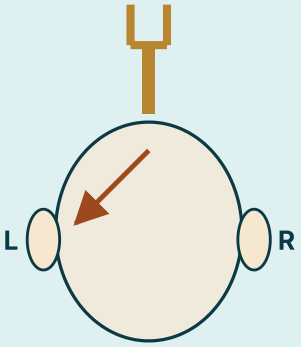

Lateralizes to the GOOD (left) ear

Rinne: mastoid, then ear

Rinne right: AC > BC (positive, both reduced)

Causes: aging, noise, ototoxic drugs

Use a 512 Hz fork. AC is air conduction; BC is bone conduction.

Where the Weber goes, and what the Rinne says. Conductive loss sends the Weber to the bad ear and flips the Rinne. Sensorineural loss sends the Weber to the good ear and leaves the Rinne positive.

Nodes, eyes and ears: expected versus abnormal

Finding	Expected	Abnormal and meaning
Cervical node	Non-palpable or under 1 cm, soft, mobile, non-tender	Hard, fixed, matted, painless: malignancy at any size
Supraclavicular node	Never palpable	Any palpable node; left is Virchow
Trachea	Midline	Away from lesion: tension pneumothorax, effusion; toward: atelectasis
Visual acuity	20/20 adult	20/200 or worse best eye corrected: legal blindness
Pupils	3 to 5 mm, equal, brisk	New unilateral dilated fixed pupil: herniation
Pinpoint pupils	Not expected	Opioid effect or pontine lesion
Red reflex	Present and symmetric	White reflex: urgent referral
Tympanic membrane	Pearly gray, cone of light at 5 (R) and 7 (L) o'clock	Red, bulging, immobile: acute otitis media
Weber	Heard equally	To bad ear: conductive; to good ear: sensorineural
Rinne	AC > BC, about 2 to 1	BC ≥ AC: conductive loss that side

Mouth and throat

Finding	Meaning	Action
White plaques that scrape off, red base	Candidiasis	Report; ask about inhaled steroids, antibiotics, diabetes
White patch that will not scrape off	Leukoplakia, precancerous	Refer for biopsy
Gum overgrowth	Drug induced hyperplasia (phenytoin, CCBs, cyclosporine)	Report, oral hygiene
Uvula deviated, trismus, one sided swelling	Peritonsillar abscess	Urgent evaluation
Tonsils 1+ to 4+	1+ visible; 2+ halfway; 3+ touch uvula; 4+ touch each other	Chart size, color, exudate separately
Centor criteria	Fever, exudate, tender anterior nodes, no cough	Strep testing
Drooling, muffled voice, stridor	Airway threat, such as epiglottitis	No tongue blade; airway team
Dry sticky mucosa, furrowed tongue	Dehydration; reliable in any skin tone	Assess intake and output

Worked cases

WORKED CASE 1 · READING A SNELLEN RESULT

Mr. Ford, wearing his glasses, reads the 20/70 line with his left eye, missing one letter.

STEP 1 · CHART IT

"Corrected acuity 20/70 − 1 OS."

STEP 2 · EXPLAIN IT

At 20 feet he reads what a person with normal vision reads at 70 feet.

STEP 3 · COMPARE WITH LEGAL BLINDNESS

20/200 or worse in the better eye with correction. 20/70 is not that, but it is a real deficit.

STEP 4 · ACT ON IT

If this is new, report it with the time course and the other eye's acuity, and plan for safety.

WORKED CASE 2 · WEBER AND RINNE TOGETHER

Ms. Lane reports muffled hearing on the right. Weber lateralizes to the right. On the right Rinne, bone conduction equals air conduction.

STEP 1 · READ THE WEBER

It goes to the right ear, the side she says is bad.

STEP 2 · READ THE RINNE

BC ≥ AC on the right is a negative Rinne.

STEP 3 · COMBINE

Weber to the bad ear plus a negative Rinne: conductive loss in the right ear.

STEP 4 · THINK OF CAUSES

Cerumen, effusion, perforation or otosclerosis. Look with the otoscope next.

WORKED CASE 3 · A NODE THAT LEAVES THE ROOM WITH YOU

Mr. Ruiz, 58, has a left supraclavicular node 2.5 cm across, hard, painless and fixed.

STEP 1 · CHECK THE LOCATION RULE

Any palpable supraclavicular node is abnormal at any size.

STEP 2 · CHECK THE PATTERN

Hard, fixed and painless is the malignant pattern; painless is not reassuring.

STEP 3 · KNOW THE LINK

The left node (Virchow) drains the thoracic duct and may signal gastric, pancreatic, esophageal or lung cancer.

STEP 4 · ACT

Urgent provider evaluation, with the node described by location, size, shape, consistency, mobility and tenderness.

WORKED CASE 4 · A NECK AFTER THYROID SURGERY

At 1615 Mr. Alvarez, day zero after thyroidectomy, has a fuller neck than at 1545, a taut dressing, hoarseness, throat tightness and RR 26 with noisy inspiration.

STEP 1 · RECOGNIZE IT

Expanding neck hematoma compressing the airway.

STEP 2 · ACT FIRST

Sit him upright, oxygen, stay with him, emergency airway tray and suture removal set at the bedside, call for help.

STEP 3 · SBAR

Situation and concern for the airway; background of the surgery and enoxaparin; the measured findings; then the request: come now, and do you want the wound opened if he worsens?

TRAPS PEOPLE FALL INTO

- **Charting "HEENT within normal limits."** Chart what you checked: nodes, trachea, thyroid, pupils in mm, acuity.
- **Pressing hard to find nodes.** Heavy pressure pushes small nodes away.
- **Calling a painless node reassuring.** Painless is part of the malignant pattern.
- **Testing acuity before irrigating a chemical splash.** Irrigate first, for at least 15 to 20 minutes.
- **Pulling the pinna up and back in a 2 year old.** Under 3 it is down and back.
- **Mistaking peripheral scleral yellow or scleral melanin for jaundice.** Check the sclera next to the iris and the hard palate.
- **Skipping the lateral tongue and floor of the mouth.** They are the commonest oral cancer sites.
- **Putting a tongue blade in a drooling, stridorous child.** It can close the airway completely.

Chapter 9 self-test · ten items

1. A patient has a right sided facial droop, but he can still wrinkle his forehead on both sides. What does this pattern suggest?

A. A peripheral cranial nerve palsy
B. A normal facial asymmetry
C. A central lesion such as stroke
D. A temporomandibular problem

C. A central lesion such as stroke Forehead sparing points to a central lesion. A droop including the forehead points to a peripheral palsy such as Bell palsy.

2. Which node finding needs a provider report even though it is under 1 cm?

A. A soft, mobile, tender node
B. A warm node with a sore throat
C. Two small nodes, both mobile
D. A hard, fixed, painless node

D. A hard, fixed, painless node The malignant pattern is reportable at any size. Tender, mobile nodes with an infection are usually reactive.

3. A short of breath patient has absent breath sounds on the right and a trachea shifted to the left. What is most likely?

A. Right lower lobe atelectasis
B. Right tension pneumothorax
C. Left sided pneumonia
D. Right lower lobe pneumonia

B. Right tension pneumothorax Air under pressure pushes the trachea away from the affected side. Atelectasis pulls it toward the affected side.

4. A patient swallows water while the nurse watches a neck mass. The mass rises. What is it most likely?

A. Thyroid gland tissue
B. A cervical lymph node
C. A carotid artery bulge
D. A thyroglossal cyst

A. Thyroid gland tissue Thyroid tissue rises with swallowing. A thyroglossal duct cyst rises when the tongue is stuck out.

5. Two hours ago both pupils were 3 mm and brisk. Now the right is 6 mm and fixed, and the patient is harder to rouse. What is the priority?

A. Recheck at the next neuro check
B. Dim the lights, recheck in 15 min
C. Chart physiologic anisocoria
D. Call a rapid response right now

D. Call a rapid response right now A new unilateral fixed dilated pupil with falling consciousness suggests CN III compression from herniation.

6. How should the nurse straighten the ear canal of an 18 month old for otoscopy?

A. Pull the pinna up and back
B. Pull the pinna straight out
C. Pull the pinna down and back
D. Push the tragus forward

C. Pull the pinna down and back Under 3 years the canal angles upward, so downward traction aligns it.

7. Tragus pressure causes pain, but the tympanic membrane looks normal. What is most likely?

A. Otitis externa
B. Acute otitis media
C. Mastoiditis
D. Otitis media with effusion

A. Otitis externa Pain on manipulating the pinna or tragus localizes the problem to the canal.

8. The Weber test lateralizes to the left ear, and both Rinne tests are positive. A loss on the right is suspected. Which type?

A. Conductive loss on the right
B. Sensorineural loss on the right
C. Conductive loss on the left
D. Normal hearing on both sides

B. Sensorineural loss on the right Weber goes to the good ear in sensorineural loss, and the Rinne stays positive.

9. Tonsils touch the uvula but not each other. What grade is this?

A. 1+
B. 2+
C. 3+
D. 4+

C. 3+ 1+ just visible, 2+ halfway to the uvula, 3+ touching the uvula, 4+ touching each other.

10. A 4 year old has a high fever, drools, has a muffled voice and sits forward with stridor. What must the nurse avoid?

A. Examining the throat with a tongue blade
B. Keeping the child upright on a parent's lap
C. Giving oxygen held near the child's face
D. Calling the airway team to the bedside

A. Examining the throat with a tongue blade Instrumenting the pharynx can cause complete obstruction. Keep the child calm and upright and get the airway team.

Assessing the Thorax and Lungs

Read it in full: **Chapter 10 in the textbook**. Practice it in the lab: **Lobe Map, Exam Order and the Respiratory Baseline** and **Auscultation and Voice-Transmitted Sounds**.

What to know

Every lung finding needs a rib level and a reference line. Find the **sternal angle** (angle of Louis) about 5 cm below the suprasternal notch; the second rib joins there, so the space below is the second intercostal space. It also marks the tracheal bifurcation (about T4 to T5). Behind, C7 is the **vertebra prominens**, and the scapular tips sit at about the seventh rib. Lines: midsternal, midclavicular, anterior, mid and posterior axillary, scapular and vertebral. The costal angle is normally under 90 degrees.

The right lung has three lobes, the left two plus the lingula. The oblique fissure runs from about T3 behind to the sixth rib at the midclavicular line, so the back below the scapular tips is lower lobe. The right horizontal fissure runs from the fourth rib at the sternum to the fifth rib at the midaxillary line, so the **right middle lobe is heard only in front and at the side**. Apices rise 2 to 4 cm above the clavicles. Lower borders: rib 6 midclavicular, rib 8 midaxillary, T10 behind. Dullness at the right base near rib 6 is normal liver.

Count respirations for 30 seconds and double if regular, or a full 60 seconds if irregular, extreme or in an infant, without announcing it. Chart rate, depth, rhythm, effort and SpO_2 with the device and flow. Rates: newborn 30 to 60, infant 30 to 53, toddler 22 to 37, preschool 20 to 28, school age 18 to 25, adolescent and adult 12 to 20. A sustained rate over 24 in an older adult is a sepsis and pneumonia screen. In pregnancy the rate stays about the same while tidal volume rises 30 to 40%. SpO_2 90% is about a PaO_2 of 60 mm Hg; chronic CO_2 retainers often target 88 to 92%, but never withhold oxygen from a severely hypoxemic patient.

Inspect first. The adult AP to transverse ratio is about 1:2; a barrel chest nears 1:1 with horizontal ribs and a costal angle over 90 degrees (normal in infants). Normal I:E ratio is about 1:2. Look for tripod posture, words per breath, retractions, nasal flaring, grunting, head bobbing, accessory muscle use and paradoxical movement. Clubbing means months of hypoxemia.

Patterns: tachypnea over 20, bradypnea under 12 (check sedation), Kussmaul (deep, fast, regular: metabolic acidosis), Cheyne-Stokes (crescendo-decrescendo with 15 to 60 second apneas), Biot (irregular with abrupt apneas: ominous), apnea of 20 seconds or more in an infant. Orthopnea is charted by the number of pillows.

Palpate with purpose. Chest **expansion**: thumbs at the tenth rib should separate 3 to 5 cm symmetrically; the side that lags is the abnormal side. Tactile **fremitus** ("ninety-nine") is strongest near the large airways and fades at the bases. Solid lung conducts better, so fremitus **increases** in consolidation. Air, fluid or fat conduct worse, so fremitus **decreases** in pneumothorax, effusion, emphysema, an obstructed bronchus or a thick chest wall. Crepitus feels like bubble wrap; mark its border and time and escalate.

Percussion reads about 5 to 7 cm deep. Strike the pleximeter DIP joint with the plexor fingertip from the wrist, two taps, withdraw, over interspaces only, side to side in a ladder. Tones: **flatness** (muscle, bone; massive effusion), **dullness** (liver, heart; over lung means consolidation, atelectasis, effusion), **resonance** (normal lung), **hyperresonance** (emphysema, asthma, pneumothorax; normal in a child's thin chest), **tympany** (gastric bubble; large pneumothorax). **Diaphragmatic excursion** is the distance between the dull point on full expiration and full inspiration along the scapular line: 3 to 5 cm expected, up to 7 to 8 cm in a tall fit adult.

Auscultate on bare skin with the diaphragm, mouth open, one full breath per site: back from above the scapulae to T10, the sides at the midaxillary line, then the front to the sixth rib. **Vesicular** sounds (soft, inspiration about 3:1) belong in the periphery; **bronchovesicular** (I = E) near the first and second interspaces and between the scapulae; **bronchial** (loud, expiration longer, with a pause) only over the trachea and manubrium. Bronchial sounds in the periphery mean consolidation. Bronchovesicular sounds throughout are normal in children.

Adventitious sounds: **fine crackles** (brief, high, end-inspiratory: edema, pneumonia, fibrosis, atelectasis), **coarse crackles** (wet, lower), **wheezes** (musical, mostly expiratory: bronchospasm), **rhonchi** (low, snoring, often clear with cough), **stridor** (harsh, inspiratory, upper airway: emergency) and a **pleural friction rub** (grating, both phases). Have the patient cough: sounds that clear were secretions. A **silent chest** in a wheezing asthmatic means airflow has dropped too low to make sound: impending arrest.

Voice sounds confirm consolidation: **bronchophony** ("ninety-nine" louder and clearer), **egophony** ("ee" sounds like "aa"), and **whispered pectoriloquy** (a whisper heard clearly; the most sensitive). Consolidation: dull, increased fremitus, bronchial sounds, positive voice tests. The earliest sign of hypoxia is restlessness or new confusion, not cyanosis. UAP may count respirations, report a pulse oximetry number, position and remind about a spirometer already taught; auscultation, interpretation, oxygen titration, first teaching and any unstable patient stay with the RN.

LOCK THESE IN

- Sternal angle = second rib; scapular tips = about rib 7; C7 = vertebra prominens.
- Right middle lobe and lingula: front and side only. Back below the scapulae: lower lobes.
- Adult 12 to 20; newborn 30 to 60; sustained over 24 in an older adult is a red flag.
- Expansion and excursion both 3 to 5 cm; the lagging side is the abnormal side.
- Fremitus up in consolidation; down with air, fluid or a thick chest wall.
- Resonance is normal lung; dull means solid or fluid; hyperresonant means too much air.
- Bronchial sounds in the periphery plus egophony mean consolidation.
- Restlessness precedes cyanosis; a silent chest and stridor are emergencies.

Which lobe lies under your stethoscope?

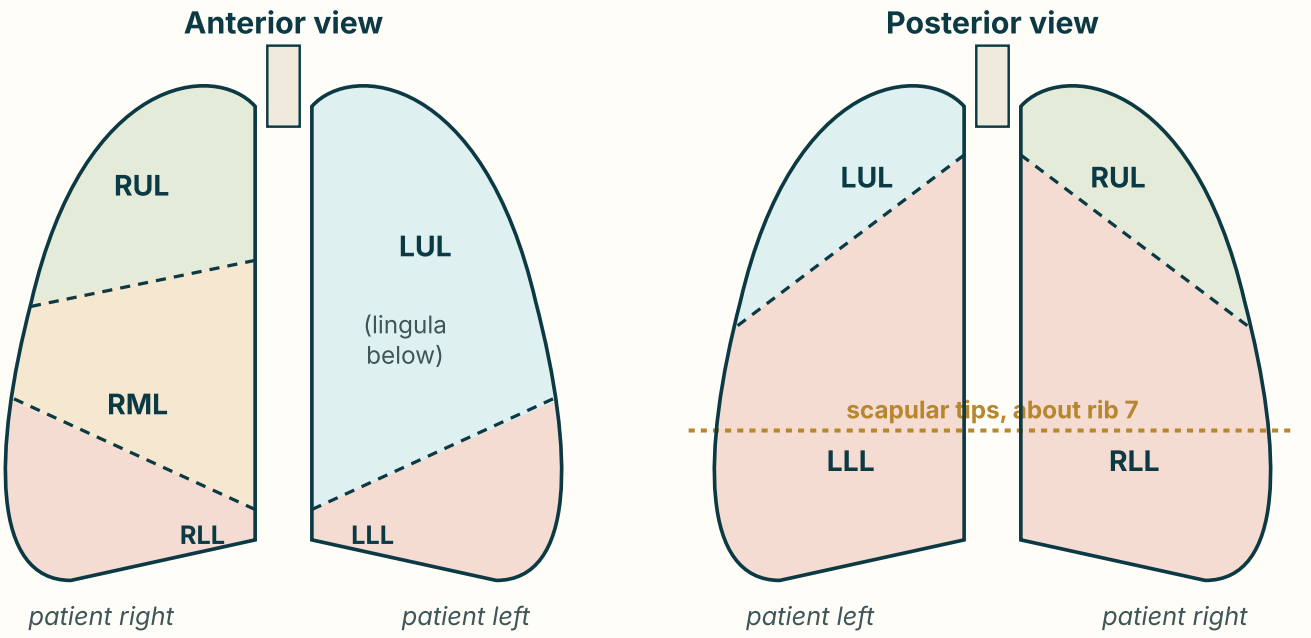

Anterior and lateral only
The right middle lobe and the lingula are never heard on the back. Listen at the midaxillary line.

Back below the scapular tips
is lower lobe. Oblique fissure: about T3 behind to rib 6 at the midclavicular line.

Front, side and back hear different lobes. Most of the back is lower lobe, most of the front is upper lobe, and the right middle lobe lives only in front and at the side. A posterior-only exam misses it.

Patterns that sort the big four

Finding	Consolidation	Pneumothorax	Pleural effusion	Atelectasis (large)
Expansion	Reduced on that side	Reduced on that side	Reduced on that side	Reduced on that side
Fremitus	Increased	Decreased or absent	Decreased or absent	Decreased
Percussion	Dull	Hyperresonant or tympanic	Dull to flat	Dull
Breath sounds	Bronchial in the periphery	Diminished or absent	Diminished or absent	Diminished
Voice sounds	Increased (egophony, pectoriloquy)	Decreased	Decreased; egophony just above the fluid	Decreased
Trachea	Midline	Away if tension	Away if large	Toward the collapsed side

Breath and adventitious sounds

Sound	Description	Meaning
Vesicular	Soft, low, inspiration about 3:1	Normal in the periphery
Bronchovesicular	Moderate, I = E	Normal near the main bronchi; in adult periphery suggests early consolidation
Bronchial	Loud, high, expiration longer with a pause	Normal over the trachea only; in the periphery means consolidation
Fine crackles	Brief, high, end-inspiratory, like Velcro	Edema, pneumonia, fibrosis, atelectasis
Coarse crackles	Wet, lower, early inspiratory	Secretions in larger airways
Wheeze	Continuous, musical, mostly expiratory	Bronchospasm; fixed and one sided suggests a foreign body or tumor
Rhonchi	Low, snoring, often clears with cough	Mucus in large airways
Stridor	Harsh, inspiratory, heard without a stethoscope	Upper airway obstruction: emergency
Friction rub	Grating, both phases, localized, painful	Pleural inflammation

Worked cases

WORKED CASE 1 · MEASURING DIAPHRAGMATIC EXCURSION

On the right scapular line, the note turns dull 3.5 cm below a reference mark on full inspiration and 1.0 cm above it on full expiration.

STEP 1 · PICTURE THE TWO MARKS

The expiration mark is higher; the inspiration mark is lower.

STEP 2 · ADD THE DISTANCES

1.0 cm above + 3.5 cm below = 4.5 cm apart.

STEP 3 · COMPARE

4.5 cm is inside the 3 to 5 cm expected range.

STEP 4 · CHECK THE OTHER SIDE

Asymmetry worries more than the absolute number; a side moving under 3 cm suggests effusion, atelectasis, phrenic injury or splinting.

WORKED CASE 2 · PUTTING THE FINDINGS TOGETHER

Mrs. Grant has a fever. Over the right lower back: dull percussion, increased fremitus, bronchial breath sounds, and "ee" heard as "aa."

STEP 1 · LIST THE FINDINGS

Dull, more fremitus, bronchial sounds in the periphery, positive egophony.

STEP 2 · MATCH THE PATTERN

Solid lung conducts sound better: consolidation.

STEP 3 · COMPARE THE ALTERNATIVES

Effusion and pneumothorax would both reduce fremitus and breath sounds.

STEP 4 · ACT

Chart the location by rib level and line, check SpO_2 and RR, and escalate for a likely pneumonia.

WORKED CASE 3 · THE SILENT CHEST

Mr. Odum has asthma and has wheezed loudly for an hour. His family is relieved that "the wheezing stopped." He is sitting forward, speaking two words at a time, and is drowsy.

STEP 1 · DO NOT BE REASSURED

A wheeze needs airflow. When airflow falls far enough, the wheeze stops.

STEP 2 · READ THE OTHER SIGNS

Tripod posture, two word speech and drowsiness mean exhaustion.

STEP 3 · ACT

Rapid response now, keep him upright, prescribed oxygen and bronchodilator, stay with him.

CHART IT TRUTHFULLY

Never document that the wheezing "resolved."

WORKED CASE 4 · A DESATURATION AFTER HIP SURGERY

Mrs. Alvarez, 74, day two after a hip arthroplasty, has RR 30, HR 118, BP 104/62, SpO_2 88% on room air (95% on admission), crackles at both bases that do not clear, dullness at the right base, and new confusion.

STEP 1 · ACT FIRST

Sit her up, start oxygen under the standing protocol, stay.

STEP 2 · SITUATION AND BACKGROUND

Your name and unit, the patient, the new dyspnea and SpO_2 88%; heart failure, COPD, bed rest since surgery.

STEP 3 · ASSESSMENT

The numbers, accessory muscles, crackles, right base dullness, no stridor, trachea midline, new confusion, SpO_2 92% on 2 L.

STEP 4 · RECOMMENDATION

"Please come now. I am requesting a chest x-ray, an ABG and an oxygen order. Do you want a rapid response called?" Read back the orders.

TRAPS PEOPLE FALL INTO

- **Listening only on the back.** The right middle lobe and lingula are heard only in front and at the side.
- **Calling dullness at the right base near rib 6 consolidation.** That is the liver.
- **Listening through the gown.** Fabric rustle sounds like crackles.
- **Percussing over ribs or the scapula.** Bone gives a dull note that means nothing.
- **Reading a quiet chest in an asthma attack as better.** A silent chest means airflow is failing.
- **Confusing stridor with a wheeze.** Stridor is inspiratory and upper airway; it buys minutes.
- **Waiting for cyanosis.** Restlessness and confusion come first; cyanosis is late.
- **Charting "lungs clear" and nothing else.** Chart rate, effort, expansion, percussion, sounds, the sites and key negatives.

Chapter 10 self-test · ten items

1. A firm ridge about 5 cm below the suprasternal notch marks which landmark?

A. The xiphoid process at the sixth rib
B. The vertebra prominens at C7
C. The costal angle at the tenth rib
D. The sternal angle at the second rib

D. The sternal angle at the second rib The sternal angle is where the second rib joins, so the space below it is the second intercostal space.

2. To detect right middle lobe pneumonia, where must the nurse listen?

A. The back below the right scapula
B. The front and right side of the chest
C. The back above the right scapula
D. Over the right supraclavicular area

B. The front and right side of the chest The right middle lobe lies in front and at the midaxillary line, never on the back.

3. What is the expected respiratory rate for a healthy 4 year old?

A. 30 to 60 breaths per minute
B. 12 to 20 breaths per minute
C. 20 to 28 breaths per minute
D. 22 to 37 breaths per minute

C. 20 to 28 breaths per minute Preschool children (3 to 5 years) breathe 20 to 28 times per minute.

4. The right chest lags on inspiration and fremitus is increased on that side. What is most likely?

A. A right sided pneumothorax
B. Consolidation, as in pneumonia
C. A large right pleural effusion
D. Emphysema in the right lung

B. Consolidation, as in pneumonia Solid lung conducts vibration better, so fremitus rises. Air and fluid lower it.

5. An adult with sudden dyspnea has hyperresonance over the left upper chest. What should the nurse check next?

A. Left breath sounds and the trachea
B. Bowel sounds in all four quadrants
C. The right lower lobe for dullness
D. Capillary refill in the left hand

A. Left breath sounds and the trachea Hyperresonance suggests too much air, such as pneumothorax. Absent sounds and a shifted trachea point to tension.

6. A nurse marks the diaphragm level on full expiration and full inspiration in a healthy adult. About how far apart should the marks be?

A. 1 to 2 cm
B. 6 to 8 cm
C. 8 to 10 cm
D. 3 to 5 cm

D. 3 to 5 cm Expected excursion is 3 to 5 cm, up to 7 to 8 cm in a tall, fit adult.

7. Bronchial breath sounds are heard over the right posterior base. What do they suggest?

A. Normal sounds for that area
B. Air trapping from emphysema
C. A large pleural effusion there
D. Consolidated lung at that site

D. Consolidated lung at that site Bronchial sounds belong only over the trachea. In the periphery, solid lung is carrying airway sound outward.

8. Low pitched snoring sounds clear after the patient coughs. What were they?

A. Fine end-inspiratory crackles
B. Inspiratory stridor
C. Rhonchi in large airways
D. A pleural friction rub

C. Rhonchi in large airways Rhonchi come from secretions in large airways and often clear with an effective cough.

9. Which voice test is the most sensitive sign of consolidation?

A. Whispered pectoriloquy
B. Bronchophony testing
C. Egophony, E to A
D. Tactile fremitus check

A. Whispered pectoriloquy If a whisper comes through clearly, the lung beneath is consolidated until proven otherwise.

10. On a stable patient, which respiratory task may the RN delegate to a UAP?

A. Teaching incentive spirometry for the first time
B. Counting and reporting the respiratory rate
C. Titrating oxygen to the ordered saturation
D. Interpreting a downward trend in SpO_2

B. Counting and reporting the respiratory rate UAP may collect and report data on stable patients. Teaching, titration and interpretation stay with the RN.

ONE PAGE

Cram sheet

Everything from chapters 9 and 10 in one place. Cover the right column and see if you can rebuild each row.

Numbers to know

Item	Value	Note
Mouth opening	3 to 6 cm	Under 3 cm abnormal; trismus with sore throat is urgent
Neck ROM	Flexion 45, extension 55, lateral bend 40, rotation 70 degrees	Nuchal rigidity with fever: emergency
Acuity	Snellen at 20 ft; Jaeger at 14 in	Legal blindness 20/200 best eye corrected
Visual fields	About 50 up, 60 nasal, 70 down, 90 temporal degrees	By confrontation
Pupils	3 to 5 mm room light; physiologic difference up to 1 mm	Chart size in mm
Eye irrigation	At least 15 to 20 min or pH 7.0 to 7.4	Inner to outer canthus
Epistaxis	Pinch 10 to 15 min, upright, leaning forward	Over 20 to 30 min or on anticoagulants: call
Fontanels	Anterior 2.5 to 4 cm, closes 12 to 18 months	Posterior closes by 1 to 2 months
Newborn head	32 to 38 cm	Tracked to 24 to 36 months
Respiratory rates	Newborn 30 to 60; preschool 20 to 28; adult 12 to 20	Infant apnea 20 s or more
SpO_2	95 to 100%; 90% is about PaO_2 60	Chronic CO_2 retainers 88 to 92%
Chest	AP:transverse about 1:2; I:E about 1:2	Costal angle under 90 degrees
Expansion and excursion	Both 3 to 5 cm	Excursion up to 7 to 8 cm in tall fit adults
Lung borders	Rib 6 MCL, rib 8 MAL, T10 behind	Apices 2 to 4 cm above clavicles

Quick interpretations

Test or sign	Result	Meaning
Facial droop	Forehead spared vs involved	Central (stroke) vs peripheral CN VII
Weber + Rinne	To bad ear + BC ≥ AC	Conductive loss
Weber + Rinne	To good ear + AC > BC	Sensorineural loss
Scrape test	Scrapes off vs does not	Candidiasis vs leukoplakia
Trachea	Away vs toward	Tension pneumothorax or effusion vs atelectasis
Fremitus	Up vs down	Consolidation vs air, fluid, thick wall
Cough test	Clears vs persists	Rhonchi or atelectatic crackles vs tissue disease

Rules that are not numbers

Topic	The rule
Supraclavicular node	Always abnormal; left is Virchow.
Pinna traction	Up and back at 3 and older; down and back under 3.
Airway stop rule	Drooling, muffled voice, tripod, stridor: no tongue blade, upright, airway team.
Exam route	Back, sides at the midaxillary line, front; side to side ladder.
Hypoxia	Restlessness and confusion come before cyanosis.
Delegation	UAP count, report and position; the RN auscultates, interprets, titrates and teaches.

Dr. Garg Learning · CC BY-SA 4.0